ORIGINAL RESEARCH

# Characterization of the Mechanism and Substrate of Atrial Tachycardia Using Ultra-High-Density Mapping in Adults With Congenital Heart Disease: Impact on Clinical Outcomes

Lilian Mantziari, MD, PhD; Charles Butcher, MRCP; Rui Shi, MD, PhD; Andrianos Kontogeorgis, MBBCh, PhD; Aaisha Opel, MBBS, PhD; Zhong Chen, MBBS, PhD; Shouvik Haldar, MBBS, PhD; Sandeep Panikker, MRCP, PhD; Wajid Hussain, MBChB; David Gareth Jones, MRCP, PhD; Michael A. Gatzoulis, MD, FRCP; Vias Markides, MD, FRCP; Sabine Ernst, MD;* Tom Wong, MD, FRCP*

***Background*—**Atrial tachycardia (AT) is common in patients with adult congenital heart disease and is challenging to map and ablate. We used ultra-high-density mapping to characterize the AT mechanism and investigate whether substrate characteristics are related to ablation outcomes.

***Methods and Results*—**A total of 50 ATs were mapped with ultra-high-density mapping in 23 procedures. Patients were followed up for up to 12 months. Procedures were classified to group A if there was 1 single AT induced (n=12) and group B if there were ≥2 ATs induced (n=11 procedures). AT mechanism per procedure was macro re-entry (n=10) and localized re-entry (n=2) in group A and multiple focal (n=6) or multiple macro re-entry (n=5) in group B. Procedure duration, low voltage area (0.05–0.5 mV), and low voltage area indexed for volume were higher in group B (159 [147–180] versus 412 [352–420] minutes, $P<0.001$, 22.6 [12.2–29.8] versus 54.2 [51.1–61.6] $cm^2$, $P=0.014$ and 0.17 [0.12–0.21] versus 0.26 [0.23–0.27] $cm^2/mL$, $P=0.024$ accordingly). Dense scar (<0.05 mV) and atrial volume were similar between groups. Acute success and freedom from arrhythmia recurrence were worse in group B (100% versus 77% $P=0.009$ and 11.3, CI 9.8–12.7 versus 4.9, CI 2.2–7.6 months, log rank $P=0.004$). Indexed low voltage area ≥0.24 $cm^2/mL$ could predict recurrence with 100% sensitivity and 77% specificity (area under the curve 0.923, $P=0.007$).

***Conclusions*—**Larger low voltage area but not dense scar is associated with the induction of multiple focal or re-entry ATs, which are subsequently associated with longer procedure duration and worse acute and midterm clinical outcomes. **(*J Am Heart Assoc.* 2019;8:e010535. DOI: 10.1161/JAHA.118.010535.)**

**Key Words:** ablation • atrial tachycardia • congenital heart disease • electrophysiology mapping • high density mapping • substrate mapping

Downloaded from http://ahajournals.org by on March 29, 2019

It is well established that atrial arrhythmias are related to increased morbidity and mortality in adults with congenital heart disease.[1] Catheter ablation has been shown to be more effective in achieving and maintaining sinus rhythm compared with antiarrhythmic drugs; however, the success rates of catheter ablation remain suboptimal in this cohort.[2] This is largely because of the complexity of the arrhythmia substrate in congenital heart disease. Surgical scar and mechanical stress are the main factors among others contributing to a complex arrhythmia substrate, which can give rise to focal, micro- and macro- re-entry tachycardias that can be challenging to map and ablate. Three-dimensional electroanatomical mapping systems have proven their usefulness to guide catheter ablation of these arrhythmias.[3] More recently, there has been an emergence of mapping catheters with closely spaced multipolar small electrodes paired with ultra-high-resolution automatic mapping which have been shown to be more precise in mapping the electrical characteristics of the atrial and ventricular arrhythmias.[4–6] The aim of the current study is to report on the feasibility of using this system in an

*From the Royal Brompton and Harefield NHS Foundation Trust, London, United Kingdom.*

Accompanying Videos S1 through S4 are available at https://www.ahajournals.org/doi/suppl/10.1161/JAHA.118.010535

*Dr Ernst and Dr Wong are co-senior authors.

**Correspondence to:** Tom Wong, MD, FRCP, Heart Rhythm Centre, NIHR Cardiovascular Biomedical Research Unit, Institute of Cardiovascular Medicine and Science, The Royal Brompton and Harefield NHS Foundation Trust, Imperial College, Sydney St, London SW3 6NP, United Kingdom. E-mail: t.wong2@rbht.nhs.uk

Received August 9, 2018; accepted January 2, 2019.

© 2019 The Authors. Published on behalf of the American Heart Association, Inc., by Wiley. This is an open access article under the terms of the Creative Commons Attribution-NonCommercial License, which permits use, distribution and reproduction in any medium, provided the original work is properly cited and is not used for commercial purposes.

## Clinical Perspective

### What Is New?

- Low voltage area identified with ultra-high-density mapping, but not dense scar area or chamber volume was smaller in adults with congenital heart disease with a single atrial tachycardia.
- Adults with congenital heart disease with larger low voltage area had complex atrial tachycardias, longer procedure duration, and worse acute and midterm outcomes.
- Low voltage area indexed for volume relates to the clinical success of catheter ablation of atrial tachycardia.

### What Are the Clinical Implications?

- Our findings suggest that atria with higher burden of low voltage area are more likely to maintain atrial tachycardia even when the clinical tachycardia is successfully ablated by lending a different atrial channel of low voltage to serve as the critical isthmus of the circuit.
- Increased atrial volume is not related to poor outcome unless the low voltage burden is high.

adult congenital heart disease population; to characterize the mechanism of atrial tachycardia (AT); and to investigate whether differences in arrhythmia mechanism/substrate and scar burden are related to outcomes.

## Methods

The data that support the findings of this study are available from the corresponding author upon reasonable request.

## Patients

All consecutive adult patients with congenital heart disease, who had ultra-high-resolution automatic mapping and ablation for AT from October 2014 until February 2017, were included in the study. Patient demographics, history, and periprocedural data were collected from hospital records in retrospect. The complexity of the congenital heart disease was classified according to the Bethesda classification.[7] Three-dimensional maps were analyzed offline blinded to the clinical outcome. All patients gave written informed consent for the data to be included in the study. The study was approved by the National Research Ethics Committee.

## Procedures

All procedures were performed on uninterrupted warfarin, and direct oral anticoagulants were minimally interrupted. Antiarrhythmic drugs except amiodarone were routinely interrupted for 5 half-lives before the procedure with the exception of patients with previous history of hemodynamic compromise during tachycardia. In the latter cases, the decision regarding antiarrhythmic drugs was tailored from minimal to no interruption. Intravenous heparin was given after femoral venous access to achieve and maintain an activated clotting time >350 ms throughout the procedure.

A deflectable decapolar catheter was advanced in the coronary sinus or other stable anatomical position when the coronary sinus was not available. The multipolar basket catheter (IntellaMap Orion catheter, Boston Scientific) was advanced to the right atrium/systemic venous atrium/common atrium for mapping. In case of mapping the left/subpulmonary venous atrium, a transseptal or transbaffle puncture was performed using standard technique. Long sheaths (either Agillis-Saint Jude Medical, SL0 8.5F-Saint Jude Medical or Mullins 9F-Medtronic) were used to deliver the multipolar basket catheter. Ultra-high-resolution voltage and activation time maps were acquired to guide radiofrequency ablation at 20 to 40 Watts, using a 4-mm tip ablation catheter (Blazer or Intellanav open irrigated ablation catheter, Boston Scientific). Programmed electrical stimulation was attempted after achieving sinus rhythm until no mappable atrial arrhythmia was inducible.

## Ultra-High-Density Mapping

The ultra-high-density mapping system is described in detail in previous publications.[5,8] In brief, it utilizes a

**Table 1.** Congenital Defects According to the Bethesda Classification

| Bethesda Classification | Type of Defect |
|---|---|
| Complex, n=10 | Fontan (3) |
| | TGA (2) |
| | Single ventricle+TGA+common atrium/single ventricle ASD+VSD (2) |
| | VSD/Eisenmenger (1) |
| | Pulmonary stenosis-ccTGA/pulmonary atresia (2) |
| Moderate, n=5 | AVSD repair (2) |
| | Coarctation repair, residual VSD (1) |
| | Ebstein's anomaly (1) |
| | Cor triatriatum repair (1) |
| Simple, n=5 | ASD surgically repaired (3) |
| | Valvular defects/Ross procedure (2) |

ASD indicates atrial septal defect; AVSD, atrioventricular septal defect; cc, congenitally corrected; TGA, transposition of the great arteries; VSD, ventricular septal defect.

Downloaded from http://ahajournals.org by on March 29, 2019

**Table 2.** Group A: Single AT

| Type of AT Per Procedure (n=12) | Details of AT | Anatomical Substrate/Surgery | Previous Ablation | Acute Outcome | Medium-Term Outcome |
|---|---|---|---|---|---|
| Macro-reentry (10) | | | | | |
| Atriotomy related (5) | Dual loop RA free wall atriotomy and CTI | Repaired Cor Triatriatum | 0 | Termination on ablation and confirmation of block | No recurrence at 7-mo follow-up |
| | RA free wall atriotomy re-entry (Figure 1) | Atriopulmonary Fontan | 0 | Termination on ablation and confirmation of block | No recurrence at 7-mo follow-up |
| | Dual loop RA free wall atriotomy and CTI | ASD surgically repaired | 0 | Termination on ablation and confirmation of block | No recurrence at 9-mo follow-up |
| | Dual loop RA, free wall atriotomy, and CTI (Figure 2) | Ross procedure | 0 | Termination on ablation and confirmation of block | No recurrence at 12-mo follow-up |
| | RA-SVC junction scar re-entry (Figure 3) | DORV, previous Rastelli and RV-PA conduit | Previously 2 ATs ablated, 1 atriotomy re-entry and second re-entry close to RA roof-SVC junction | Termination on ablation and confirmation of block | No recurrence 3-mo follow-up |
| CTI (2) | CTI-dependent flutter | ASD surgically repaired | Previous AVNRT ablation | Termination on ablation and confirmation of block | No recurrence at 3-mo follow-up |
| | CTI-dependent flutter | VSD, Eisenmenger's physiology | 0 | Termination on ablation and confirmation of block | No recurrence at 12-mo follow-up |
| Related to previous ablation lines (3) | Roof re-entry | ASD surgically repaired, mitral and tricuspid valve repair and Maze procedure | Previous surgical Maze | Termination on ablation and confirmation of block | No recurrence at 3-mo follow-up |
| | Roof re-entry | Coarctation repair and mechanical aortic valve replacement, residual VSD | Previous AF ablation and AT ablation ×2 | Termination on ablation | No recurrence at 6-mo follow-up |
| | CS ostium re-entry | Previous Ross procedure, then prosthetic AVR and PVR | Previous CTI | Termination on ablation | No recurrence at 12-mo follow-up |
| Localized reentry (2) | Extensive scar in LA, localized re-entry in the RUPV (Figure 4, Video S1) | Pulmonary atresia, absent RPA, MAPCAs and segmental PH | Previous AT ablated anterior to the right PVs | Termination on ablation, noninducible | Recurrence at 3-mo follow-up |
| | Localized re-entry in the lateral wall of morphological RA (via transbaffle puncture) | TGA, Mustard procedure | 2× Previous AT ablation procedures (ATs at both systemic and subpulmonary atria) | Termination on ablation, noninducible | No recurrence at 10-mo follow-up |

AF indicates atrial fibrillation; ASD, atrial septal defect; AT, atrial tachycardia; AVNRT, atrioventricular nodal re-entry tachycardia; CS, coronary sinus; CTI, cavo-tricuspid isthmus; DORV, double outlet right ventricle; MAPCAs, major atriopulmonary collateral arteries; PA, pulmonary artery; PH, pulmonary hypertension; RA, right atrium; RF, radiofrequency; RPA, right pulmonary artery; RUPV, right upper pulmonary vein; RV, right ventricle; SVC, superior vena cava; TGA, transposition of the great arteries; VSD, ventricular septal defect.

Downloaded from http://ahajournals.org by on March 29, 2019

**Table 3.** Group B: Multiple ATs

| Type of AT Per Procedure (n=11) | Details of AT | Anatomical Substrate/Surgery | Previous Ablation | Acute Outcome | Medium-Term Outcome |
|---|---|---|---|---|---|
| Focal ATs (6 procedures, 5 patients) | 2 ATs, in SVC-RA junction, focal in RAA | Ebstein's anomaly, tricuspid valve replacement | Surgical Maze in RA and previous CFAE ablation in the RA for AF | Termination on ablation | No recurrence at 11-mo follow-up |
| | Procedure 1: 2 focal ATs in RA superior-anterior-lateral wall, and RA superior posterolateral<br>Procedure 2: Faster ATs, AT1 in midlateral RA close to phrenic nerve, epicardial site, AT2 not mapped (Figure 5, Video S2) | DiGeorge syndrome, surgically repaired AVSD | Previous AF ablation, previous CTI and atriotomy scar ablation | AT1 non sustained AT2 termination on ablation<br>AT1 termination on ablation, AT2 non sustained | Recurrence at 2mo follow-up<br>Recurrence at 1-mo follow-up |
| | AT 1 nonsustained, not mapped<br>AT2 Focal anteroseptum | ccTGA, large VSD | 0 | AT2 termination on RF | No recurrence at 6-mo follow-up |
| | 3 Focal ATs | ASD and VSD rudimentary RV | Previous AF ablation 2007 then AT ablation ×2 (LA AT) | RF on earliest sites in SR (nonsustained, mechanical block) | Recurrence at 3-mo follow-up |
| | AF induced degenerated to AT1 nonsustained<br>AT2 nonsustained<br>AT3 Focal from the base of LAA | AVSD, common atrium with atrial septation operation (Dacron patch) | Previous AF ablation ×3 (PVI and CFAE in LA and RA) | Termination on ablation | Recurrence at 1-mo follow-up |
| Multiple re-entry (5 procedures, 3 patients) | Procedure 1: AF, CFAE ablation in the RA, then focal AT in the SVC-RA junction<br>Procedure 2: Several macro-re-entry circuits/ extensive RA scar, 7 ATs mapped and ablated to SR (Figure 6) | Atriopulmonary Fontan | Previous AT ablation in the RA (no details available) | Termination on ablation<br>Termination or change to different AT until termination to SR on ablation | Recurrence at 6-mo follow-up<br>No recurrence at 6-mo follow-up |
| | Procedure 1: 8 ATs mapped<br>Procedure 2: 3 ATs mapped and ablated, in the posterior wall inferior to LSVC, macro-re-entry with inferior isthmus and posterior wall below the SVC | Common atrium, DORV, TGA, left SVC | Previous ablation for atriotomy and CTI dependent AT, and focal from the AV node | Termination or change to different AT until termination to SR on ablation<br>Termination to SR on ablation | Recurrence at 1-mo follow-up<br>Recurrence at 3-mo follow-up |
| | 4 macro-re-entry ATs mapped and ablated with change to a different AT, large posterior and anterior scar (Figure 7, Videos S3 and S4) | Fontan RA-RV conduit | Previous ablation on the RA free wall scar to SVC and IVC | Termination or change to different AT still inducible | No recurrence at 3-mo follow-up |

AF indicates atrial fibrillation; ASD, atrial septal defect; AT, atrial tachycardia; AVSD, atrioventricular septal defect; cc, congenitally corrected; CFAE, complex fractionated atrial electrograms; CTI, cavo-tricuspid isthmus; DORV, double outlet right ventricle; LA, left atrium; LAA, left atrial appendage; LSVC, left superior vena cava; PA, pulmonary artery; PVI, pulmonary vein isolation; RA, right atrium; RAA, right atrial appendage; RF, radiofrequency; RUPV, right upper pulmonary vein; RV, right ventricle; SR, sinus rhythm; SVC, superior vena cava; TGA, transposition of the great arteries; VSD, ventricular septal defect.

Downloaded from http://ahajournals.org by on March 29, 2019

multipolar minibasket mapping catheter that rapidly collects anatomical and electrical data within the chamber of interest, which are automatically annotated. During tachycardia, all beats are scanned for eligibility. The atrial electrograms of interest are only accepted and annotated when fulfilling the following criteria: (1) a stable cycle length (CL); (2) stable timing difference between 2 reference electrodes; (3) respiration gating; (4) stable catheter location; (5) stability of catheter signal compared with adjacent points; and (6) tracking quality. The automatic annotation is based on 2 different reference electrograms that are usually collected from a decapolar catheter within the coronary sinus or other stable location. Incorrect automatic annotation was previously reported to be as low as 0.02% and all points were easy to identify because of inconsistent color-coding on the high-density maps.[5] Therefore, manual re-annotation of points was not performed in this study.

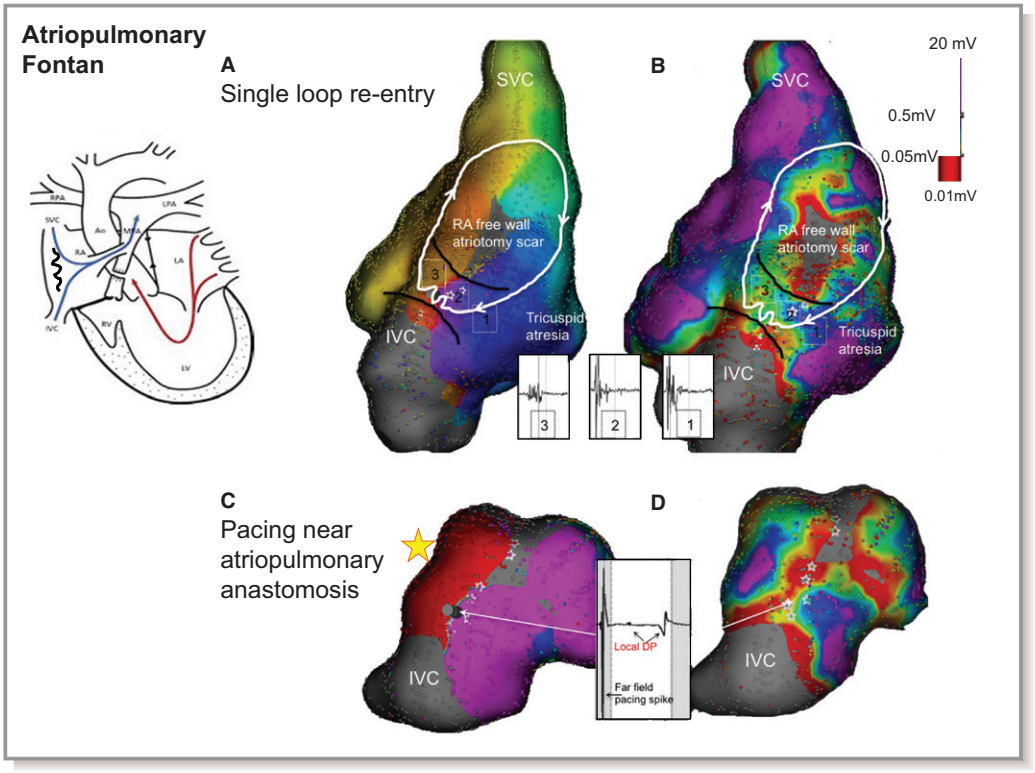


**Figure 1.** Single loop macro re-entry dependent on the atriotomy scar in the right atrial (RA) free wall in a patient with tricuspid atresia and atriopulmonary Fontan (anatomy graph in left upper corner). **A**, Time map and (**B**) the corresponding voltage map of the clinical tachycardia show clockwise activation around the atriotomy scar and an isthmus of slow conduction between the scar and the inferior vena cava (IVC) with 1,2,3 being examples of fractionated electrograms in the critical isthmus entry, mid, and exit. **C**, Time map during pacing near the atriopulmonary anastomosis and (**D**) corresponding voltage map shows the conduction block along the linear lesion postablation with the corresponding widely split double potentials (DP). Ao indicates aorta; IVC, inferior vena cava; LA, left atrium; LPA, left pulmonary artery; LV, left ventricle; MPA, main pulmonary artery; RPA, right pulmonary artery; RV, right ventricle; SVC, superior vena cava.

Downloaded from http://ahajournals.org by on March 29, 2019

## Definitions

An induced AT was considered clinical when it had the same P-wave morphology and CL compared with the documented clinical tachycardia. Each procedure was categorized according to complexity in 2 groups: Group A (single AT) consisted of all procedures where 1 AT was induced and mapped and Group B (multiple ATs) consisted of all procedures where 2 or more ATs were induced and mapped. All ATs were classified to macro re-entry, localized re-entry, or focal according to standard definitions as follows: (1) macro re-entry: Clear macro-reentry circuit with coverage of >90% of CL mapped around an anatomical obstacle or scar (ie, cavo-tricuspid isthmus [CTI]–dependent flutter, atriotomy scar–dependent flutter, etc). This included dual loop re-entry when there were 2 loops (figure-of-8) mapped from the same tachycardia (ie, CTI and atriotomy scar AT); (2) localized re-entry: when >90% of the AT CL was mapped in a small area and the rest of the chamber showed a centrifugal activation from this area; (3) focal AT: AT with centrifugal activation of the chamber from the earliest activation site. The critical isthmus of a macro re-entry tachycardia was recognized as the narrowest or the slowest part of the tachycardia wavefront where ablation affected the tachycardia by termination or change to a different tachycardia. Entrainment mapping was used as per operators choice, as an additional maneuver to confirm the critical isthmus sites, but it was not systematically applied; therefore, data regarding entrainment were not collected in the offline analysis.

## Offline Analysis

All maps of the clinical tachycardias were reviewed offline and the following predefined measurements were taken: (1) total volume of the chamber of interest mapped calculated automatically by the system; (2) dense scar area, defined as voltage <0.05 mV, was quantified with the surface measurement tool

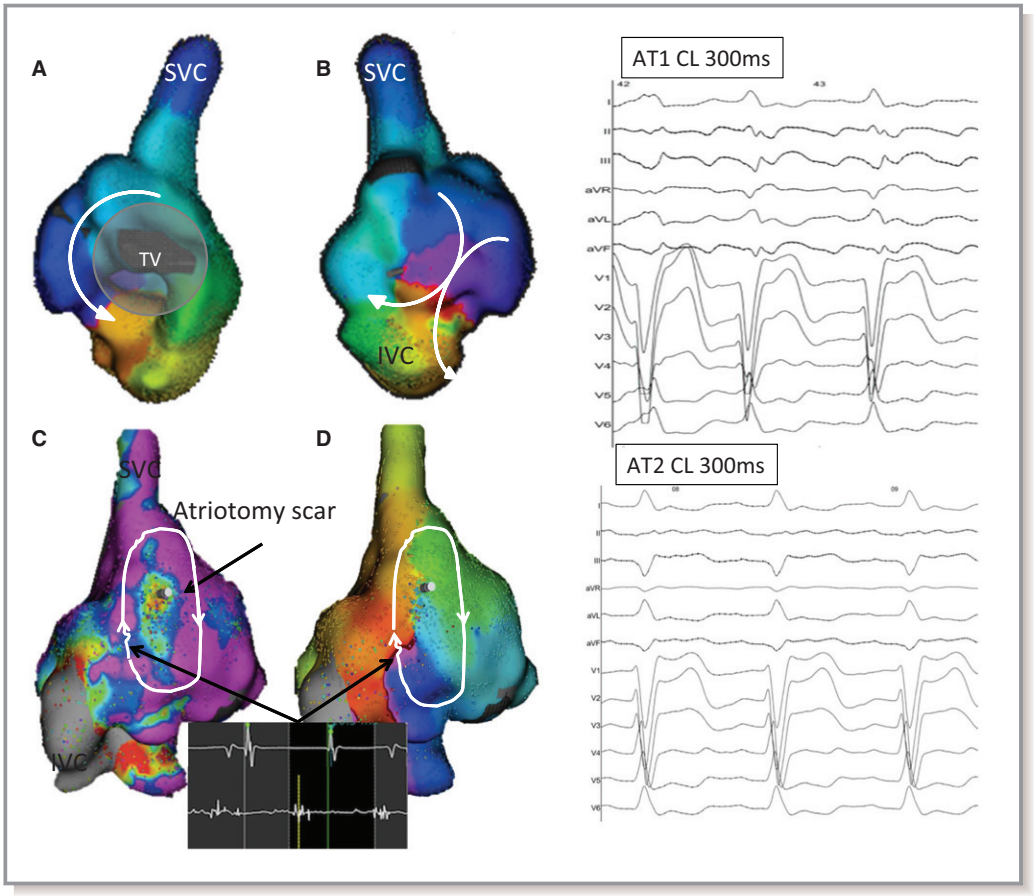


**Figure 2.** Dual-loop macro re-entry in a patient with atriotomy for Ross procedure, consisting of a counterclockwise circuit around the tricuspid valve (TV) (cavotricuspid isthmus-CTI dependent) (**A**) and a clockwise circuit around the atriotomy scar in the right atrium free wall (**B**). First a CTI line was deployed and the atrial tachycardia (AT1) P-wave morphology changed to AT2; however, the cycle length (CL) remained the same. **C** and **D**, The voltage map and activation after the cavo-tricuspid isthmus (CTI) was ablated, with arrows showing the area of slow conduction (critical isthmus) and the corresponding fractionated electrogram. A linear lesion between the atriotomy and the inferior vena cava was deployed followed by tachycardia termination and noninducibility.

Downloaded from http://ahajournals.org by on March 29, 2019

by adding all distinct areas of voltage <0.05 mV; (3) low voltage area, defined as voltage 0.05 to 0.5 mV, was calculated by adding all distinct areas of voltage <0.5 mV and then subtracting the dense scar area; (4) indexed dense scar area ($cm^2$/mL) and (5) indexed low voltage area ($cm^2$/mL) were calculated by dividing the dense scar or low voltage area accordingly by the volume mapped; (6) length of the critical isthmus was measured from the point where the wavefront enters the isthmus until the point where the wavefront exits the isthmus; (7) the slowest conduction velocity within the critical isthmus was measured at the site of the slowest conduction using the following technique as previously described: The time color map was manually adjusted to show activation in steps of 10 ms, then the shortest distance covered in 10 ms within the critical isthmus was found and measured. This distance in mm was divided by the time, namely, 10 ms, to calculate the velocity in m/s.[9]

## Acute Outcomes

Successful ablation of each AT was defined as the termination or change to a different AT during ablation and/or noninducibility of the targeted tachycardia postablation. A tachycardia change to a different AT was defined as >10% change in CL following ablation and a change of either the intracardiac electrograms activation pattern or P-wave morphology. A procedure was considered to be acutely successful when achieving sinus rhythm with noninducibility of any tachycardia.

## Midterm Clinical Outcomes

Midterm follow-up data were collected via routine follow-up clinic letters and cardiac implantable electronic devices for a period of at least 3 months up to 12 months postablation.

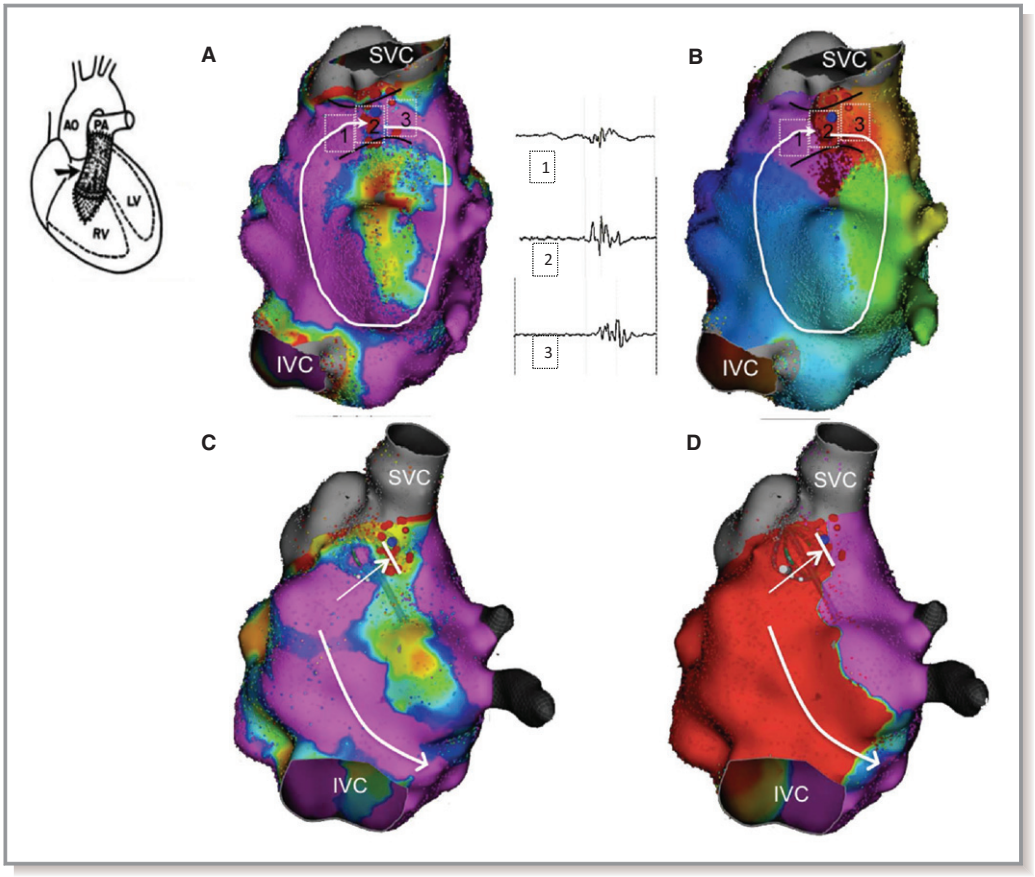


**Figure 3.** Patient with double outlet right ventricle and transposition of the great arteries and previous Rastelli and right ventricle to pulmonary artery conduit (anatomy graph in left top corner). Single loop macro re-entry around the large septal atrial scar (surgical closure of atrial septal defect). **A**, Voltage map and (**B**) time map of the clinical tachycardia with 1,2,3 indicating the entrance, mid, and exit of the critical isthmus with the corresponding fractionated electrograms showing slow conduction. Linear lesion between the scar and the superior vena cava (SVC) terminated the tachycardia. **C**, Postablation voltage and (**D**) activation map during pacing from the right atrial appendage shows conduction block along a long line consisting of the linear lesion and the septal scar. AO indicates aorta; IVC, inferior vena cava; LV, left ventricle; PA, pulmonary artery; RV, right ventricle.

Downloaded from http://ahajournals.org by on March 29, 2019

A procedure success was defined as the absence of documented sustained AT (>30 s).

## Statistical Analysis

Statistical analyses were performed with SPSS version 21. All continuous variables were reported as median (25th–75th percentile). Categorical variables are reported as percentages and absolute numbers. Comparisons between 2 groups were done with the Wilcoxon rank-sum test. Categorical variables were compared with Fisher exact test (2-sided). Kaplan–Meier survival analysis was applied to show differences in freedom from arrhythmia recurrence between groups. Receiver operating characteristic curve analysis was applied to determine the best cutoff value of indexed low voltage area to predict recurrence. Results were considered statistically significant if $P<0.05$.

## Results

### Patients

Twenty patients (10 female, median age 44 years, interquartile range 40–54) had a total of 23 ablation procedures (3 patients had 2 procedures). Types of congenital heart disease according to the Bethesda classification are listed in Table 1. Ten patients had complex congenital heart disease, 5 had moderate, and 5 had simple congenital defects. All but 2 patients were already treated with antiarrhythmic medication and 15/20 patients had previous electrophysiological studies

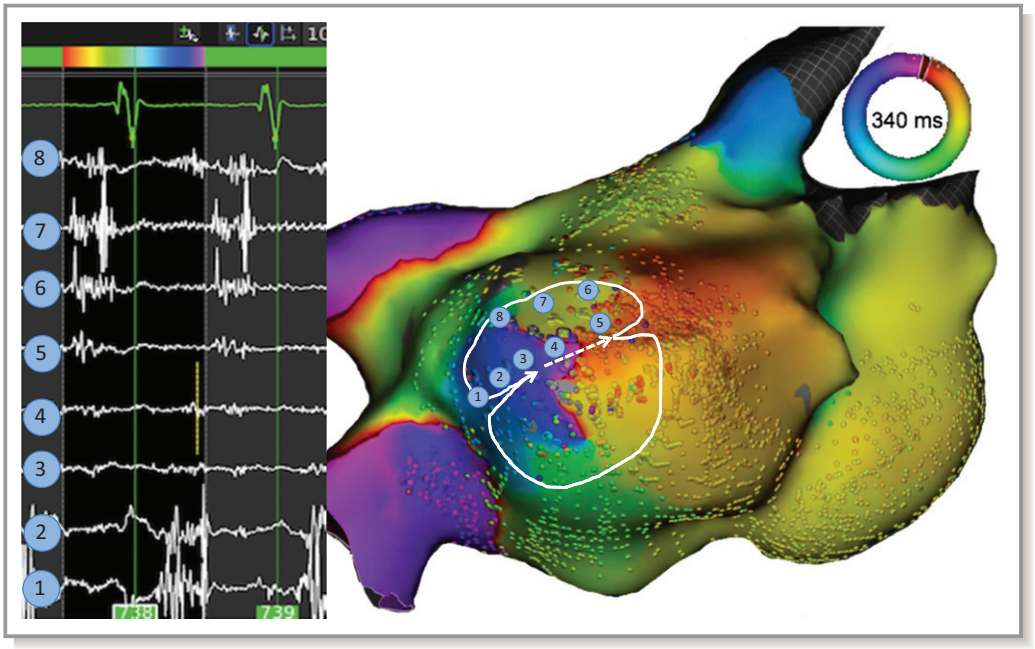


**Figure 4.** Patient with enlarged left atrium secondary to pulmonary atresia, absent left pulmonary artery, MAPCAs, and segmental pulmonary hypertension. He had previous ablation for left atrial tachycardia. Activation map during tachycardia shows a localized re-entry in front of the right pulmonary veins with a critical isthmus of slow conduction and figure-of-8 re-entry around a small area (Video S1). On the left panel, the corresponding electrograms in the entry, mid, exit, and outer loop covering 100% of the tachycardia cycle length (see activation video as supplemental material). LUPV indicates left upper pulmonary vein; MAPCAs, major aortopulmonary collateral arteries; RLPV, right lower pulmonary vein; RUPV, right upper pulmonary vein.

Downloaded from http://ahajournals.org by on March 29, 2019

and ablation or surgical ablation (7 patients had more than 1 previous ablation procedure) for atrial arrhythmias. All but 2 patients had previous cardiac surgery.

## Procedures

In total, 23 AT ablation procedures were performed. Median procedure duration was 184 (155–298) minutes and median fluoroscopy time was 13 minutes and 26 s (10:10–26:40). There was 1 procedure-related complication, specifically, retroperitoneal bleeding attributed to failed attempts to cannulate the right femoral vein, which was completely occluded with collaterals. The access was then achieved from the left femoral vein. This complication was managed conservatively with blood transfusion and no surgery was required.

## Anatomical Challenges

In 2 cases the coronary sinus was not accessible and the decapolar reference catheter was placed in the right atrium around the tricuspid annulus or close to the atriopulmonary connection in a patient with Fontan anatomy. In all cases the multipolar basket catheter was successfully delivered via either a deflectable or a nondeflectable long sheath and then fully deployed in the chamber of interest. The catheter maneuvered freely and adequately collected mapping information from all areas of the chamber. In 1 case, the access to the chamber of interest required a transbaffle puncture (Dextro-Transposition of the Great Arteries and previous Mustard operation) and the multipolar basket catheter was advanced to the subpulmonary venous atrium in a deflectable sheath in its undeployed state.

## AT Number and Mechanisms Per Procedure

A total of 50 ATs were mapped in 23 procedures. Details on the congenital cardiac defects, past surgeries, and ablation procedures and the latest procedure outcomes are summarized in Tables 2 and 3.

### *Group A: single AT*

A total of 12 tachycardias in 12 patients consisted of the following subgroups:

1. Single or dual loop macro re-entry (n=10, CL 315 [268–325] ms, electrograms 13 563 [11 255–21 689]) involving atriotomy scar (5/10) (example in Figure 1), or CTI dependent (2/10) or dependent on gaps on previous ablation lines (3/10). Dual loop tachycardias had 2 distinct

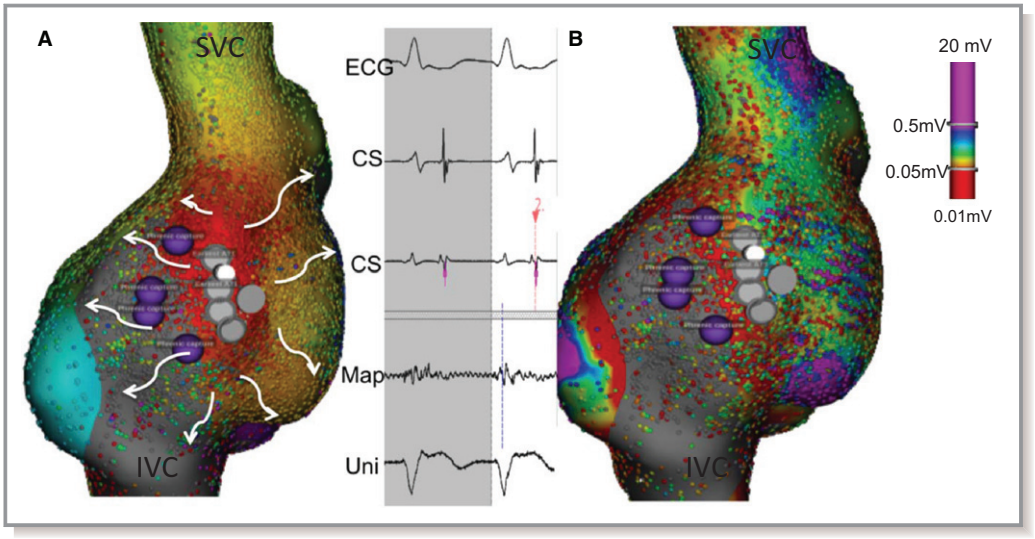


**Figure 5.** Patient with surgically repaired atrioventricular septal defect. Left lateral views of the right atrium showing atriotomy scar (gray area) and a focal tachycardia arising on the anterior border of the atriotomy scar. Focal atrial tachycardia with (**A**) local activation map with electrogram at point of earliest activation and (**B**) voltage map with electrogram with phrenic nerve capture (purple dot). The atrial tachycardia here posed a challenge because of its proximity to the phrenic nerve demonstrated by pacing. The area of focal activation is in the region of scar and its large area may be indicative of an epicardial origin (Video S2). CS indicates coronary sinus electrograms; ECG, surface electrocardiogram; IVC, inferior vena cava; Map, mapping catheter bipolar electrograms; SVC, superior vena cava; Uni, mapping catheter unipolar electrogram.

Downloaded from http://ahajournals.org by on March 29, 2019

isthmi of slow conduction, the CTI and an isthmus of slow conduction between the atriotomy scar in RA free wall and the inferior vena cava, or the tricuspid annulus (Figure 2). In 8/10 cases the isthmus conduction block was confirmed with focused remapping of the isthmus area postablation (Figure 3).

2. Localized re-entry (n=2, CL 280 and 446 ms, electrograms 5793 and 15 668 accordingly) within a low voltage area in the pulmonary venous atrium in a patient with Mustard procedure, and within a low voltage area in front of the right pulmonary veins in a patient with pulmonary atresia. Both patients had previous ablations in the same chamber (Figure 4, Video S1).

Acute success was achieved in 100% of procedures in Group A. Midterm success was 92% (1 recurrence).

### *Group B: multiple ATs*

A total of 11 procedures in 8 patients consisted of the following 2 subgroups:

1. Multiple focal ATs (n=6); A total of 14 focal ATs (CL 329 [287–390] ms, electrograms 4806 [949–9151]) were mapped in 6 procedures (5 patients). In 5/6 cases the patients had previous ablation in the same chamber, involving either complex fractionated atrial electrograms ablation for atrial fibrillation or linear lesion ablation for macro re-entrant tachycardia. In 2/6 cases the patient had atrial fibrillation in the same case. Half of the focal ATs were terminated to sinus rhythm during ablation. The rest of the focal ATs were either nonsustained (n=5), mechanically terminated (n=1), or cardioverted with direct current (n=1) and the ablations were delivered in sinus rhythm to monitor atrioventricular conduction. One patient from this group had a second ablation within the study period that was again not successful in the midterm. This was attributed to the possible epicardial focus of the AT and the earliest site of activation being in proximity to the phrenic nerve, thus limiting the radiofrequency energy delivered (Figure 5, Video S2).
2. Multiple re-entry ATs (n=5); In 5 procedures (3 patients) more than 1 distinct macro re-entry ATs were mapped during each procedure (Figures 6 and 7). A total of 24 ATs (median 4, interquartile range 2.5–8.5) were mapped (mean CL 338 [274–566] ms, electrograms 18 183 [12 522–29 335]). Two patients had a second procedure within the study period.

Acute success was achieved in 77% of procedures in Group B. Midterm clinical success of catheter ablation was 36% and cumulative success after multiple procedures was 38% in this group.

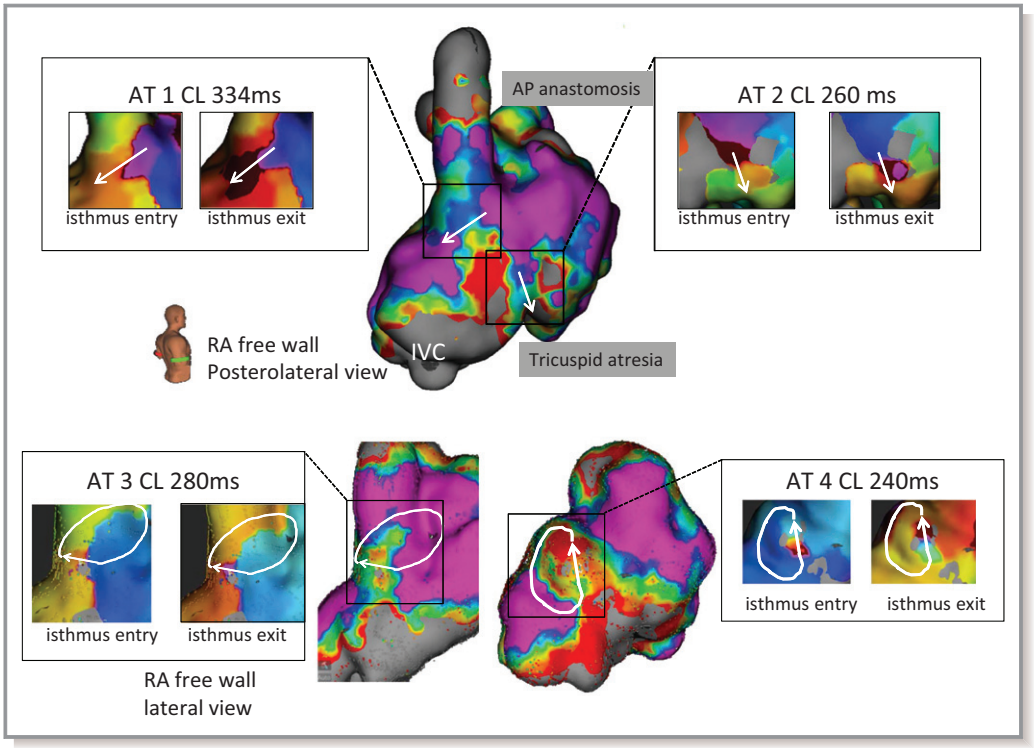


**Figure 6.** Multiple re-entry circuits in a patient with tricuspid atresia and atriopulmonary Fontan operation. Top row: the voltage map in the middle shows 2 channels that serve as critical isthmis (white arrows) for AT1 (local activation map on the left) and AT2 (local activation map on the right). AT1 was initially ablated in the critical isthmus indicated by the map on the left; subsequently it changed to AT2, a tachycardia with shorter CL with the critical isthmus shown on the right top row. After ablation on this site, AT3 was induced (left-bottom row) with a critical isthmus formed in a small area within the area that was ablated for AT1. Further ablation there resulted in AT4, a tachycardia with opposite direction of the wavefront (counterclockwise) and a critical isthmus formed within a channel lower to the previous ablation site. AP indicates atriopulmonary; AT, atrial tachycardia; CL, cycle length; IVC, inferior vena cava; RA, right atrium.

## AT Substrate Characteristics

Differences between group A and B in patients' demographics and substrate characteristics are presented in Table 4. Patients in group B had more previous ablations (0.5 [0–1] versus 2 [1–3], $P$=0.019) and the procedure duration was longer (159 [147–180] versus 412 [352–420] minutes, $P$<0.001). Low voltage area and Indexed low voltage area were larger in group B (22.6 [12.2–29.8] versus 54.2 [51.1–61.6] $cm^2$ $P$=0.014, 0.17 [0.12–0.21] versus 0.26 [0.23–0.27] $cm^2$/mL, $P$=0.024 accordingly). Dense scar, indexed dense scar, and volume of the chamber of interest were similar between groups. Other substrate characteristics such as critical isthmus length and isthmus conduction velocity were also similar between the 2 groups.

Receiver-operating characteristic curve analysis revealed that the Indexed low voltage area was able to predict recurrence (area under the curve 0.923, $P$=0.007) and the best cutoff values were ≥0.24 with 100% sensitivity and 77% specificity and ≥0.39 with 60% sensitivity and 100% specificity (Figure 8).

## Clinical Outcomes

Acute success was 100% in group A versus 77% in group B ($P$=0.009). Midterm clinical success was 92% in group A versus 36% in group B ($P$=0.009). Kaplan–Meier survival analysis showed longer freedom from arrhythmia recurrence for procedures in group A compared with group B (11.3, CI 9.8–12.7 versus 4.9, CI 2.2–7.6 months, log rank $P$=0.004) (Figure 9).

## Discussion

The prevalence of atrial arrhythmia increases considerably when patients survive longer as a consequence of improved surgical and clinical care of congenital heart disease.[10] Catheter ablation offers an opportunity to obliterate the

Downloaded from http://ahajournals.org by on March 29, 2019

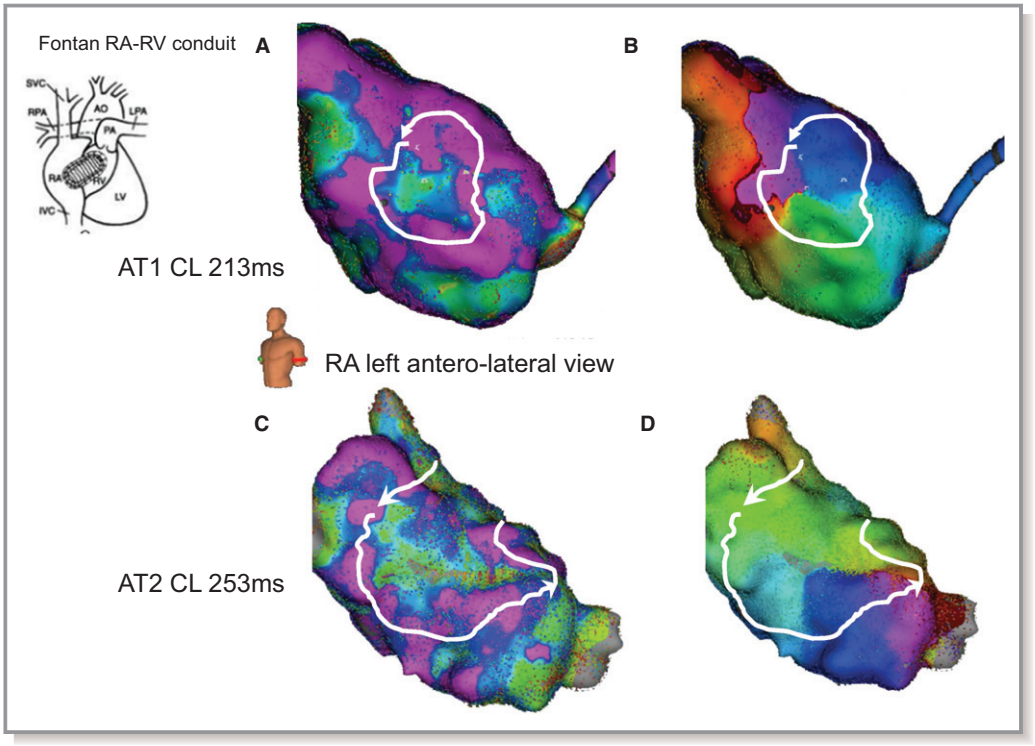


**Figure 7.** In this patient with Fontan with Right atrial to Right ventricle (RA-RV) conduit, a macro re-entrant AT1 was initially mapped (CL 231 ms) which, as depicted on the voltage (**A**) and time maps (**B**) in top row, was moving counterclockwise around a septal scar inside the enlarged RA (Video S3). After ablation and successful termination of AT1, a slower AT was induced. Voltage (**C**) and activation maps (**D**) revealed a clockwise re-entry circuit around a larger scar that included the site of successful ablation of AT1 (Video S4). AO indicates aorta; AT, atrial tachycardia; CL, cycle length; IVC, inferior vena cava; LPA, left pulmonary artery; LV, left ventricle; PA, pulmonary artery; RA, right atrium; RPA, right pulmonary artery; SVC, superior vena cava.

Downloaded from http://ahajournals.org by on March 29, 2019

arrhythmia circuits and/or foci, although this can be challenging in some cases. This study is the first to assess the underlying substrate of the atrial tissue using ultra-high-density mapping with the following novel findings: (1) Patients who had a single AT induced and mapped with ultra-high-density mapping (Group A) had smaller low voltage area and indexed low voltage area but similar dense scar area and volume of the chamber of interest compared with patients who had multiple ATs induced and mapped (Group B). (2) The ATs in group A were easier to map and ablate with shorter procedure duration and better acute procedural and midterm clinical outcomes. (3) Indexed low voltage area, but not indexed dense scar or volume of the chamber of interest relates to the clinical success of catheter ablation of AT.

Catheter ablation is recommended for the treatment of AT in adult congenital heart disease.[2] The acute success rate was previously reported at 75% to 81% and the longer-term success seems to vary considerably in recent studies from 45% to 92%, with most of the recurrences happening within the first year.[11–13] Our study showed an overall acute procedural success rate of 87% and midterm clinical success rate of 65%. The acute procedural and midterm clinical success rates were higher (100% and 92%, respectively) in the cases with less extensive low voltage area, which presented with single AT (Group A). However, the acute procedural and midterm clinical success rates were much lower (77% and 35%) in the cases with larger low voltage area, which presented multiple focal or multiple macro re-entry ATs (Group B). Among other factors leading to the worse outcomes in Group B are the temporal instability of ATs and the presence of multiple channels of slow conduction. Although our study included only a modest number of patients and our follow-up is relatively short, we showed for the first time that the extent of low voltage area but not dense scar is higher in the patients who present with multiple ATs and that Indexed low voltage area (but not indexed dense scar) is higher in patients who have recurrence within the first year of catheter ablation (Figure 10). The percentage of patients with complex congenital defects was similar between Groups A and B (42% versus 55%, respectively $P$=0.68), implying that the underlying complexity of the structural congenital defect was not necessarily related to the

**Table 4.** Demographics and Substrate Characteristics Per Group of Complexity

| | Group A: Simple (n=12) | Group B: Complex (n=11) | *P* Value |
|---|---|---|---|
| Age, y | 51±13 | 43±9 | 0.113 |
| Number of ATs mapped, n (IQR) | 1 (1–1) | 2 (2–5) | <0.001* |
| Complex congenital defect, n (%) | 5 (42) | 6 (55) | 0.684 |
| Previous ablations, n | 0.5 (0–1) | 2 (1–3) | 0.019* |
| Previous cardiac surgeries, n | 1.5 (1–2.7) | 1 (1–2) | 0.379 |
| Procedure duration, min | 159 (147–180) | 412 (352–420) | <0.001* |
| AT CL, ms | 315 (255–322) | 338 (275–452) | 0.151 |
| Percentage of CL mapped per AT, % | 100 (97–100) | 100 (80–100) | 0.128 |
| EGMs per AT acquired, n | 14 054 (10 136–19 803) | 9278 (5200–19 315) | 0.498 |
| Volume mapped, mL | 112 (107–131) | 240 (222–246) | 0.546 |
| Critical isthmus length, mm | 7.6 (6.4–14) | 13.2 (9.4–21.2) | 0.385 |
| Critical isthmus CV, m/s | 0.40 (0.30–0.90) | 0.47 (0.28–0.70) | 0.999 |
| Low voltage area, $cm^2$ | 22.6 (12.2–29.8) | 54.2 (51.1–61.6) | 0.014* |
| Indexed low voltage area, $cm^2$/mL | 0.17 (0.12–0.21) | 0.26 (0.23–0.27) | 0.024* |
| Dense scar, $cm^2$ | 15.7 (1.27–27.8) | 26.3 (21.5–27.1) | 0.549 |
| Indexed dense scar area, $cm^2$/mL | 0.07 (0.01–0.14) | 0.11 (0.09–0.13) | 0.664 |

AT indicates atrial tachycardia; CL, cycle length; CV, conduction velocity; EGMs, electrograms; IQR, interquartile range.
*$p < 0.05$.

complexity of the "electrical" substrate; for example, some patients with complex structural defects such as atriopulmonary Fontan or Transposition of the Great Arteries (see examples in Figures 1 and 3) only had limited low voltage area, in whom single occurring AT was ablated successfully. Group B patients may have had more extensive low voltage areas because of chronic pressure or volume overload and chamber distension or because of previous ablation lesions that were either not transmural or not durable.

## Value of Ultra-High-Density Mapping in Identifying the Arrhythmia Mechanism

In our cohort the ultra-high-density mapping system was able to localize and characterize the critical isthmus of a single macro re-entry and dual loop re-entry or localized re-entry AT and to guide successful ablation. This can be attributed to 3 main characteristics of the mapping system: (1) the accurate automatic acquisition and annotation of electrograms (no need for manual re-annotation of points) that achieves high density of points in relative short mapping times; (2) the ability to record low voltage electrograms with very low noise levels (0.011±0.004 mV in human atria[9] and <0.01 mV in canine atria[4]) that achieves very high resolution; and (3) the ability to allow a quick remap of the critical area postablation to confirm conduction block along the ablation line. Activation mapping in this cohort successfully identified localized re-entry as a mechanism of AT in 2 cases. A previous study has shown that ultra-high-density mapping with the 64-pole basket catheter gives a detailed substrate and activation definition and it was able to differentiate carousels that are true localized re-entry circuits from pseudo re-entry.[14] A study using point-by-point, nonautomated 3-dimensional electroanatomical mapping reported high success rates of catheter ablation in congenital heart disease attributed by the authors to the correct setting of the window of interest.[15] Although the identification of the critical isthmus of macro reentrant ATs can be achieved using other mapping systems as well, ultra-high-density mapping offers much more detailed substrate information, which may provide insight not only on the mechanisms of tachycardia but also the underlying tissue voltage characteristics that may relate to the propensity of arrhythmia recurrence.

## Tachycardia Mechanism and Ablation Outcomes

In cases of a single macro re-entry or localized re-entry circuit, the ablation was acutely successful and showed improved midterm freedom from arrhythmia recurrence. In multiple focal or multiple re-entry ATs, the acute procedural and midterm clinical outcomes of ablation were not as good and this may be attributed to inherent difficulties in mapping such as instability of the tachycardia, higher likelihood of mechanical termination of focal ATs, and safety issues that may discourage the

Downloaded from http://ahajournals.org by on March 29, 2019

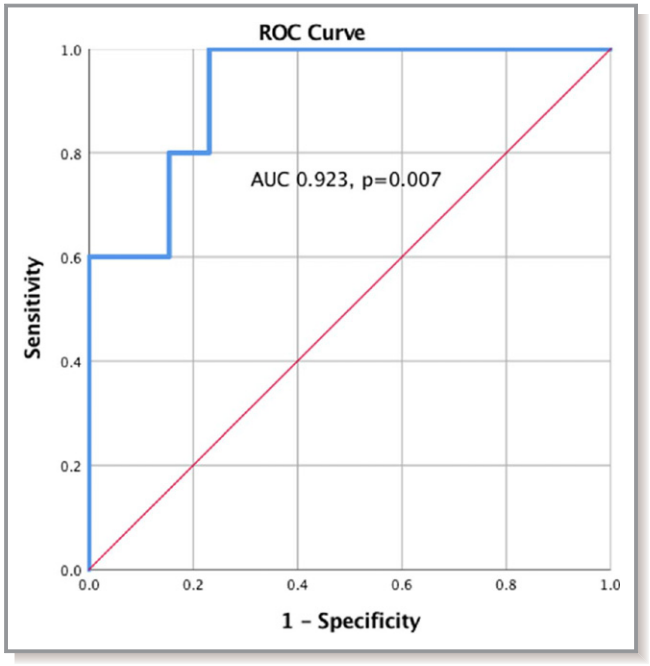


**Figure 8.** Receiver operating characteristic (ROC) curve of indexed low voltage area shows very good accuracy in predicting midterm recurrence following catheter ablation for atrial tachycardia in adult congenital heart disease. AUC indicates area under the curve.

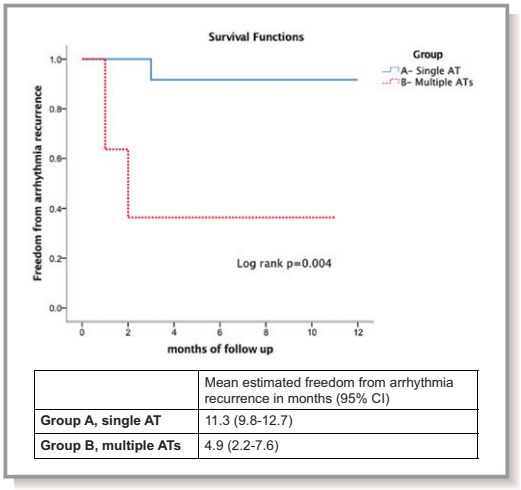


| | Mean estimated freedom from arrhythmia recurrence in months (95% CI) |
|---|---|
| **Group A, single AT** | 11.3 (9.8-12.7) |
| **Group B, multiple ATs** | 4.9 (2.2-7.6) |

**Figure 9.** Kaplan–Meier curve showing freedom from arrhythmia recurrence for group A-single AT (blue line) and group B-multiple ATs (red dotted line). AT indicates atrial tachycardia.

ablation on the site of earliest activation (such as proximity to the phrenic nerve and the intrinsic conduction system). Multiple re-entry ATs are related to large areas of low voltage with various channels of slow conduction that might lend themselves as isthmi for the next re-entry circuit after the first AT is successfully ablated (example in Figures 6 and 7).

## Clinical Implications

In our cohort almost half of the procedures involved multiple focal or re-entry circuits (group B). The procedures in group B were longer in duration and had worse acute procedural and midterm outcomes compared with group A. Total low voltage area was 2.2 times larger in group B but dense scar area and total volume mapped were not significantly different between groups, suggesting that atria with higher burden of low voltage areas are more likely to maintain AT even when the clinical tachycardia is successfully ablated by lending a different atrial channel of low voltage to serve as the critical isthmus of the circuit. In cases with multiple focal ATs, the increased burden of low voltage is probably related to increased atrial tissue heterogeneity and nonuniform conduction contributing to triggered activity[16] or micro re-entry at a cellular level, not discernible even with ultra-high-density mapping. In our cohort, increased chamber volume does not seem to be related to poor outcome unless the low voltage burden is high. Indexed low voltage area equal to or larger than 0.24 $cm^2$/mL can predict recurrence within the first year with 100% sensitivity and 77% specificity. On the contrary, ultra-high-density mapping in cases with a single AT identified correctly the sites for successful ablation and was used to prove bidirectional block of linear lesions leading to improved acute and midterm outcomes. We believe that all ablation lesions should be as complete as possible to ensure transmurality and durability; for instance, the linear lesions must be assessed for bidirectional block. Suboptimal ablation may inadvertently extend the low voltage areas with electrically conducting channels in-between and subsequently increase the tissue ability to perpetuate further atrial arrhythmias.

## Limitations

This study was not prospective and the offline measurements were done in retrospect; however, the researcher collecting the information was blinded to the midterm clinical outcome. Unstable CL may impose a challenge to any automated annotation platform. In the mapping system used in the current study, the “CL” parameter of the beat acceptance criteria can be adjusted either to restrict the system to map the precise AT 1 at a time (with a tight CL window) or alternatively, if the variation of CL is small, typically in focal AT, it can be adjusted to map with a wider CL window. The number of patients and procedures is modest; therefore, multivariate analysis and identification of predictors of outcome were not feasible. There was no comparison to other mapping systems. The group of patients studied is

Downloaded from http://ahajournals.org by on March 29, 2019

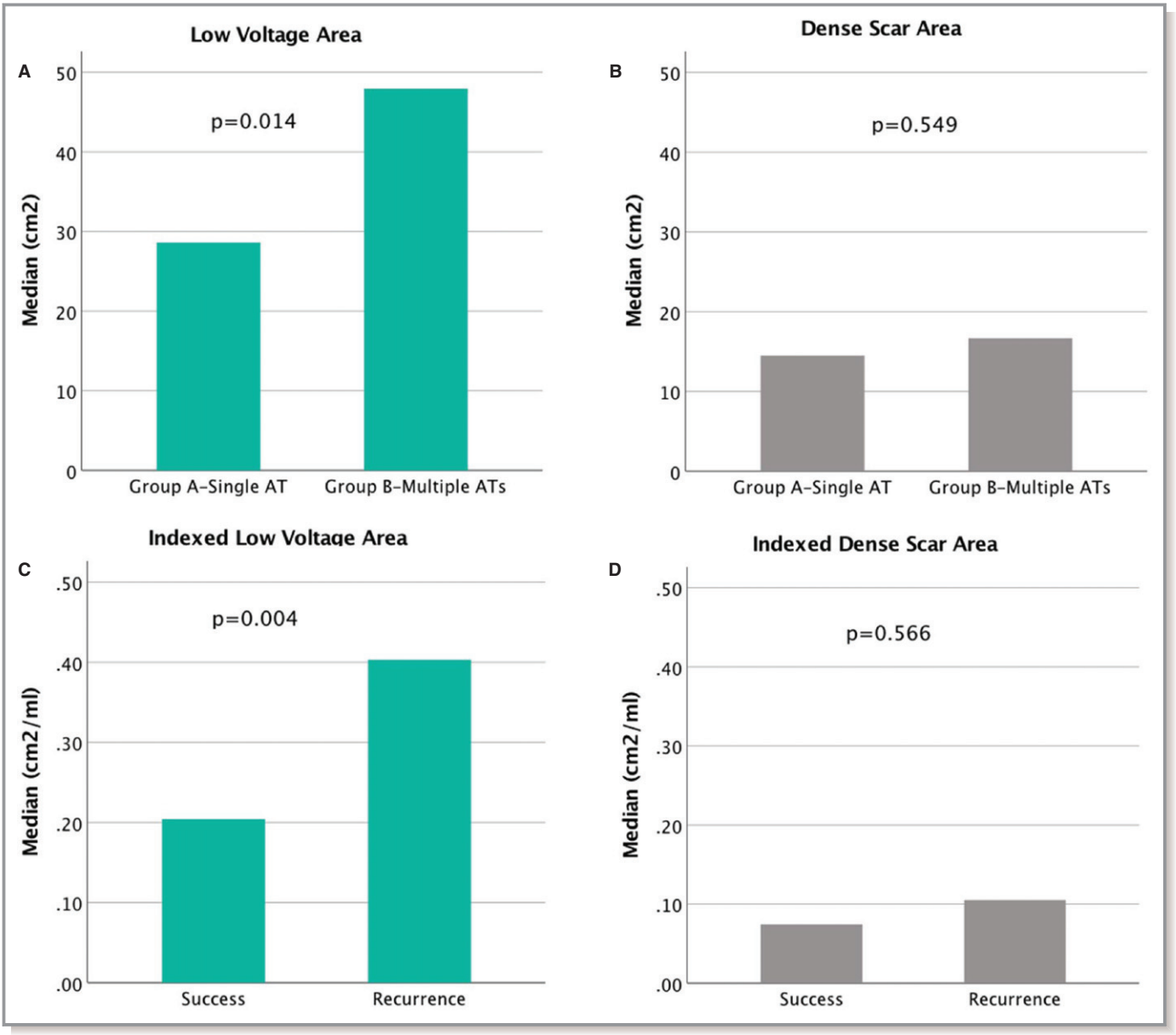


**Figure 10.** In top row, bars represent medians of low voltage area (**A**) and dense scar (**B**) in groups A and B. There was a larger low voltage area (*P*=0.014) but not larger dense scar area in the procedures where 2 or more ATs were induced (**B**) as compared with Group A. In bottom row, bars represent medians of Indexed low voltage area (**C**) and indexed dense scar area (**D**) in the procedures that were successful in the midterm vs those that were not. There was a higher indexed low voltage area (*P*=0.004) but not indexed dense scar in the procedures that were followed by recurrence in the midterm. AT indicates atrial tachycardia.

Downloaded from http://ahajournals.org by on March 29, 2019

heterogeneous because it comprises various congenital heart defects and the number of cases in each group is relatively small; therefore, analysis of the mechanisms of AT by congenital defect was not possible. Many of the patients included in this study had previous catheter or surgical ablation in our or in different centers but substrate and tachycardia maps were not available to include in the current study. Therefore, we cannot comment on the possible contribution of previous ablation procedures to the results of our study. Whether our findings are applicable to patients without congenital heart disease or patients with simple lesions (such as atrial septal defect) without previous surgical intervention needs to be carefully studied in the future.

## Conclusions

There are significant differences in the underlying atrial substrate, revealed by ultra-high-density mapping, between patients who have congenital heart disease and who present a single versus multiple ATs during catheter ablation

procedures. Low voltage area and indexed low voltage area, but not dense scar or chamber volume, are larger in the patients with multiple ATs that are subsequently related to worse acute procedural and midterm clinical outcomes. The complexity of the electrical substrate rather than the structural congenital defects appears to associate with the atrial arrhythmia burden and procedural and clinical outcomes.

## Disclosures

None.

## References


1. Khairy P, Balaji S. Cardiac arrhythmias in congenital heart diseases. *Indian Pacing Electrophysiol J*. 2009;9:299–317.
2. Khairy P, Van Hare GF, Balaji S, Berul CI, Cecchin F, Cohen MI, Daniels CJ, Deal BJ, Dearani JA, de Groot N, Dubin AM, Harris L, Janousek J, Kanter RJ, Karpawich PP, Perry JC, Seslar SP, Shah MJ, Silka MJ, Triedman JK, Walsh EP, Warnes CA. PACES/HRS expert consensus statement on the recognition and management of arrhythmias in adult congenital heart disease. *Heart Rhythm*. 2014;11:e102–e165.
3. Mantziari L, Suman-horduna I, Babu-narayan SV, Ernst S. Advanced ablation strategies for management of post-surgical atrial arrhythmias. *Glob Cardiol Sci Pract*. 2013;2013:140–148.
4. Nakagawa H, Ikeda A, Sharma T, Lazzara R, Jackman WM. Rapid high resolution electroanatomical mapping evaluation of a new system in a canine atrial linear lesion model. *Circ Arrhythm Electrophysiol*. 2012;5:417–424.
5. Mantziari L, Butcher C, Kontogeorgis A, Panikker S, Roy K, Markides V, Wong T. Utility of a novel rapid high-resolution mapping system in the catheter ablation of arrhythmias an initial human experience of mapping the atria and the left ventricle. *JACC Clin Electrophysiol*. 2015;1:411–420.
6. Anter E, Tschabrunn CM, Buxton AE, Josephson ME. High-resolution mapping of postinfarction reentrant ventricular tachycardia: electrophysiological characterization of the circuit. *Circulation*. 2016;134:314–327.
7. Warnes CA, Williams RG, Bashore TM, Child JS, Connolly HM, Dearani JA, del Nido P, Fasules JW, Graham TP Jr, Hijazi ZM, Hunt SA, King ME, Landzberg MJ, Miner PD, Radford MJ, Walsh EP, Webb GD. ACC/AHA 2008 guidelines for the management of adults with congenital heart disease: a report of the American College of Cardiology/American Heart Association Task Force on Practice Guidelines (Writing Committee to Develop Guidelines for the Management of Adults With Congenital Heart Disease). *Circulation*. 2008; 118:e714–e833.
8. Viswanathan K, Mantziari L, Butcher C, Hodkinson E, Lim E, Khan H, Panikker S, Haldar S, Jarman JWE, Jones DG, Hussain W, Foran JP, Markides V, Wong T. Evaluation of a novel high-resolution mapping system for catheter ablation of ventricular arrhythmias. *Heart Rhythm*. 2017;14:176–183.
9. Laţcu DG, Bun SS, Viera F, Delassi T, El Jamili M, Al Amoura A, Saoudi N. Selection of critical isthmus in scar-related atrial tachycardia using a new automated ultrahigh resolution mapping system. *Circ Arrhythm Electrophysiol*. 2017;10:e004510.
10. Bouchardy J, Therrien J, Pilote L, Ionescu-Ittu R, Martucci G, Bottega N, Marelli A. Atrial arrhythmias in adults with congenital heart disease. *Circulation*. 2009;120:1679–1686.
11. Anguera I, Dallaglio P, Macías R, Jiménez-Candil J, Peinado R, García-Seara J, Arcocha MF, Herreros B, Quesada A, Hernández-Madrid A, Alvarez M, Filgueiras D, Matía R, Cequier A, Sabaté X. Long-term outcome after ablation of right atrial tachyarrhythmias after the surgical repair of congenital and acquired heart disease. *Am J Cardiol*. 2015;115:1705–1713.
12. Klehs S, Schneider HE, Backhoff D, Paul T, Krause U. Radiofrequency catheter ablation of atrial tachycardias in congenital heart disease: results with special reference to complexity of underlying anatomy. *Circ Arrhythm Electrophysiol*. 2017;10:1–12.
13. Ueda A, Suman-Horduna I, Mantziari L, Gujic M, Marchese P, Ho SY, Babu-Narayan SV, Ernst S. Contemporary outcomes of supraventricular tachycardia ablation in congenital heart disease: a single-center experience in 116 patients. *Circ Arrhythm Electrophysiol*. 2013;6:606–613.
14. Luther V, Sikkel M, Bennett N, Guerrero F, Leong K, Qureshi N, Ng FS, Hayat SA, Sohaib A, Malcolme-Lawes L, Lim E, Wright I, Koa-Wing M, Lefroy DC, Linton N, Whinnett Z, Kanagaratnam P, Davies W, Peters NS, Lim PB. Visualizing localized reentry with ultra-high density mapping in iatrogenic atrial tachycardia beware pseudo-reentry. *Circ Arrhythm Electrophysiol*. 2017;10: e004724.
15. Drago F, Russo MS, Marazzi R, Salerno-Uriarte JA, Silvetti MS, De Ponti M. Atrial tachycardias in patients with congenital heart disease: a minimally invasive simplified approach in the use of three-dimensional electroanatomic mapping. *Europace*. 2011;13:689–695.
16. Miura M, Nishio T, Hattori T, Murai N, Stuyvers BD, Shindoh C, Boyden PA. Effect of non-uniform muscle contraction on sustainability and frequency of triggered arrhythmias in rat cardiac muscle. *Circulation*. 2010;121:2711–2717.


Downloaded from http://ahajournals.org by on March 29, 2019

# SUPPLEMENTAL MATERIAL

Downloaded from http://ahajournals.org by on March 29, 2019

## Supplemental Video Legends

**Video S1. Activation map during tachycardia shows a localised re-entry in front of the right pulmonary veins with a critical isthmus of slow conduction and figure of 8 re-entryaround a small area.** Best viewed with Windows Media Player.

**Video S2. Mapping system review screen showing the activation map of a focal atrial tachycardia in the right atrium (right lateral view on the left and posterior view on the right).** The far right panel shows local electrograms at the point of earliest activation (grey dots). The atrial tachycardia here posed a challenge due to its proximity to the phrenic nerve demonstrated by pacing (purple dots). The area of focal activation is in the region of scar and its large area may be indicative of an epicardial origin. Best viewed with Windows Media Player.

**Video S3. In this patient with Fontan with Right atrial to Right ventricle (RA-RV) conduit a macro re-entrant AT1 was initially mapped (CL 231ms) which was moving counter-clockwise around a septal scar inside the enlarged RA (Activation map on the left and voltage map on the right).** Best viewed with Windows Media Player.

**Video S4. In the same Fontan patient as in video 3, after ablation and successful termination of AT1 (as shown in Video S3) a slower AT (AT2) was induced.** The activation map revealed a clock-wise re-entry circuit around a larger scar that included the site of successful ablation of AT1. Best viewed with Windows Media Player.

Downloaded from http://ahajournals.org by on March 29, 2019