Post chemoradiation re-staging of rectal cancer using MRI

Thesis submitted in accordance with the regulations of
Imperial College London

for the degree of
MD (Res)

Uday Patel MBBS FRCR
Division of Surgery, Oncology, Reproductive Biology and Anaesthetics
December 2013

Copyright Declaration

The copyright of this thesis rests with the author and is made available under a Creative Commons Attribution Non-Commercial No Derivatives licence. Researchers are free to copy, distribute or transmit the thesis on the condition that they attribute it, that they do not use it for commercial purposes and that they do not alter, transform or build upon it. For any reuse or redistribution, researchers must make clear to others the licence terms of this work.

Declaration of Originality

I declare that the research and preparation of this thesis is the result of my independent work with the exception of the technical assistance acknowledged elsewhere.

The work has not already been accepted in substance for any other degree and is not being concurrently submitted in candidature for any other degree.

Signed…… (Candidate)

Date……

ABSTRACT

The role of MRI after preoperative treatment of rectal cancer is unclear. This thesis investigates its diagnostic relevance in patient management.

Matching pathology with MR images aimed to characterise post treatment rectal cancer appearances on T2 weighted MRI and verify the proposed MRI tumour regression grading system(mrTRG). Correlation of post-chemoradiation mrTRG, T stage(ymrT), N stage(ymrN) and Circumferential Resection Margin(ymrCRM) with histopathological T stage(ypT), N stage (ypN), and pathological CRM(pCRM) was investigated. These parameters were also compared against survival outcomes.

The alternative response assessment methods of tumour volume and length change/RECIST as well as mrTRG and ymrT were evaluated against pathology. The accuracy and reproducibility of MRI parameters in assessing rectal cancer response to neoadjuvant chemotherapy was also investigated.

Patients with good response to chemoradiation(assessed by mrTRG) were enrolled into a deferral of surgery trial. Serial MRI-based monitoring enabled evaluation of quantitative imaging methods such as Apparent Diffusion Co-efficient (ADC) measurements in distinguishing tumour vs. complete response.

Pathological fibrosis correlated with low signal on MRI, tumour was intermediate signal. mrTRG showed good diagnostic accuracy against ypT&pTRG, ymrT's diagnostic accuracy was fair but improved when grouped into favourable and unfavourable categories. MRI Length&volume assessment were less consistently related. Negative ymrN and potentially clear ymrCRM correlated well with their respective pathological endpoints. Importantly, mrTRG and ymrCRM involvement predicted survival outcomes.

mrTRG showed good diagnostic accuracy against pTRG when assessing neoadjuvant chemotherapy response, ymrT correlated less well. Overall mrTRG and ymrT were the most reproducible parameters. ADC values were significantly lower in patients with tumour vs. complete response with ADC measurement of $<1.3X10^{-3}/mm^2/sec$ associated with tumour regrowth in 86% of cases.

mrTRG and MRI CRM assessment appear the most important post treatment imaging parameters. Grouped ymrT may also be useful. These parameters could be used by the multidisciplinary team to tailor treatment pre-operatively.

PUBLICATIONS

Elements of this thesis have been previously published or presented as outlined below:

Original Papers:

Patel UB, Koh DM, Tekkis P, Yu S K, Collins D, Heald RJ, Wotherspoon A, Chua S, Chau I, Tait DM, Brown G.
Serial ADC Measurements in Rectal Cancer Patients Deferring Surgery Following Chemoradiotherapy—Detecting Residual Disease, Complete Response and Tumour Regrowth.
Radiology. 2013; Submitted.

Patel UB, Blomqvist L, Taylor F, George C, Guthrie A, Bees N, Brown G.
Magnetic Resonance Imaging following treatment for Locally Advanced Rectal Cancer – How to report Tumour Response: the MERCURY Experience.
AJR. 2012; In press. Ref: 118210.

Patel UB, Brown G, Rutten H, West N, Sebag-Montefiore D, Glynne-Jones R, Rullier E, Peeters M, Van Cutsem E, Ricci S, Van de Velde C, Kjell P, Quirke P.
Comparison of Magnetic Resonance Imaging and Histopathological Response to Chemoradiotherapy in Locally Advanced Rectal Cancer.
Ann Surg Oncol. 2012;19(9):2842-52.

Patel UB, Taylor F, Blomqvist L, George C, Evans H, Tekkis P, Quirke P, Sebag-Montefiore D, Moran B, Heald R, Guthrie A, Bees N, Swift I, Pennert K, Brown G.
Magnetic Resonance Imaging-Detected Tumour Response for Locally Advanced Rectal Cancer Predicts Survival Outcomes: MERCURY Experience.
J Clin Oncol. 2011;29(28):3753-60.

Review articles:

Patel UB, Brown G.
MRI-based Assessment of Tumor Regression in Rectal Cancer.
Curr Colorectal Cancer Rep. 2012 9(2) In press.

Yu S, **Patel UB**, Tait DM, Brown G.
Primary staging and response assessment post chemoradiotherapy in rectal cancer.
Colorect. Cancer. 2012 1(1):57-70.

Evans J, **Patel UB**, Brown G.
Rectal cancer: primary staging and assessment after chemoradiotherapy.
Semin Radiat Oncol. 2011;21(3):169-77.

Invited presentations:

Patel UB, Brown G, Santos Cores J, Gil Garcia MI, Ayuso JR, Roman IP , Mas F, Risueno N, Fernandez Martos C.
Comparison of magnetic resonance imaging and histopathological response to neoadjuvant chemotherapy in locally advanced rectal cancer: The GEMCAD 0801 trial.
Radiological Society of North America Annual Conference 2012.
Code: VSGI41-10.

Patel UB, Collins DJ,Chong I,Koh DM,Tait D, Brown G.
Serial ADC measurements in rectal cancer patients deferring surgery following chemoradiotherapy.
Radiological Society of North America Annual Conference 2009. Abstract book pg 671. Code: SST04-05.

Patel UB, Barbachano Y, Quirke P, MD, Brown G.
Scoring rectal cancer regression on magnetic resonance imaging (MR) after chemo-radiotherapy. Investigating the relationship between MR score and pathological tumour regression and T stage.
Radiological Society of North America Annual Conference 2008.

Poster presentations:

Patel UB, Brown G, Santos Cores J, Gil Garcia MI, Ayuso JR, Roman IP, Mas F, Risueno N. Fernandez Martos C.
Comparison of magnetic resonance imaging and histopathological response to neoadjuvant chemotherapy in locally advanced rectal cancer: The GEMCAD 0801 trial.
American Society of Clinical Oncology Annual Meeting 2012.
J Clin Oncol 30, 2012 (suppl; abstr e14097)

Patel UB, George CD, Blomqvist L, Guthrie JA, Evans H, Brown G.
MRI Tumour Regression Grading: A New Method of Restaging Locally Advanced Rectal Cancer after Chemoradiotherapy
Radiological Society of North America Annual Conference 2011.

Patel UB, Wong G, Wotherspoon A, Brown G.
Precise interpretation of magnetic resonance (MR) imaging findings of locally advanced rectal cancer after chemo radiotherapy (CRT). How such imaging findings correlate with post operative pathological specimens.
Radiological Society of North America Annual Conference 2008.

Wong G, **Patel UB**, Brown G.
The immunopathogenesis of radiation induced fibrosis.
Radiological Society of North America Annual Conference 2008.

TABLE OF CONTENTS

ABSTRACT **4**

PUBLICATION **5**
Original Papers: 5
Review articles: 5
Invited presentations: 6

TABLE OF CONTENTS **7**

ACKNOWLEDGEMENTS **13**

1 BACKGROUND AND LITERATURE REVIEW **18**

1.1 Introduction **18**

1.2 Pathological assessment of rectal cancer **19**
1.2.1 Morphological pathological description of rectal cancer 19
1.2.2 Mucinous tumours 19
1.2.3 Pathological assessment 20
1.2.4 Pathological national minimum dataset for colorectal cancer 20
1.2.5 Pathological T staging in rectal cancer 22
1.2.6 Controversies between different TNM editions 27
1.2.7 Tumour involvement of the Circumferential Resection Margin (CRM) 29

1.3 Baseline staging of rectal tumours with MRI **30**
1.3.1 Normal bowel wall 30
1.3.2 MRI morphological description 30
1.3.3 Mucinous versus non mucinous tumours 32
1.3.4 MRI prediction of extramural spread / T-Stage 33
1.3.5 Tumour height and MRI assessment of the potential circumferential resection margin (CRM) 36
1.3.6 Peritoneal reflection involvement 39
1.3.7 MRI assessment of lymph nodes 40
1.3.8 MRI assessment of extra mural venous invasion (EMVI) 41

1.4 Rectal cancer surgery **42**
1.4.1 Total mesorectal excision 42
1.4.2 Abdominoperineal excision 42
1.4.3 Timing of surgery 42

1.5 Neo Adjuvant treatment **43**
1.5.1 Importance of local recurrence 43
1.5.2 Pre versus Post operative treatment 43
1.5.3 Selection of patients for neoadjuvant treatment 43
1.5.4 Short course radiation Vs. Long course chemoradiation 44
1.5.5 “Good” prognosis tumours 46
1.5.6 Adjuvant chemotherapy 47
1.5.7 Patient selection for neoadjuvant treatment in The Royal Marsden Network 47
1.5.8 Neoadjuvant chemotherapy prior to chemoradiation 48

1.6 Pathological restaging of rectal cancer post chemoradiation 50
1.6.1 Morphological changes post chemoradiation 50
1.6.2 Pathological T stage post chemoradiation (ypT) 50
1.6.3 Definition of tumour stages – Pathological complete response 51
1.6.4 Pathological Tumour regression grading 51
1.6.5 Pathological lymph node assessment post chemoradiation 52
1.6.6 Pathological CRM assessment post chemoradiation 53
1.6.7 Summary 54

1.7 MRI Restaging post chemoradiation 55
1.7.1 T stage on MRI post chemoradiation 55
1.7.2 N stage on MRI post chemoradiation 56
1.7.3 Refinement of T and N restaging post chemoradiation 57
1.7.4 MRI Tumour regression grading 58
1.7.5 Volumetric Analysis using MRI 59
1.7.6 MRI Length assessment /modified MRI RECIST 59
1.7.7 Diffusion weighted MR Imaging 60

1.8 Clinical importance of MRI Restaging post chemoradiation 61
1.8.1 Good response 61
1.8.2 Poor response 62

1.9 Conclusion 62

2 AIMS 63

2.1 Overall Hypothesis 63

2.2 Aims 63

3 MATERIALS & METHODS 64

3.1 Patients 64
3.1.1 Patient Databases 64
3.1.2 MERCURY study patients & statistical considerations 64
3.1.3 CORE study patients & statistical considerations 65
3.1.4 GEMCAD study patients 65
3.1.5 Deferral of surgery patients 65

3.2 High-resolution MRI scanning protocol 67
3.2.1 MR technique 67
3.2.2 MRI Quality Assurance 71

3.3 Image interpretation software- Diffusion View 73

3.4 Histopathology 73
3.4.1 Overview 73

4 POST TREATMENT HIGH RESOLUTION MRI CORRELATION WITH PATHOLOGY 74

4.1 Introduction 74

4.2 Methods & Materials 74
4.2.1 Patients 74
4.2.2 Inclusion and exclusion criteria 74
4.2.3 Preoperative treatment 76
4.2.4 Surgery 76
4.2.5 Histopathological assessment 76
4.2.6 Matching MRI images with pathology 76
4.2.7 MRI assessment 77

4.3 Statistics 78
4.3.1 Receiver Operating Curve and Kappa Analysis 78
4.3.2 Univariate logistic regression 78

4.4 Results 79
4.4.1 Demographics 79
4.4.2 Observations 79
4.4.3 MRI correlation with pathology 87

4.5 Discussion 102
4.5.1 Observations on MRI post chemoradiation 102
4.5.2 ymrT and mrTRG assessment on MRI post chemoradiation 102
4.5.3 CRM and node assessment on MRI post chemoradiation 103

4.6 Conclusion 104

5 COMPARISON OF DIFFERENT MRI RESPONSE ASSESSMENT METHODS AND HISTOPATHOLOGICAL END POINTS IN LOCALLY ADVANCED RECTAL CANCER POST CHEMORADIOTHERAPY 105

5.1 Introduction 105

5.2 Aims 106

5.3 Methods & Materials 107
5.3.1 Patients 107
5.3.2 Eligibility 108
5.3.3 Preoperative treatment 108
5.3.4 MRI technique 108
5.3.5 MRI image analysis 108
5.3.6 Surgery 112
5.3.7 Histopathological assessment 112

5.4 Statistics 113
5.4.1 Grouping of pathological endpoints 113
5.4.2 mrTRG analysis 113
5.4.3 ymrT analysis 113
5.4.4 MRI modified RECIST and MRI Volumetric Analysis. 113
5.4.5 Univariate logistic regression 114

5.5 Results 114
5.5.1 mrTRG results 116
5.5.2 Post CRT ymrT results 118
5.5.3 MRI modified RECIST analysis 119
5.5.4 MRI Volumetric Analysis 120

5.5.5 Univariate binary logistic regression results 121
5.5.6 Interobserver agreement 121

5.6 Discussion 125

5.7 Conclusion 125

5.8 Raw data tables 126

6 MRI DETECTED TUMOUR RESPONSE FOR LOCALLY ADVANCED RECTAL CANCER AND SURVIVAL OUTCOMES 127

6.1 Introduction 127

6.2 Aims 128

6.3 Methods & Materials 129
6.3.1 Patients, recruitment, preoperative treatment and surgery 129
6.3.2 MRI assessment 129
6.3.3 Histopathological assessment 130

6.4 Statistics 131
6.4.1 Grouping of data 131
6.4.2 Follow-up 131
6.4.3 Analysis 131

6.5 Results 132

6.6 Discussion 142

6.7 Conclusion 143

6.8 Supplement 143
6.8.1 Histopathological and post treatment MRI factors vs. survival 143
6.8.2 Discussion 143

7 COMPARISON YMRT AND MRTRG TO HISTOPATHOLOGICAL RESPONSE TO CHEMOTHERAPY IN 'INTERMEDIATE RISK' RECTAL CANCER 145

7.1 Introduction 145

7.2 Aims 146

7.3 Methods & Materials 147
7.3.1 Patients 147
7.3.2 Treatment 147
7.3.3 Surgery 148
7.3.4 MRI imaging technique and image interpretation 148
7.3.5 Histopathology 149

7.4 Statistics 150
7.4.1 ROC analysis 150

7.4.2 MRI modified RECIST Analysis 150
7.4.3 Univariate logistic regression 150
7.4.4 Intra-observer agreement 150

7.5 Results 151
7.5.1 Correlation of MRI parameters and pathological TRG 153
7.5.2 Examples of treatment response 157
7.5.3 CRM positive case 159

7.6 Discussion 160

7.7 Conclusions 161

8 SERIAL ADC MEASUREMENTS IN RECTAL CANCER PATIENTS DEFERRING SURGERY FOLLOWING CHEMORADIOTHERAPY— DETECTING RESIDUAL DISEASE, COMPLETE RESPONSE AND TUMOUR REGROWTH 162

8.1 Introduction 162

8.2 Aims 163

8.3 Materials and methods 164
8.3.1 Patients 164
8.3.2 Treatment 164
8.3.3 Surveillance schedule 165
8.3.4 MRI Imaging technique 165
8.3.5 MRI Diffusion weighted imaging analysis 166
8.3.6 Surgical and Pathology assessment 166

8.4 Statistics 168

8.5 Results 169
8.5.1 Patients 169
8.5.2 ADC results 175
8.5.3 Receiver operating characteristic analysis 182

8.6 Discussion 184

8.7 Conclusions 185

9 OVERALL DISCUSSION 186

9.1 Study endpoints 186

9.2 Post treatment MRI TRG, T stage, N stage and CRM assessment 187
9.2.1 Observational findings 187
9.2.2 mrTRG and ymrT assessment 187
9.2.3 MRI Nodal status and CRM assessment 188
9.2.4 Summary 189

9.3 MRI volume and length response assessment methods 190

9.4 Tumour response for rectal cancer treated with chemotherapy..... 194

9.5 The role of MRI in patients deferring surgery following good response to chemoradiation..... 196
9.5.1 Clinical considerations..... 196
9.5.2 Diffusion weighted imaging..... 197

10 FINAL CONCLUSIONS 199

11 BIBLIOGRAPHY 201

12 APPENDIX 1 REGROUPING OF MERCURY SURVIVAL DATA 213

Acknowledgements

This work was carried out during my appointment as a Radiology Registrar in the South West Thames Radiology Rotation and as an Academic Clinical Fellow in the Department of Radiology, Royal Marsden NHS Foundation Trust.

For all studies I retrieved images, collated the imaging and pathology, designed and inputted the trial database and conducted data analysis.

For the MERCURY analysis; I interpreted images and matched imaging to pathology slides with Dr Gina Brown, Dr Christopher George and Dr Hywel Evans. I also wish to acknowledge and thank the radiologists, pathologists, surgeons and nurse specialists from the original MERCURY Study Group who were responsible for the conception and design of the study and collection of data.

In the CORE study; all images were independently double read by me and Dr Gina Brown. I would also like to acknowledge and thank, Professor Harm Rutten, Professor David Sebag-Montefiore and Dr Robert Glynne-Jones for original trial design as well as referring patients. Professor Philip Quirke and Dr Nicholas West conducted the histopathological analysis.

In the GEMCAD study, image interpretation was undertaken by Dr Gina Brown, Dr Jesus Santos, Dr Maria Gil-Garcia, Dr Juan Ayuso, Dr Iciar Puchades Roman, Dr Fernando Mas Estelles and Noelia Risueno. I am also grateful to Dr Carlos Fernandez Martos, Ms Modesta Arryo and Dr Antonieta Salud, for their contributions in trial inception and patient recruitment.

During the Deferral of Surgery study I conducted image analysis along with Dr Gina Brown and Dr Dow-Mu Koh. I would also like to acknowledge Dr Stanley Yu and Dr Diana Tait for trial patient recruitment and follow-up. Dr Andrew Wotherspoon conducted the histopathological analysis.

Ms Karen Thomas, Mr Paris Tekkis and Dr Kjell Pennart provided statistical advice for all analysis.

Finally I would like to thank my supervisor Dr Gina Brown, to whom I am greatly indebted to for her guidance.

List of Figures

Figure 1.1. Minimum pathology reporting dataset 21
Figure 1.2. Semi-Annular tumour 31
Figure 1.3. Polypoid tumour 31
Figure 1.4. Mucinous tumour 32
Figure 1.5. Summary diagram of T staging 34
Figure 1.6. T3a tumour 34
Figure 1.7. T3b tumour 35
Figure 1.8. T3c tumour 35
Figure 1.9. T3d tumour 36
Figure 1.10. Low rectal tumour 37
Figure 1.11. Low rectal tumour with potential resection margin involvement 38
Figure 1.12. Peritoneal infiltration 39
Figure 1.13. Morphological criteria for nodal assessment at MR imaging 41
Figure 1.14. Selection of patients for neoadjuvant treatment at The Royal Marsden Colorectal network 48
Figure 1.15. Pathological Tumour regression grading 53
Figure 3.1. Imaging sequences for rectal cancer imaging 70
Figure 4.1. MERCURY trial progress flowchart 75
Figure 4.2. Correlating fibrosis on pathology with imaging 79
Figure 4.3. Mucinous response with imaging and pathology correlation-Example 1 81
Figure 4.4. Mucinous response with imaging and pathology correlation-Example 2 82
Figure 4.5. Mucinous degeneration post treatment in a non mucinous tumour at baseline 83
Figure 4.6. Mucinous change in lymph node post chemoradiation 83
Figure 4.7. Desmoplastic reaction 84
Figure 4.8. Nodular invasive margin 85
Figure 4.9. Pseudotumour 86
Figure 4.10. Histogram showing pathological T stage and mrTRG 88
Figure 4.11. Receiver Operating curve showing illustrating the performance of mrTRG against the binary outcome of favourable and unfavourable pathology 88
Figure 4.12. mrTRG1 89
Figure 4.13. mrTRG 2 90
Figure 4.14. mrTRG2, example 2 91
Figure 4.15. mrTRG3 91
Figure 4.16. mrTRG4 92
Figure 4.17. mrTRG5 93
Figure 4.18. Post treatment MRI T stage 95
Figure 4.19. Nodal restaging following chemoradiation treatment 97
Figure 4.20. Spiculation at the circumferential resection margin 98
Figure 4.21. Fibrosis at the potential circumferential resection margin 99
Figure 4.22. Example of incorrect CRM assessment by MRI 100
Figure 5.1. Trial progress flowchart 107
Figure 5.2. mrTRG1-5 109
Figure 5.3. mrTRG ROC analysis 117
Figure 5.4. ROC analysis of ymrT vs. Binary Pathological Regression Grade 118
Figure 5.5 Histogram showing distribution of MRI RECIST data by T stage pathology 119
Figure 5.6 MRI Volume Groups and Pathological T stage 120
Figure 6.1. mrTRG and overall survival 138
Figure 6.2. mrTRG and disease free survival 139
Figure 6.3. ypT and overall survival 140
Figure 6.4. ypT and disease free survival. 141
Figure 7.1. Trial progress flowchart 151
Figure 7.2. mrTRG vs. pathological TRG 153
Figure 7.3. ROC analysis for ymrT vs. pathological TRG 154

Figure 7.4. Acellular mucinous response post neoadjuvant chemotherapy 157
Figure 7.5. Fibrosis post neoadjuvant chemotherapy 158
Figure 7.6. Coronal T2 weighted MRI image showing involved lymph node (black arrowhead), at the potential CRM (white arrows). 159
Figure 8.1. Incremental response to CRT during follow-up 172
Figure 8.2. Extramural relapse during surveillance 173
Figure 8.3. Subtle submucosal regrowth during follow-up 174
Figures 8.4-8.7. Serial ADC measurements for reader 1, n=38 178
Figures 8.4 & 8.5. Serial mean ADC measurements in 22 patients with clinical and T2 MRI complete response initially 178
Figures 8.6. Serial mean ADC measurements in 11 patients with clinical and T2 MRI incremental response 180
Figure 8.7. Serial mean ADC measurements in 5 patients with clinical and T2 MRI of residual tumour throughout the trial 181
Figure 8.8. ROC curve used to evaluate optimum cut-off between complete response and residual/ regrowth of tumour 183
Figure 9.1. Neoadjuvant chemotherapy for MRI defined high risk rectal cancer 195

List of Tables

Table 1.1. Astler and Coller's Modification of the Dukes' staging system 22
Table 1.2. Definitions of TNM components in the 7th edition of the AJCC system for staging cancer of the colon & rectum, 2010 24
Table 1.3. Overall 7th Edition TNM staging summary from the American Joint Committee on Cancer 25
Table 1.4. MRI based T staging of rectal tumours 33
Table 1.5. Treatment of rectal tumours, NICE guidelines (NICE 2011) 45
Table 1.6. Tumour regression grading of rectal cancer on MR imaging 59
Table 3.1 Imaging sequences for rectal imaging using Siemens' 1.5 T MR System 68
Table 3.2 Imaging sequences for rectal imaging using Philips' 1.5T Integra System 69
Table 3.3. Small field of view Diffusion weighted imaging parameters 71
Table 4.1. mrTRG and pathological T stage 87
Table 4.2. The sensitivity and specificity of different mrTRG cut-offs vs. pathological T stage 88
Table 4.3. Pathological T stage and ymrT 94
Table 4.4. Raw data for Nodal status and CRM status 96
Table 4.5. Pathological endpoints by MRI parameters 101
Table 5.1. Patient characteristics of patients with full imaging and pathology n=78 115
Table 5.2. Histopathological T stage by individual mrTRG grade 116
Table 5.3. mrTRG vs. Pathological Tumour Regression Grade 116
Table 5.4 Histopathological T stage by individual ymrT stage 118
Table 5.5. ymrT Vs. Pathological Tumour Regression Grade 118
Table 5.6. MRI RECIST vs. Pathological T stage 119
Table 5.7. Mann-Whitney U test results for MRI RECIST and T stage pathology 120
Table 5.8. MRI Volume Change vs. Pathological T stage 120
Table 5.9. Kruskal Wallis Analysis of MRI Volume Change vs. T stage pathology 121
Table 5.10. ypT pathology status by clinical and MRI parameters 122
Table 5.11. TRG pathology status by clinical and MRI parameters 123
Table 5.12. Interobserver agreement of MRI parameters 124
Table 6.1. Patient demographics and survival outcomes in 111 patients undergoing preoperative therapy in the MERCURY study 134
Table 6.2. Multivariate analysis preoperative factors, Data presented as Hazard ratios 136
Table 6.3. Multivariate analysis histopathologic factors, Data presented as Hazard ratios 137
Table 6.4. Multivariate analysis MRI and histopathologic factors, Data presented as Hazard ratios 144
Table 7.1. Chemotherapy alone in the treatment of rectal cancer 146
Table 7.2. Patient characteristics of patients with full imaging and pathology 152
Table 7.3. Raw data table for mrTRG vs. pathological TRG 153
Table 7.4. Raw data table for ymrT vs. pathological TRG 154
Table 7.5. MRI RECIST vs. Pathological TRG 155
Table 7.6. Mann-Whitney U test results for MRI RECIST and TRG pathology 155
Table 7.7. TRG pathology status by MRI parameters 156
Table 8.1. Trial surveillance protocol 167
Table 8.2. Baseline, pre-treatment, post treatment and tumour characteristics of 41 patients undergoing deferral of surgery following chemoradiotherapy for rectal cancer 170
Table 8.3. Characteristics of 10 patients that relapsed during surveillance 171
Table 8.4. ADC results 175
Table 8.5 Raw ADC data for reader 1, n=38 176
Table 8.6. Sensitivity and Specificity for tumour at different ADC pixel values 182
Table 9.1. Studies Correlating workstation calculated tumour volume change against pathology 191
Table 9.2. Studies Correlating workstation calculated tumour volume change against survival 192
Table 9.3. Studies investigating tumour ADC change pre and post chemoradiation 198

List of Abbreviations

mrT; Baseline MRI T stage.
mrN; Baseline MRI N stage.
EMVI; Extramural vascular invasion.

y; Post treatment.
ymrT; Post treatment MRI T stage.
ymrN; Post treatment MRI N stage.
ymrCRM; Post treatment MRI circumferential resection margin.

mrTRG; MRI based tumour regression grading.
mrRECIST; MRI based Response Evaluation Criteria In Solid Tumours.

TME; Total mesorectal excision.
APE; Abdominoperineal excision.

pTRG; Pathological tumour regression grade.
ypT; Pathological T stage post treatment.
ypN; Pathological N stage post treatment.
pCRM; Pathological circumferential resection margin.
pCR; Pathological complete response.
H&E; Haematoxylin and eosin stain.

OS; Overall survival.
DFS; Disease free survival.
LR; Local recurrence.
HR; Hazard ratio.

DWI; Diffusion weighted imaging.
ADC; Apparent diffusion coefficient.

CRT; Chemoradiotherapy.
RT; Radiotherapy.
PET; Positron Emission Tomography.
CEA; Carcinoembryonic antigen.

1 Background and Literature Review

1.1 Introduction

Colo-Rectal cancer is the third most common form of cancer in the UK, with 33000 new cases every year (accounting for 12% of all new cancers) (Office for National Statistics 2011). It is the second commonest cause of cancer-related mortality, responsible for more than 16,000 deaths per year, or 10% of the total (Koh, Brown et al. 2005). Rectal tumours have a relatively poor prognosis due to the high risk of metastases and local recurrence. Total Mesorectal Excision (TME) is the surgical treatment of choice as it gives the best chance of a tumour-free circumferential resection. TME involves complete removal of the rectum and surrounding mesorectal fat by sharp dissection along the investing mesorectal fascia (Heald and Ryall 1986).

High resolution pelvic magnetic resonance imaging is a well validated tool for the baseline staging of rectal cancer. The plane for TME excision, the circumferential resection margin (CRM), is well demonstrated on MR. Studies have demonstrated that 94% of patients with MRI predicted negative CRM had tumour free resection margins on histopathological examination (MERCURY 2006). In the 20-30% of patients which have involvement of the CRM on baseline MR imaging there is a high likelihood of not achieving curative resection. This group of patients is offered preoperative chemo radiation therapy (CRT) in many UK centres. This approach has been shown to reduce the recurrence rate from 8.2% to 2.4% at 2 years (Kapiteijn, Marijnen et al. 2001).

At present after CRT patients undergo surgery at a date determined at the beginning of each case, often without restaging imaging. However there is increasing interest that imaging can be used to restage disease post CRT, and used to tailor treatment. Histopathologists have reported in up to 25% of patients no residual tumour is seen on pathological examination. i.e. a complete response of a locally advanced tumour to neo-adjuvant CRT (O'Neill, Brown et al. 2007). Identification of such excellent response as well as poor response prior to definitive surgery is an important goal- excellent responders may be offered less radical treatment, and poor responders could be considered for more radical surgery or second line chemo-radiotherapy (Habr-Gama, Perez et al. 2004).

This thesis investigates several approaches to accurately restage residual tumour/ fibrosis post CRT. The background for this thesis explores the current standard of care and what is known regarding the restaging of rectal cancer:

1.2 Pathological staging of rectal cancer.
1.3 Baseline MRI staging of rectal cancer with MRI.
1.4 Surgery.
1.5 Neoadjuvant treatment.
1.6 Pathological staging of rectal cancer post chemoradiation.
1.7 Restaging of rectal cancer post chemoradiation.
1.8 Clinical importance of restaging rectal cancer.

1.2 Pathological assessment of rectal cancer

1.2.1 Morphological pathological description of rectal cancer

Rectal and rectosigmoid cancer account for up to 50% of all large bowel cancers. The majority; 60% of colorectal cancers are moderately differentiated adenocarcinomas with the remaining approximately 20% well differentiated and 20% poorly differentiated (Jass, Atkin et al. 1986).

Rectal tumours commonly arise from pre-existing mucosal adenomas that develop increasing degrees dysplasia from mild to severe. Such adenomas may be polypoid or flat and have a tubular or villous configuration. Macroscopically rectal tumours commonly appear as an ulcerating tumour with a central depression and raised rolled edges. When these tumours encompass the full circumference of the bowel wall forming an annular growth, they produce marked stricturing of the bowel lumen increasing the risk of bowel obstruction or perforation. Ulcerating tumours, even when a relatively small size, may produce a stricture causing stenosis. (Cohen, Brown et al. 1981; Bjerkeset, Morild et al. 1987; Michelassi, Leuthner et al. 1987).

A fairly well circumscribed border is commonly seen when rectal tumours invade through the bowel wall into perirectal fat. However, in 25% of cases the pattern of spread is widely infiltrative with ill-defined borders. This infiltrative pattern of spread has been shown to worsen prognosis (Grinnell 1966; Spratt JA 1967; Jass, Atkin et al. 1986). Conversely, the presence of an inflammatory response at the advancing margin of the tumour has been observed as a favourable prognostic feature (Jass, Atkin et al. 1986; Halvorsen and Thompson 1989).

Colorectal tumours, unlike upper gastrointestinal tumours, rarely show submucosal or intramural spread beyond their macroscopic borders. This characteristic is important in the surgical planning of resection margins (Hughes 1983; Madsen and Christiansen 1986; Andreola, Leo et al. 1997).

1.2.2 Mucinous tumours

Pathologically mucinous tumours are defined as a tumour containing >75% mucin and form a distinct subgroup of rectal tumours. Mucinous tumours have a gelatinous appearance caused by secretion of mucus by tumour cells causing the formation of pools/ lakes of extracellular mucin, lined by columns of malignant cells, cords and vessels. This gives an overall meshlike internal structure (Secco, Fardelli et al. 1994).

Mucinous tumours account for 10% of carcinomas of the large intestine and represent a poor prognostic subgroup (Sasaki, Atkin et al. 1987). The 5-year survival for mucinous carcinomas has been recorded at 11% versus 57% for nonmucinous carcinomas. The reason for this difference maybe because mucinous rectal carcinomas are usually diagnosed at a more advanced stage due to a greater tendency to infiltrate diffusely (Pihl, Nairn et al. 1980).

1.2.3 Pathological assessment

Most laboratories use a similar protocol for specimen processing; A freshly resected specimen is initially opened anteriorly, pinned on to a board, and fixed in 10% formalin. Dissection is then performed and generally consists of serial 5-10 mm slicing of the whole tumour and the surrounding mesorectum in the transverse plane.

The maximum extent of tumour spread from the outer limit of the muscularis propria is measured by ruler, this measurement is to the edge of tumour's greatest distance of penetration from the muscular wall, be it direct, discontinuous, vascular or lymph node involvement. Area(s) of involvement can usually be seen by naked eye and any suspicious areas are sampled for histology. The slice containing the most lateral spread is identified as the "primary slice" and is selected for division into blocks which are all embedded and processed for haematoxylin and eosin (H&E) staining. Sometimes one block is sufficient but up to six can be needed in cases with extensive spread. On average four blocks suffice for the majority of tumours. Remaining slices are wholly embedded for single large-mount sections of the tumour and mesorectum, cut at 10 pxn on a sledge microtome, and stained with H&E. The circumferential resection margin of the block is marked with India ink to demarcate it on histology and rule out false positive tumour involvement of a tissue margin caused by poor embedding practice (Quirke, Durdey et al. 1986).

The rest of the specimen both above and below the tumour is then serially sliced. While incising the mesentery and mesorectum, lymph nodes and tumour deposits are identified and sampled. Metastases and lymph nodes adjacent to the circumferential margin are sampled en-bloc with the resection margin again identified by painting with India ink.

1.2.4 Pathological national minimum dataset for colorectal cancer

In the UK the Royal College of Pathologists has developed a national minimum dataset for the reporting of colorectal cancer. The dataset has been approved by all the professional bodies in the UK concerned with treating colo-rectal cancer. The reporting proforma is shown in Figure 1.1. The adoption of a proforma has been shown to increase the completeness of the reporting. The following sections give background on the different data recorded (Quirke and Morris 2007).

Figure 1.1. Minimum pathology reporting dataset

APPENDIX C PROFORMA FOR COLORECTAL CANCER RESECTIONS

Surname: ..... Forenames: ..... Date of birth: .....

Hospital..... ..... Hospital no: ..... NHS no: .....

Date of receipt: ..... Date of reporting: ..... Report no: .....

Pathologist: ..... Surgeon: ..... Sex: .....

Specimen type: Total colectomy / Right hemicolectomy / Left hemicolectomy / Sigmoid colectomy / Anterior resection / Abdominoperineal excision / Other (state) .....

Gross description

Site of tumour .....

Maximum tumour diameter: .....mm

Distance of tumour to nearer cut end .....mm

Tumour perforation (pT4) Yes ☐ No ☐

If yes, perforation is serosal ☐ retro/infra peritoneal ☐

For rectal tumours:

Relation of tumour to peritoneal reflection (tick one):

Above ☐ Astride ☐ Below ☐

Plane of surgical excision (tick one):

Mesorectal fascia ☐

Intramesorectal ☐

Muscularis propria ☐

For abdominoperineal resection specimens:

Distance of tumour from dentate line .....mm

Histology

Type

Adenocarcinoma Yes ☐ No ☐

If No, other type .....

Differentiation by predominant area

Well / moderate ☐ Poor ☐

Local invasion

No carcinoma identified (pT0) ☐

Submucosa (pT1) ☐

Muscularis propria (pT2) ☐

Beyond muscularis propria (pT3) ☐

Tumour invades adjacent organs (pT4a) ☐

AND/OR

Tumour cells have breached the serosa (pT4b) ☐

Maximum distance of spread beyond muscularis propria .....mm

Response to neoadjuvant therapy

Neoadjuvant therapy given Yes ☐ No ☐ NK ☐

If yes:

No residual tumour cells / mucus lakes only ☐

Minimal residual tumour ☐

No marked regression ☐

Tumour involvement of margins

	N/A	Yes	No
Doughnuts	☐	☐	☐
Margin (cut end)	☐	☐	☐
Non-peritonealised 'circumferential' margin	☐	☐	☐

Histological measurement from tumour to non-peritonealised margin ..... mm

Metastatic spread

No of lymph nodes present .....

No of involved lymph nodes .....

(pN1 1–3 nodes, pN2 4+ nodes involved)

Highest node involved (Dukes C2) Yes ☐ No ☐

Extramural venous invasion Yes ☐ No ☐

Histologically confirmed distant metastases (pM1):

Yes ☐ No ☐ If yes, site: .....

Background abnormalities: Yes ☐ No ☐

If yes, type: (delete as appropriate)

Adenoma(s) (state number .....)

Familial adenomatous polyposis / Ulcerative colitis / Crohn's disease / Diverticulosis / Synchronous carcinoma(s)

(complete a separate form for each cancer)

Other .....

Pathological staging

Complete resection at all surgical margins

Yes (R0) ☐ No (R1 or R2) ☐

TNM (5th edition)

(y) pT ..... (y) pN .....(y) pM .....

Dukes

Dukes A ☐ (Tumour limited to wall, nodes negative)

Dukes B ☐ (Tumour beyond M. propria, nodes negative)

Dukes C1 ☐ (Nodes positive and apical node negative)

Dukes C2 ☐ (Apical node involved)

1.2.5 Pathological T staging in rectal cancer

Historical perspectives

In 1932 Cuthbert Dukes proposed the first recorded staging system for colo-rectal cancer based on analysis of 215 patients. Three stages of disease were defined:

A: Cancer limited to the rectal wall.
B: Spread of the cancer into extrarectal tissues but no nodal involvement.
C: Lymph node involvement present.

Later studies showed statistically significant differences in post operative survival with three-year survival of 80%, 73% and 7% for groups A, B and C respectively (Dukes 1932.). In subsequent years, the Dukes system was further modified, in 1954 Astler and Coller noted statistically significant differences in overall survival between different depths of tumour penetration. They proposed subdivision of Duke's C cases into C1 and C2 to underline the importance of the degree of local tumour extension in the presence of involved lymph nodes. This is shown in Table 1.1. (Astler and Coller 1954).

Table 1.1. Astler and Coller's Modification of the Dukes' staging system

Stage	Histopathology definition	Five year overall survival
A	Lesion limited to the mucosa	100%
B1	Lesion involving the submucosa or muscularis propria but not beyond it	66.6%
B2	Lesion beyond the muscularis propria	53.9%
C1	B1. With nodal metastasis	42.8%
C2	B2. With nodal metastasis	22.4%

The TNM staging system

In 1985, a general staging system for solid organ cancers of all sites was jointly proposed by the American Joint Committee on Cancer (AJCC) and the Union Internationale Contre le Cancer (UICC). The TNM system maps the anatomical extent of the malignancy using:

Size and extent of the primary tumour (T),
The absence or extent of regional lymph node metastasis (N),
The presence or absence of distant metastasis (M).

A higher numerical value (ranging between 0 and up to 4) is given the greater the extent of the cancer in each of the TNM categories. Various TNM groupings are divided into stages (Stage I to IV) based on prognosis.

The TNM staging system is revised every five years by a group of experts appraising recent clinical trials. In clinical guidelines TNM is linked to treatment approaches, therefore

changes to the TNM classification have important implications for patient care. The most recent TNM 7 system was released in 2010 and is detailed in table 1.2.

Table 1.2. Definitions of TNM components in the 7th edition of the AJCC system for staging cancer of the colon & rectum, 2010

Category	*Description*
Tx	The primary tumour cannot be assessed
T0	No evidence of primary tumour
Tis	Carcinoma in situ (intraepithelial or intramucosal carcinoma)
T1	Tumour invades into the submucosa
T2	Tumour invades into the muscularis propria
T3	Tumour invades through the muscularis propria into the subserosa, or into non-peritonealised pericolic or perirectal tissues Optional subdivision of T3: T3a Minimal invasion: <1mm beyond the border of the muscularis propria T3b Slight invasion: 1-5mm beyond the border of the muscularis propria T3c Moderate invasion: ≥5-15mm beyond the border of the muscularis propria T3d Extensive invasion: ≥15mm beyond the border of the muscularis propria
T4	Tumour directly perforates the visceral peritoneum (T4a) or invades into other organs or structures (T4b)
Nx	Regional lymph nodes cannot be assessed
N0	No regional lymph node metastases
N1	Metastatic tumour in 1 to 3 pericolic or perirectal lymph nodes N1a Metastasis in one regional lymph node N1b Metastasis in 2–3 regional lymph nodes N1c Tumour deposit(s) in the subserosa, mesentery, or nonperitonealised pericolic or perirectal tissues without regional nodal metastasis
N2	Metastatic tumour in 4 or more pericolic or perirectal lymph nodes N2a Metastasis in 4–6 regional lymph nodes N2b Metastasis in 7 or more regional lymph nodes
Mx	The presence of distant metastasis cannot be assessed
M0	No distant metastasis
M1	Distant metastasis present

Table 1.3. Overall 7th Edition TNM staging summary from the American Joint Committee on Cancer

Stage			
0	Tis	N0	M0
I	T1	N0	M0
	T2	N0	M0
IIA	T3	N0	M0
IIB	T4a	N0	M0
IIC	T4b	N0	M0
IIIA	T1-2	N1/N1c	M0
	T1	N2a	M0
IIIB	T3-T4a	N1/N1c	M0
	T2-T3	N2a	M0
	T1-T2	N2b	M0
IIIC	T4a	N2a	M0
	T3-T4a	N2b	M0
	T4b	N1-N2	M0
IVA	Any T	Any N	M1

T staging

The TNM system for staging cancer of the colon and rectum was originally devised to correspond directly with the original Dukes system (Dukes 1932.): Stage I, Dukes A; Stage II, Dukes B; Stage III, Dukes C with Stage IV corresponding to the presence of distant metastases. However with periodic review and new prognostic outcome data the latest (7th) revision, published in 2010 is much changed from this original template. Current TNM staging criteria is shown in Table 1.2. The TNM classification is the standard for colorectal cancer staging, recommended in the UK by the Royal College of Pathologists and in the USA by College of American Pathologists.

Both T1 and T2 tumours have high 5-year survival rates. TNM 6&7 suggested an optional sub-classification of T3 tumours according to measured depth of extramural invasion. A four tiered subclassification was proposed (≤1mm; 1-5mm; ≥5-15mm; ≥15mm). This was to address the wide range of survival reported in patients with T3 tumours, which make up 80% of those seen in clinical practice (Wittekind, Henson et al. 2003).

T3 subdivision is carried out as follows: the sections are first examined microscopically for lateral circumferential resection margin involvement. If the margin is clear, the extent of extramural spread is measured from the muscularis propria to the outermost part of the tumour; if mesorectal tumour or lymph node deposits are present the measurement is made to the outer border of the deposit. As well as indicating T substage this enables detection of surgical margin involvement (Quirke, Durdey et al. 1986).

A T4a tumour was classified in TNM 5&6 as a tumour directly invading other organs, while a T4b tumour invaded the visceral peritoneum. This sub-classification was reversed

in TNM 7 and has been suggested to be more intuitive, with the invasion of the peritoneal surface- despite the risk of transcoelomic metastasis- representing a less advanced stage than direct organ invasion (Doyle and Bateman 2012).

Lymph Node Involvement

Assessment of positive lymph nodes

Upon retrospective review of 379 histological sections from patients with rectal cancer Jass et al identified lymph node involvement as one of four pathological variables that independently affected long-term cancer-associated mortality. The other three variables included; invasive margin, peritumoural lymphocytic infiltration, and local spread (T stage) (Jass, Love et al. 1987). Such studies lead the 5&6 editions of the TNM classification to subdivide stage III patients according to the depth of tumour penetration and the number of proven lymph nodes; with N1 indicating 1 to 3 involved pericolic or perirectal lymph nodes and N2 indicating involvement of 4 or more lymph nodes.

More recently a Surveillance, Epidemiology, and End Results (SEER) analysis of over 35,000 patients with rectal cancer stratified N1 and N2 disease as follows: N1a/N1b (one vs. two-three nodes) and N2a/N2b (four-six vs. seven nodes). A statistically significant difference in 5-year survival was shown between patients with one positive node (N1a) and those with two to three positive nodes (N1b). Furthermore patients with four to five positive nodes (N2a) have a better prognosis than patients with seven positive nodes (N2b) (Gunderson, Jessup et al. 2010). The latest, 7th edition of the TNM staging system (Table 1.2) incorporates these changes.

Number of lymph nodes excised

Detection of metastatic deposits in lymph nodes is improved by examining multiple pathological sections (Messerini, Cianchi et al. 2006). This has been supported by several studies concluding that a high nodal harvest is related to improved survival in both stages II and III disease (Puppa, Sonzogni et al. 2010). In the UK, the Royal College of pathologists recommends examining a minimum of 12 nodes (Sobin and Greene 2001).

As well as macrometastatic nodal disease, small deposits of tumour cells, less than 2 mm in diameter can also be found in regional lymph nodes. These have been defined as nodal micrometastases. Micrometastases are only seen in a small minority of nodes using routine H&E stains with immunohistochemical techniques using monoclonal antibodies targeting specific proteins shown to be more sensitive (Puppa, Sonzogni et al. 2010).

The significance of micrometastases is debatable with some studies suggesting they may not affect survival as they are biologically distinct from macrometastases because they lack their own blood supply (Schofield, Mounter et al. 2006). The present TNM 7th edition classifies nodal micrometastasis as N1 disease, with the number of lymph nodes involved by micrometastasis to be clearly stated

1.2.6 Controversies between different TNM editions

1.2.6.1 Extramural Tumour deposits

Tumour deposits are discrete nodules of adenocarcinoma deposited in pericolonic and perirectal fat. Their prevalence ranges from 6% to 64%. The presence of extramural deposits implies that cancer cells have spread discontinuously, presumably via lymphatic /venous channels. Such aggressive tumours have a poorer prognosis, irrespective of other factors (Ono, Yoshinaga et al. 2002).

1.2.6.2 Extramural Venous invasion

Extramural venous invasion has been demonstrated in 10 to 22% of post operative specimens in colorectal cancer (Shirouzu, Isomoto et al. 1991; Saclarides, Bhattacharyya et al. 1994). Shirouszu upon prospectively reviewing postoperative specimens of 645 patients with colorectal cancer found the degree of pathological vascular invasion influenced the likelihood of liver metastasis and survival. For example in patients with Dukes' stage C, survival was 77% for slight vascular invasion; 56% for moderate, and 44% for marked venous invasion. A similar relationship was seen for Dukes A and B. Extramural venous invasion has also been found to be significantly associated with the likelihood of nodal dissemination (Saclarides, Bhattacharyya et al. 1994).

1.2.6.3 Extramural Tumour deposits definition in TNM classifications

Satellites of tumour within the mesorectum have generated a great deal of interest and controversy. Extramural/Peritumoural deposits have been recognized as an entity since at least 1935, when Gabriel et al noted their existence (Gabriel and Bussey 1935). The source of such deposits is uncertain as there is no associated lymph node architecture, making their optimum classification unclear. Some authors suggest that they derive from vascular metastases that grow through the vessel wall and into the surrounding tissue, while others suggest they represent direct extension from the adenocarcinoma or completely replaced lymph nodes (Goldstein and Turner 2000).

TNM 4&5

Up to and including the 4th TNM edition in 1992, it was left to the pathologist to determine whether peritumoural satellites represented of T, N or venous invasion (Hermanek 1993). The TNM 5 system (1997) defined discrete tumour cell collections in the perivisceral fat ≤3mm in size as primary tumour and tumour cell collections in the perivisceral fat >3mm as nodal disease. This was based on a study that was not subsequently published. Extramural vascular invasion was defined as “tumour present within an extramural endothelium lined space surrounded by either a rim of muscle of contains red blood cells” (Williams, Quirke et al. 2007)

TNM 6

Subsequent work by Goldstein et al showed that increasing peritumoral deposit size was associated with decreased survival and deposits of any size, including those less than 3 mm in maximum dimension, had a significantly worse survival relative to the absence of deposits (Goldstein and Turner 2000). Therefore in TNM 6 (2002), the size criteria was replaced with shape, with a nodule in the perivisceral fat considered as venous invasion if the nodule was irregular in contour and as lymph node metastasis if the nodule was smooth in contour. Venous invasion was coded as an extension to T stage.

The TNM 6 definition has been shown to be poorly reproducible. A study by Howarth et al asked 23 pathologists to assess extramural nodules in 80 cases according to TNM 6. The interobserver agreement was marginal at 0.36. Importantly 5 of the 80 cases were upstaged from N0 to N1 and would therefore have been offered adjuvant chemotherapy (Howarth, Morgan et al. 2006). Furthermore recent data has shown that the shape of tumour deposits is not related to their origin, and that the use of this criteria has less prognostic value than the 3 mm rule (Nagtegaal, Tot et al. 2011).

TNM 7

Further changes were proposed in TNM 7 (2010); with lymph node metastasis defined by the reporting pathologist as a node completely replaced with tumour (generally having a smooth contour) while nodules with an irregular contour are placed in a new N1c category, (stage III disease) (Quirke, Cuvelier et al. 2010). Given these distinctions are at the discretion of the reporting pathologist the definition has been suggested to essentially revert back to the TNM 4 criteria (Sobin, Compton et al. 2010). As noted by Ricci, some inconsistencies ensue; for example, the N status of a patient with tumour deposits only would be N1c, whereas a case with tumour deposits and 1 to 3 positive "true" lymph node(s) would paradoxically "regress" to N1a/b (Ratto and Ricci 2011).

The TNM 7 definition has been considered by some to be poorly reproducible (Nagtegaal and Quirke 2010) and shown to offer no significant improvement in prognostic value over TNM5 (Ueno, Mochizuki et al. 2012). This has lead to several leading pathologists to continue to use the TNM 5 criteria (Nagtegaal and Quirke 2010). For example the UK Royal College of pathologists use TNM 5 in the in the minimum dataset, stating this criteria is quantitative and can be used as a starting point to test hypotheses in clinical trials (Quirke, Cuvelier et al. 2010).

New proposals

A study by Ueno investigating the impact of peritumoural deposits on survival has suggested a revised classification based on peritumoral deposit origin. On retrospective review pathological samples of 1027 patients, 205 patients were found to have peritumoural deposits. Deposits were classified as according to contour (TNM 6 criteria) as well as vascular invasion (confined to a vascular space), non vascular invasion, or aggressive non vascular invasion (defined as invasion by a tumour deposit into adjacent vessel/nerve). The hazard ratios for patients with smooth and irregular contour deposits were 3.5 and 3.9

respectively. Vascular invasion, non vascular invasion and aggressive non vascular invasion had hazard ratios of 2.5, 4.7 and 8.0 respectively (Ueno, Mochizuki et al. 2007).

By using the Akaike information criterion, N staging was found to predict survival outcome with the highest accuracy when both nodal involvement and non-vascular deposits were combined together as an N factor and vascular invasion was treated as a T factor (Ueno, Mochizuki et al. 2007). Given the poor prognosis of patients with aggressive non vascular deposits Puppa et al has proposed assigning these lesions to the M category as in-transit metastases of colorectal cancer (Puppa, Sonzogni et al. 2010).

1.2.7 Tumour involvement of the Circumferential Resection Margin (CRM)

When the surgically excised specimen is sectioned transversely, the lateral border of the specimen is termed the circumferential resection margin. One of the main predictors of postoperative recurrence is involvement of the operative circumferential resection margin due to lateral spread of the tumour. A positive circumferential resection margin (CRM) is defined as tumour within 1mm of the edge of the resected specimen.

The importance of CRM involvement was first described by Quirke et al in a study of 52 patients. Spread to the lateral resection margin was noted in 14 /52 patients and 12 of these proceeded to local pelvic recurrence (Quirke and Dixon 1988). In a further prospective study of 190 patients with rectal cancer, Cox's regression analysis showed tumour involvement of the circumferential margin (tumour within 1mm of the CRM) independently influenced both local recurrence (HR=12.2 (4.4-34.6)) and survival (HR=3.2 (1.6-6.53)), (Adam, Mohamdee et al. 1994).

In Quirke et al's initial study, each tumour was embedded in its entirety with preparation of multiple wholemount blocks. Quirke later showed that visual inspection of the macroscopic slices was sufficient to select sections with suspected CRM involvement (Quirke and Dixon 1988; Adam, Mohamdee et al. 1994). This has also proved to be reproducible in other institutions (de Haas-Kock, Baeten et al. 1996). Therefore, CRM involvement became an important addition to the pathological staging of rectal cancer.

There is a relationship between the CRM status and the height of the tumour, with low rectal cancers having higher risk of positive CRM (25.9% versus 16.5% in a series by Kapiteijn et al) (Kapiteijn, Marijnen et al. 2001), with subsequent significant increase in local recurrence (Nagtegaal, van de Velde et al. 2002). Currently, a distal resection margin of at least 2 cm from the cancer is regarded as standard, though given the relative rarity of distal intramural spread, a 1 cm margin as standard has also been proposed (Pricolo, Abodeely et al. 2010). This is important in surgical planning for low rectal cancer, where options include a low anterior resection (with an anastomosis potentially in the anal canal) or an abdominoperineal excision with stoma formation.

1.3 Baseline staging of rectal tumours with MRI

Two main imaging techniques have been investigated for staging rectal cancer pre-operatively. They are endoluminal ultrasound (EUS) and MRI. Both techniques can differentiate tumour from the normal rectal wall (unlike CT). Studies have shown that MRI depicts anatomy beyond the immediate vicinity of the rectum more accurately than EUS (Blomqvist, Machado et al. 2000; Brown, Davies et al. 2004).

1.3.1 Normal bowel wall

The rectal wall in anatomical cross section comprises the mucosal layer, the muscularis mucosa, submucosa and muscularis propria which is turn comprises the circular and longitudinal layers.

T2-weighted imaging sequences depict the rectal wall anatomy clearly. The MRI appearances of the bowel wall show the mucosal layer as a fine low signal line on T2 weighted imaging, beneath the mucosa lies the thicker higher signal submucosal layer. The muscularis propria is represented by an intermediate hypointense layer. The outer longitudinal muscle layer of the muscularis propria can have an irregular grooved appearance with interruptions due to vessels entering the rectal wall. The perirectal fat appears hyper intense (Brown, Richards et al. 1999).

1.3.2 MRI morphological description

Rectal tumours have two common macroscopic appearances on MRI. One appearance is that of an ulcerating tumour with raised rolled edges and a central depression (figure 1.2). If these tumours grow to involve the full bowel wall circumference, they produce marked stricturing - increasing the risk of bowel obstruction. Exophytic or polypoidal tumours have a distinctive protuberant morphology with a tumour mass projecting into the lumen (figure 1.3). Several studies have indicated that polypoidal lesions are often of a relatively low grade of malignancy (Cohen, Wood et al. 1980; Michelassi, Ayala et al. 1991).

Figure 1.2. Semi-Annular tumour

Axial T2 weighted fast spin-echo image (A) and corresponding histological (H&E stained) wholemount section (B) demonstrating a semiannular plaque of tumour with central ulceration (arrowhead) and raised rolled edges (arrows).

A) B)

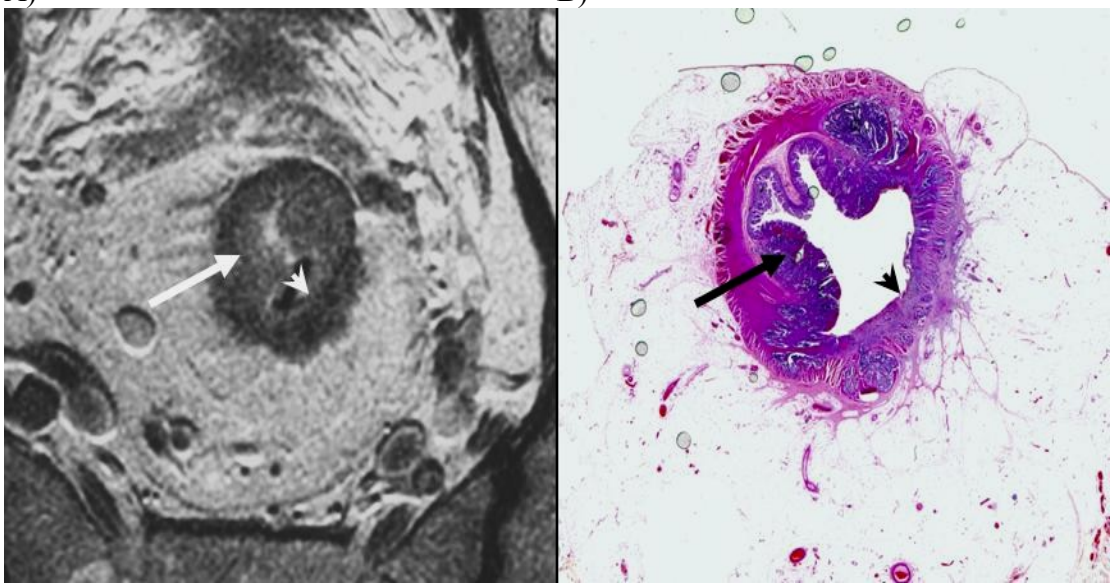

Figure 1.3. Polypoid tumour

High resolution T2 weighted fast spin-echo image (A) and corresponding histological (H&E stained) wholemount section (B) demonstrating a T1 polyp (long arrow). There is partial preservation of the submucosal layer (short arrow) seen as a thin rim of high signal intensity deep to the tumour.

A) B)

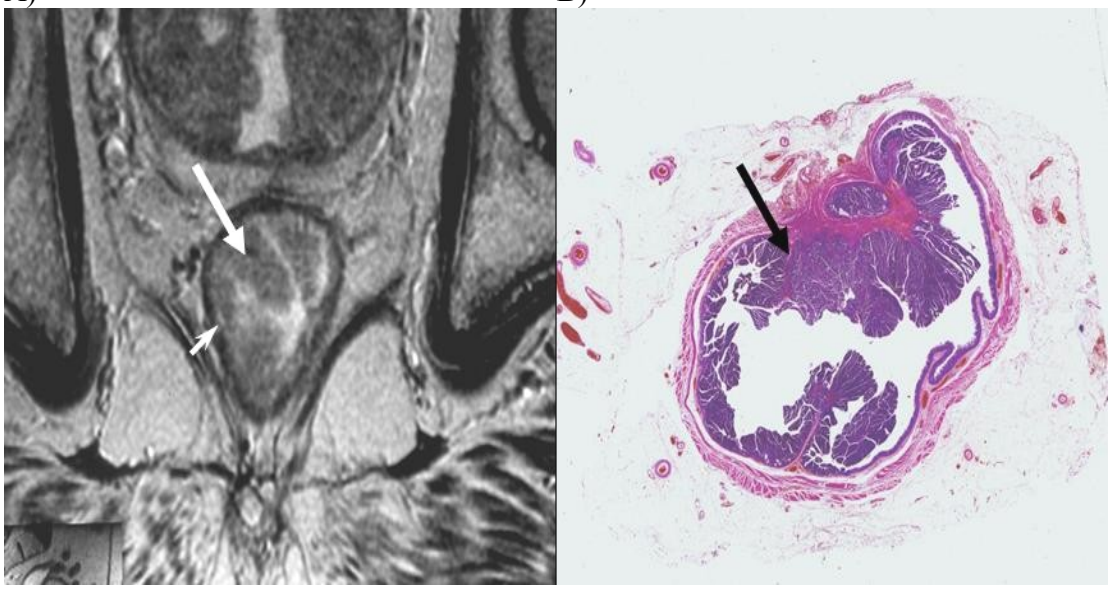

1.3.3 Mucinous versus non mucinous tumours

As previously mentioned, mucinous tumours form a distinct subgroup of tumours. Non mucinous rectal tumours are generally intermediate signal intensity on T2 weighted imaging, with higher signal intensity than the circular and longitudinal muscle layers but lower signal intensity than the submucosa.

Mucinous rectal tumours have much higher signal intensity on the T2-weighted images compared to both muscle and fat as shown in figure 1.4. This was quantified by Hussain et al, showing that 9 patients with pathologically proven mucinous rectal tumours had significantly higher tumour to muscle, tumour to fat, and tumour to urine signal intensity ratios compared with the 17 patients with nonmucinous tumours (Hussain, Outwater et al. 1999).

Figure 1.4. Mucinous tumour

High resolution axial T2 weighted fast spin-echo image demonstrating an advanced predominantly high signal mucinous tumour (long arrow). Short arrows show the potential circumferential resection margin.

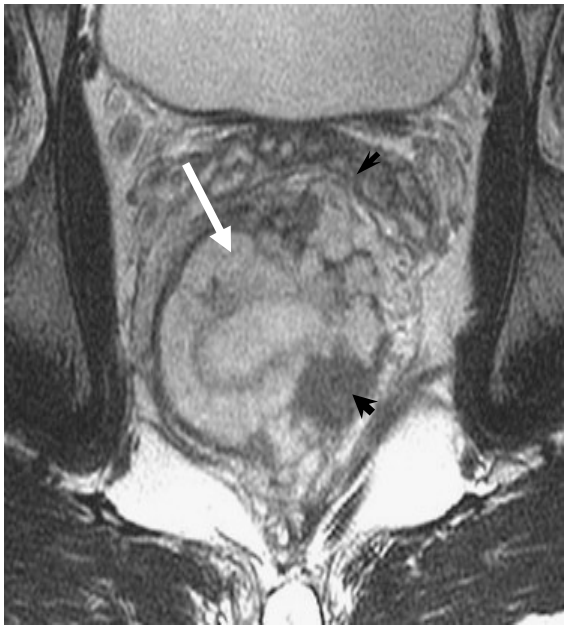

1.3.4 MRI prediction of extramural spread / T-Stage

MRI based T staging is based on the degree to which intermediate tumour signal invaded the different layers of the bowel wall. MRI based T staging is summarised in Table 1.4 (Iafrate, Laghi et al. 2006).

Table 1.4. MRI based T staging of rectal tumours

Tumour stage.	Imaging criteria.
T1	Tumour signal intensity is confined to the submucosal layer. The signal intensity is low compared to the high signal intensity of the adjacent submucosa.
T2	Tumour signal intensity extends into the muscle layer, with loss of interface between the submucosa and circular muscle layer.
T3	Tumour signal intensity extends through the muscle layer into the perirectal fat, with obliteration of the interface between muscle and perirectal fat.
T4	Tumour signal intensity extends into an adjacent structure or viscus.

A T3 tumour is characterised by the muscularis propria being totally disrupted, with tumour invading through the muscular layer and into the perirectal fat. Early T3 tumours, T3a and T3b extend less than 1mm and 1-5mm beyond the border of the muscularis propria respectively. More advanced T3 tumours, T3c and T3d, extend 5-15mm or greater than 15mm beyond the muscularis propria, these tumours carry a far worse prognosis than T3a/T3b tumours and are associated with high rate of both local and systemic failure. The T3 subdivision is illustrated in figure 1.5. The subdivision matches the pathological subdivision of T3 tumours proposed by Herminak (Hermanek, Henson et al. 1993.).

Baseline T staging of rectal tumours using the MRI criteria above has shown good correlation with pathology. In a prospective study by Brown et al 98 patients undergoing surgical excision were assessed by preoperative high-resolution MRI for T N stage and depth of extramural tumour spread. The MR images were compared with histopathological findings by carefully matching whole-mount sections of the surgical specimen. Good agreement between pathology and MRI assessment of T-stage (weighted κ=0.67), as well as between MRI assessment of nodal status (weighted κ =0.68) was observed (Brown, Radcliffe et al. 2003).

Figure 1.5. Summary diagram of T staging

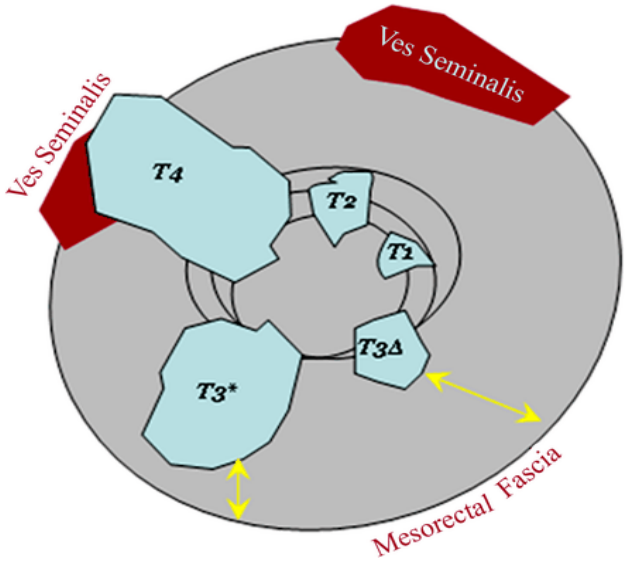

T1 - Tumour signal intensity confined to the submucosal layer.
T2 - Tumour signal intensity extends into the muscle layer.
T3 - Tumour signal extending beyond the muscularis propria.
T4 - Tumour signal extending through the peritoneum of into an adjacent organ.

Figure 1.6. T3a tumour

A) Thin section T2 weighted axial MR image shows a T3a rectal cancer, with extension of less than 1mm beyond the muscularis propria (curved arrow).
The invasive margin is at the 11'o'clock position.
B) Photograph of a section of the explanted rectum shows tumour invasion at the 11 'o' clock position (curved arrow).

A) B)

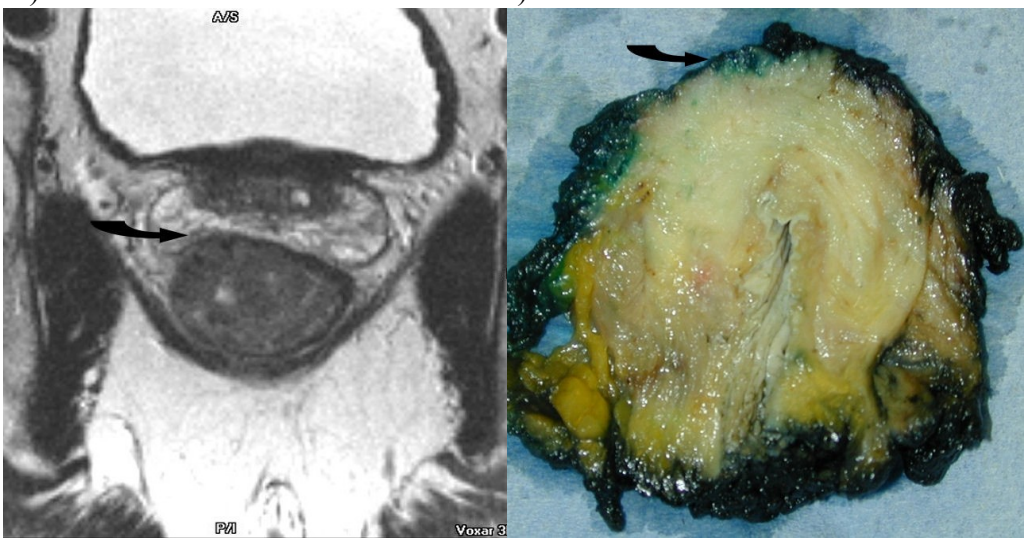

Figure 1.7. T3b tumour

A) Thin section T2 weighted axial MR image shows a T3b rectal cancer (curved arrow), with extension of approx 3mm beyond the muscularis propria.
B) The invasive margin is at the 4 'o'clock position. Photomicrograph (Original magnification X 0.4, haematoxylin-eosin (H-E) stain) shows tumour (curved arrow) extending beyond the muscularis propria (arrowheads).

A) B)

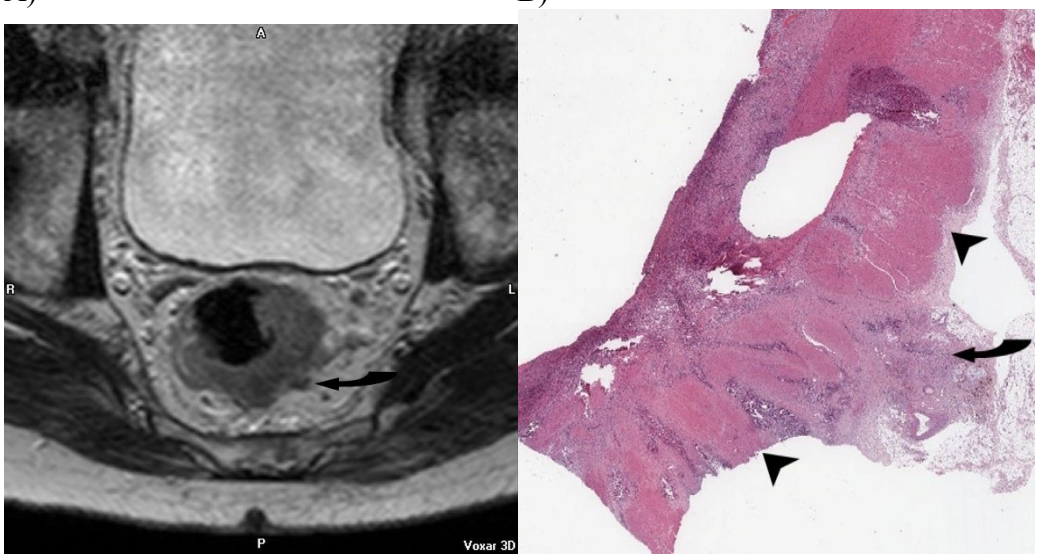

Figure 1.8. T3c tumour

Thin section T2 weighted axial MR image shows baseline images of a T3c rectal cancer with tumour invasion at the 6 'o'clock and 10 'o'clock positions (curved arrows).
There is 10 mm and of 8mm invasion from the muscularis propria respectively.



Figure 1.9. T3d tumour

A) Thin section T2 weighted axial MR image shows baseline image of a T3d rectal cancer with tumour invasion at the 7 'o'clock position (curved arrow). The arrowhead indicates the muscularis propria. There is greater than 15 mm of invasion beyond the muscularis propria. B) Photomicrograph (Original magnification X 0.4, haematoxylin-eosin (H-E) stain) shows tumour (arrow) extending beyond the muscularis propria (arrowheads).

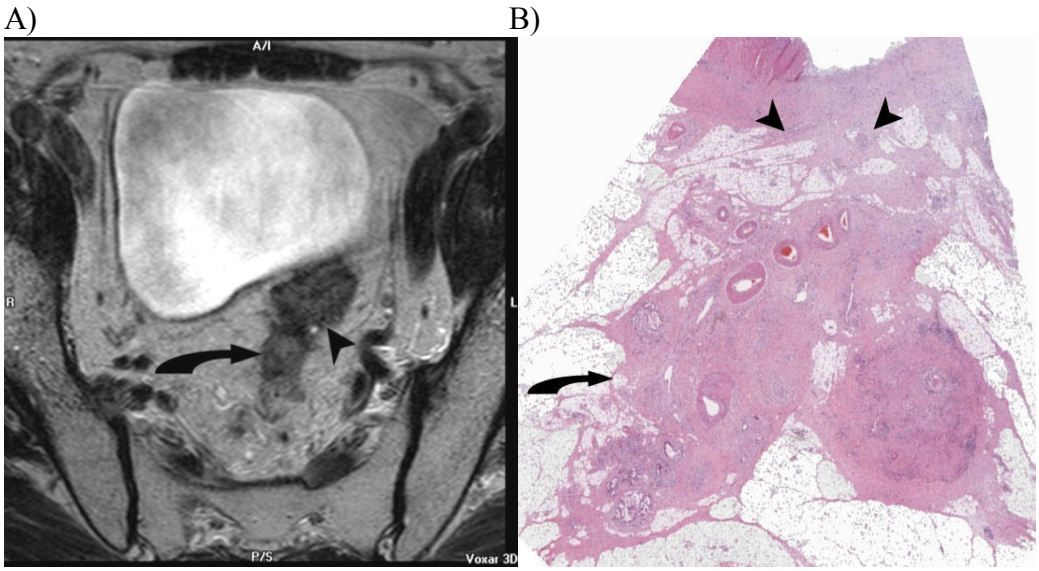

1.3.5 Tumour height and MRI assessment of the potential circumferential resection margin (CRM)

The mesorectum is a discrete anatomical unit composed of the rectum, perirectal fat, blood vessels, nerves and lymphatic vessels. A layer of fibroareolar tissue called the mesorectal fascia surrounds the mesorectum and forms the potential operative circumferential resection margin (CRM) (Heald 1988). On MRI imaging the CRM is a fine linear structure enveloping the mesorectal compartment harbouring the rectum and perirectal fat which appears hypointense on T2 weighted MR images.

Knowledge of tumour extension to the potential circumferential resection margin (CRM) is important as the multidisciplinary team may offer preoperative chemoradiation in an attempt to bring about tumour regression away from the margin. The plane of surgical excision may also be widened.

Studies have proposed different cut-off values for the distance of tumour to the mesorectal fascia which best predicts CRM status. Original studies suggested that CRM status could be predicted with a high degree of accuracy and consistency when a cut-off of 5mm measured distance to the CRM was used (Beets-Tan, Beets et al. 2001). Larger, more recent studies,

have shown a smaller distance. Brown et al's prospective study involving 98 patients undergoing pre-operative MRI staging, predicted positive CRM status when tumour was identified by MRI within 1mm of the mesorectal fascia. Comparison with histology showed excellent (92%, κ=0.81) agreement. (Brown, Radcliffe et al. 2003). Figure 1.4 shows a mucinous tumour with potential CRM involvement at 12'o' clock.

The height of a tumour is given using sagittal images, with the distance from the anal verge to the lower edge of the tumour recorded. The rectum is divided into low tumours (≤5cm from the anal verge) (figure 1.10), mid rectal tumours (5-10cm from the anal verge) and high tumours (10-15cm from the anal verge). The length of a tumour is also measured on sagittal images.

Assessment of tumour height is important as low rectal tumours lie below the puborectalis sling and at this level the total mesorectal excision plane is defined as the space between the muscle coat of the rectum becoming the internal sphincter and the fibres of the puborectalis sling which merge with the external sphincter fibres. Therefore at this level tumour invading the intersphincteric plane (figure 1.11) or extending to within 1mm of the levator muscle is considered to potentially involve the CRM (Shihab, Moran et al. 2009) (Figure 1.12).

Figure 1.10. Low rectal tumour

A) Axial T2 weighted MRI image at the level of puborectalis (arrowhead). A T1 tumour (arrow) is shown. The tumour is predominantly intramural with likely invasion of the submucosa.
B) Axial T2 weighted MRI post treatment. There is a low signal scar at the 12 'o'clock position (arrow), with normal submucosa seen. The puborectalis is indicated by arrowhead.

A) B)

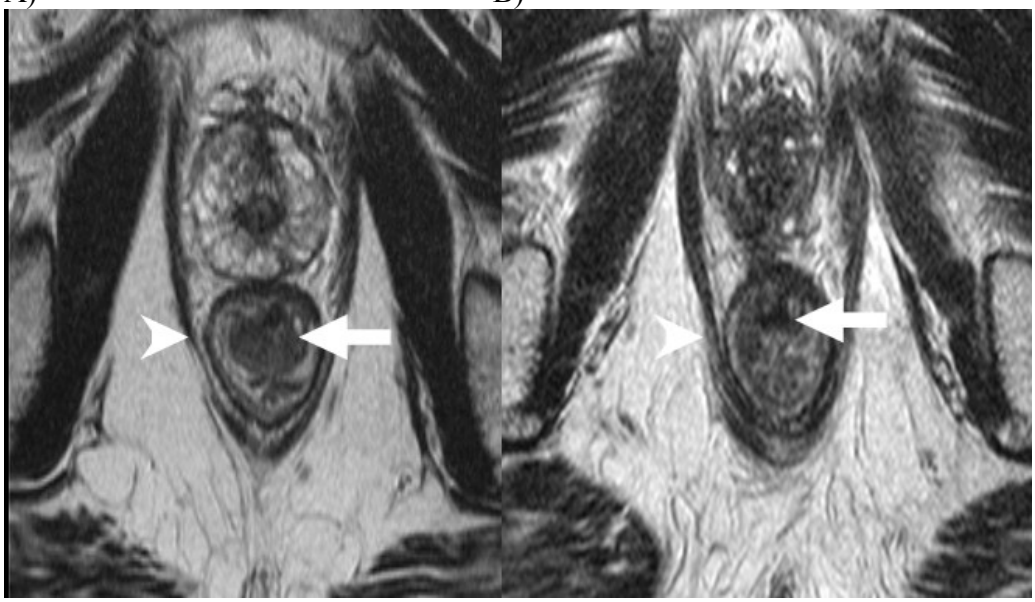

Figure 1.11. Low rectal tumour with potential resection margin involvement

A) Baseline Axial T2 weighted baseline MR image shows a semiannular infiltrating tumour between 7'o'clock-9'o'clock. The tumour extends extramurally (arrow) and extends up to the left levator muscle (arrowhead). The potential resection margin is therefore threatened.
B) Same patient as A, Baseline Coronal T2 weighted image shows extramural tumour extension (arrow) up to the left levator muscle (arrowhead).

A) B)

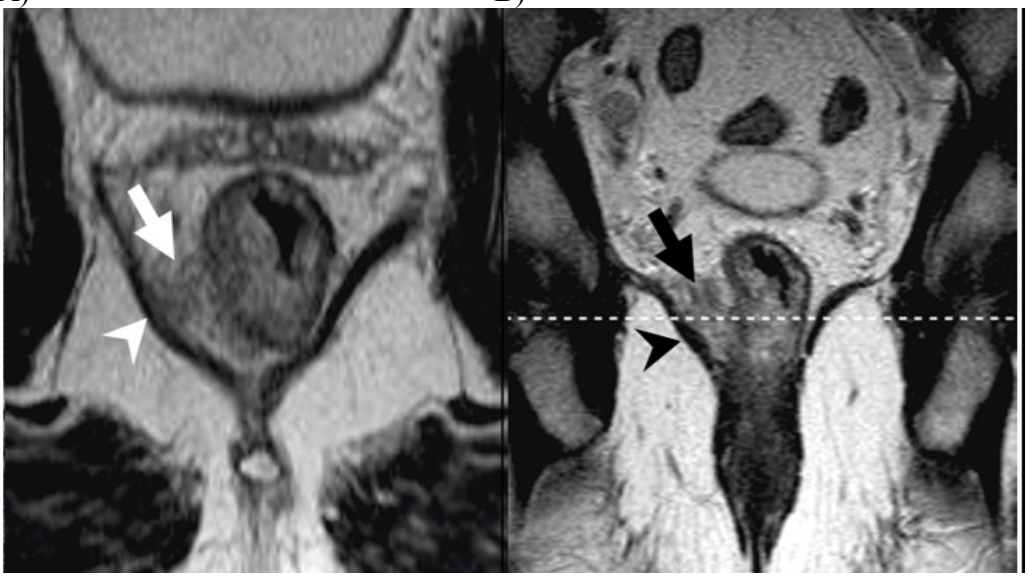

1.3.6 Peritoneal reflection involvement

The anterior wall of the upper rectum is covered by the peritoneal reflection. On sagittal MRI images the peritoneal reflection appears as a low signal intensity linear structure that extends over the surface of the bladder and can be traced posteriorly to its point of attachment onto the rectum. On axial images the peritoneum attaches in a V-shape onto the anterior aspect of the rectum. This appearance has been characterised as the "seagull" sign (Taylor, Swift et al. 2008).

The typical appearance of peritoneal reflection involvement on MRI is one of nodular intermediate signal intensity extending into the fine low signal intensity peritoneal reflection at or above the level of its attachment to the anterior rectum surface.(Smith, Barbachano et al. 2008). Such tumours are staged as T4a (figure 1.12).

Figure 1.12. Peritoneal infiltration

A) Axial T2 weighted MR images shows tumour (open arrow) demonstrated on the surface of the peritoneal attachment (white arrow)
B) Corresponding histological (H&E stained) wholemount section demonstrating tumour (open arrow), infiltrating the peritoneal reflection (not shown).

A) B)

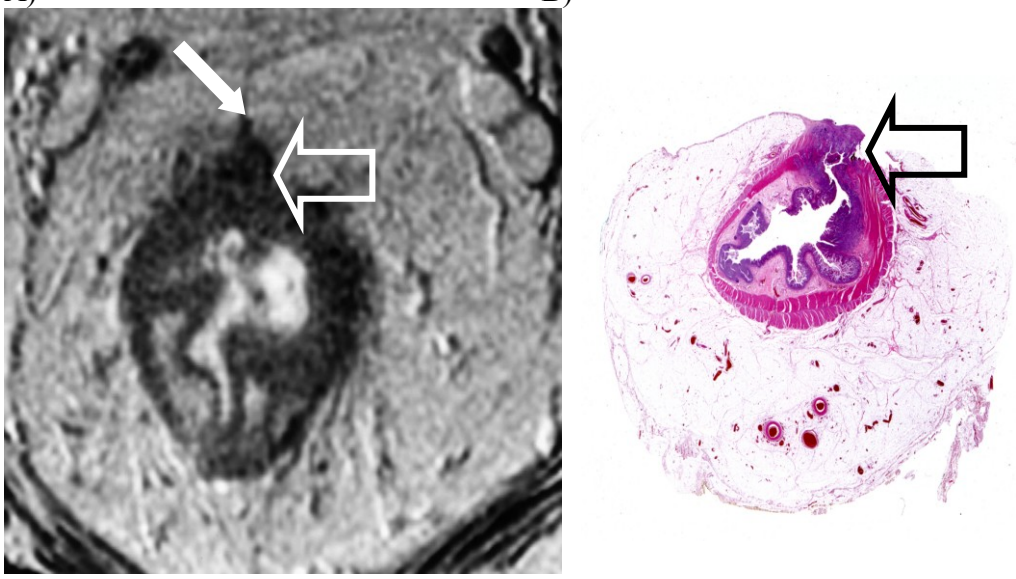

1.3.7 MRI assessment of lymph nodes

The identification of tumour infiltration into lymph nodes is important for two main reasons: Firstly, the number of involved lymph nodes at baseline predicts postoperative survival (Gunderson, Jessup et al. 2010). Secondly, defining an involved lymph node near the mesorectal fascia will often lead to change of treatment approach to ensure adequate tumour clearance. For example, the multidisciplinary team may offer neoadjuvant preoperative therapy to induce nodal regression or the standard potential circumferential resection plane could be altered.

The ability to predict lymph node status prior to surgery is a major challenge for radiologists as involved nodes may be normal sized and only contain microscopic tumour. Initial investigations focused on defining nodal size criteria with cut-off values for nodal positivity ranging from 3mm to 10 mm (Zerhouni, Rutter et al. 1996; Vogl, Pegios et al. 1997). More recent investigations have shown no particular size cut-off is useful in predicting nodal status. Brown et al carefully matched and compared the axial pre-operative MRI images with transversely sectioned histopathology specimens in an analysis of 437 lymph nodes harvested from 42 post operative specimens. This study showed the diameters of benign and malignant nodes were similar (Brown, Richards et al. 2003).

The same study also demonstrated that intranodal signal heterogeneity (mixed signal) was a highly specific discriminant and also reported a very high specificity (98%), and moderate sensitivity (75%) of lymph node border characteristics in MR images. Combining the two measures, with suspicious lymph nodes defined having an irregular border or mixed signal intensity (figure 1.13), greater accuracy was achieved, with sensitivity of 85% and specificity of 97% (Brown, Richards et al. 2003).

MR imaging using ultra-small particles of iron oxide (USPIO) contrast agent has shown promise in identifying very small (>1mm) tumour foci within lymph nodes. Following administration of USPIO malignant nodes (confirmed by pathological correlation) had an eccentric and uniform high signal intensity, while benign/ reactive nodes showed uniform or central low signal intensity patterns (Koh, Brown et al. 2004).

Figure 1.13. Morphological criteria for nodal assessment at MR imaging

A) T2-weighted MR imaging showing a node (circled) with irregular outline and heterogeneous signal intensity.
B) H&E histological slide confirms the lymph node is infiltrated by malignancy with extracapsular extension of disease.

A) B)

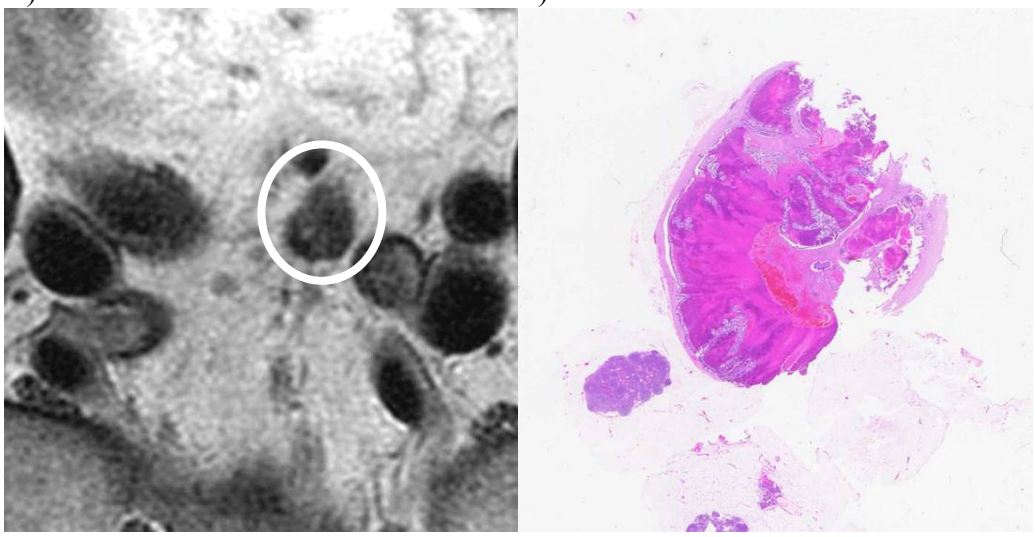

1.3.8 MRI assessment of extra mural venous invasion (EMVI)

Extramural venous invasion is defined by the presence of malignant cells within endothelial cell lined blood vessels beyond the muscularis propria. On T2 weighted MRI EMVI is characterised as causing expansion and irregularity of venules adjacent and contiguous to the primary tumour. A similar T2 signal intensity as the primary tumour is seen in the involved vessels (Brown, Radcliffe et al. 2003).

A recent EMVI scoring system has been developed, with 0, indicating no features suggestive of extramural vascular invasion and the maximum score of 4 assigned when overt features such as irregular vessel border are seen. The system predicts survival, with Smith et al's univariate analysis showing a 35% 3 year relapse free survival for patients with an MRI EMVI score of 3-4, compared with 74 per cent for those with a score of 0-2 ($p < 0.001$) (Smith, Barbachano et al. 2008).

1.4 Rectal cancer surgery

1.4.1 Total mesorectal excision

Total mesorectal excision (TME) involves sharp dissection along the plane that separates the visceral from the parietal layer of the perirectal pelvic fascia. This allows the radical removal of the rectum within the surrounding mesorectum (Heald, Husband et al. 1982).

Mid to low rectal tumours undergo total mesorectal excision with division of the rectum within centimetres of the anal canal. After the rectum has been removed circular staples are used to anastomose the anus to the sigmoid. Very low resections with primary anastomosis are generally covered by a defunctioning loop ileostomy or colostomy. The surgery enables en bloc removal of rectum and its draining lymph nodes while enabling anal sphincter and autonomic nerve preservation.

Given most rectal tumours are limited to within the mesorectal 'packet', the rate of CRM positivity and local recurrence is much lower when TME is performed. However, if tumour grows up to or through the mesorectal fascia the CRM may still be positive. Therefore the significance of CRM status as a prognostic factor is not diminished by TME.

1.4.2 Abdominoperineal excision

Abdominoperineal excision is used for very low rectal cancers when the distal resection is insufficient to allow re-anastomosis. The same dissection in the mesorectal plane is performed from above with perineal dissection (excision of the anus) being carried out from below. A permanent end colostomy is created in the left iliac fossa from the proximal sigmoid colon. Recent muscle flap techniques using gluteal, gracilis and vertical rectus abdominis flaps have improved perineal wound healing rates when compared with primary closure of the perineal wound (Palmer, Vernon et al. 1983; Chessin, Hartley et al. 2005).

1.4.3 Timing of surgery

The Lyon R90-01 trial compared surgery at 2 vs. 6 weeks post radiotherapy completion. The longer interval group (6 weeks) had better tumour response (53. 1% in the 2 week group vs. 71.7% in the 6 week group, p=0.007) and pathological downstaging (10.3% in the 2 week group v 26% in the 6 week group, p=0.005)

As a consequence, surgery at 6 weeks after completion of radiotherapy has become the standard of care (Francois, Nemoz et al. 1999). Extending the interval to surgery beyond 6 weeks has been speculated to increase the proportion of tumours downstaged by preoperative treatment, and is the subject of debate (Evans, Tait et al. 2011).

1.5 Neo Adjuvant treatment

1.5.1 Importance of local recurrence

Patients with rectal cancer have a relatively poor survival when compared to those with colonic tumours. This has been attributed to both metastatic disease and the increased tendency for local recurrence. In the 1970-1980s the rate of recurrent disease in the surgical bed or in adjacent pelvic organs was as high as 25-40%. (Chung, Stryker et al. 1983). The incidence of local recurrence in more recent trials is far lower (5-15% in the Swedish rectal cancer trial). This is due to improved surgical techniques such as TME and targeted radiation/chemoradiation to reduce local recurrence (Swedish Rectal Cancer Trial 1997).

1.5.2 Pre versus Post operative treatment

Radiation therapy seeks to eradicate peripheral microscopic tumour foci in the peritumoural tissue. The addition of chemotherapeutic agents such as fluorouracil and leukovuerin to preoperative radiotherapy has been shown to increase the proportion of tumours downstaged, as well as reduce local recurrence rates (Gerard, Conroy et al. 2006). Current British Medical Journal guidelines recommend Fluorouracil / Fluorouracil and Folinic acid / Capecitabine (BMJGuidelines 2012)

An important study Sauer et al randomised patients with locally advanced (T3/greater and/or Node positive) rectal cancer between pre and post operative chemo-radiotherapy. Improved local control and decreased toxicity was found in the preoperative chemo-radiotherapy group, but no survival difference was seen (Sauer, Becker et al. 2004). Therefore preoperative treatment is used in most centres in preference to postoperative therapy.

1.5.3 Selection of patients for neoadjuvant treatment

1.5.3.1 Surveillance, Epidemiology, and End Results (SEER) data

Many centres in the United States offer preoperative CRT to patients with T3 or Node positive disease (i.e. AJCC stage II and III disease). This approach is based on SEER data detailing decreased overall survival with increasing T stage and nodal stage; T stage results; 5 year OS: T2N0, 78% vs. T3N0 64%; N stage results; 5 year OS T3N0, 64% vs. T3N1, 52.4% vs. T3N2, 37.5% (Gunderson, Jessup et al. 2010). MRI based staging is not widespread in the USA, with many centres preferring a combination of endoscopic ultrasound and clinical assessment.

1.5.3.1 MRI based selection –Poor prognosis tumours

MRI staging has enabled the development of criteria for pre-operative therapy based on imaging findings. An example of selection criteria for poor prognosis tumours is found in the recent UK based EXPERTc trial (Comparing Oxaliplatin (Eloxatin), Capecitabine (Xeloda) and pre-operative radiotherapy with or without Cetuximab followed by total mesorectal excision). The MRI based inclusion criteria was: CRM involved or threatened, T3 low lying tumour at or below the levators (i.e. low rectal tumours, where the resection margin is closer to the rectum), tumour extending 5 mm or more into perirectal fat (T3c or above), tumour invading surrounding structures or peritoneum (T4), and T1-4 N2 tumours (Chau, Brown et al 2006).

1.5.3.1 MRI based selection –Intermediate prognosis tumours

Intermediate tumours do not show potential CRM involvement on baseline MRI, several other parameters are used to define this group. Parameters include the presence of extramural venous invasion (3 year relapse-free survival, 35% vs. 74.1%; $p< 0.001$), as well as extramural spread of tumour beyond 5 mm (5 year disease specific survival, 54.1% vs. 85.4%; $p< 0.0001$) (Smith, Barbachano et al. 2008). In the United Kingdom The National Institute of Clinical Excellence has suggested >T3b / Nodal involvement / Vascular invasion as criteria for intermediate prognosis, see Table 1.5 (NICE 2011).

1.5.4 Short course radiation Vs. Long course chemoradiation

While few would disagree with maximal preoperative long course chemoradiation therapy for tumours invading local structures and most consider neoadjuvant therapy unnecessary for very early T1 or T2 cancers, there is considerable variation in treatments offered to intermediate prognosis patients.

In general, intermediate risk rectal cancer patients are offered either preoperative short course radiotherapy or long course chemoradiotherapy (CRT) followed by TME surgery. Short course radiotherapy uses 25 Gy in 5 fractions while long-course treatment uses a higher dose of 50.4 Gy in 28 fractions and is combined with chemotherapy. Both long course chemoradiation and short-course radiotherapy has been shown to reduce local recurrence versus surgery alone (Kapiteijn, Marijnen et al. 2001; Sauer, Becker et al. 2004).

The choice between preoperative CRT and short course radiation is a subject of debate. Two randomised studies have compared preoperative CRT with preoperative short course radiation using the inclusion criteria of T3 or node positive disease. Bujko et al randomised 316 patients with adenocarcinomas above the anorectal ring. Over a median follow-up of 48 months no significant differences in local control or survival were observed (Bujko, Nowacki et al. 2006). Similarly, Ngan et al randomised 326 patients with T3 any N rectal cancer to short course versus CRT. Again no significant differences in 3 year local recurrence (8% vs. 4%) or 5 year survival (74% vs. 70%) were seen (Ngan 2010). Sphincter function results were not presented in either trial.

Interim results from the ongoing Stockholm III trial are similar, with no significant difference between pathological response rates between short course radiotherapy with surgery after 4-8 weeks and long-course radiotherapy with surgery after 4-8 weeks. The full results of this study are awaited (Pettersson, Cedermark et al. 2010).

The data has lead to some UK, Northern European and Scandinavian centres using short course treatment for intermediate risk rectal cancer patients. For example, the UK NICE guidelines recommend short course treatment in intermediate risk rectal cancer, but long course treatment in those with intermediate/high risk tumours (NICE 2011). However, many centres in the United States use CRT, as short course treatment "cannot be safely combined with adequate doses of systemic concurrent chemotherapy, and, as currently designed, it does not increase sphincter preservation." (Minsky 2011).

Table 1.5. Treatment of rectal tumours, NICE guidelines (NICE 2011)

Prognosis	Characteristics of rectal tumours predicted by MRI	Treatment recommendations
Poor prognosis. High risk of local recurrence.	A threatened (< 1 mm) or breached resection margin **or** Low tumours encroaching onto the inter-sphincteric plane **or** with levator involvement	Offer preoperative chemoradiotherapy with an interval before surgery to allow tumour response and shrinkage (rather than short course radiotherapy), to patients with high-risk operable rectal cancer.
Intermediate Prognosis. Moderate risk of local recurrence.	Any T3b or greater, in which the potential surgical margin is not threatened **or** Any suspicious lymph node not threatening the surgical resection margin **or** The presence of extramural vascular invasion	Consider Short Course Preoperative Radiotherapy then immediate surgery for patients with moderate-risk operable rectal cancer. Consider preoperative chemoradiotherapy with an interval to allow tumour response and shrinkage before surgery for patients with tumours that are borderline between intermediate and poor prognosis.
Good prognosis. Low risk of local recurrence.	T1 or T2 or T3a **and** No lymph node involvement	Do not offer short-course preoperative radiotherapy or chemoradiotherapy to unless as part of a clinical trial.

1.5.5 "Good" prognosis tumours

"Good" rectal tumours have very low local recurrence rates and high cure rates after TME surgery. A recent analysis of patients treated by TME surgery classified good prognosis tumours as T1-T3b, irrespective of nodal status. Such patients had a 5 year overall survival of 68%, disease free survival of 85% and local recurrence rate of 3% (Taylor, Quirke et al. 2011). NICE has adopted a more selective definition of T1-T3a with no lymph node involvement.

Experimental treatments for early stage tumours are aimed at rectum preservation with subsequent improved quality of life. Such treatments include transanal local excision and transanal endoscopic microsurgery (TEM) with or without preceding chemoradiotherapy (Zeestraten, Kuppen et al. 2012). In TEM surgery, the margin of excision around the tumour is marked using cautery, the lesion excised and the wound sutured. Most local excision procedures are carried out on tumours <3 cm in diameter, involving <30% of the bowel circumference and histologically moderately or well differentiated.

A meta-analysis conducted in 2011 of the available trials suggests TEM has fewer complications but a higher local recurrence rate (12%) compared with standard surgery (0.5%) with no difference in survival advantage (Wu, Wu et al. 2011). The local failure rate for TEM is likely to be due to false negatives from both MRI and endoscope ultrasound in the identification of involved mesorectal lymph nodes. Furthermore endoscopic ultrasound evaluation of tumour invasion depth in villous lesions has been reported at 60% due to difficultly in assessment of large villous lesions (≥20 mm wide, ≥5 mm high) (Konishi, Akita et al. 2003). Therefore, at present TEMS surgery is considered if the patient is unfit for TME surgery or chooses TEMS while understanding the risks of recurrence (BMJGuidelines 2012).

Several pathological studies have shown pT1 and pT2 tumours which show deeper invasion into the submucosa (SM3), lymphovascular invasion (Nascimbeni, Burgart et al. 2002) or poor differentiation carry a significantly greater rate of lymph node involvement (Tominaga, Nakanishi et al. 2005). Therefore if post procedure pathology shows a poorly differentiated tumour/lymphovascular invasion or tumour 1mm from the margin (i.e. pT2 tumour) then further surgery/radiotherapy/CRT is necessary.

A further alternative approach for this group of patients is to perform a local excision intended as a "full-thickness excisional biopsy," which allows complete pathologic examination of the entire specimen. If histological findings are favourable (low risk T1), close observation by endoscopy and endorectal ultrasonography can be offered, while a deeper stage or any unfavourable pathologic features (high risk T1), could prompt radical resection, or neoadjuvant CRT (Pricolo 2011).

1.5.6 Adjuvant chemotherapy

Current UK guidelines recommend patients with high risk stage II disease (presence of T4 disease, high grade tumour or extramural vascular invasion) and all stage III disease (T1-4 N1/2 M0) are offered adjuvant chemotherapy. This approach is based on studies such as the QUASAR trial, which showed a small significant 5 yr survival benefit of 3–4% for those patients with pathological stage II (T1-4 N0) rectal cancer treated with adjuvant 5-FU-based chemotherapy (Gray, Barnwell et al. 2007). A recent Cochrane meta-analysis of 21 randomised controlled trials comparing patients receiving adjuvant chemotherapy (n=4854) to those observed (n=4367) supported the use of 5-FU based postoperative adjuvant chemotherapy. A significant reduction in the risk of death (17%) among patients undergoing postoperative chemotherapy as compared to those undergoing observation was found (HR=0.83, CI: 0.76-0.91) (Petersen, Harling et al. 2012).

Chemotherapy options include fluorouracil/folinic acid/ FOLFOX 4 (Oxaliplatin, Folinic acid, bolus Fluorouracil) /Capecitabine. The use of FOLFOX 4 and Capecitabine in this setting is based on extrapolation of data from colon cancer studies (BMJGuidelines 2012).

1.5.7 Patient selection for neoadjuvant treatment in The Royal Marsden Network

The treatment algorithm presented in figure 1.14 is the current the standard of care in The Royal Marsden cancer network. This algorithm classifies patients according to the presence of four factors on baseline staging MRI: the extent of extramural spread of tumour, the relation to the mesorectal fascia, the presence of 4 or more lymph nodes and the presence of extramural vascular invasion. The inclusion criteria used for preoperative treatment in the 4 studies used in this thesis vary and are detailed in the relevant chapter.

Figure 1.14. Selection of patients for neoadjuvant treatment at The Royal Marsden Colorectal network

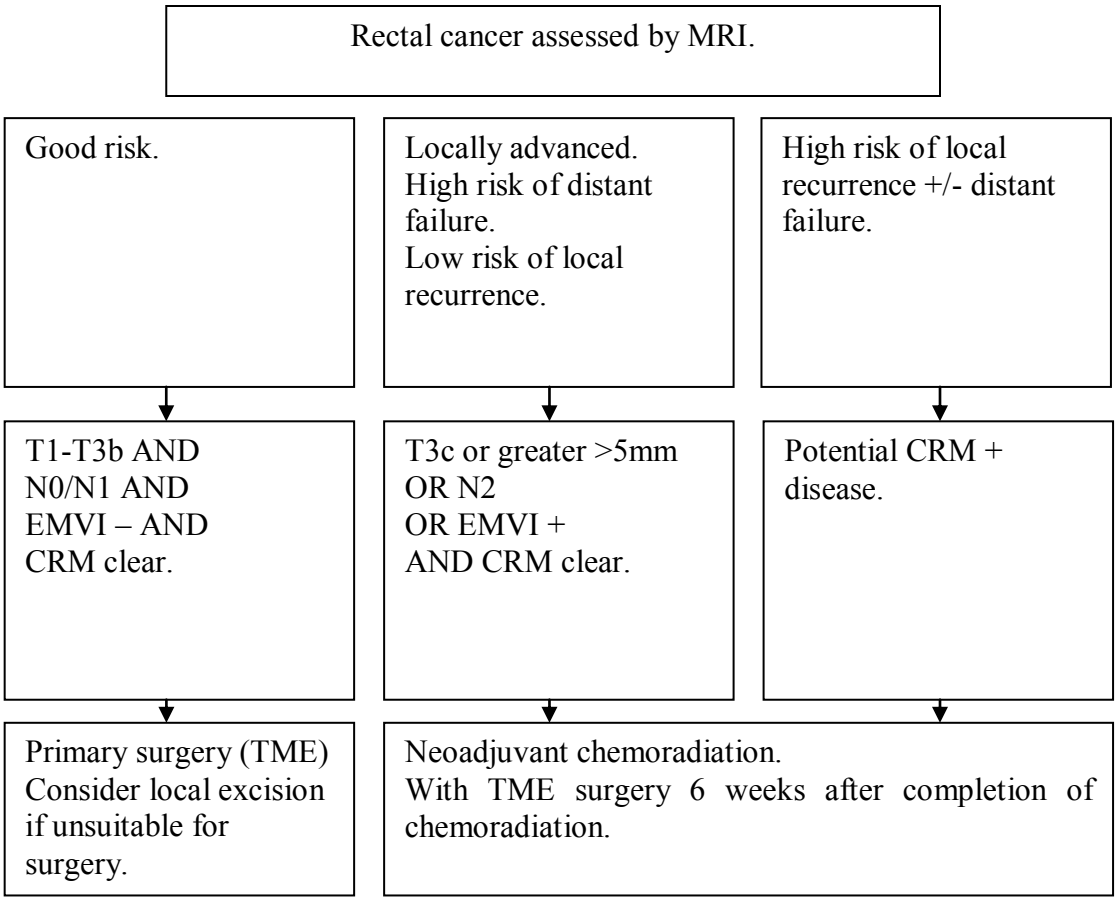

Adjuvant chemotherapy if pathological stage III or high risk selected stage II patients.

1.5.8 Neoadjuvant chemotherapy prior to chemoradiation

There are several potential uses for neoadjuvant chemotherapy in the treatment of rectal cancer.

The first approach is neoadjuvant chemotherapy pre/post chemoradiation. A recent systematic review included 16 studies using chemotherapy as induction to CRT and 5 studies investigating chemotherapy post CRT as consolidation. The addition of neoadjuvant chemotherapy as induction to chemoradiation did not appear to increase pathological complete response rate, or negative pathological CRM rates (Glynne-Jones, Anyamene et al. 2012). However, in some of the included studies rates of grade 3 or 4 toxicity were significantly different (19% induction arm vs. 54% adjuvant arm, p= 0.0004) (Fernandez-Martos, Pericay et al. 2010). Therefore neoadjuvant chemotherapy appears

better tolerated than adjuvant treatment and may improve upon the moderate levels of compliance observed to adjuvant chemotherapy (Fernandez-Martos, Pericay et al. 2010).

Few studies to date have used imaging to evaluate response to induction neoadjuvant chemotherapy regimes. Measuring MRI length change, using RECIST (Response Evaluation Criteria In Solid Tumours) criteria Chau et al observed radiological response in 60/68 patients (88%) (Chau, Allen et al. 2003). A smaller study of 10 patients showed that all patients responded to induction chemotherapy MRI volume reduction criteria (Seierstad, Hole et al. 2009).

There is increasing interest in the use of neoadjuvant chemotherapy for the treatment of a subgroup of MRI defined 'intermediate risk' patients, which have a high risk of distant metastatic relapse but a low risk of local recurrence as the CRM is not threatened (Hunter, Garant et al. 2012). The use of chemotherapy at systemically effective doses may improve survival in this subgroup of patients as neoadjuvant chemotherapy theoretically allows early treatment of micrometastases and enables delivery of chemotherapy at full systemic doses. There are few trials in this area but "Overall, there appears to be sufficient preliminary evidence to support the view that in less locally advanced patients selected by initial MRI, the role of neoadjuvant chemotherapy alone, without radiation, should be evaluated" (Glynne-Jones, Anyamene et al. 2012).

Which of the available MRI imaging assessment methods can identify good versus poor responders to neoadjuvant chemotherapy compared with histopathological reference standards is presently unknown. The ability of MRI to select intermediate risk patients is also uncertain.

1.6 Pathological restaging of rectal cancer post chemoradiation

1.6.1 Morphological changes post chemoradiation

Surgical specimens post chemoradiation show; collagen, desmoplasia, fibrosis, inflammatory change as well as submucosal oedema, mucin and necrosis.

Fibrotic stroma consists of matrix components such as collagen as well as cells responsible for matrix production such as fibroblasts and histiocytes (Knutsen, Adell et al. 2006). Fine and elongated collagen fibres stratified into layers makes up mature fibrotic stroma while immature fibrotic stroma consists of randomly orientated collagen bundles (Ueno, Jones et al. 2004).

Desmoplastic reaction is also called reactive fibrosis. Pathologically this process involves the deposition of collagen as a stromal response, anatomical distortion may result. Mature desmoplastic reaction does not contain tumour (Puppa, Sonzogni et al. 2010).

As well as residual mucin producing tumour cells, the presence of acellular mucinous lakes has been reported in 20-55% of patients post chemoradiation. Shia et al analysed the pattern and significance of mucin pools in 108 consecutive, prospectively collected resection specimens from patients with rectal cancer treated with preoperative long course CRT. Mucin pools were identified in 33/108 specimens; in 16/108 they were acellular. The presence of mucin pools had no impact on 3 year recurrence free survival (Shia, McManus et al. 2011). Therefore pathologists do not upstage tumours due to mucinous degeneration (Nagtegaal 2008).

1.6.2 Pathological T stage post chemoradiation (ypT)

T staging post chemoradiation has been shown to predict outcome. For example Kim et al retrospectively reviewed 114 patients who had undergone neoadjuvant chemoradiation for advanced rectal cancer (T3 or T4 and node positive) using TMN 6 criteria. This study showed 5 year survival rates according to pathologic stage were: 100% in pathologic complete remission (n = 10), 80% in stage I (n = 23), 56.8% in stage II (n = 34), and 42.3% in stage III (n = 47) (p= 0.00001) (Kim, Baik et al. 2006). Other groups have shown similar results (Janjan, Crane et al. 2001; Theodoropoulos, Wise et al. 2002).

Applying T stage criteria to post treatment specimens has been noted by several authors to lead to difficulty in assessment of residual tumour (Puppa, Sonzogni et al. 2010). There is uncertainty how small microfoci of tumour post chemoradiation should be recorded. Some groups have suggested such foci with a smooth contour should be considered as lymph nodes as the TNM 6 criteria. However other pathologists believe such rules should not be applied post CRT and the presence of microfoci should be recorded in ypT stage rather than ypN stage. (Quirke, Williams et al. 2007). This is a similar discussion as the classification of extramural tumour deposits discussed in 1.2.6.

It is important to note that the current TNM 7th edition states in its supplement booklet that only viable tumour cells should be used for TN staging purposes. Findings of regressed

tumour tissue such as scars, fibrosis and mucin lakes in either intestinal wall, perivisceral fat, or regional lymph nodes are not recorded (Sobin and Wittekind 2009) . This view has changed since 2nd edition of the TNM Supplement, where "ypTNM considered not only viable tumour cells but also signs of regressed tumour tissue such as scars, fibrotic areas, fibrotic nodules, granulation tissue, mucin lakes (Wittekind, Henson et al. 2002)."

1.6.3 Definition of tumour stages – Pathological complete response

Pathological complete response (pCR) has been used as an endpoint in many clinical trials investigating chemotherapy regimes in rectal cancer. Approximately 10–20% of patients are downstaged to pCR in most trials (Hartley, Ho et al. 2005). There has been some confusion as to what constitutes a pCR: ypT0 alone or ypT0 plus ypN0. This is important as lymph node metastasis are found in 7.1% of ypT0 cases. Most current trials use ypT0N0 to define complete pathological response (Nagtegaal 2008).

Patients with pCR group have been shown to have a survival advantage in several clinical trials. For example Capirici et al reported a retrospective review of 566 patients treated at multiple European centres who achieved a pCR after receiving a variety of long course CRT regimens. With a median follow-up of 46 months, the local recurrence rate was only 1.6%, and the 5 year disease free and overall survival rates were 85% and 90% respectively (Capirci, Valentini et al. 2008).

1.6.4 Pathological Tumour regression grading

Some pathologists believe "T-downstaging" does not entirely reflect cancer regression following neo-adjuvant therapy as, for example, a small focus of residual extramural tumour surrounded by fibrous tissue is classified as a T3 tumour despite a good response. Pathological TRG systems have been developed to overcome this issue. Dworak et al reviewed 17 surgical specimens post CRT and described varying degrees of replacement of tumour with fibrous or fibroinflammatory tissue. The degree of fibrosis versus degree of residual tumour is used as the basis for the Dworak tumour regression system (Dworak, Keilholz et al. 1997) as well as the modified Mandard tumour regression system used in oesophageal cancer (Mandard, Dalibard et al. 1994). Such systems provide information about the grade of tumour regression/ response to chemoradiation which is not readily available from T staging (figure 1.15).

The usefulness of Dworak system was investigated by Rodel et al, in 385 patients, it was found that complete and intermediate tumour regression response had improved disease free survival after preoperative CRT compared to poor response (Rodel, Martus et al. 2005).

However pathological TRG has several limitations;

As the definition of each grade is subjective, this leads to a lack of reproducibility as reported by Nagtegaal (Nagtegaal 2008). A more quantitative definition to include the percentage of regression cannot be employed as there is no baseline pathology.

Simplified TRG systems with three or four grades have also been employed and have different cutoffs between favourable and unfavourable groups, however, there is no accepted cutoff. The lack of an accepted classification system has resulted in the studies investigating correlation between pathological TRG and survival grouping tumour regression grades differently. For example Rodel et al showed 63% disease free survival for TRG0+1, 75% DFS for intermediate TRG groups 2+3 and 86% DFS for favourable TRG 4, while Suarez reported 74% DFS for TRG 1+2 and 100% DFS for TRG 3+4+5 (Rodel, Martus et al. 2005; Suarez, Vera et al. 2008). Importantly both these studies showed TRG to be a significant prognostic factor on univariate analysis, and as Chetty et al recently noted TRG "has not been established to be an independent prognostic value that is superior to ypTNM in predicting clinical outcome" (Chetty, Gill et al. 2012).

1.6.5 Pathological lymph node assessment post chemoradiation

Studies have shown the presence of lymph node metastases after neoadjuvant therapy is a major prognostic factor (Lee, Jang et al. 2012). However, areas of discussion remain; TNM criteria considers 12 lymph nodes an adequate pathological sample for assessment. However several large studies have found that such numbers of lymph nodes are often not obtained post chemoradiation, with mean numbers of lymph nodes reported as 7, 8.4 and 10.8. It is not clear if the minimum acceptable harvest of 12 lymph nodes still applies to these cases, with some authors currently advocating that if no positive nodes are identified in a lower yield post chemoradiation sample, a stage of N0 is reported (Nagtegaal 2008).

A further issue to consider is that neoadjuvant therapy is likely sterilise a number of initially positive nodes. Therefore ypN0 is a heterogeneous group of patients with initially node-negative disease and patients with sterilised metastatic nodal deposits. It is uncertain if this is of significance.(Puppa, Sonzogni et al. 2010; Marzouk O. 2011).

Figure 1.15. Pathological Tumour regression grading

A) TRG 4. Total regression. No viable tumour cells, only fibrotic mass.
B) TRG 3.Very few, difficult to find microscopically, tumour cells in fibrotic tissue with or without mucus substance.
C) TRG 2. Dominant fibrotic changes with few tumour cells (easy to find).
D) TRG 1. Dominant tumour with obvious fibrosis.
TRG 0. Complete tumour, No regression. (Not illustrated).

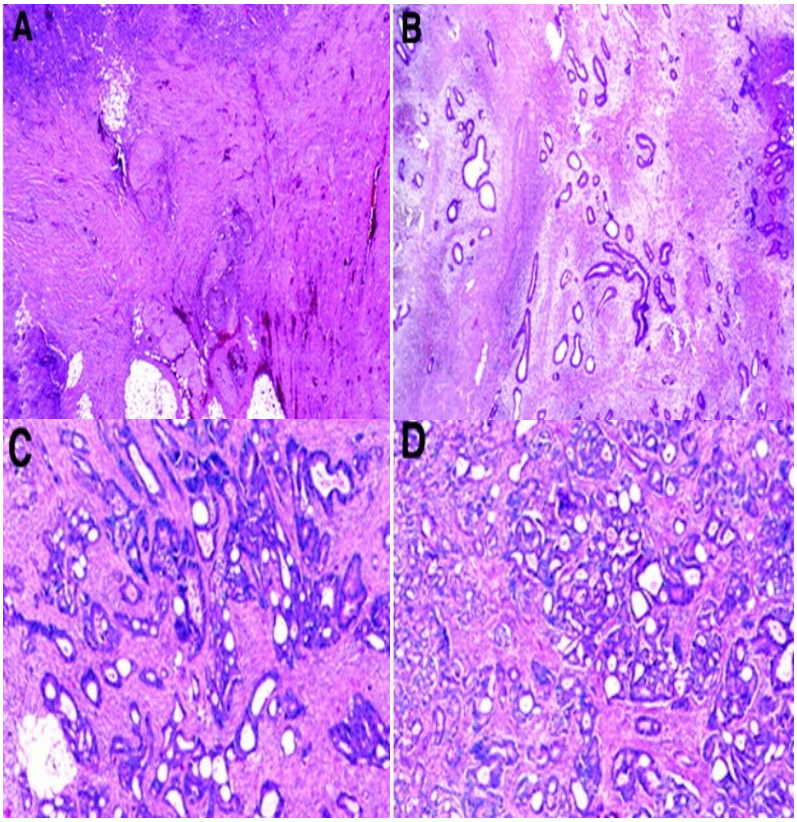

1.6.6 Pathological CRM assessment post chemoradiation

The same criteria are applied to CRM assessment regardless of whether the patient has undergone neoadjuvant treatment. Microscopic tumour foci within 1mm of the CRM is regarded as a R1 margin and macroscopic tumour within 1mm of the CRM regarded as an R2 resection (Puppa, Sonzogni et al. 2010).

CRM is an important post treatment prognostic factor, with a recent review of data from 17,500 patients demonstrating that the prognostic value of an involved CRM for local recurrence is stronger for those patients undergoing neoadjuvant therapy compared to patients treated with surgery alone (HR=6.3; 95% CI, 3.6-16.7 Vs HR=2.2; 95% CI, 1.5-3.2) (Nagtegaal, Gosens et al. 2007).

1.6.7 Summary

Histopathologists grade tumour response in three ways: firstly assessment of the status of the circumferential resection margin (CRM), secondly, the depth of tumour spread and nodal status (ypT and ypN stage) and thirdly by evaluating tumour regression grade (pTRG) (Kapiteijn, Marijnen et al. 2001; Sauer, Becker et al. 2004; O'Neill, Brown et al. 2007; Guillem, Diaz-Gonzalez et al. 2008; Suarez, Vera et al. 2008).

A number of studies have shown that both ypT, ypN and pCRM stage are independent predictors for outcome and in several retrospective studies a link between outcome and histopathology assessment of tumour regression after CRT has been shown (Theodoropoulos, Wise et al. 2002; Valentini, Coco et al. 2002; Kuo, Liu et al. 2007).

1.7 MRI Restaging post chemoradiation

1.7.1 T stage on MRI post chemoradiation

The first study to conduct MR imaging in patients with rectal carcinoma treated with radiation was undertaken by Sugimura et al in 1990. Ten of the 51 patients irradiated in this study had rectal and anal carcinoma, remaining patients had malignancies of other pelvic organs. Pathological correlation was available in 16/51 cases. The imaging appearances of the rectal tumours post chemoradiation was not fully commented on, however difficulties in the interpretation of post chemoradiation images was noted; for example in 1 patient imaging demonstrated extensive submucosal thickening and increase in the muscularis signal intensity, which was interpreted as post radiation change, but an invasive rectal tumour was found pathologically (Sugimura, Carrington et al. 1990).

In 1991 de Lange et al further evaluated the role of MR imaging in assessing the effect of preoperative irradiation in 11 patients with primary rectal carcinoma. Findings on MR images obtained at baseline and 5-6 weeks post treatment were correlated with histopathological findings (9 patients) or findings at laparotomy (2 patients). The study reported a relatively low incidence of tumour downstaging on MRI, with no change in the MR tumour stage in 9 of the 11 patients. There was agreement between MR T stage and subsequent pathology in 9/11 cases, with 1 patient overstaged and 1 patient understaged. Difficulties in interpreting post CRT MR images was noted, with extensive streaks of tissue from the bowel wall into the perirectal fat interpreted as tumour invasion on MR, but found to be linear areas of fibrous tissue/ desmoplastic reaction pathologically (de Lange, Fechner et al. 1992)

The correlation between MR imaging in advanced rectal carcinoma after preoperative radiotherapy and histopathology was investigated in a larger series of 35 patients by Hoffman et al. Post CRT MRI and pathological T stage matched in 19/35 patients, leading to the conclusion that "MRI proved independent of response status and is not suitable to restage locally advanced rectal carcinoma after preoperative radio chemotherapy" (Hoffmann, Rau et al. 2002).

Subsequent trials in 2005 by Kuo et al (n=36) and Chen et al (n=50) found MRI T stage had an accuracy of 47% and 52% respectively when compared to pathological T stage (Chen, Lee et al. 2005; Kuo, Chern et al. 2005). Allen et al recorded similar results, with, 18 of 30 (60%) tumours correctly T staged after treatment. Concordance between postchemoradiation therapy MRI T stage and histological T stage was fair to moderate (κ = 0.40; 95% CI, 0.10–0.66) (Allen, Padhani et al. 2007). The main reason given for the relatively poor accuracy was that MRI could not completely differentiate the changes of post chemoradiation fibrosis from residual tumour.

1.7.2 N stage on MRI post chemoradiation

As noted during pathological evaluation CRT often reduces the size and number of benign and malignant lymph nodes. Frequently nodal downstaging is accompanied by tumour downstaging, while malignant nodes are often identified in those with significant residual disease (Taylor, Swift et al. 2008).

As with baseline imaging determining a node to be benign or malignant uses morphological rather than size criteria, with a malignant node showing irregular outline or internal signal heterogeneity. High signal mucinous degeneration can also occur within lymph nodes and is a sign of treatment response (Koh, Chau et al. 2008). Using this criteria Koh et al (Koh, Chau et al. 2008) showed a 80% positive predictive value, 90% negative predictive value and 88% accuracy in detecting nodal disease after neoadjuvant treatment.

Several studies have shown that lymph node specific contrast agents such as ultra small super paramagnetic iron oxide particles may aid in the detection of small tumour deposits and lymph node characterisation (Koh, Brown et al. 2004). These particles are phagocytosed by nodal macrophages, producing susceptibility effects which result in signal loss in normal nodes on T2 weighted MR images. In nodes that are totally or partially replaced by tumour macrophage numbers are depleted and little susceptibility artifact and relatively high signal intensity are demonstrated. Nodal staging with ultra small super paramagnetic iron oxide particles has a sensitivity and specificity of approximately 95% for detecting malignant lymph nodes in patients with primary rectal cancer (Koh, Brown et al. 2004; Koh, Brown et al. 2006). However, there is limited commercial availability of ultra small super paramagnetic iron oxide particles with the application for marketing authorisation recently been withdrawn in Europe, and approval declined by the Food and Drug Administration in the United States (Magnetic Resonance Technology Information Portal2007).

1.7.3 Refinement of T and N restaging post chemoradiation

Brown et al have proposed refined criteria for interpretation of post treatment MRI.

In this study 78 patients with MRI defined locally advanced rectal cancer were treated with long course chemoradiation. Sixty four patients had an evaluable restaging MR imaging 4 weeks after completing CRT (Brown, Chau et al. 2003);

The following criteria were used for post treatment assessment:

1. Tumour- Persistent intermediate signal intensity was classified as indicating residual tumour following therapy. Intermediate signal was interpreted in relation to the bowel wall as well as mesorectal fascia for assessment of T stage and potential CRM involvement respectively. The potential CRM was considered involved on post treatment MRI if the shortest distance from the outermost part of the tumour to the adjacent mesorectal fascia was <1mm.

2. Mucinous tumour- Intermediate signal intensity foci seen within pools of much higher signal intensity material was classified as representing mucinous tumour. Regression of such intermediate areas post chemoradiation was classified as treatment response.

3. Treatment response- Low signal intensity of the muscularis propria with thickening of the muscularis propria was classified as representing fibrosis following tumour necrosis.

4. Treatment effects- Low signal intensity stranding was classified as desmoplastic changes following extramural tumour necrosis. As pathological desmoplastic reaction does not contain tumour, linear low signal spiculations seen on MRI were interpreted as desmoplastic reaction not containing tumour cells.

5. Lymph node assessment: A node was classified as malignant if it contained either mixed signal intensity or had an irregular contour as described by Koh et al (Koh, Chau et al. 2008).

Using this criteria favourable post treatment MRI T staging was 81% predictive of favourable T stage pathology, while an unfavourable MRI T stage was 90% predictive of an unfavourable pathological T stage. Post treatment MRI nodal positivity was 77% predictive of pathological nodal disease while post treatment node negativity was 73% predictive of pathological N0. MRI predicted post treatment CRM involvement correctly in 69% while MRI predicted a potentially clear CRM correctly in 73%.

Therefore, the definitions of residual tumour, treatment response and treatment effects used in this study show promise, but need further characterisation by for example matching imaging appearances to pathology.

Furthermore, The accuracy of the proposed refined system of T, N and CRM assessment have yet not been assessed against pathology or survival endpoints in multicentre multireader studies.

1.7.4 MRI Tumour regression grading

It has been noted that the TNM classification does not make allowances for microscopic foci of tumour cells within a stroma of extensive fibrosis and necrosis. Such patients are staged as pT3 despite only microscopic residual disease present and may not have the same prognosis as a large volume T3 tumour (Mehta, Johnson et al. 1994; Wheeler, Warren et al. 2002). Therefore, an alternative staging classification has been proposed that incorporates the initial MR imaging findings to give the true degree of downstaging in these patients (Brown, Chau et al. 2003). Such a classification is based on the degree of tumour and fibrosis on the post treatment MRI, with patients categorised in a similar way to the Dworak tumour regression grading system (Dworak, Keilholz et al. 1997). Importantly while Dworak TRG 2 is defined as dominant fibrotic changes with few tumour cells, the related MRI TRG grade 3 is defined as ~50% fibrosis/acellular mucin with remaining intermediate signal representing residual tumour.

MRI based tumour regression grading system proposes that firstly, the entire tumour is assessed to determine whether fibrous signal intensity or tumour signal intensity predominates. This requires a comparison of the high resolution oblique images with the baseline scans to determine the proportion of tumour that has become fibrotic low signal intensity/featureless high signal mucinous response and the proportion of remaining residual intermediate signal intensity. If there is a predominance of fibrosis/acellular mucin with no or minimal residual intermediate tumour signal this is classified as TRG 1 and 2 respectively. If there is substantial tumour signal present but this does not predominate the fibrosis/acellular mucin this is classified as TRG3. If there is a predominance of tumour with minimal low signal fibrosis/high signal mucin this is classified as TRG 4. If the tumour appears unchanged from baseline this is classed as TRG 5.

The accuracy of post chemoradiation MRI tumour regression system has not been assessed against histopathological or survival endpoints or compared against the existing standard of T staging.

Table 1.6. Tumour regression grading of rectal cancer on MR imaging

mrTRG grade	Response	Description
Grade 1.	Complete radiological response	Absence of any tumour signal.
Grade 2.	Good response.	Dense hypointense fibrosis/acellular mucin. Minimal residual tumour.
Grade 3.	Moderate response.	Mixed areas of low signal fibrosis and intermediate signal intensity present but without predominance of tumour
Grade 4.	Slight response.	Minimal fibrosis/acellular mucinous degeneration, mostly tumour.
Grade 5.	No response.	Tumour has same appearance as baseline.

1.7.5 Volumetric Analysis using MRI

MR volumetry performed before and after neoadjuvant chemoradiation has been investigated as a method of predicting treatment response. Torkzad et al selected a single axial slice where a tumour was at its largest dimensions and measured tumour width and thickness. Tumour length was then measured, defined as the distance between the extremes of the tumour in sagittal plane. Tumour volume was calculated by width multiplied by length and thickness of the tumour. Using this method tumour volume was calculated at baseline and post CRT. A statistically significant correlation was shown between percentage of residual tumour at second MR (tumour volume post CRT / tumour volume at baseline) and ypT. All ypT0-T1 cases had a residual volume of less than 44%, 5/7 ypT2 cases had a residual volume of less than 44%, while 11/14 ypT3-4 cases had a residual volume of greater than 44% (Torkzad, Lindholm et al. 2007).

1.7.6 MRI Length assessment /modified MRI RECIST

Change in tumour length on sagittal images has been investigated as a tool to evaluate tumour response to treatment. (Chau, Brown et al. 2006). At the time of starting this thesis, data from the EXPERT-C trial had shown a decrease in maximum tumour length between baseline and post treatment sagittal images. Favourable pathology (ypT0-2) outcome was seen in 35/67 patients post TME. Although the data correlating change in tumour length and pathology was not presented it appears a relationship may exist (Chau, Brown et al. 2006).

As yet no studies have compared the diagnostic accuracy of post chemoradiation volume reduction post treatment and modified RECIST length measurement with more established techniques such as T staging or other proposed approaches such as MRI tumour regression grading.

1.7.7 Diffusion weighted MR Imaging

1.7.7.1 Introduction to technique

Diffusion weighted imaging (DWI) explores the random motion of water molecules in the body. The degree of restriction of water diffusion in biologic tissue is inversely correlated to the tissue cellularity and the integrity of cell membranes. Therefore tissue contrast in DWI is derived from differences in the diffusion of water between tissues.

By applying a pair of strong magnetic field gradient pulses within the imaging sequence, imaging is sensitised to random spin displacements of diffusing free water molecules. The apparent diffusion coefficient (ADC) can be calculated from DWI measurements. The ADC is a measure of restriction to diffusion of molecules by structures such as cell membranes, allowing inferences to be made about microstructure of the cellular environment. Therefore, diffusion-weighted MRI has been suggested as a tool to distinguish different tissue compartments and to detect changes in cellular tissue structure, which could be used to monitor effects of radiation in tumour tissue (Koh and Padhani 2006)

1.7.7.2 Studies to date

The first study assessing the correlation of tumour ADC values with response to chemoradiation was carried out by Dzik-Jurasz et al in 2002. Tumour ADC values were measured before and after chemotherapy in 14 patients. Patients showing a greater than 50% reduction in tumour size between baseline and post treatment MR imaging were classified as responders (n=7), while non-responders (n=7) showed less than a 50% decrease. The ADC of responders fell after chemotherapy and increased after chemoradiation, while non-responders maintained a high ADC throughout treatment. A significant difference between mean ADC of responders and non-responders was shown before ($p=0.03$) and after chemotherapy ($p=0.03$), but not after the end of chemoradiation ($p=0.20$) (Dzik-Jurasz, Domenig et al. 2002).

Conversely a subsequent study by Kremser et al showed high ADC values in pathological responders, while lower ADC values are seen in pathological nonresponders. DWI was used in 8 patients with primary advanced rectal carcinoma undergoing preoperative chemoradiation. Mean tumour ADC values were determined weekly during therapy and correlated with pathology. In the four patients with T-downstaging (ypT0–2) there was a significant increase in ADC value during week 1 of therapy, followed by a steady decrease, while in four patients with no downstaging (ypT3) no initial increase of ADC values was observed (Kremser, Judmaier et al. 2003)

1.8 Clinical importance of MRI Restaging post chemoradiation

At present after CRT patients undergo surgery at a date determined at the beginning of each case, often without restaging imaging. Accurate preoperative assessment of response to therapy may permit the clinical teams to modify definitive treatment in different ways.

1.8.1 Good response

Histopathologists have reported no residual tumour is seen on pathological examination in up to 25% of patients, i.e. a complete response of a locally advanced tumour to neo-adjuvant CRT (O'Neill, Brown et al. 2007). There is potential for deferral of surgery in this subgroup of excellent responders to CRT. A landmark study in this area was carried out by Habr Gama et al. Two hundred and sixty five patients with distal rectal adenocarcinoma considered resectable were treated by neoadjuvant chemoradiation between 1991-2002. Complete clinical response was observed in 71 patients (26.8%) following chemoradiation (Observation group), 22 patients (8.3%) showed incomplete clinical response and subsequent pT0N0M0 pathology (Resection group). No difference was observed in the 5 year overall and disease free survival rates in these 2 groups (Resection Group, 5 yr OS and DFS; 88% and 83% respectively, Observation group, 5 yr OS and DFS; 100% and 92% respectively). Patients in this study were selected by digital rectal examination, pelvic CT and proctoscopy, the ability of MRI to select patients and monitor patients was not evaluated (Habr-Gama, Perez et al. 2004).

Habr Gama et al's group recently published updated results of their deferral of surgery cohort. Data from 173 patients recruited between 1991-2009 from one of the two original centres was presented. Trends from the original dataset have continued, with overall, 67 (39%) of patients developing complete clinical response. Sigmoidoscopy was the main modality used for surveillance, MRI was not available. Overall survival and disease free survival rates at 5 years in the observation group were 96% and 72%, respectively. Fifteen patients developed disease recurrence; 8 developed local recurrences while 7 developed distant metastases (Habr-Gama, Perez et al. 2011). All local recurrences were potentially amenable to salvage therapy.

Smaller studies have shown less favourable results, Nakagawa et al recruited 52 patients with mid or low rectal tumours. Post CRT 10 patients had biopsy confirmed complete response. Of the 10 cases with pCR, 8 presented with local recurrence between 3.7-8.8 months. MRI was not used for selection or during surveillance (Nakagawa, Rossi et al. 2002).

Therefore the criteria to enrol patients into a deferral of surgery programme are uncertain, as is the approach to monitor such patients to detect tumour regrowth. As discussed in section 1.7.7.2, diffusion weighted imaging indices appear to change during treatment, therefore there may be a role for diffusion weighed imaging in surveillance.

1.8.2 Poor response

The subgroup of patients with unfavourable post treatment MRI parameters appears to be at higher risk of local or systemic failure following a standard TME resection. The surgeon may be warned of this preoperatively, and direct dissection accordingly. In future studies, this group could be considered for further therapy such as intensified or extended systemic chemotherapy, a radiotherapy boost or more intensive postoperative follow up (O'Neill, Brown et al. 2007) . Such approaches have not yet been studied in clinical trials.

1.9 Conclusion

MRI is a validated technique for the baseline staging of rectal cancer. Those patients with MRI defined locally advanced disease often undergo preoperative chemoradiation prior to total mesorectal excision.

Although post operative pathological staging of rectal tumours gives useful prognostic information about survival and can be used to plan adjuvant therapy, it is clear that the availability of this information preoperatively could influence treatment substantially. For example those with good response on MRI could enter a deferral of surgery programme- however the use of MRI in a surveillance setting has not been evaluated.

Overall, from the literature, the precise role, importance and validity of restaging rectal cancers after preoperative therapy (chemoradiation/ chemotherapy) is uncertain. Many studies to date evaluating the T restaging of rectal cancer post chemoradiation have been disappointing with radiologists unable to reliably differentiate the changes of post chemoradiation fibrosis from residual tumour. Other groups have suggested novel criteria using the degree of fibrosis and residual tumour (mrTRG), volumetric tumour reduction and the use of diffusion weighted imaging. These approaches are not well validated against pathological endpoints. Moreover, no present study has investigated the relationship between any MRI parameter and survival endpoints.

2 Aims

2.1 Overall Hypothesis

A validated approach for rectal cancer assessment following preoperative therapy using MRI can be developed and validated against histopathological and survival outcomes.

2.2 Aims

1. To characterise the imaging appearances of treatment response/fibrosis and residual mucinous and non-mucinous tumour by matching post neoadjuvant therapy high resolution MR images with histological specimens.

2. To evaluate the accuracy of post chemoradiation MRI based tumour regression system, T staging, N staging and CRM against with histopathological endpoints (T stage, N stage, and Circumferential Resection Margin).

3. To compare the post chemoradiation diagnostic accuracy of MRI tumour regression grading, T staging, volume reduction post treatment, and modified RECIST length measurement; with the histopathological standards of T stage and tumour regression grading.

4. To evaluate the prognostic relevance, as judged by overall survival, disease free survival and local recurrence of post chemoradiation MRI tumour regression grading, T staging, N stage and post treatment MRI CRM status.

5. To identify which of the available MRI imaging methods, MRI tumour regression grading, T staging, and modified RECIST length measurement can identify good versus poor responders to neoadjuvant chemotherapy compared with the histopathological reference standard of tumour regression grade.

6. To determine, in a group of rectal cancer patients with MRI determined good response to chemoradiation and enrolled in a deferral of surgery programme, whether ADC values differ between patients with residual/recurrent tumour and those patients in clinical, radiological and biopsy confirmed complete response.

3 Materials & Methods

An overview of the materials and methods used to evaluate the aims of this thesis are presented. Further details particular to the specific aims of each study are described in the individual chapters.

3.1 Patients

3.1.1 Patient Databases

The clinical material for this thesis came from four prospective studies: (a) Magnetic Resonance Imaging and Rectal Cancer European Equivalence Study, (MERCURY Study) [Project number MREC 02/01/01], (b) Capecitabine Oxaliplatin Radiation Excision Trial (CORE Trial) [Project Number C86-01], (c) Groupo Espanol Multidisciplinario del Cancer Digestivo (GEMCAD study) [EudraCT Project Number 2008-006974-14], and (d) Deferral of surgery study [LREC Project Number UKCRN ID 8565]. The studies were approved by either local or multi-centre research and ethics committees. Written consent was obtained from all patients prior to inclusion into the studies.

3.1.2 MERCURY study patients & statistical considerations

The MERCURY study was a prospective multi-centre study evaluating the equivalence of MR imaging in the evaluation of rectal cancer between centres. Eleven specialist colorectal units in 5 European countries participated in the trial. Over 700 patients were enrolled into the study between February 2002 and October 2003. Five year follow up was completed in December 2008.The MERCURY group has developed a unique pathological and imaging database that has been integrated to form an important teaching and research resource for radiologists and pathologists. This database of radiological pathological correlated cases of rectal cancer is the most comprehensive and largest in the world (MERCURY 2007).

Using this database, an observational study was performed to match the appearance of rectal tumours, fibrosis and treatment effects after neo-adjuvant chemoradiation treatment to histopathology **(Aim 1).**

Using this information; the accuracy of post chemoradiation MRI based tumour regression system, T staging, N staging and CRM was assessed against histopathological endpoints (T stage, N stage, and Circumferential Resection Margin) **(Aim 2).**

To validate the interpretation principles developed from the radiology pathology matching study, a prospective study of the 111 patients with rectal cancer treated by neoadjuvant therapy in this cohort was performed. Patients were assessed for response by both MR and pathology T, N staging and CRM status. MRI tumour regression grade was also assessed. Overall survival was estimated using the Kaplan-Meier product-limit method. A Cox proportional hazard model was used to determine the association between good and poor responders on MRI/ Pathology and survival outcomes after controlling for patient characteristics **(Aim 4).**

3.1.3 CORE study patients & statistical considerations

The CORE (Capecitabine, Oxaliplatin, Radiation, Excision) study was a prospective phase II trial evaluating if treating patients with Oxaliplatin and Capecitabine with concomitant pelvic radiotherapy reduced distant recurrence and increased tumour resectability. Enrolment was between July 2003-December 2004. Eleven specialist colorectal units in 6 European countries took part in the trial (Rutten, Sebag-Montefiore et al. 2006).

Eighty-six patients underwent chemoradiotherapy for MRI defined locally advanced rectal cancer. Eighty-three patients had evaluable imaging and 78 had final pathology.

MRI tumour regression grade and post treatment MRI T stage were assessed alongside the parameters of MRI volume change and MRI length change/mrRECIST by two independent readers in all 78 patients. Parameters were analysed against both T stage pathology and pathological tumour regression grading. Several statistical tests were used, (Receiver operating curve analysis, Kappa Calculation, Mann-Whitney U test, Kruskal Wallis analysis of variance and univariate logistic regression), to enable calculation of the diagnostic accuracy for each MRI parameter **(Aim 3).**

3.1.4 GEMCAD study patients

The GEMCAD (Groupo Espanol Multidisciplinario del Cancer Digestivo) study is a prospective phase II trial evaluating the safety and efficacy of neoadjuvant Capecitabine, Oxaliplatin and Bevacizumab in intermediate-risk rectal cancer patients defined by MRI. Twenty eight eligible patients were enrolled between July 2009-May 2011. Twenty four patients had evaluable imaging and pathology.

The reproducibility of different post treatment assessment methods was investigated by 7 radiologists independently assessing baseline and post treatment MRIs for: MRI T stage, MRI tumour regression grade, and MRI length change. Parameters were analysed against pathological tumour regression grading using Receiver operating curve analysis and the Mann-Whitney U test as well as univariate logistic regression. Agreement between the 7 radiologists for each parameter was assessed by Krippendorff's alpha. Krippendorff's alpha is applicable to any number of readers, can compensate for missing data and can adjust itself to small sample sizes **(Aim 5).**

3.1.5 Deferral of surgery patients

This is an ongoing multicentre prospective phase II trial studying patients undergoing imaging and clinical surveillance following a good response to preoperative CRT. The primary endpoint of the trial is to demonstrate that surgery can be deferred and even permanently deferred in patients that show complete response. The follow-up protocol includes serial MRI, sigmoidoscopies and biopsies. Forty one patients have been enrolled between 2006-2012,

The ability of serial MRI diffusion weighted imaging to identify and monitor patients likely to be in complete response versus those with tumour is investigated in this thesis **(Aim 6)**.

Two radiologists independently drew a region of interest over the treated tumour/scar on a single slice of the MRI ADC map. Scans were coded as showing complete response or tumour according to biopsy and MRI T2 imaging findings. Linear mixed effects modelling was used to test for significant differences in ADC values, which were regressed as a factor of time and presence/ absence of tumour regressed as an independent variable. Receiver operating curve (ROC) analysis was also used to define the mean ADC cut-off value in discriminating the tumour group from complete response group and to investigate the level of agreement between the two observers.

In each statistical test employed a p-value of <0.05 was considered statistically significant.

3.2 High-resolution MRI scanning protocol

3.2.1 MR technique

3.2.1.1 Background

Preoperative thin section MR imaging was first shown to improve staging in rectal cancer and demonstrated accurate measurement of depth of extramural tumour infiltration in 1999 (Brown, Richards et al. 1999). The details of the MRI technique published in 2005 and its accurate reproducibility confirmed in 2007 (Brown 2005) (Koh, Brown et al. 2007). This high resolution technique is recommended for optimal visualisation of rectal and mesorectal anatomy (Brown, Kirkham et al. 2004), and for characterisation of mesorectal lymph nodes (Brown, Richards et al. 2003).

3.2.1.2 Protocol

Each trial employed a similar imaging protocol; Patients were placed supine on the table with the flexible multi-element phased array body/ pelvic coil placed firmly around the pelvis to minimise motion. A full bladder and purgatives were not necessary and anti-peristaltic agents were not needed as small bowel movement was not a problem.

The same technique was used both for baseline and post treatment imaging, with images acquired using same angles. This enabled direct comparison. Baseline images were also used to help locate the treated tumour – which was difficult to visualise in some patients that had a good response (Brown 2005). Full MR parameters for both Siemens and Philips systems are detailed in tables 2.1 and 2.2.

After initial localisation imaging, initial large field of view sagittal and axial images were acquired (Brown 2005). These first two sequences allowed an overview of the treated tumour, potentially involved lymph nodes and direction of the rectal wall. This enabled planning of high resolution sequences, which were vital for the visualisation of the tumour and post treatment fibrosis. Besides the imaging plane, these sequences were obtained with the same imaging parameters (figure 3.1).

First sequence planned axial to the plane of the tumour and rectal wall; Figure 3.1A
Thin-section (maximum 3 mm) axial T2 weighted images through the treated rectal cancer were planned using the sagittal T2 weighted images. These images were performed perpendicular to the long-axis of the rectum, using a 16 cm field of view.

Second sequence for oblique axial imaging for lymph node drainage territory; Figure 3.1B
Obtaining oblique axial imaging ensured coverage of draining nodes and tumour deposits, which can extend above the superior edge of tumour.

Third sequence in coronal plane for low rectal cancers. Figure 3.1C
Relying on oblique axial imaging alone can be limiting at the level of the anorectal junction. At this level the rectal wall changes in diameter and distance to the neighbouring tissues is smaller. The images may not show the rectal wall in its entirety and overstaging

may result from partial volume artefact. Therefore high resolution coronal imaging was useful for lower third rectal tumours, which showed the relationship between the rectal wall and the levator muscles, the anal sphincter complex and the intersphincteric plane.

Table 3.1 Imaging sequences for rectal imaging using Siemens' 1.5 T MR System

NSA= Number of signal averages.
TSE= Turbo spin echo.

	Sequence	FOV mm	TR/ TE	Slice mm	Matrix	NSA	Time mins
Sagittal T2 From one pelvic sidewall to other	TSE/ 23	354	5478/ 128	3 interleaved	276 x 512	3	3.22
Axial T2 Iliac crest to pelvic floor	TSE/ 23	354	5478/ 128	5 interleaved	322 x 512	3	3.55
Axial T2 Perpendicular to the rectum **Oblique Axial T2** To cover lymph node territory	TSE/ 23	185	5383/ 128	3 (0.1 gap)	230 x 256	3	4.23
Coronal T2 Low tumours parallel to anal canal	TSE/ 23	185	5383/ 128	3 (0.1gap)	230 x 256	3	4.23

Table 3.2 Imaging sequences for rectal imaging using Philips' 1.5T Integra System

NSA= Number of signal averages.
TSE= Turbo spin echo.
SENSE= Sensitivity encoding for fast MRI.

	Sequence	FOV mm	TR/ TE	Slice mm	Matrix	NSA	Time mins
Sagittal T2 From one pelvic sidewall to other	TSE/ 23	250	3500/ 125	3 interleaved	304 x 512	4	6.36
Axial T2 Iliac crest to pelvic floor	TSE/ 22	420	3500/ 80	5 interleaved	352 x 512	1	1.38 SENSE 2
Axial T2 Perpendicular to the rectum **Oblique Axial T2** To cover lymph node territory	TSE/ 16	160	3500/ 120	3 interleaved	256 x 512	6	5.36
Coronal T2 Low tumours parallel to anal canal	TSE/ 16	160	3500/ 120	3 interleaved	256 x 512	6	5.36

Figure 3.1. Imaging sequences for rectal cancer imaging

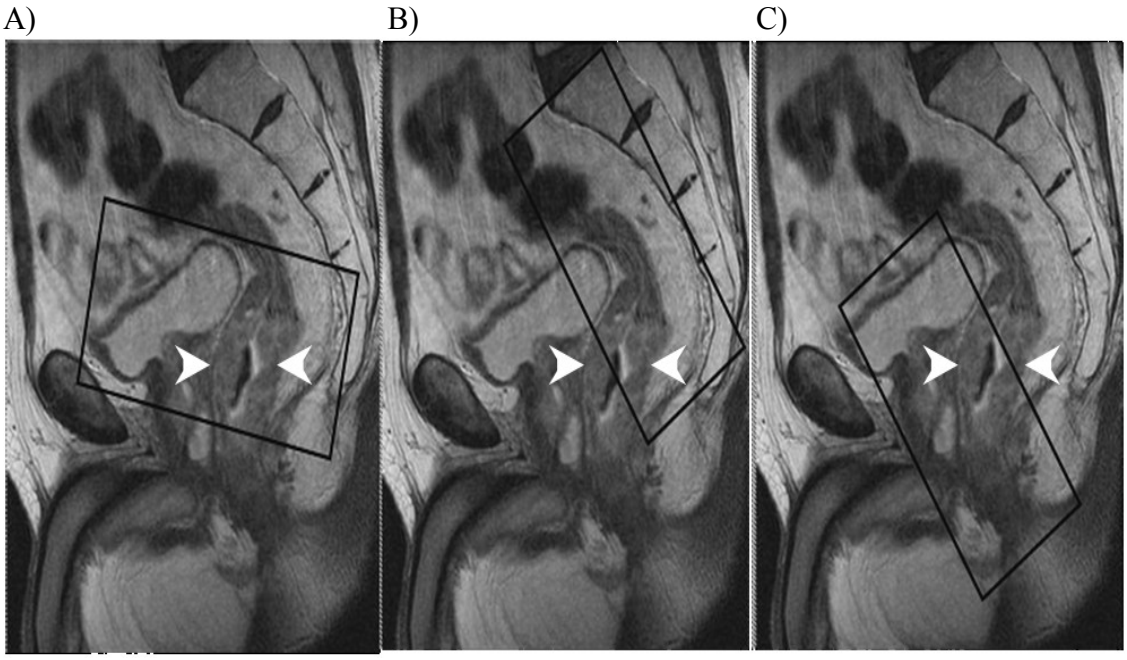

The tumour is indicated by arrowheads.

A) Planned high resolution block (black box) axial to the plane of the tumour and rectal wall. Images are acquired perpendicular to the long-axis of the rectum.
B) Oblique axial block (black box) to cover lymph node drainage territory- which can extend above the superior edge of tumour.
C) Block in coronal plane (black box) for low rectal cancers. This shows the relationship between the rectal wall and the levator muscles, the anal sphincter complex and the intersphincteric plane.

3.2.1.3 Diffusion weighted imaging protocol

Axial Diffusion Weighted (DW) MR images were obtained by using a DW MR echo-planar sequence on both Philips and Siemens MRI scanners. Imaging parameters are detailed in Table 3.3. DW MR Images and ADC maps were acquired by using b values of 0, 350 and 750 sec/ mm. All DW MR imaging was performed during free breathing with fat suppression. Both the high resolution T2 and diffusion weighted imaging was performed in the same plane.

Table 3.3. Small field of view Diffusion weighted imaging parameters

SPAIR= Spectral attenuated inversion recovery.

Parameter	**Philips**	**Siemens**
Field of view (cm)	280	220
Matrix size	112X256	138X256
TR	2500	3100
TE	66	71
Echo planar imaging factor	75	112
Parallel imaging factor	2	2
No. signals averaged	4	8
Section thickness (mm)	5	5
Direction of motion probing gradients	3 scan trace	3 scan trace
Fat suppression	SPAIR	SPAIR
b factors (s/mm2)	0,350,750	0,350,750

3.2.1.4 Additional MR techniques

3 Tesla MR Systems are increasingly available in radiology departments. Such systems shorten the examination time as 3 dimensional image acquisitions remove the need for multiplanar 2D images. Improved spatial resolution and signal to noise ratio has also been reported (Kim, Lim et al. 2010). Studies comparing 2D with multiplanar reconstruction and 3D T2 weighted imaging protocols in staging rectal cancer patients have shown no significant differences in T and N staging accuracy (Futterer, Yakar et al. 2008; Maas, Lambregts et al. 2012). These studies did not investigate the accuracy of 3D T2 weighted imaging in restaging rectal cancer post chemoradiation. This thesis presents images acquired using a 1.5-T whole-body MR imager with a pelvic phased-array coil.

Dynamic contrast-enhanced MRI (DCE-MRI) has been evaluated in the restaging of rectal cancer post CRT. Derives et al (n=17) (Devries, Griebel et al. 2001) showed DCE-MRI perfusion index values before chemoradiation correlated with T downstaging. Diner et al (n=33) (Dinter, Horisberger et al. 2009) showed the slope of the contrast media enhancement curve helped to identify responders to chemoradiation. Overall, given the absence of published evidence regarding the accuracy, reproducibility and DCE-MRI's comparative value versus high resolution T2 scanning we did not use this sequence in the restaging of rectal cancer.

3.2.2 MRI Quality Assurance

The centres participating in the trials detailed in this thesis conducted regular quality assurance to detect any changes in machinery performance which could adversely affect images obtained. The schedule of quality assurance was conducted in line with the individual institution's standard operating procedures. The method of assurance involved conducting a series of test measurements on a body phantom supplied by the relevant MRI

manufacturer. The measurements where then compared with published acceptable limits. The measurements and reference limits have been described fully elsewhere (Firbank, Harrison et al. 2000). In the event of a substantial deviation from the accepted limit the machine was not used.

To ensure the standard protocol described in section 3.2 was used by all centres in the MERCURY, CORE and GEMCAD trials an imaging workshop was conducted prior to patient recruitment. All patients in the deferral of surgery study are imaged at The Royal Marsden Hospital.

3.3 Image interpretation software- Diffusion View

Diffusion View™ is a program developed at The Royal Marsden Hospital for quantitative image interpretation. The program requires selected slices to be imported into its image viewer to be in a DICOM format. A freehand region of interest (ROI) is then drawn on the required area of the imported slices. The program calculates the signal for each pixel of the ROI. For the deferral of surgery study small field of view ADC map images were imported into Diffusion View.

3.4 Histopathology

3.4.1 Overview

Pathological endpoints were recorded for each of the four available patient datasets. The exact pathological specimen handling and definitions used are detailed in the relevant chapter.

TNM 5 definitions are used in this thesis, as noted in 1.2.7, some pathologists disagree with the definition of tumour microdeposits in TNM 6 and 7. Extramural depth of tumour invasion and presence of tumour microdeposits were recorded separately in each patient database to enable calculation of TNM stage by version 6 or 7 criteria.

MERCURY dataset; ypT (with T3 substaging) and ypN assessed according to TNM 5 and circumferential margin status.

CORE dataset; ypT (with T3 substaging) assessed according to TNM 5 and pTRG assessed by 5 point system (0-4).

GEMCAD dataset; assessed according to TNM 5 and pTRG assessed by 5 point system (0-4) and circumferential margin status (pCRM).

Deferral of surgery; ypT (with T3 substaging) and ypN stage (according to TNM 5) and circumferential margin status.

4 Post treatment High Resolution MRI correlation with pathology

4.1 Introduction

The precise role, importance and validity of restaging rectal cancers after preoperative therapy is uncertain (Kim, Kim et al. 2010). As discussed previously, refinements in T,N and CRM assessment post treatment have been proposed as well as the novel MRI based tumour regression grading system (Brown, Chau et al. 2003). These proposals remain unvalidated in large numbers of patients in a multicentre trial.

This study matched pathological slides to post treatment MRI images with the aim of characterising the MRI appearances of;
Treatment response- fibrosis and acellular mucin,
Residual tumour-mucin and non mucinous and
Treatment effects- desmoplastic reaction and oedema.

Additionally, the accuracy of MRI tumour regression (mrTRG), T staging (ymrT), N staging and CRM (ymrCRM) was assessed against with pathological endpoints (ypT, ypN, pCRM).

4.2 Methods & Materials

4.2.1 Patients

Patients were enrolled into the original MERCURY prospective study evaluating diagnostic accuracy of MRI staging of rectal cancer between February 2002 and October 2003. The 90 patients treated with preoperative chemoradiotherapy or long course radiotherapy with evaluable post treatment MRI and pathology were evaluated for this study.

4.2.2 Inclusion and exclusion criteria

Inclusion Criteria

Biopsy proven rectal cancer.

Considered by individual centre multidisciplinary team as high risk and requiring preoperative therapy for downstaging or downsizing of the primary tumour. The uniform criterion used by all centres was potential CRM involvement on MRI. Most centres also offered CRT to advanced T3c, T3d or T4 tumours.

One hundred and eleven of 374 patients underwent preoperative chemoradiotherapy/ long course preoperative radiotherapy.

Exclusion criteria

Patients with distant metastatic disease on body computed tomography (CT).
Patients having contraindications to MRI.
Patients undergoing primary surgery or surgery following short course preoperative radiotherapy.

Figure 4.1. MERCURY trial progress flowchart

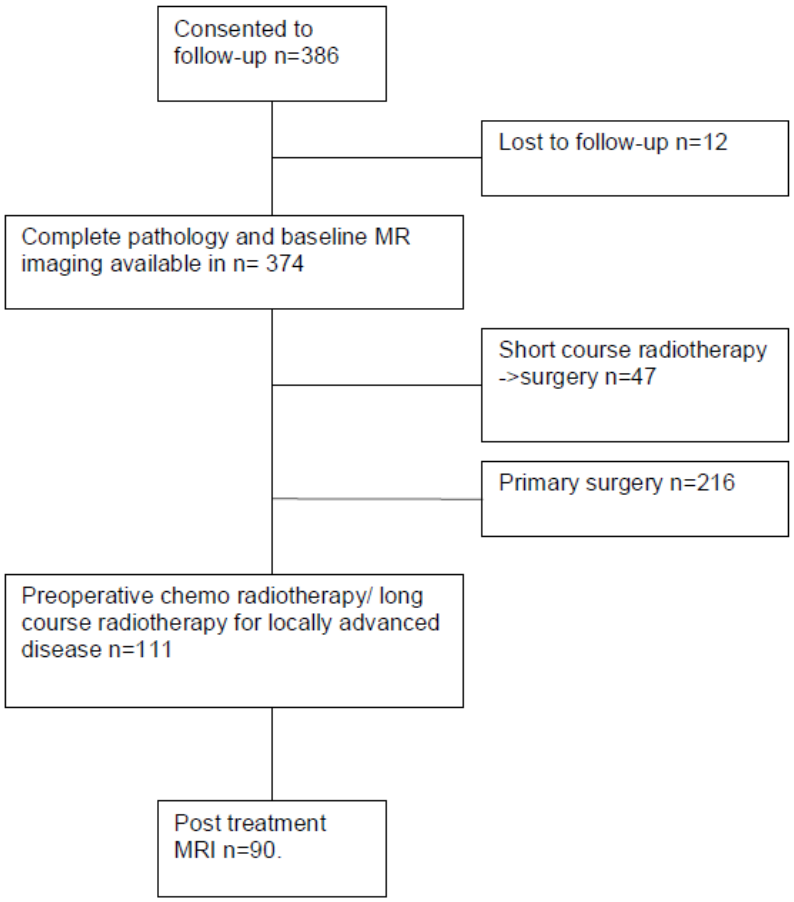

4.2.3 Preoperative treatment

Radiotherapy consisted of 45-54Gy delivered to the primary tumour and pelvic lymph nodes at risk. Fifty eight patients and 53 patients received long course radiotherapy or concurrent chemoradiotherapy with a fluoropyrimidine respectively. MRI scans were performed following completion of radiotherapy at an interval of 4 to 6 weeks and surgery was undertaken at 6-8 weeks after chemoradiotherapy.

4.2.4 Surgery

Surgical options included standard TME plane surgery or extended TME (TME with adjacent visceral resection) with or without sphincter preservation according to a standardised technique. The units' policies were to offer postoperative single agent chemotherapy for AJCC stage III disease. No patient received postoperative radiotherapy.

4.2.5 Histopathological assessment

Following TME, the specimen was opened along its anterior surface proximal to the tumour and fixed in formalin for a minimum of 72 hours. After painting the entire mesorectal surface with marker inks the whole tumour and mesorectum was serially sliced axially at 3-5 mm intervals in order to produce tissue slices that corresponded precisely with the MR slices.

A clear pCRM was defined as greater than, or equal to, 1 mm between the tumour and the resection margin. Eighteen pathologists, with 5-25 years experience in gastrointestinal pathology, evaluated specimens for the post treatment T (ypT), N (ypN) stage, and circumferential margin status (pCRM).

4.2.6 Matching MRI images with pathology

MRI was carried out according to standardised protocol detailed in chapter 3.2.1.

Pathological slides were matched to post treatment MR images using a subset of the MERCURY dataset to have undergone post treatment imaging. Baseline MRI images were also used for information regarding to original anatomical location of the tumour.

Observational pathological findings were divided into: 1) Treatment response -Collagen/ Fibrosis and Acellular mucinous, 2) Residual tumour 3) Treatment related effects- Submucosal oedema and desmoplastic reaction. Spatial correlation between pathological slices and post treatment MRI images was achieved by identifying anatomical and morphological landmarks (lymph nodes, blood vessels and the bowel contour, tumour contour) visible on the pathological specimen and then respectively on the MR images. This was undertaken by two radiologists (GB &UP) in consensus with 15 and 5 years experience in GI imaging.

4.2.7 MRI assessment

A one day imaging workshop for specialist gastrointestinal radiologists participating in the study was held prior to recruitment in 2002 to ensure standardisation of scan acquisition techniques (section 3.2.1) and image interpretation prior to the study using previously published criteria (Brown, Richards et al. 1999; Brown, Radcliffe et al. 2003; Brown, Davies et al. 2004). All scans were single read by each investigating centre radiologist, with 5-15 years GI radiology experience.

T staging of tumour post treatment (ymrT) was based on interpretation of local extent of persistent tumour signal intensity relative to the layers of bowel wall on T2 weighted images. High resolution scans were used to enable accurate delineation of residual tumour signal versus low signal fibrosis and to depict the area of treated tumour.

A T1 tumour was classified if tumour was confined to the submucosal layer. If tumour signal had extended into, but not through the muscle layer a T2 tumour was classified. A T3 tumour was characterised by tumour extension through the muscularis propria. An early T3a tumour extended less than 1mm beyond the border of the muscularis propria. A T3b tumour extended between 1-5mm. More advanced T3 tumours, T3c and T3d, extended 5-15mm or greater than 15mm beyond the muscularis propria.

Nodal stage post treatment was based on interpretation of lymph node border characteristics and signal intensity (Koh, Chau et al. 2008). A node was regarded as positive if either an irregular border or mixed signal intensity was demonstrated.

Post treatment MRI scans were also evaluated for predicted circumferential resection margin status (ymrCRM). A predicted clear circumferential resection margin was recorded if the distance of intermediate signal tumour to the mesorectal fascia was greater than or equal to 1 mm on MRI. For lower third rectal tumours, the definition of predicted ymrCRM involvement was tumour within 1 mm of the levator muscle. If the tumour was present at or below the level of the puborectalis sling, the ymrCRM was predicted involved if there was invasion into the intersphincteric plane or beyond.

4.2.7.1 MRI tumour regression grading

Of 111 patients undergoing preoperative therapy, 90 also underwent post treatment MRI before surgery. Sixty six of 90 (73%) pre and post treatment scans were available for MRI TRG grading. MRI scans were anonymised and centrally reviewed by a radiologist with 14(GB) years experience in MRI assessment of rectal cancers using previously defined criteria (Brown, Chau et al. 2003).

MRI TRG is based on similar principles to the pathological TRG originally described by Dworak. Scans were reviewed to determine the degree of tumour replacement by fibrotic stroma (Dworak, Keilholz et al. 1997) (Table 1.6).

4.3 Statistics

4.3.1 Receiver Operating Curve and Kappa Analysis

Based on known histopathological outcomes according to ypT stage, "good" ypT stage was defined as stages T0, T1, T2 and T3a with "poor" defined as ypT stages T3b,T3c,T3d or T4. Stage T3a and T2 tumours have similar outcomes and were therefore classified as "good"(Hermanek P 1993; Willett, Badizadegan et al. 1999). Binary pathological outcome enabled a cut-off between favourable and unfavourable mrTRG groups to be derived using ROC analysis. This also enabled calculation of the diagnostic accuracy of the mrTRG using the area under the curve (AUC). The AUC is classified as follows: 0.9-1=excellent, 0.8-0.9=good, 0.7-0.8=fair, 0.6-0.7=poor, 0.5-0.6=fail.

Cohen's Kappa was used to analyse the association between ymrT and pathological T stage, ymrN and ypN, as well as ymrCRM and pCRM. Kappa was used as the same criteria were used by both radiologists and pathologists in looking at post treatment MRI and pathology samples respectively. Kappa was classified as follows, $\kappa < 0$, poor agreement;κ =0–0.20, slight agreement; κ =0.21–0.40, fair agreement; κ =0.41–0.60, moderate agreement; κ =0.61–0.80, substantial agreement; and κ =0.81–1.00, almost perfect agreement.

4.3.2 Univariate logistic regression

Based on known histopathological outcomes according to ypT (Willett, Badizadegan et al. 1999), favourable regression was defined as stages ymrT0,1,2, and 3a, while unfavourable grading was defined as ymrT3b,c,d and 4. Favourable and unfavourable mrTRG was defined according to ROC analysis as detailed in 4.3.1.

MR predicted involvement of CRM or pCRM involved were defined as "poor", while clear pCRM/ymrCRM were classified as "good". Likewise MR predicted nodal positivity or ypN involved were defined as "poor", while node negative ypN/ymrN were classified as "good".

Univariate logistic regression analysis was used to analyse the association between MRI parameters (mrTRG, ymrT, ymrN and ymrCRM) and pathologic tumour response (in terms of ypT,ypN and pCRM). This enabled calculation of odds ratios for the probability of an unfavourable pathological outcome.

P values of less than 0.05 were considered significant.

4.4 Results

4.4.1 Demographics

Of the 111 patients who underwent preoperative treatment 49 were <65 and 62 were ≥65. Sixty nine patients were male and 42 were female. Fifty nine patients had mid/high rectal cancers, with 52 patients having low rectal cancers.

4.4.2 Observations

4.4.2.1 Treatment response- Fibrosis and acellular mucin

Pathologically fibrotic stroma consisted predominantly of fibrosis as well as cells responsible for fibrosis development such as fibroblasts and histiocytes. Areas of pathological fibrosis were correlated with very low signal on T2 MRI weighted images (as seen on figure 4.2), while residual tumour was intermediate signal. The signal intensity of fibrosis was similar to that of muscularis propria, while residual tumour was of similar signal as baseline tumour. Careful review of high resolution images enabled detection of small foci of intermediate signal intensity tumour within areas of low signal fibrosis. Varying degrees of residual fibrosis and tumour were observed both between patients and within the same patient at different levels of the tumour.

Figure 4.2. Correlating fibrosis on pathology with imaging

A) Axial T2 weighted image showing intermediate signal semi-annular tumour between 12'o'clock-6'o'clock (outlined).
B) Post treatment axial T2 weighted image shows a residual low signal intensity crescentic area (white arrow).
C) Corresponding photomicrograph (Original magnification X 0.4, H&E stain). The low signal area of on T2 correlates with an area of fibrosis (black arrow).

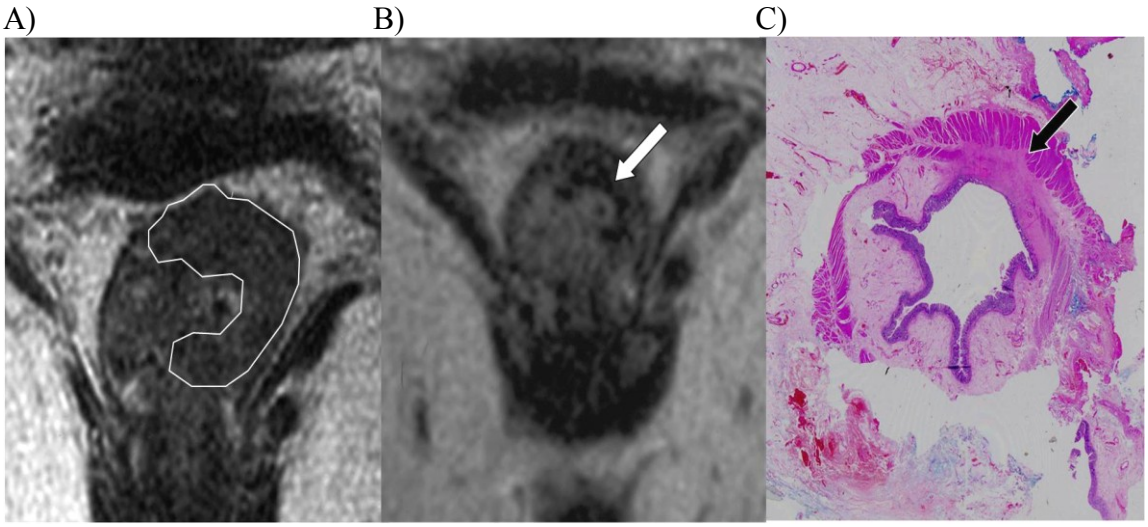

Final pathology showed an acellular mucinous response in two scenarios;

1) In a tumour that on baseline MRI appeared mucinous.
Such tumours pathologically consisted of pools or lakes of extracellular mucin, lined by columns of malignant cells, cords and vessels. Cellular mucin on T2 imaging was hyperintense, but upon close matching with pathology, contained areas of more intermediate signal corresponding to the histologically demonstrated malignant cells, cords and vessels. After treatment, the necrosis of these viable nests/cords of tumour could result in the formation of acellular mucin - namely pools of featureless high signal intensity fluid-like signal on the T2 weighted images which when compared with pre-treatment scans contain no or minimal intermediate signal intensity, this is seen in figures 4.3 and 4.4.

2) In a tumour/lymph node that on baseline MRI appeared non-mucinous i.e. on baseline imaging the tumour was of entirely intermediate signal intensity. Matching post chemoradiation MRI images with pathological slides it was found that acellular mucin pathologically correlated with very high signal intensity pools within the previously documented intermediate signal intensity tumour stroma. This is seen in figures 4.5 and 4.6.

Figure 4.3. Mucinous response with imaging and pathology correlation-Example 1

A) Axial T2 weighted image showing intermediate signal semi-annular tumour between 3'o'clock-10'o'clock (white arrow).The tumour shows an high signal mucinous extramural component (white arrowhead)- this has intermediate signal components (black arrowhead) consistent with tumour.

B) Post treatment axial T2 weighted image shows a high signal intensity extramural area (white arrowhead).Previous intermediate signal components are less visible (black arrowhead), in keeping with response.

C) Corresponding wholemount pathological specimen. Pathological mucin is identified extramurally (black arrowheads).

D) & E) Corresponding photomicrographs (Magnification X 0.4, and 0.8 respectively, haematoxylin-eosin (H-E) stain). The high signal extramural area on T2 correlates with areas of acellular mucin (black arrowheads).

A) B) C)

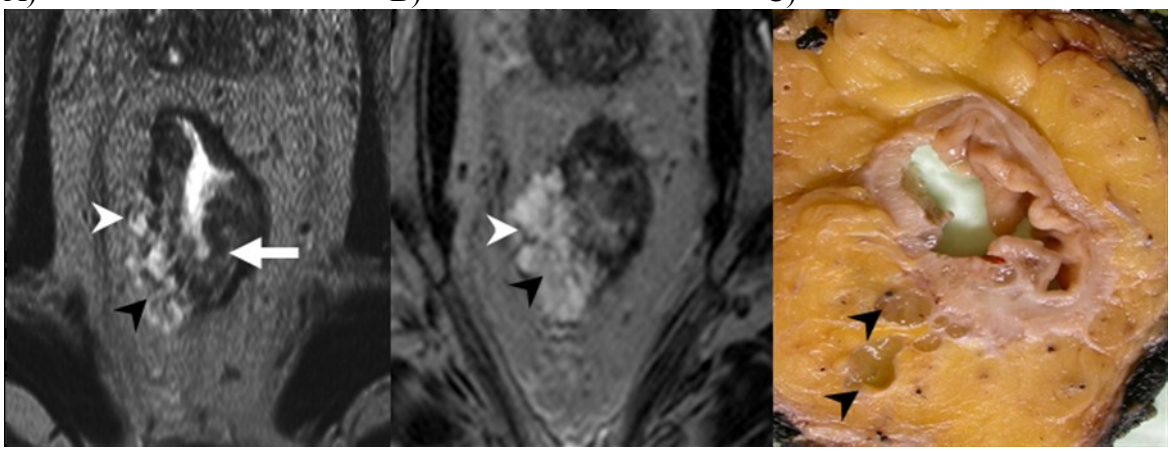

D) E)

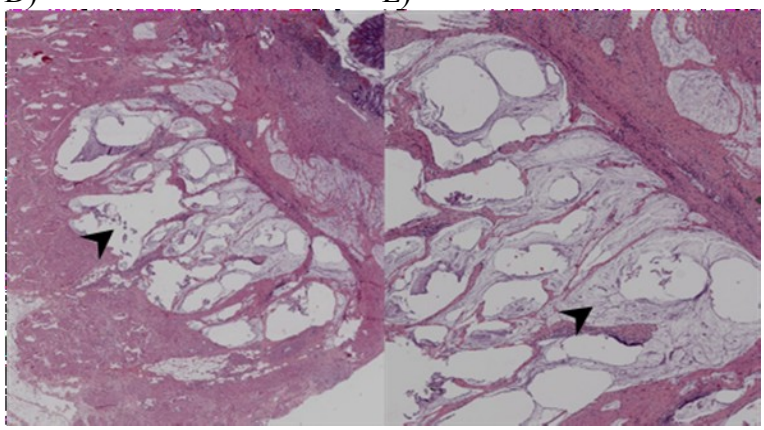

Figure 4.4. Mucinous response with imaging and pathology correlation-Example 2

A) Sagittal T2 baseline image shows large tumour with high signal compatible with mucin. There are intermediate solid cellular components noted within the tumour (arrows).

B) Sagittal T2 post treatment image. There has been formation of acellular mucin indicated by featureless areas of high signal (arrowhead). Areas of intermediate signal residual tumour (arrow) remain.

A) B)

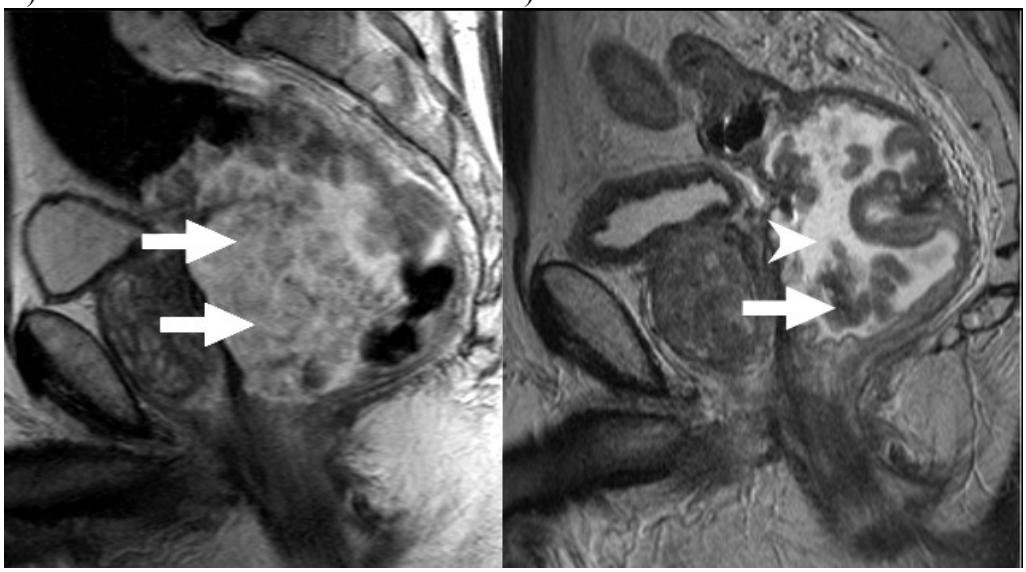

Figure 4.5. Mucinous degeneration post treatment in a non mucinous tumour at baseline

A) Coronal baseline T2 weighted image showing a semiannular tumour as intermediate signal intensity in the rectal wall between 12 'o'clock-9'o'clock (arrow).
B) Coronal post treatment T2 image shows high signal areas of mucinous degeneration (arrow). This was correlated with acellular mucin pathologically (not shown).

A) B)

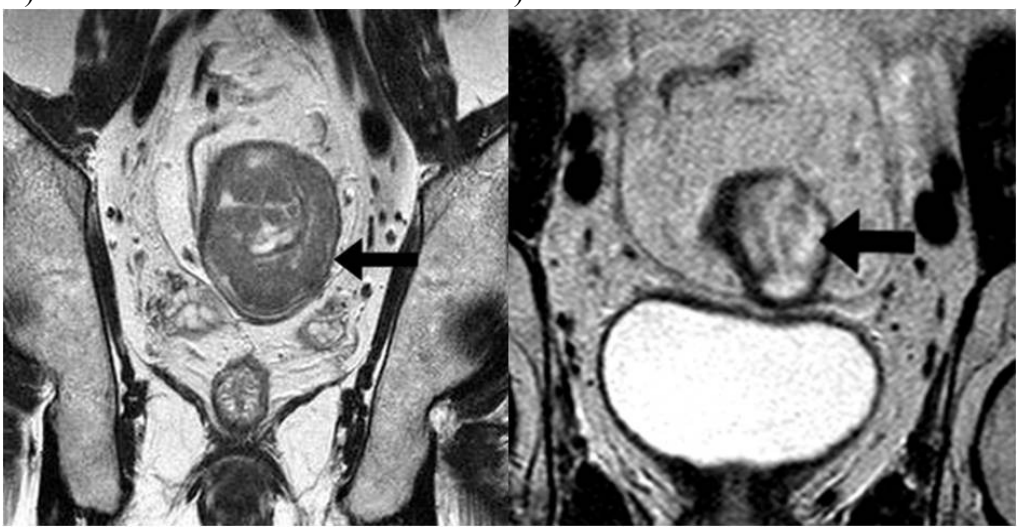

Figure 4.6. Mucinous change in lymph node post chemoradiation

A) Baseline T2-weighted image showing a heterogeneous lymph node in the left mesorectum (arrow).
B) Following chemoradiation treatment, the node now returns high signal intensity, indicating mucinous change (arrow).

A) B)

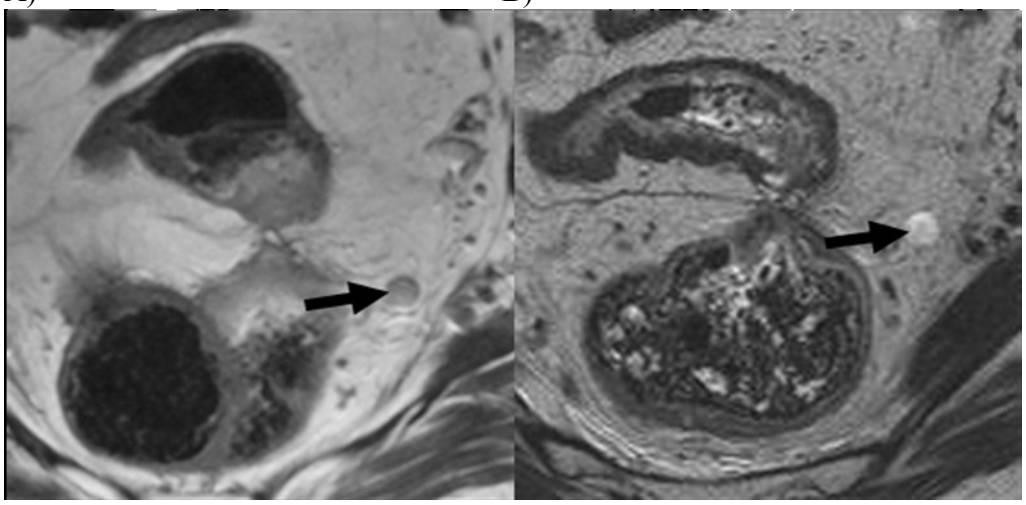

4.4.2.2 Residual tumour

Several mucinous tumours at baseline remained unchanged post chemoradiation. Pathologically persistent columns of malignant cells and cords were shown, On MRI this was seen on baseline as tumours containing high signal with intermediate signal intensity components which remained on post treatment imaging. Pathological non mucinous residual tumour correlated with intermediate signal on post treatment MRI, often with a similar appearance as baseline.

4.4.2.3 Treatment effects, desmoplastic reaction and oedema

Pathologically desmoplastic reaction corresponded to the deposition of collagen as a stromal response. Several cases where observed were anatomical distortion was caused as a result. Pathologically desmoplastic reaction did not contain tumour. Figure 4.7 illustrates this.

On both baseline and post CRT MR imaging desmoplastic reaction corresponded to low-intensity spicules or strands in the perirectal fat radiating from the residual tumour. Conversely the pathological appearance of an advancing tumour margin was correlated to a more nodular, intermediate signal intensity appearance on imaging. Figure 4.8 illustrates this.

Figure 4.7. Desmoplastic reaction

A) Axial T2 post treatment image shows a semi-annular tumour between 12'o'clock-4'o'clock (arrow). Low-intensity spicules in the perirectal fat radiating from the residual tumour (arrowheads) represent desmoplastic reaction.
B) Corresponding photomicrograph (Original magnification X 0.4, haematoxylin-eosin (H-E) stain) showing desmoplastic reaction (arrowheads).

A) B)

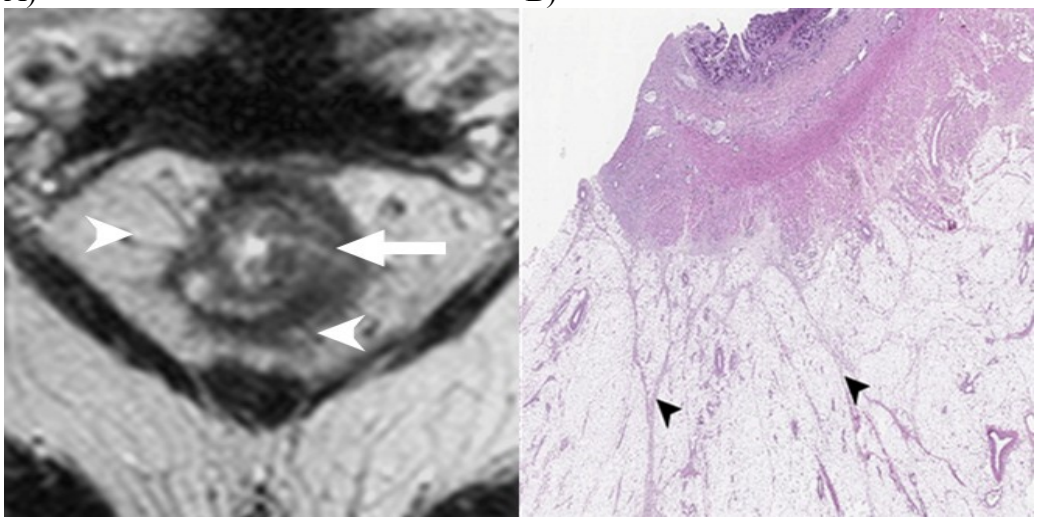

Figure 4.8. Nodular invasive margin

A) Axial T2 post treatment image shows a semi-annular tumour between 6'o'clock-12'o'clock (arrow). Nodular intermediate signal radiating into the perirectal fat represents tumour (white arrowhead).
B) Corresponding photomicrograph (Magnification X 0.4, haematoxylin-eosin (H-E) stain) showing extramural tumour invasion (black arrowhead).

A) B)

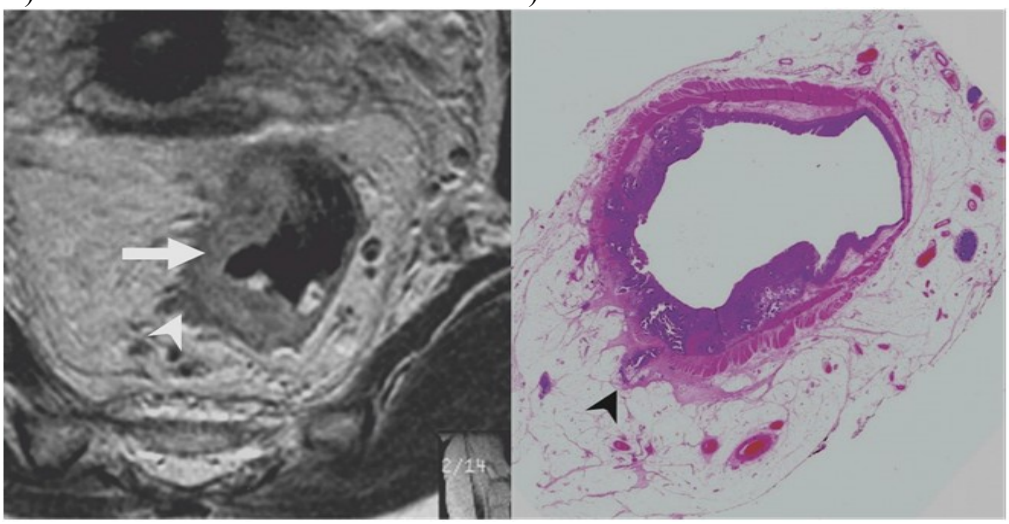

It was observed that on both baseline imaging and pathology rectal carcinoma often grows circumferentially eventually leading to annular stenosis of the bowel wall. Certain tumours showed central indentation with rolled everted edges and invasion/ulceration at their base, with the remaining rectal mucosa and submucosa appearing heaped up into the lumen.

In some cases this appearance became exaggerated after treatment. The original tumour become fibrotic, low signal and less bulky, which resulted in near normal thickness of treated rectal wall, while the unaffected intermediate signal intensity submucosa became oedematous and thickened. This appearance is important as it can lead to the oedematous submucosa being incorrectly interpreted as tumour (figure 4.9).

Figure 4.9. Pseudotumour

A) Baseline T2 weighted axial MR image shows a semi-annular tumour (curved black arrow) the unaffected portion of rectal wall is in the posterior midline at the 6'o' clock position (arrowhead).
B) Images of the same tumour after CRT, and C) Corresponding wholemount pathological specimen. The tumour is at the 12'o'clock position (curved black arrow), with the pseudotumour at the 6 'o' clock position (arrowhead), due to treatment related oedema of mucosa and submucosa.

A) B) C)

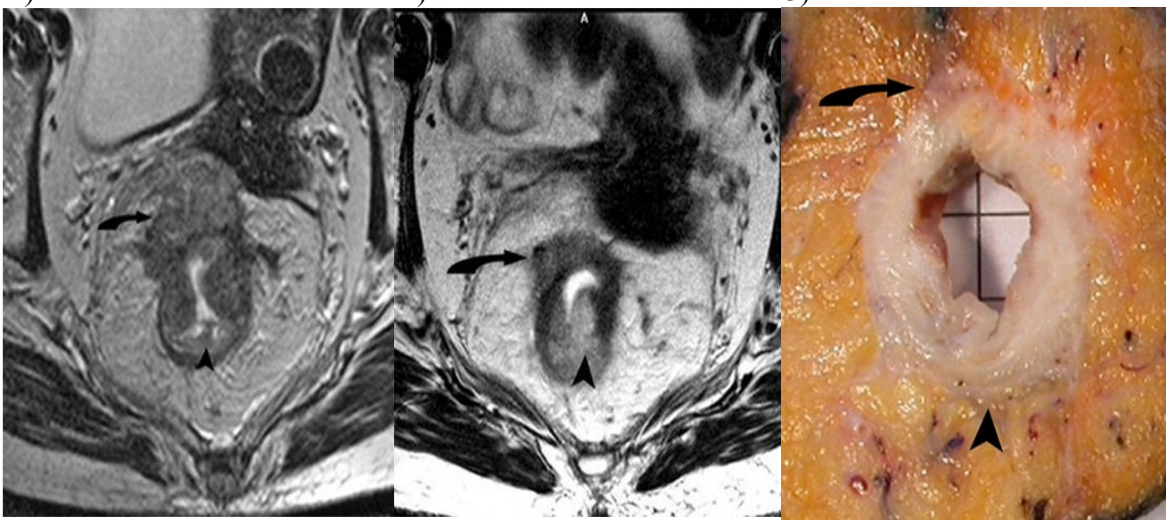

4.4.3 MRI correlation with pathology

4.4.3.1 mrTRG results

Using mrTRG; 5/111 cases were classified as mrTRG1, 15/111 cases were classified as mrTRG2, 12/111 cases were classified as mrTRG3, 22/111 cases were classified as mrTRG4, 12/111 cases were classified as mrTRG5 and 45 patients were either not reimaged or had missing scans.

Pathology, 5/111 cases were classified as ypT0 (complete response), 2/111 ypT1, 25/111 ypT2, 9/111 ypT3a, 20/111 ypT3b, 30/111 ypT3c, 4/111 ypT3d and 16/111 were ypT4. Table 4.1 shows the raw data.

Table 4.1. mrTRG and pathological T stage

		Pathology T stage								
		pT0	pT1	pT2	pT3a	pT3b	pT3c	pT3d	pT4	Total
mrTRG	1	1	0	1	0	2	1	0	0	5
	2	3	2	6	2	1	1	0	0	15
	3	0	0	4	3	3	1	0	1	12
	4	0	0	1	1	6	9	1	4	22
	5	0	0	0	0	1	4	1	6	12
	Missing MRI	1	0	13	3	7	14	2	5	45
	Total	5	2	25	9	20	30	4	16	111

4.4.3.2 mrTRG Receiver operator curve (ROC) analysis

Figure 4.10 shows the number of patients in each of the five mrTRG categories using binary favourable and unfavourable pathology to group the data. ROC analysis was undertaken to calculate the area under the curve (AUC) as well as propose a cut-off between favourable and unfavourable mrTRG. Figure 4.11 shows the ROC analysis. The area under the ROC curve (AUC) is 0.85, indicating mrTRG has a good diagnostic accuracy for T stage pathology.

Table 4.2 illustrates the sensitivity and specificity for the different mrTRG group cut-offs. Grouping mrTRG groups 1-3 as favourable and mrTRG 4&5 as unfavourable gives a sensitivity of 76% and a specificity of 83% against T stage pathology. Matched examples of mrTRG 1-5 are shown in figures 4.12-4.17.

Figure 4.10. Histogram showing pathological T stage and mrTRG

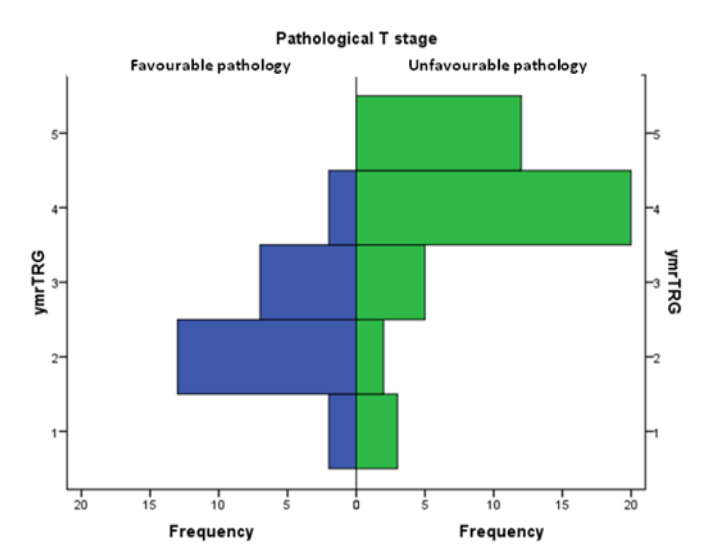

Figure 4.11. Receiver Operating curve showing illustrating the performance of mrTRG against the binary outcome of favourable and unfavourable T stage pathology

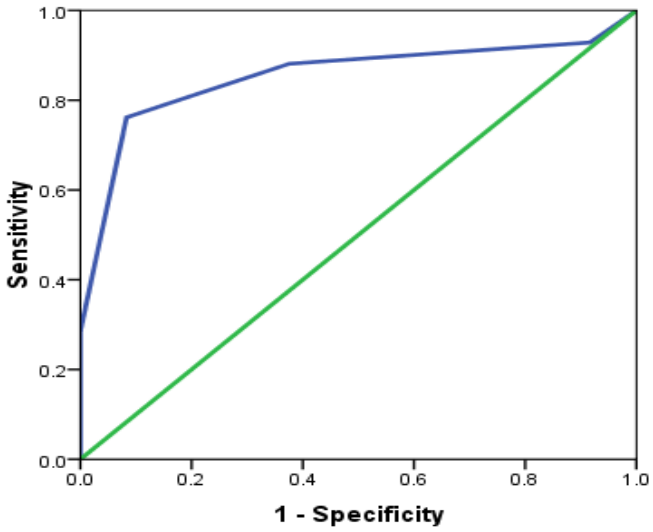

The area under the curve is 0.85, 95% confidence interval (0.76-0.95).

Table 4.2. The sensitivity and specificity of different mrTRG cut-offs vs. pathological T stage

Proposed mrTRG cut-offs	Sensitivity (%)	Specificity (%)
mrTRG1 vs. mrTRG 2-5	92.9	8.3
mrTRG1&2 vs. mrTRG 3-5	88.1	62.5
mrTRG1-3 vs. mrTRG 4&5	76.2	83.0
mrTRG1-4 vs. mrTRG 5	28.6	91.7

Figure 4.12. mrTRG1

A) Axial T2 weighted MR image shows a semiannular infiltrating tumour (arrow).
B) Axial post treatment image shows a fibrotic low signal scar at 7'o'clock-8'o'clock (arrowhead), absence of any tumour signal indicates an mrTRG1.
C) Photomicrograph (Original magnification X 0.4, haematoxylin-eosin (H-E) stain) shows fibrosis (arrowhead) extending beyond the muscularis propria.

A) B)

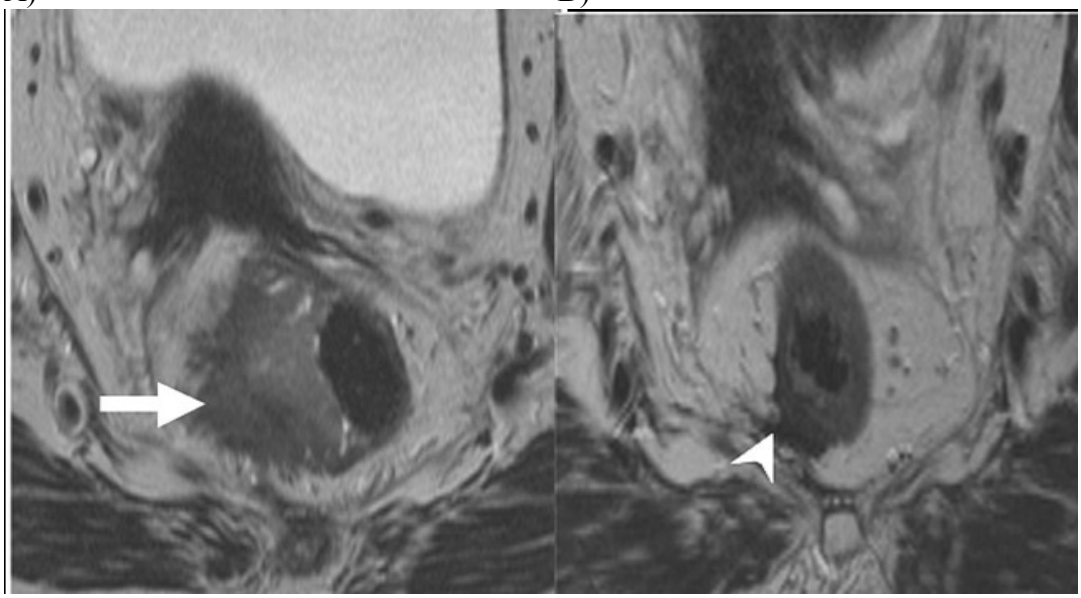

C)

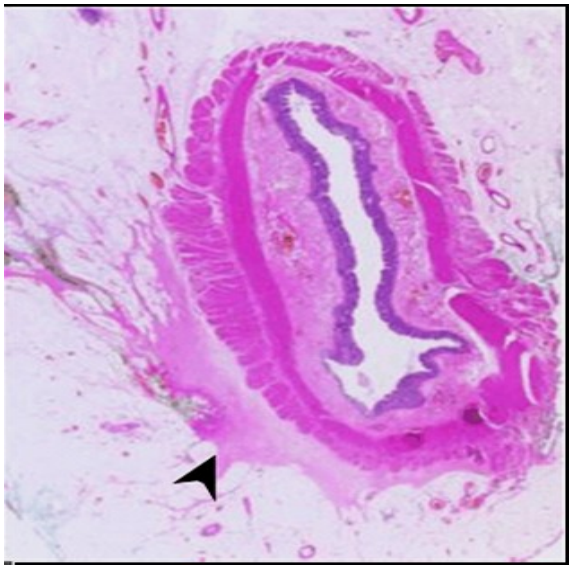

Figure 4.13. mrTRG 2

A) Axial T2 weighted MR image shows a semiannular tumour between the 10‘o’clock and 5‘o’ clock positions (arrow).
B) Axial T2 post treatment image shows tumour regression within the rectal wall, with fibrotic low signal scar (arrowheads). Small foci of residual intermediate signal indicating tumour is noted at the 12‘o’ clock position (arrow). Overall this is compatible with MRI tumour regression grade 2.
C) Photomicrograph (Original magnification X 0.4, haematoxylin-eosin (H-E) stain) shows fibrosis (arrowhead) extending beyond the muscularis propria.

A) B)

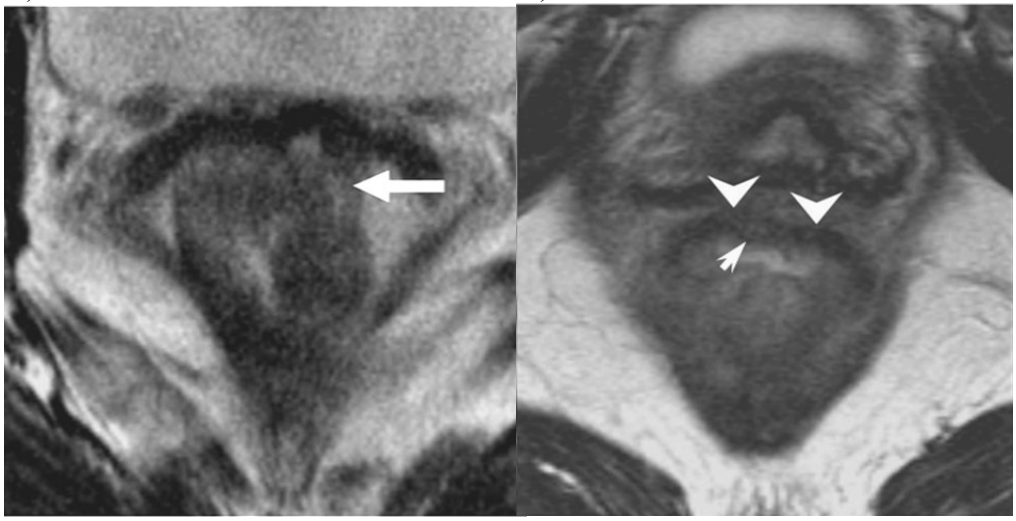

C)

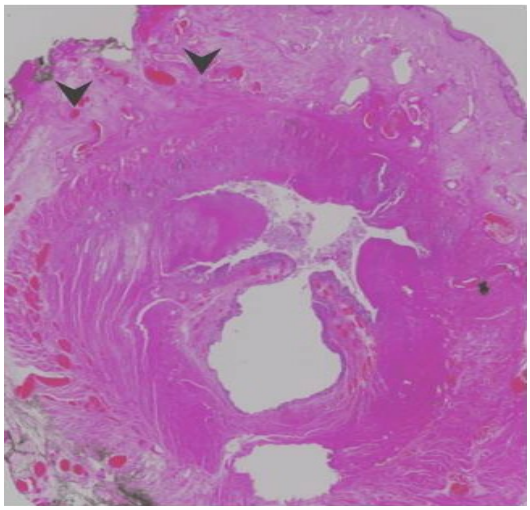

Figure 4.14. mrTRG2, example 2

A) Axial T2 weighted post treatment image shows a predominantly low signal area of fibrosis with small intermediate signal areas (arrow). This is in keeping with mrTRG 2.
B) Corresponding photomicrograph (Magnification X 0.4, haematoxylin-eosin (H-E) stain) demonstrating foci of extramural viable tumour (arrowheads), within the area of fibrosis.

A) B)

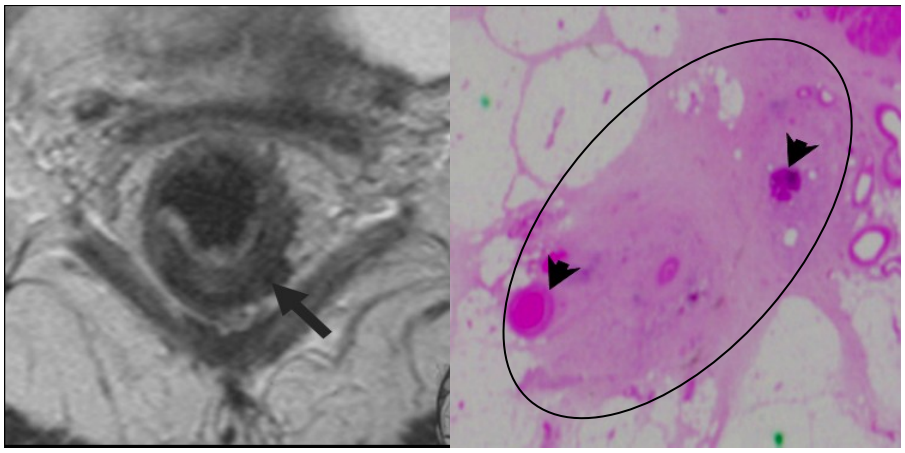

Figure 4.15. mrTRG3

A) Axial baseline T2 image shows tumour centred at the 3'o'clock position, infiltrating through the rectal wall (arrow).
B) Axial post treatment T2 image shows a mixed area; part low signal fibrosis and part intermediate signal intensity indicating mrTRG 3 (arrow).

A) B)

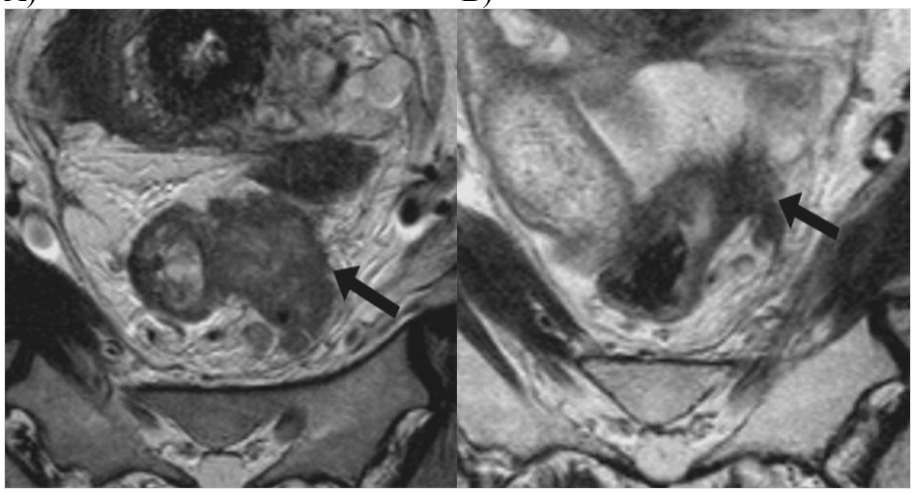

Figure 4.16. mrTRG4

A) Axial T2 weighted MR image shows a semi annular infiltrating tumour between 1'o'clock-5'o'clock (arrow).
B) Axial post treatment image shows a fibrotic low signal extramural rim (arrowheads), however there is dominant residual intermediate signal tumour (arrow). Overall this is consistent with mrTRG4.
C) Photomicrograph (Original magnification X 0.4, haematoxylin-eosin (H-E) stain) shows extramural fibrosis (arrowhead) with residual tumour between 1'o'clock-5'o'clock (arrow).

A) B)

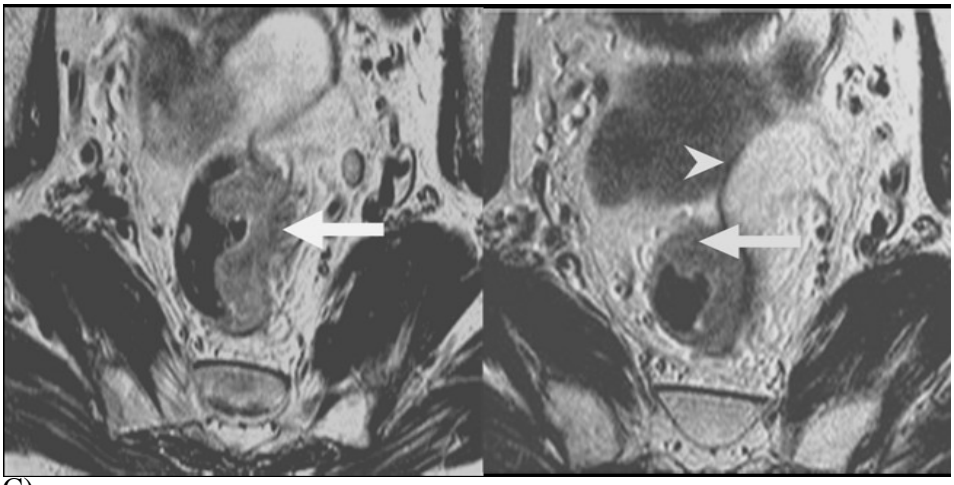

C)

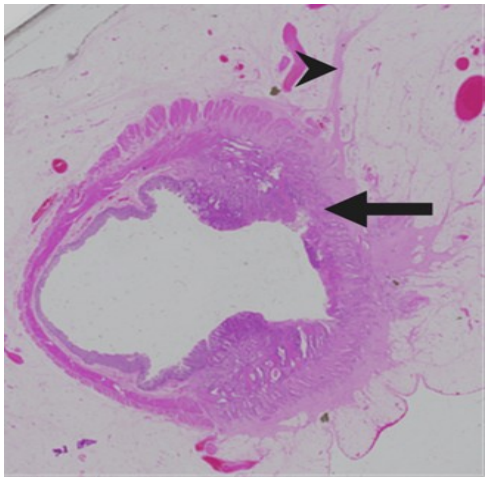

Figure 4.17. mrTRG5

A) Coronal T2 weighted baseline images showing a semiannular tumour as intermediate signal intensity in the rectal wall between the 11'o' clock to 4'o'clock position (arrow).
B) Coronal T2 weighted post treatment image shows little response compared with the baseline scan.

A) B)



4.4.3.3 MRI T stage post treatment

Using the refined ymrT criteria, tumour downstaging was observed between baseline and post treatment MRI. Baseline MRI T stage of the 111 evaluable patients was mrT1:1, mrT2:9, mrT3a:8, mrT3b:11, mrT3c:29, mrT3d:16, mrT4:37. Post treatment T stage was ymrT0:6, ymrT1:1, ymrT2:12, ymrT3a:3, ymrT3b:14, ymrT3c:24, ymrT3d:8 ymrT4:22, Missing/not re imaged:21. Table 4.3 shows the raw data.

Table 4.3. Pathological T stage and ymrT

		Pathology T stage								
		pT0	pT1	pT2	pT3a	pT3b	pT3c	pT3d	pT4	Total
ymrT	T0	2	1	2	0	0	1	0	0	6
	T1	0	0	1	0	0	0	0	0	1
	T2	1	1	7	1	2	0	0	0	12
	T3a	0	0	1	0	1	1	0	0	3
	T3b	1	0	4	2	6	1	0	0	14
	T3c	0	0	2	3	6	11	1	1	24
	T3d	0	0	1	1	0	5	0	1	8
	T4	0	0	1	1	3	4	1	12	22
	Missing MRI	1	0	6	1	2	7	2	2	21
		5	2	25	9	20	30	4	16	111

Observations showed that often low signal fibrosis can extend extramurally with intermediate signal residual tumour present only in the bowel wall. Figure 4.18 illustrates an example of residual tumour and fibrosis at differing extramural depths. Cohen's kappa analysis showed a fair level of agreement between ymrT and pathological T stage with K=0.449, standard error 0.053.

Figure 4.18. Post treatment MRI T stage

A) Axial T2 weighted MR image shows a semiannular infiltrating tumour (arrowhead) a nodule of intermediate signal is seen in a medium sided vein at 3‘o’clock (arrow).
B) Axial post treatment image shows tumour regression within the rectal wall, with fibrotic low signal scar between 9’o’clock-4’o’clock (arrowhead). A focus of residual disease remains in a vein at 3‘o’clock (large arrow). The residual venous disease is 6mm beyond the muscularis propria indicating ymrT3c (double headed arrow).

A) B)

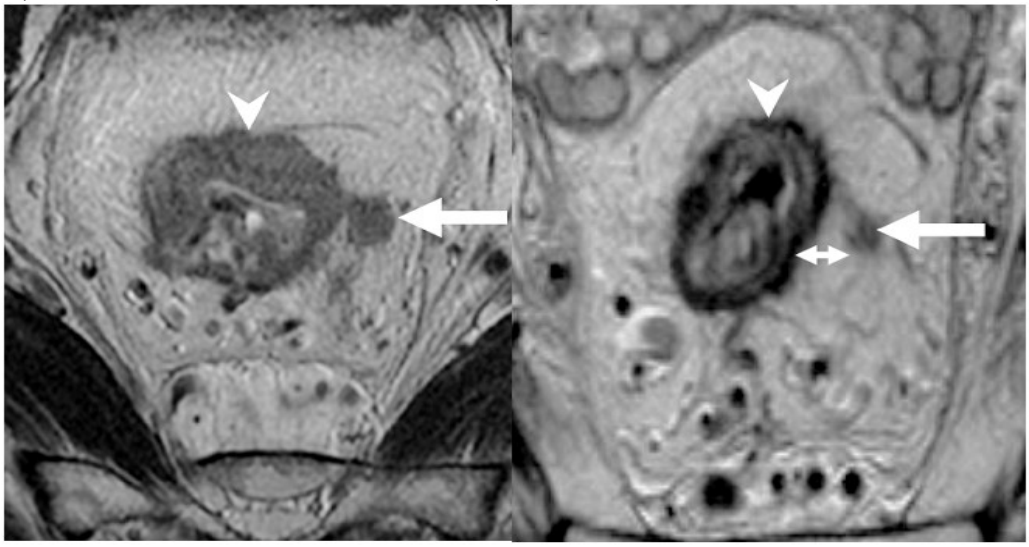

4.4.3.4 MRI N stage and MRI CRM status post treatment

Forty cases were recorded as ymrN positive (N1 or N2) and 50 cases ymrN negative (N0). Sixty seven/111 cases were pathological node negative (ypN0), while 44/111 were pathological node positive (ypN1/2).The raw data is shown in table 4.4.

The predictive value for MRI identified node negative disease was 76%, while the ability to of MRI to identify positive lymph nodes was 60%. An example of an involved lymph node with corresponding pathology is shown in figure 4.19. Cohen’s kappa analysis showed a slight level of agreement with between post treatment MRI Node negative cases and pathological node negative cases with a Kappa=0.364, standard error=0.099.

Table 4.4. Raw data for Nodal status and CRM status

	ypN0	ypN1-2
ymrN		
Negative	38	12
Positive	16	24
Missing	13	8
	pCRM Clear	pCRM Involved
ymrCRM		
Clear	54	1
Involved	19	18
Missing	15	4

Eighty eight/111 cases were CRM pathologically clear while 23/111 were CRM pathologically involved. The predictive value for MRI CRM clear was 98% while the ability of MRI to predict a potentially involved CRM was 49%. Cohen's kappa analysis showed a fair level of agreement between post treatment MRI CRM status and pathological CRM status with kappa=0.48, Standard Error=0.083.

Examples of a potentially clear CRM are seen in figure 4.20 and 4.21 , with spiculation and fibrosis seen at the CRM on MRI identified pathologically. Of the 19 patients with ymrCRM potentially involved but pathological CRM clear, 15/19 had locally advanced T3b-T4 tumours, Thirteen/19 patients were observed to have small areas of intermediate single within more dense areas of fibrosis at the margin, but were pCRM negative. Figure 4.22 shows an example of this scenario.

Figure 4.19. Nodal restaging following chemoradiation treatment

A) Axial T2 weighted MR image shows a lymph node in the right lower mesorectum (arrow). Malignancy is indicated by signal heterogeneity
B) Images after CRT, The node continues to have an irregular edge, and signal heterogeneity indicating malignancy (arrow).
C) Corresponding photomicrograph (Original magnification X 0.7, haematoxylin-eosin (H-E) stain) shows widespread tumour deposition in the lymph node. Since there is minimal normal nodal tissue it is indistinguishable from an extra nodal deposit.

A) B)

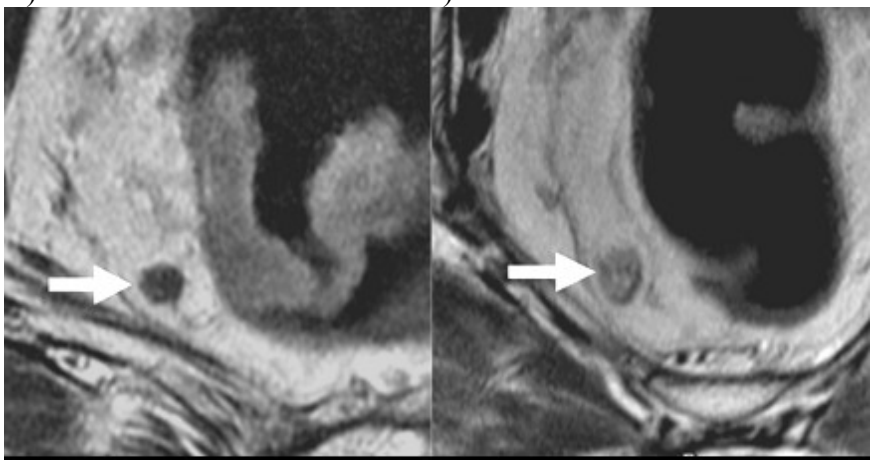

C)

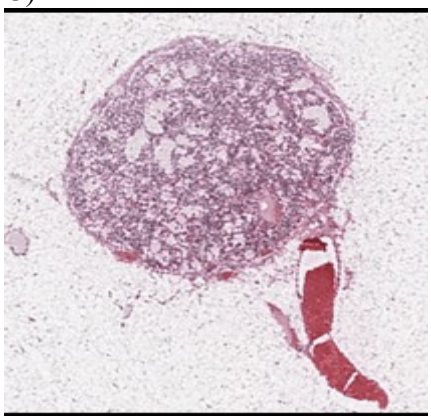

Figure 4.20. Spiculation at the circumferential resection margin

A) T2 weighted image shows a residual area of mural fibrosis (arrow), with spiculations (white arrowhead) extending to the CRM (black arrowhead).
B) Corresponding photomicrograph shows fibrosis (star) extending to the CRM (black arrowheads).

A) B)

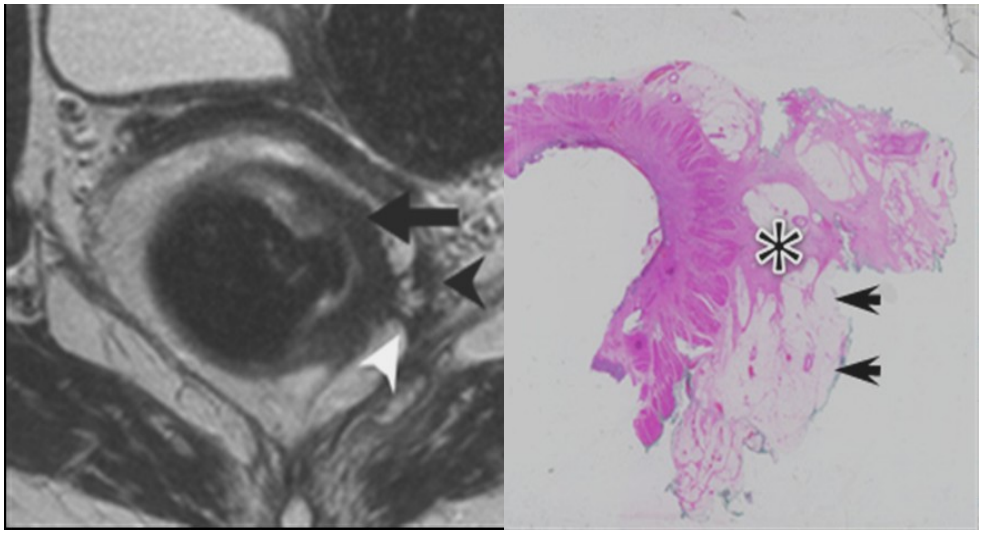

Figure 4.21. Fibrosis at the potential circumferential resection margin

A) Baseline T2-weighted image showing a bulky tumour with invasive at the 3'o'clock position. There is intermediate signal at the circumferential resection margin (arrowhead).
B) Following chemoradiation treatment, the tumour is now a combination of fibrosis (black arrow), which extends to the CRM (white arrowhead). Mucinous degeneration is also seen (dashed white arrow). Residual intermediate signal tumour remains at the 6'o' clock position (white arrow). The overall mrTRG grade is 3.

A) B)

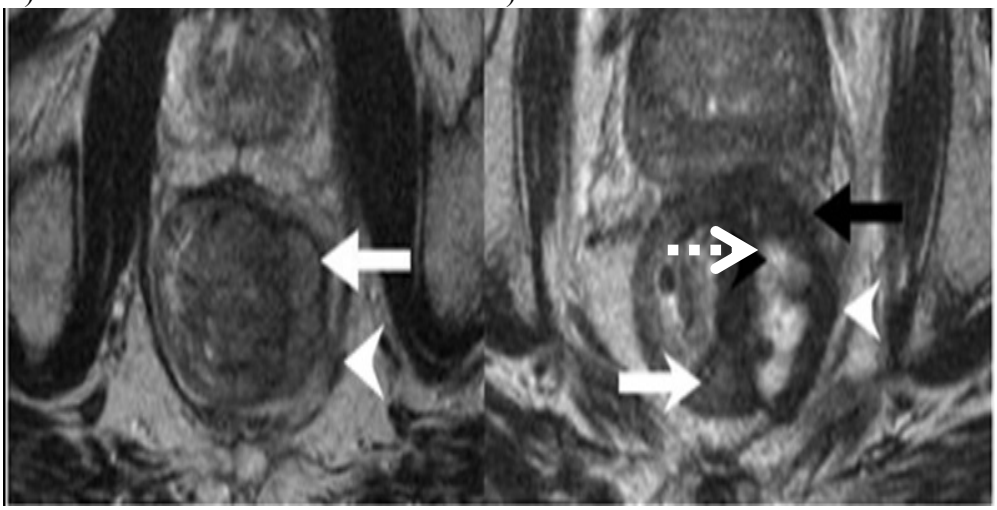

Figure 4.22. Example of incorrect CRM assessment by MRI

A) Post chemoradiation axial T2 weighted image shows apparent intermediate signal tumour (arrow) at the CRM (arrowhead)
B) Corresponding H&E stained section showed only inflammation (arrow) at the CRM. The residual tumour was staged at T3c, with 6mm extramural invasion.

A) B)

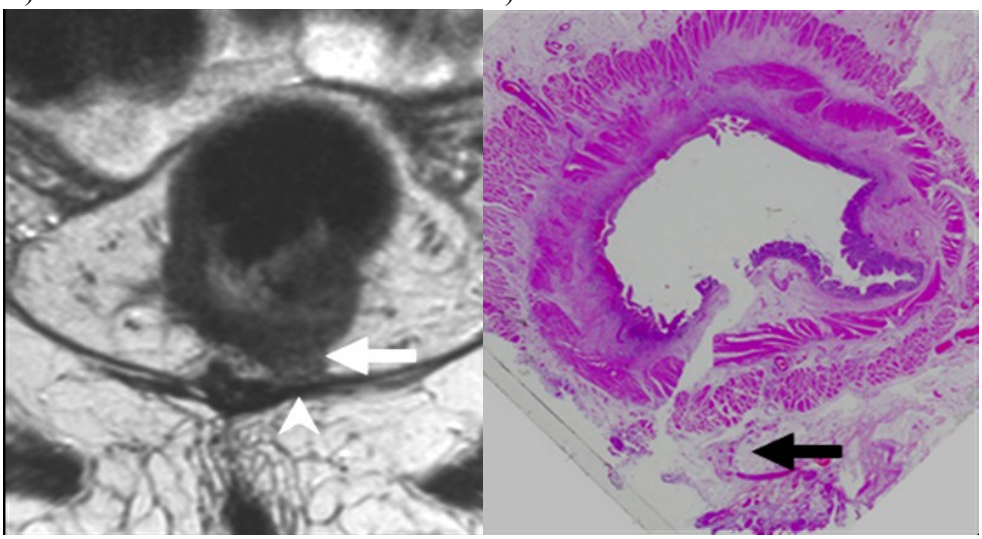

4.4.3.5 Univariate logistic regression analysis

The data for univariate logistic regression analysis was grouped as section 4.3.2. Using data from ROC analysis of mrTRG, Favourable mrTRG was defined as 1-3, unfavourable mrTRG 4-5. Table 4.5 shows univariate logistic regression results.

Patients with mrTRG stage 4-5 were significantly associated with unfavourable pathology (32/34), compared with mrTRG stage 1-3 (10/32); p=0.0001; OR 35.2.

ymrT stages T3b-4 were significantly associated with unfavourable pathology (52/67), compared with ymrT stage T0-T3a (5/23); p=0.001; OR 11.05.

Post treatment MRI node positive cases stages were significantly associated with node positive pathology (24/40), compared with node negative MRI (12/50); p=0.001; OR 4.75.

Cases identified as having a potentially involved CRM on Post treatment MRI were significantly associated with pathological CRM involvement (18/37), compared with case with a potentially clear CRM on Post treatment MRI (1/55); p=0.001; OR 45.9.

Table 4.5. Pathological endpoints by MRI parameters

	ypT0-T3a	ypT3b-4	Positive (PPV) and Negative predictive (NPV) value	OR (95% CI) p value
mrTRG 1-3 4-5 Missing n=45	 22 2	 10 32	 PPV=70% NPV=94%	 35.20 (7.02-176.5) p=0.0001
ymrT T0-T3a T3b-4 Missing n=21	 18 15	 5 52	 PPV=78% NPV=78%	 11.05 (3.52-34.68) p=0.001
	ypN0	ypN1-2		
ymrN Negative Positive Missing n=21	 38 16	 12 24	 NPV=76% PPV=60%	 4.75 (1.91-11.75) p=0.001
	pCRM Clear	pCRM Involved		
ymrCRM Clear Involved Missing n=19	 54 19	 1 18	 NPV=98% PPV=49%	 45.90 (5.72-367.78) p=0.001

4.5 Discussion

4.5.1 Observations on MRI post chemoradiation

This study has confirmed that low signal on T2 represents fibrosis, intermediate signal-tumour, high signal with intermediate components-mucinous tumour and uniform high signal mucinous response. Such changes can be heterogeneous- It is possible for small foci of intermediate signal tumour to persist in areas of low signal fibrosis.

Treatment related effects such as spiculation- linear low signal strands often radiating from areas of mural fibrosis, are important to appreciate as misinterpretation of desmoplastic reaction for residual tumour can lead to overstaging, as the spiculated areas are presumed to represent tumour rather than reaction. Likewise the inflammatory pseudotumour pitfall can be avoided by direct comparison of the pre-treatment scans and documenting the invasive and rolled edge of tumour as well as the portion of the rectal wall circumference that has not been involved by tumour. Other signs such as desmoplastic reaction from the tumour were also found to be helpful.

4.5.2 ymrT and mrTRG assessment on MRI post chemoradiation

The mrTRG system is based on the degree of fibrosis/acellular mucinous response versus intermediate signal tumour/mucinous tumour. ymrT assesses the extent of residual tumour in relation to the bowel wall.

The diagnostic accuracy of mrTRG calculated by area under the ROC curve was good, but not excellent at 0.85. Using ROC analysis mrTRG groups 1-3 were classed as favourable, with mrTRG 4&5 unfavourable. Using this grouping for univariate logistic regression analysis mrTRG showed a significant relationship with T stage pathology.

Post treatment MRI T stage showed a showed a fair level of agreement between ymrT and pathological T stage with Kappa=0.45. When ymrT was grouped as favourable and unfavourable for univariate logistic regression a statistically significant relationship was observed.

From the observations and data presented it is suggested that the extent of fibrosis can be documented and recorded as a separate entity to the extent of tumour signal since fibrosis may or may not contain viable tumour and maybe managed differently.

Our grouped ymrT data is similar to studies published from other centres while this thesis was being undertaken. For example, Barbaro et al (n=53) analysed the correlation between pathological T stage and MR T stage in 53 rectal cancer patients after chemoradiotherapy. This study grouped pathological and radiological T stage into T0-T2 (responders) and T3-T4 (non responders). Of the 36 MR T stage responders, 30 were pathological responders, while of the 17 MR T stage non-responders, 12 were pathological nonresponders. The overall accuracy of MR was 79%. Likewise Dresen et al, using the same radiological and pathological grouping between T0-T2 tumours versus T3-T4 tumours found of the 11 yMR T0-T2 staged patients, 10 were pathological ypT0-T2, while of the 56 yMR T3-4 staged

patients, 42 were pathologically staged as yp3-4. (Barbaro, Fiorucci et al. 2009; Dresen, Beets et al. 2009).

The correlation between restaging MRI T stage and pathology T stage is better in these studies than previous investigations. This maybe partly due to recent studies (Barbaro, Fiorucci et al. 2009; Dresen, Beets et al. 2009) used a 3mm slice thickness high resolution protocol, similar to section 3.2. This is likely to have enabled higher quality images compared to previous studies using 4mm (Chen, Lee et al. 2005) and 5mm slice thickness (Kuo, Chern et al. 2005). Thus, more subtle appearances can be appreciated than on low-resolution techniques used by earlier studies.

It is important to note that more recent investigations (Barbaro, Fiorucci et al. 2009; Dresen, Beets et al. 2009) did not state if any refinements were made to MRI T staging criteria post treatment. Nevertheless a greater appreciation of the reactive changes that occur after chemo radiotherapy, meaning morphological changes such as desmoplastic reaction were not misinterpreted as tumour, is likely to have contributed to the improved reported results. i.e., although not explicitly stated is likely only residual tumour was re T staged according to baseline MRI criteria.

Both mrTRG and ymrT showed good ability to identify those with pathological complete response (ypT0, n=5)/ near compete response (ypT1 n=2). All 7 patients in this group were TRG1/2 and 6/7 were ymrT 1/2. These assessments may therefore be useful as entry criteria in a deferral of surgery approach.

4.5.3 CRM and node assessment on MRI post chemoradiation

While the predictive value for MRI identified node negative disease and potential CRM clearance was relatively high at 76% and 98% respectively, the ability to of MRI to identify positive lymph nodes and potentially involved CRM was lower at 60% and 49% respectively. As a result, a fair degree of agreement between MRI CRM potential involvement and pathological CRM involvement was observed.

In this analysis of the 19 cases of where the ymrCRM was reported as potentially involved in but pathological was CRM clear, 15 had locally advanced ypT3b-T3d tumours extending close to the margin. These patients are likely to remain in a poor prognostic group due to locally advanced ypT despite being pCRM clear. Therefore correlation of MRI and pathological parameters against survival outcomes is warranted. Thirteen/19 patients were observed to have small areas of intermediate signal within more dense areas of fibrosis at the margin, but were pCRM negative.

Two further studies have supported this chapter's data on the difficulty in predicting a potentially involved CRM on MRI post CRT. Vliegen et al suggested the development of a fat pad larger than 2 mm between a residual tumour mass and the CRM on MRI as a definitive sign of the CRM being clear, while the presence of an iso/hyperintense mass infiltrating into or beyond the CRM was considered a definitive sign of tumour invasion. This study found the prediction of a CRM clear of tumour by MRI was 100% (11/11),

while the ability of MRI to predict an involved margin was 57% (30/53). (Vliegen, Beets et al. 2008). Barbaro et al's found similar results; of the 7 patients classified as having MRI CRM involvement, only 3 had histologic findings of CRM involvement. While 100% (46 /46) cases with a clear CRM on MRI had a clear pathological CRM (Barbaro, Fiorucci et al. 2009). Overall, the data suggests that any surgery should remove fibrotic stroma regardless of whether residual tumour signal can be seen.

The ability to predict node positive and negative disease on MRI in this analysis was lower than that previously demonstrated by Koh et al. This study showed a negative predictive value of 90% (18/20 patients) and a positive predictive value of 80% (4/5 patients) (Koh, Chau et al. 2008). The reason for this difference may be due to this study using data from multiple local radiologists rather than two central radiologists. However if involved lymph nodes are removed by careful TME dissection they may not influence survival. This is further discussed in chapter 6.

4.6 Conclusion

This study shown the novel MRI based tumour regression grading system has a good diagnostic accuracy vs. T stage pathology. Using this relatively small data set mrTRG1-3 appear favourable categories, while mrTRG 4 and 5 appear unfavourable.

Individual post treatment MRI T staging showed only a fair level of agreement with pathology. However regression analysis grouping post treatment T stage into favourable and unfavourable categories demonstrated a statistically significant relationship with pathology.

The ability of post treatment MRI to predict node negative pathology and a potentially pathologically clear circumferential resection margin was high. However identifying pathologically involved nodes and an involved CRM on MRI was difficult.

5 Comparison of different MRI response assessment methods and histopathological end points in locally advanced rectal cancer post chemoradiotherapy

5.1 Introduction

High resolution pelvic magnetic resonance imaging (MRI) is a valuable preoperative staging tool for rectal cancer (MERCURY 2007). Most centres offer preoperative chemo-radiotherapy (CRT) to patients with locally advanced, T3, T4 rectal adenocarcinoma and those threatening the potential anatomical planes of resection. Preoperative CRT has been shown to be beneficial in reducing local recurrence rates, and has become a standard of care for locally advanced rectal cancer (Sauer, Becker et al. 2004). Accurate preoperative assessment of response to therapy may permit the clinical teams to modify conventional surgical treatment (Habr-Gama, Perez et al. 2004; O'Neill, Brown et al. 2007).

A number of different methods have been proposed for assessing response of rectal cancer to CRT on MRI. For example MRI tumour regression grading (mrTRG) - investigated in chapter 4 using the MERCURY database, showed good diagnostic accuracy correlation pathological T stage.

Other proposed methods to assess treatment response involve tumour volume reduction estimation and tumour length reduction on MRI. For example Dresden et al examined the relationship between tumour volume and pathological T stage. The tumour volume reduction rate (TVRR) was significantly higher in ypT0-2 tumours compared to ypT3-4 tumours. This study suggested the following criteria to predict an ypT0-2 tumour: Tumour volume of <50cm3, a volume reduction rate of >75%, a normal two layered bowel wall pattern, and any residual tumour surrounded by a hypodense line corresponding with an intact muscular bowel wall (Dresen, Beets et al. 2009). Yeo et al also investigated tumour volume reduction using a work station based method of volume calculation in 405 patients. In this study the tumour volume reduction ratio significantly correlated with both ypT and TRG pathological grading as well with complete response. When the TVRR was categorised into three groups (<60%, 60–80%, and >80%), the rates of ypT0-T2 and ypN0 were significantly greater for patients with a TVRR of >60%, as was the favourable TRG regression rate (pTRG 3-4) for patients with a TVRR >80% ($p < 0.05$) (Yeo, Kim et al. 2009).

There is no published evidence for the superiority of a workstation based volume assessment compared with conventional three dimensional estimation of tumour volume in rectal cancer. Similar work in cervical cancer did not find the workstation method to be substantially different to conventional volume measurements (Mayr, Yuh et al. 2006). Therefore investigation of tumour response using the less time intensive single slice technique appears the preferred option.

Change in maximum tumour length between baseline and post treatment sagittal images (modified RECIST) may also be useful in assessment in tumour response. As previously discussed, 68/70 patients enrolled in the EXPERT study showed a decrease in maximum tumour length post treatment and correlation with survival, but the correlation between the change in tumour length and pathology was not presented (Chau, Brown et al. 2006).

5.2 Aims

The usefulness of ymrT and mrTRG in the reassessment of rectal cancer post CRT was assessed in chapter 4. This analysis used a single pathological outcome (ypT) and did not use MRI to assess change in tumour volume or length.

The aim of this study was to compare which of the available imaging methods- post treatment T staging (ymrT), tumour regression grading (mrTRG), volume reduction post treatment, and modified RECIST length measurement; can identify good vs. poor responders to CRT compared with the histopathological reference standards of ypT and pTRG.

5.3 Methods & Materials

5.3.1 Patients

This analysis was performed in the context of a prospective phase II trial treating patients with MRI defined locally advanced rectal cancer with Oxaliplatin, Capecitabine and concomitant pelvic radiotherapy. Eighty Six patients were enrolled between July 2003-December 2004. The local scientific and research ethics committees of each institution approved the trial. Eighty three patients had evaluable imaging and 78 had final pathology (5 did not undergo surgery). This is summarised in Figure 5.1.

Figure 5.1. Trial progress flowchart

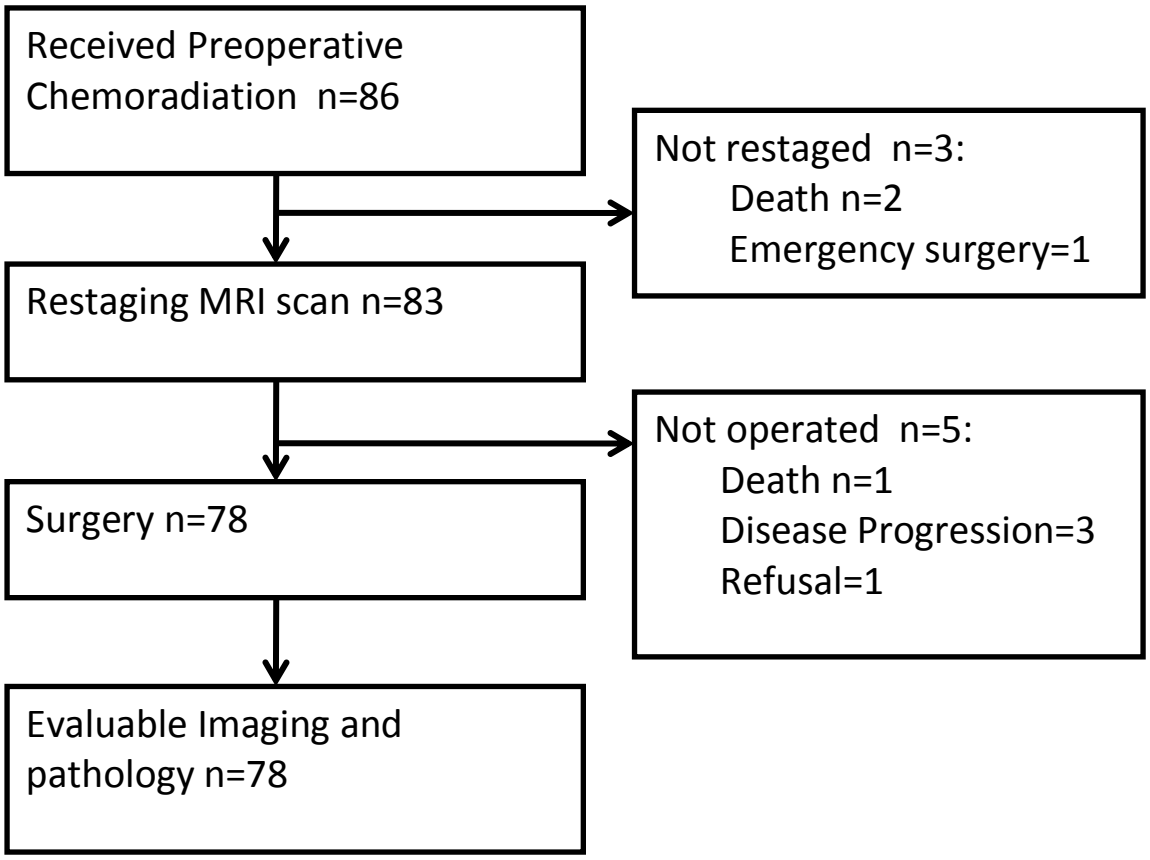

5.3.2 Eligibility

The treatment group comprised only patients that were considered at risk of circumferential resection margin (CRM) involvement based on baseline preoperative MRI staging. This was defined as tumour within 2 mm of the mesorectal fascia, or any mrT3/T4 tumour arising at <5 cm from the anal verge. Patients with distant metastatic disease on clinical examination and computed tomography (CT) of chest, abdomen, and pelvis were excluded. Patients were also excluded if they had a history of pelvic malignancy, pelvic radiotherapy, or pelvic floor surgery for faecal incontinence or rectal prolapse.

5.3.3 Preoperative treatment

Patients received preoperative treatment with Oxaliplatin, Capecitabine, and radiotherapy (XELOX-RT). Chemoradiation therapy comprised 45 Gy RT (1.8 Gy/dose) 5 days/wk for 5 wks, weekly Oxaliplatin 50 mg/m^2, and twice-daily Capecitabine 825 mg/m^2 on each day of RT. Patients were restaged using high resolution pelvic MRI 6-8 weeks post chemoradiation therapy.

5.3.4 MRI technique

MRI was performed with 1.5 T whole body MR image systems with a pelvic phased array coil according to chapter 3.

5.3.5 MRI image analysis

The terms ymrT (T stage on MRI images obtained after CRT), mrTRG (tumour regression grade on MRI images obtained after CRT), mrRECIST (modified RECIST based on tumour length on baseline and MRI images obtained after CRT), ypT (T stage on post treatment histopathological examination of the resection specimen) and pTRG (tumour regression grade on post treatment histopathological examination of the resection specimen) are used to describe the data.

Images were prospectively read by central and local investigators for mrRECIST and ymrT. Percentage Volume reduction and mrTRG were retrospectively read by the central and second reviewer.

5.3.5.1 T stage post CRT

ymrT assessment was based on identification of persistent tumour signal intensity relative to the layers of bowel wall on T2 weighted images. Comparison was made with the pre-treatment images. Tumour response manifested as either replacement of tumour signal by low signal intensity fibrosis or the development of high signal intensity mucin pools -such areas where not considered as tumour and did not contribute to T stage. ymrT staging criteria was the same as baseline MRI T staging (this was detailed in section 4.2.7).

Based on known histopathological outcomes according to ypT stage and along similar lines to other studies, ymrT stage was divided into favourable and unfavourable response to enable binary comparison. Favourable regression was defined as stages ymrT0,1,2, and 3a, while unfavourable grading was defined as ymrT3b,c,d and 4 (Willett, Badizadegan et al. 1999).

5.3.5.2 MRI tumour regression grading

The MRI scans were anonymised and separately reviewed by two radiologists with 14 (GB) and 5 (UBP) years experience in MRI assessment of rectal cancers using the previously defined criteria in Table 1.6. Figure 5.2 illustrates the MR tumour regression system.

Good MRI tumour regression grade was defined as grades 1,2 and 3 with poor defined as stages 4 and 5. This binary division was chosen as per chapter 4 results.

Figure 5.2. mrTRG1-5

mrTRG1
A) Axial baseline images showing a semiannular tumour as intermediate signal intensity in the posterior rectal wall between the 3'o' clock to 9'o'clock position.
B) Axial post treatment image shows a fibrotic low signal scar at 6'o'clock, there is high signal intensity submucosal oedema, absence of any tumour signal indicates an mrTRG1.

A) B)

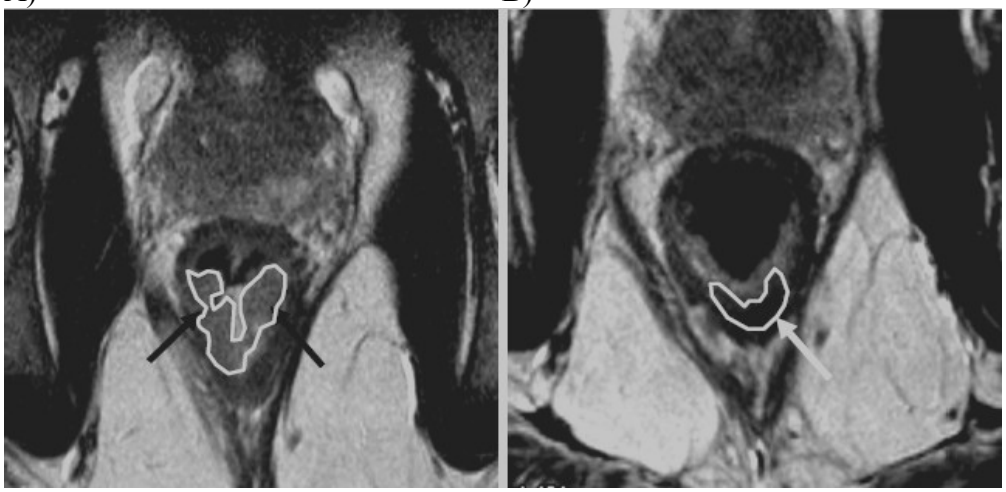

mrTRG2

C) Coronal baseline images show a semiannular tumour centered at the 9'o'clock position (arrow).

D) Coronal post treatment image shows a fibrotic low signal scar at 9'o'clock. A small amount of residual tumour remains inferior to the scar (white arrow), therefore there is predominant scar signal intensity post treatment with minimal residual tumour indicating mrTRG2.

C) D)

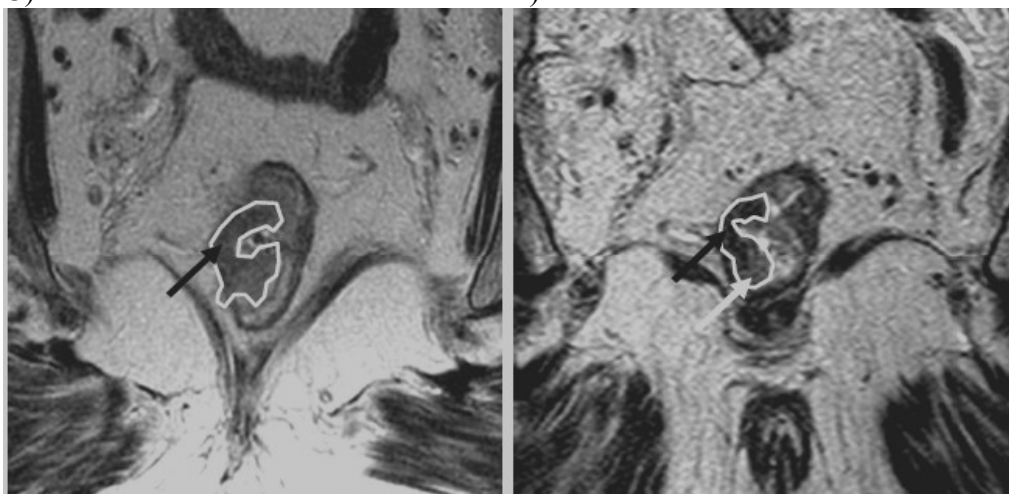

mrTRG3

E) Axial baseline image shows tumour centred at the 12'o'clock position (arrows), infiltrating through the anterior rectal wall.

F) Axial post treatment image show mixed areas of low signal fibrosis and intermediate signal intensity indicating mrTRG 3 (arrow).

E) F)

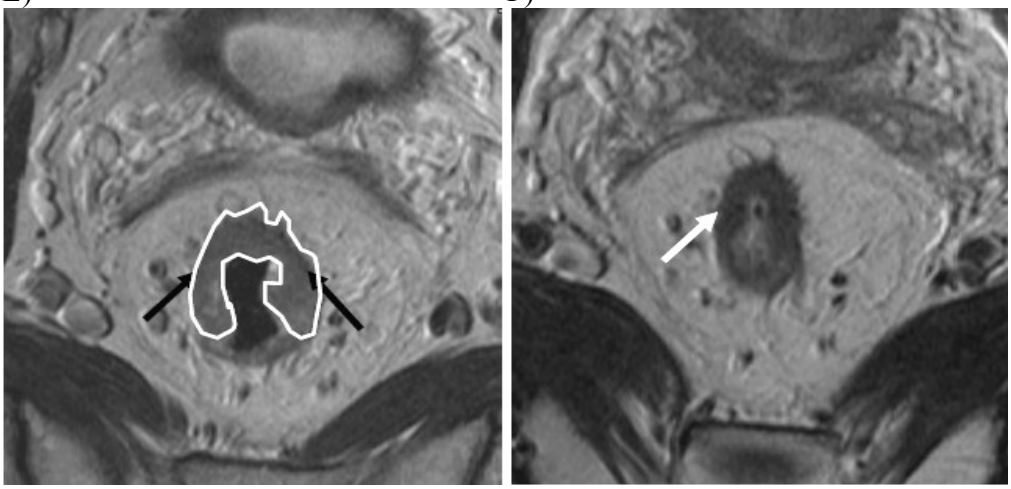

mrTRG4
G) Axial baseline images show an annular infiltrating tumour (black arrows).
H) Axial post treatment images shows persistent intermediate signal intensity tumour with minimal low signal fibrosis (white arrow), therefore tumour signal intensity predominates in keeping with mrTRG 4.

G) H)

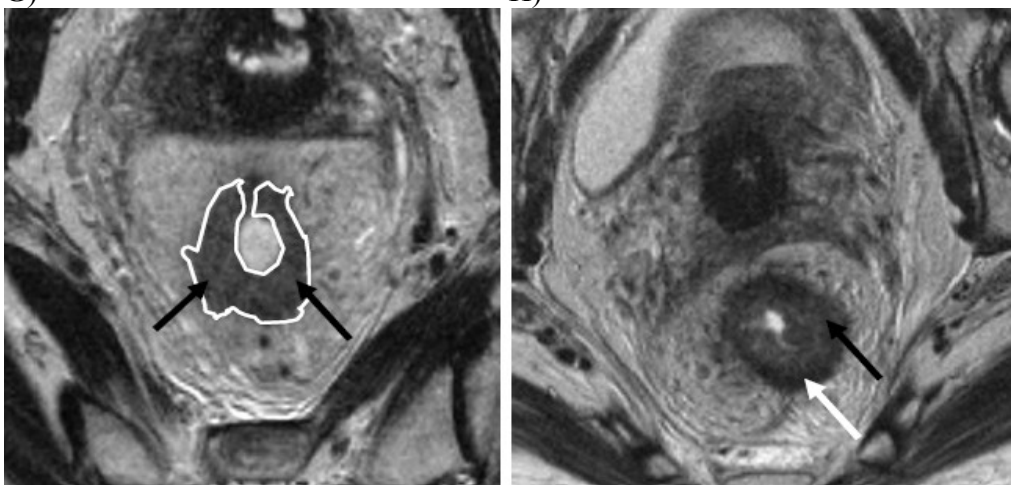

mrTRG5
I) Axial baseline images show an annular tumour (black arrow), with extramural extension at the 3'o'clock position (white arrow).
J) Axial post treatment images show little response compared with the baseline scan, MR TRG5

I) J)

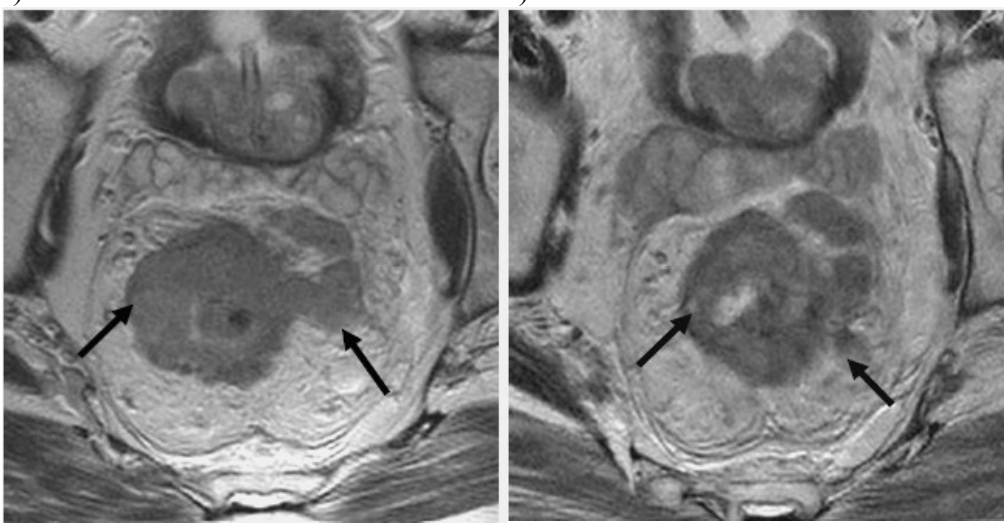

5.3.5.3 MRI modified RECIST

Maximum tumour length was measured on sagittal images pre and post treatment. Percentage change in tumour length was classified using RECIST criteria with complete disappearance of tumour being defined as complete response. Partial response to treatment was defined as at least a 30% decrease in tumour length, taking as reference the baseline tumour length. Progression of disease was defined as at least a 20% increase in tumour length, stable disease was defined as neither sufficient shrinkage to qualify for partial response nor sufficient increase to qualify for progression of disease (Therasse, Arbuck et al. 2000). For the analysis partial response was categorised as favourable, while stable disease or progression of disease was unfavourable.

5.3.5.4 MRI volumetric analysis

MRI scans were assessed using previously defined criteria; (Barbaro, Fiorucci et al. 2009) an axial slice was selected where the tumour had maximal dimensions. The length and width of the tumour was measured on this slice. Maximal height was measured on a sagittal section. Tumour volume was obtained by multiplying tumour length, width and height. Percentage volume reduction, was defined as 100* [(Volume baseline-Volume post CRT)/Volume baseline)]. Volume reduction rates were categorised into three groups (≤60%, 60–80%, and ≥80%), according to previous criteria (Yeo, Kim et al. 2010).

5.3.6 Surgery

Total mesorectal excision with or without abdominoperineal excision was performed 6-8 weeks after the completion of CRT. This time is based on the only randomised controlled trial to investigate timing of surgery post CRT (Francois, Nemoz et al. 1999).

5.3.7 Histopathological assessment

After surgical resection, the specimen was fixed in formalin for 48 hours, cross sectioned into 3-5 mm slices and histologically sampled. There was a defined a pathologic protocol to classify pCR; Firstly the whole area of the tumour was embedded, and at least five blocks were sampled including at least one large block. If tumour cells could not be found on initial examination, three levels were taken and examined from each tumour block. If after these assessments no tumour cells were indentured then the tumour was considered to have undergone a complete pathologic response.

5.4 Statistics

5.4.1 Grouping of pathological endpoints

As well as grading and staging by the 5 point pTRG (Dworak, Keilholz et al. 1997) and ypTNM version 5 systems, a simplified pathological grading of favourable and unfavourable pathology was also undertaken. Favourable pathology was defined as ypT stages 0, 1, 2 and 3a or pTRG stages 3 and 4, while unfavourable pathology was defined as ypT stages 3b, c, d and 4 or pTRG stages 0,1,and 2. ypT3a was included in the favourable group as these tumours have been shown to have a similar prognostic outcome as ypT2 tumours (Willett, Badizadegan et al. 1999).

The area under the ROC was used to indicate the diagnostic accuracy of MRI parameters (details below) and was classified as follows: 0.9-1=excellent, 0.8-0.9=good, 0.7-0.8=fair, 0.6-0.7=poor, 0.5-0.6=fail.

Kappa analysis was also used and defined as follows; $\kappa < 0$, poor agreement; $\kappa = 0–0.20$, slight agreement; $\kappa = 0.21–0.40$, fair agreement; $\kappa = 0.41–0.60$, moderate agreement; $\kappa = 0.61–0.80$, substantial agreement; and $\kappa = 0.81–1.00$, almost perfect agreement.

Central reviewer data was used for analysis. Agreement between the two observers grading categorical variables (ymrT, mrTRG, change in volume and mrRECIST) was also determined by kappa calculation. Calculations were performed using Statistical Package for Social Sciences program, version 15.0 (SPSS, Chicago, Illinois, USA). P values of less than 0.05 were considered significant.

5.4.2 mrTRG analysis

ROC analysis was used to calculate the diagnostic accuracy of the mrTRG with the binary pathological outcome measure of favourable and unfavourable T stage pathology. ROC analysis was also used to assess any relationship between mrTRG and favourable and unfavourable TRG.

5.4.3 ymrT analysis

Cohen's Kappa was used to analyse the association between ymrT and pathological T stage. ROC analysis was also used to assess any relationship between ymrT and favourable and unfavourable TRG

5.4.4 MRI modified RECIST and MRI Volumetric Analysis.

The Mann-Whitney U test was used to assess if there was a significant difference between the Sum of Ranks of favourable and unfavourable mrRECIST scores. Similarly the Kruskal Wallis one way analysis variance test was used to assess if there was a significant difference between the three volume reduction rates distributions.

5.4.5 Univariate logistic regression

Univariate logistic regression analysis was undertaken to analyse the association between demographic variables (patient age and sex), type of operation, MRI parameters divided into favourable and unfavourable groups (ymrT, mrTRG, change in volume, mrRECIST) and pathologic tumour response (in terms of ypT and pTRG). This enabled calculation of odds ratios for the probability of an unfavourable pathological outcome.

5.5 Results

Table 5.1 shows the baseline demographics of the patients who were eligible for this study. The mean baseline tumour length was 5.32cm; standard deviation (SD) 1.83cm. The mean baseline tumour volume was 58.13 (SD 80.03cm^3). The mean post treatment tumour length was 3.55 (SD 1.37cm^3) and the mean post treatment tumour volume was 17.43 (SD 19.92cm^3). The mean tumour length change was -31.57% (SD 20.95%) and the mean tumour volume reduction rate was -62.76% (SD 34.39%).

Table 5.1. Patient characteristics of patients with full imaging and pathology n=78

		No of patients
Age:	<65 years	52
	≥65 years	26
Sex:	Male	58
	Female	20
Height of primary tumour (from anal verge):	Low (0-5 cm)	51
	Medium/High (≥5-10 cm)	27
Tumour stage at baseline on MR:	T2	11
	T3a	6
	T3b	15
	T3c	21
	T3d	16
	T4	6
	Poor image quality	3
Tumour stage post CRT on MR (ymrT) Central r/v:	T0	9
	T1	3
	T2	10
	T3a	8
	T3b	13
	T3c	21
	T3d	4
	T4	5
	Missing	5
Tumour regression grade on MR (mrTRG) Central r/v:	TRG1	6
	TRG2	27
	TRG3	14
	TRG4	20
	TRG5	2
	Missing	9
Modified MR RECIST Central r/v:	Partial response	46
	Stable disease	26
	Progression	0
	Missing	6
Volume change Central r/v:	>-80% to 100%	20
	≥- 60% to ≤-80%	25
	≥0% to <-60%	23
	Missing	10
Post operative T stage pathology (ypT): n=78	T0	11
	T1	4
	T2	13
	T3a	6
	T3b-d	40
	T4	4
Post operative TRG	Favourable	27
	Unfavourable	51

5.5.1 mrTRG results

Table 5.2 shows the ypT histopathology status of patients by individual mrTRG grade. Table 5.3 shows simplified ypTRG status by individual mrTRG grade. ROC analysis was undertaken to calculate the area under the ROC curve (AUC). Figure 5.3 shows the ROC analysis for mrTRG vs. both T stage pathology and pathological TRG. The AUC is 0.82 for ypT, indicating mrTRG has a good diagnostic accuracy for T stage pathology. The AUC for mrTRG vs. TRG pathology was 0.77 indicating a fair diagnostic accuracy. Section 5.8 shows raw data tables indicating grouping mrTRG stages 1-3 as favourable and mrTRG stages 4&5 as unfavourable gives the highest possible sensitivity and specificity for both pathological endpoints.

Table 5.2. Histopathological T stage by individual mrTRG grade

		Pathological T stage					
		T0	T1	T2	T3a	T3b-d	T4
mrTRG	1	1		2		3	
	2	8	4	9	2	4	
	3			1	2	11	
	4				2	17	1
	5					2	
	Missing	2	0	1	0	3	3

Table 5.3. mrTRG vs. Pathological Tumour Regression Grade

		pTRG favourable (pTRG3&pTRG4)	pTRG unfavourable (pTRG0, 1& 2)
mrTRG	1	3	3
	2	17	10
	3	1	13
	4	1	19
	5	1	1
		Missing n=9	

Figure 5.3. mrTRG ROC analysis

A, mrTRG vs. Pathological T stage
B, mrTRG vs. Pathological TRG

A

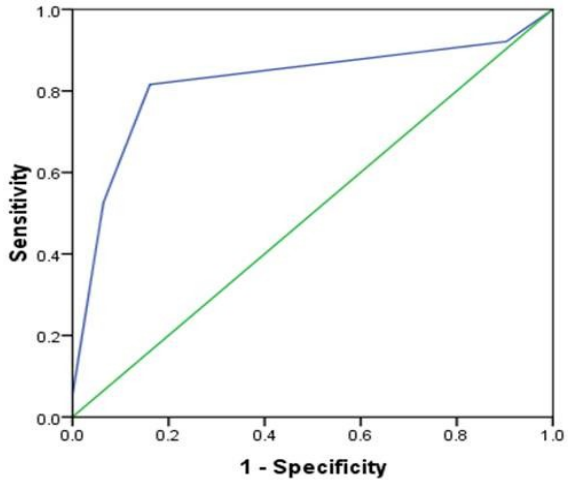

Area	Std. Error[a]	95% Confidence Interval	
		Lower Bound	Upper Bound
.821	.054	.714	.928

B

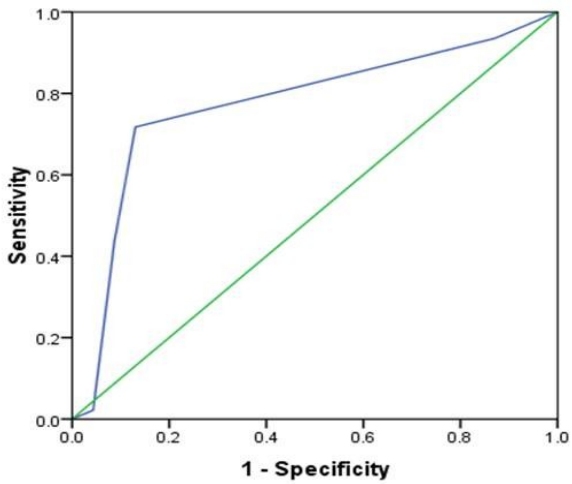

Area	Std. Error[a]	95% Confidence Interval	
		Lower Bound	Upper Bound
.772	.062	.650	.894

5.5.2 Post CRT ymrT results

Cohen's kappa analysis showed a fair level of agreement between ymrT and pathological T stage with Cohen's kappa=0.33, standard error 0.069. Table 5.4 shows the raw data used for this calculation.

Table 5.4 Histopathological T stage by individual ymrT stage

		Pathological T stage					
		T0	T1	T2	T3a	T3b-d	T4
ymrT	ymrT0	3	1	3		2	
	ymrT1		1	2			
	ymrT2	3	1	2	2	2	
	ymrT3a	1		3	2	2	
	ymrT3b	1		2		10	
	ymrT3c	2				17	2
	ymrT3d					4	
	ymr4		1		2	1	1
	Missing	1	0	1	0	2	1

ROC analysis was undertaken to assess the relationship between ymrT and pathological tumour regression grade. Figure 5.4 shows the ROC analysis, Table 5.5 shows the raw data. The area under the ROC curve (AUC) is 0.78, 95% confidence limits (0.65-0.91), indicating ymrT has a fair diagnostic accuracy for TRG pathology.

Figure 5.4. ROC analysis of ymrT vs. Binary Pathological Regression Grade

Table 5.5. ymrT Vs. Pathological Tumour Regression Grade

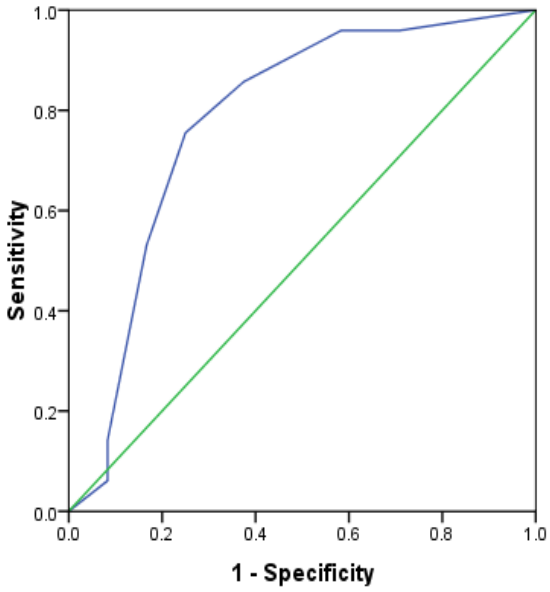

		pTRG good (pTRG3 pTRG4)	pTRG poor (pTRG0 pTRG1 pTRG2)
ymrT	ymrT0	7	2
	ymrT1	3	
	ymrT2	5	5
	ymrT3a	3	5
	ymrT3b	2	11
	ymrT3c	2	19
	ymrT3d		4
	ymr4	2	3

Missing n=5

5.5.3 MRI modified RECIST analysis

Table 5.6 shows the distribution of MRI RECIST scores across the different pathological T stages. Figure 5.5 graphically displays the same data, with individual pathological T stages as the y axis and frequency as the x axis. The blue bars show those with a MRI RECIST partial response, while the green bars show MRI RECIST stable disease/progression. The figure shows the data to be distributed non-parametrically.

Table 5.6. MRI RECIST vs. Pathological T stage

		Pathological T stage					
		T0	T1	T2	T3a	T3b-d	T4
MR RECIST	Partial Response	7	3	12	3	20	1
	Stable/ Progression	3	1	0	3	17	2

Missing n=6

Figure 5.5 Histogram showing distribution of MRI RECIST data by T stage pathology

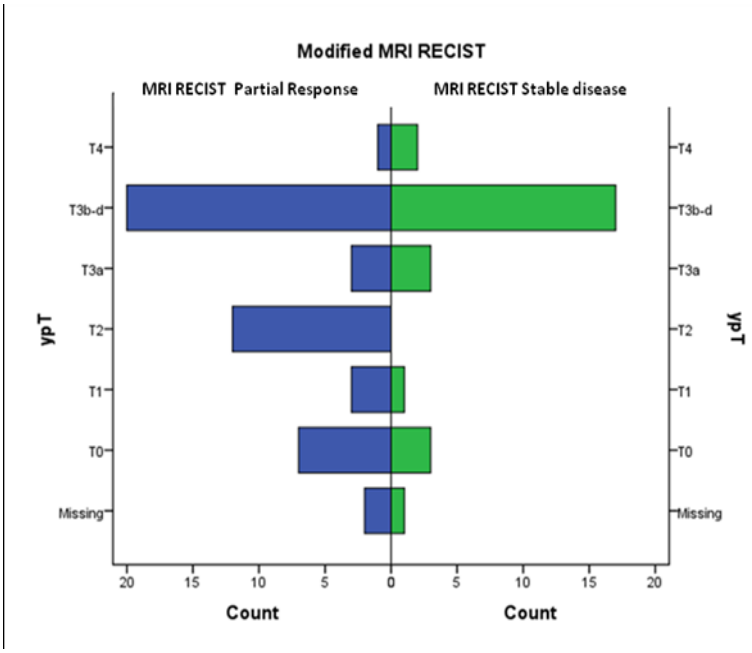

The Mann-Whitney U test calculation was performed to assess if there was a difference between the Sum of Ranks between the Partial Response MRI group and the Stable Disease MRI group. A significant difference (p=0.025) was found between the MRI partial response group and the MRI Stable disease group. This is shown in table 5.7.

Table 5.7. Mann-Whitney U test results for MRI RECIST and T stage pathology

Modified MRI RECIST	n	Mean Rank	Sum of Ranks	Test Statistic
Partial response	46	32.64	1501.50	p=0.025
Stable disease/Progression	26	43.33	1126.50	

5.5.4 MRI Volumetric Analysis

Table 5.8 shows the distribution of data between the three MRI Volume groups and different pathological T stages. Group 1 80% to 100% volume reduction, Group 2 60% to 80% volume reduction , Group 3 no change in volume up to 60% volume reduction). Figure 5.6 graphically displays the same data, with individual pathological T stages as the x axis and frequency as the y axis.

Table 5.8. MRI Volume Change vs. Pathological T stage

		Pathological T Stage					
		T0	T1	T2	T3a	T3b-d	T4
MRI Volume change	>-80% to 100%	2	2	7	1	8	
	≥- 60% to ≤-80%	6	2	3	2	11	1
	≥0% to <-60%	1		2	3	17	

Missing n=10

Figure 5.6 MRI Volume Groups and Pathological T stage

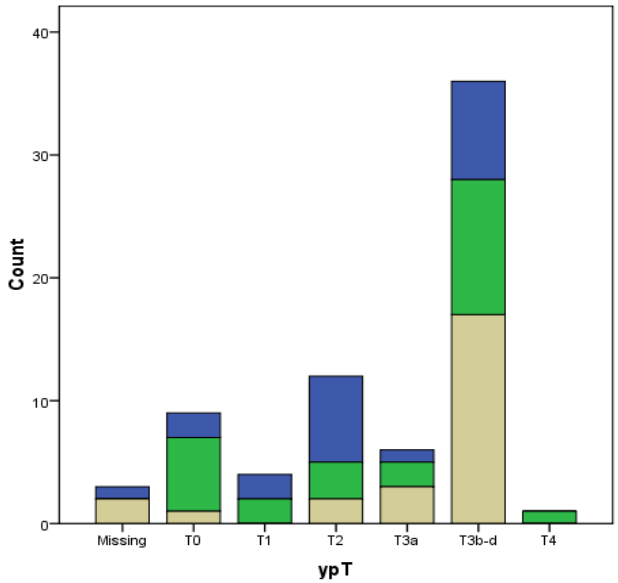

Blue = 80% to 100% volume reduction group, Green = 60% to 80% volume reduction group
Beige = No change in volume to 60% volume reduction group

The Kruskal Wallis One-Way Analysis of Variance was used as the data was distributed in a non-parametrically. A borderline significant difference (p=0.05) was found between the Mean Ranks between the three MRI volume change groups. This is shown in table 5.9.

Table 5.9. Kruskal Wallis Analysis of MRI Volume Change vs. T stage pathology

		n	Mean Rank	Test Statistic
Volume change	>-80% to 100%	20	29.70	p=0.05
	≥- 60% to ≤-80%	25	31.24	
	≥0% to <-60%	23	42.22	

5.5.5 Univariate binary logistic regression results

Table 5.10 shows the ypT histopathology status of patients by age, sex, operation, mrTRG, ymrT, mrRECIST, and volume change. Patients with mrTRG stage 4-5 were significantly associated with unfavourable pathology (20/22), compared with mrTRG stage 1-3 (18/47); p=0.001; OR 16.11 (3.36-77.29). Furthermore, ymrT stage T3b-4 was significantly associated with unfavourable pathology (35/43), compared with ymrT stage T0-T3a (6/30); p=0.001; OR 17.50 (95% CI 5.38-56.89).

mrRECIST stable disease/progression was significantly associated with unfavourable pathology (19/26), compared with partial response (21/46); p=0.028; OR 3.23 (95% CI 1.14-9.17). No change to a 60% decrease in volume was significantly associated with unfavourable ypT (17/23), compared with an 80-100% decrease in volume (8/20); p=0.028; OR 4.25 (95% CI 0.92-15.45).

Table 5.11 shows the TRG histopathology status of patients by age, sex, operation, mrTRG, ymrT, mrRECIST and volume change. As with ypT significantly more patients with mrTRG stage 4-5 had unfavourable pathology (20/22), compared with mrTRG stage 1-3 (26/47); p=0.009; OR 7.98 (95% CI 1.66-38.29). Furthermore, significantly more patients with ymrT stage T3b-4 had unfavourable pathology (37/43), compared with ymrT stage T0-T3a (12/30); p=0.001; OR 9.25 (95% CI 3.00-28.64). Borderline statistical significance was seen for age. No significant relationship was shown for either mrRECIST or volume change and pathological TRG.

5.5.6 Interobserver agreement

There was a moderate level of agreement for mrTRG (49 cases reviewed κ =0.55 SE=0.11). A moderate level of agreement was also calculated for ymrT (76 cases κ =0.41 SE=0.11). For ymrT and mrTRG disagreements between the central reviewer and second reviewer were in the identification of favourable responders, with the central reviewer classifying more patients as good responders (see Table 5.12). There was fair agreement for change in

tumour volume on MRI (64 cases reviewed κ =0.27 SE=0.08). There was slight agreement for mrRECIST (64 cases reviewed κ = 0.13 SE=0.12).

Table 5.10. ypT pathology status by clinical and MRI parameters

	ypT0-T3a	ypT3b-4	OR (95% CI)	P value
Age				
<65 years	20	32	1.00	0.19
≥65 years	14	12	0.54 (0.21-1.39)	
Sex				
Male	27	31	1.00	0.37
Female	7	13	1.62(0.56-4.64)	
Operation				
TME	22	34	1.00	0.22
APR	12	10	0.54(0.19-1.46)	
mrTRG Central r/v				
1-3	29	18	1.00	0.001
4-5	2	20	16.11 (3.36-77.29)	
Missing n=9				
ymrT Central r/v				
T0-T3a	24	6	1.00	0.001
T3b-4	8	35	17.50 (5.38-56.89)	
Missing n=5				
mrRECIST				
Partial Response	25	21	1.00	0.028
Stable/ Progression	7	19	3.23 (1.14-9.17)	
Missing n=6				
Volume change				
>-80% to 100%	12	8	1.00	
≥- 60% to ≤-80%	13	12	1.39 (0.42-4.55)	0.59
≥0% to <-60%	6	17	4.25 (0.92-15.45)	0.028
Missing n=10				

Table 5.11. TRG pathology status by clinical and MRI parameters

	TRG good (3,4)	TRG poor (0,1,2)	OR (95% CI)	P value
Age				
<65 years	14	38	1.00	0.047
≥65 years	13	13	0.37 (0.14-0.99)	
Sex				
Male	23	35	1.00	0.12
Female	4	16	2.63 (0.78-8.86)	
Operation				
TME	20	36	1.00	
APR	7	15	1.19 (0.42-3.40)	0.75
mrTRG Central r/v				
1-3	21	26	1.00	0.009
4-5	2	20	7.98 (1.66-38.29)	
Missing n=9				
ymrT Central r/v				
T0-T3a	18	12	1.00	0.001
T3b-4	6	37	9.25 (3.00-28.64)	
Missing n=5				
mrRECIST				
Partial Response	18	28	1.00	0.14
Stable/ Progression	6	20	2.23 (0.78-6.38)	
Missing n=6				
Volume change				
>-80% to -100%	8	12	1.00	
≥-60% to ≤-80%	10	15	1.09 (0.33-3.67)	0.89
≥0% to <-60%	5	18	2.33 (0.60-9.02)	0.22
Missing n=10				

Table 5.12. Interobserver agreement of MRI parameters

Table 5.4A. mrTRG agreement

	Central r/v		
2nd reader r/v		Favourable	Unfavourable
	Favourable	24	0
	Unfavourable	11	14

κ =0.55, SE=0.11, n=49.

Table 5.4B. ymrT agreement

	Central r/v		
Local reader r/v		Favourable	Unfavourable
	Favourable	15	5
	Unfavourable	16	40

κ =0.41, SE=0.11, n=76.

Table 5.4C. mrRECIST agreement

	Central r/v		
Local reader r/v		Favourable	Unfavourable
	Favourable	25	13
	Unfavourable	15	13

κ =0.13, SE=0.12, n=66.

Table 5.4D. Volumetric analysis agreement

	Central r/v			
Local reader r/v		>80% reduction	60-80% reduction	<60% reduction/ unchanged
	>80% reduction	16	15	4
	60-80% reduction	1	3	5
	<60% reduction/unchanged	2	5	13

κ =0.27, SE=0.08, n=64.

5.6 Discussion

This study assessed the relationship between ymrT staging, mrTRG, change in volume and modified RECIST agreement with the pathology standards of ypT and pTRG.

Using ROC analysis mrTRG had a good diagnostic accuracy for T stage pathology and a fair diagnostic accuracy for TRG pathology. A combination of ROC and kappa analysis showed ymrT had a good diagnostic accuracy for TRG pathology and a fair level of agreement with pathological T stage. Binary logistic regression analysis showed that grouped ymrT and mrTRG assessment showed a statistically significant relationship with both histopathological parameters.

The Mann-Whitney U test showed a significant difference between the Sum of Ranks for the MRI partial response group and the MRI Stable disease group, while a borderline significant difference was found between MRI volume change groups using the Kruskal Wallis test. Binary logistic regression analysis showed both RECIST measurements and volume reduction of >80% had odds ratios of 3.23 and 4.25 respectively for a good ypT score, however no relationship was observed with histopathological TRG. Furthermore, the interobserver agreement for RECIST and MRI volume measurements was only slight and fair compared with better, moderate interobserver agreement for mrTRG and ymrT staging.

The binary logistic regression analysis suggests the strength of the relationship of mrTRG and ymrT with histopathology is stronger than RECIST and volume measurements. No previous studies investigating volume measurement and final pathology have formally compared these endpoints against other MRI parameters such as ymrT and mrTRG assessment (Yeo, Kim et al. 2010),(Dresen, Beets et al. 2009),(Kang, Kim et al. 2010), this is an important area for future research.

A potential limitation of the present study is that tumours were not outlined slice-by-slice on a workstation to calculate volume. However, as previously noted, there is no published evidence for the superiority of a workstation based volume assessment compared with conventional three dimensional estimation of tumour volume in rectal cancer. A further possible limitation is that not all MR parameters were measured for all 78 patients, nevertheless 87 % (68/78) had complete data indicating that our results are likely to be representative of the population studied.

5.7 Conclusion

Overall mrTRG and ymrT staging showed fair/good levels of diagnostic accuracy compared to MRI length and volume assessment. MR RECIST analysis also showed a significant difference between the MRI partial response group and the MRI Stable disease group. These parameters appear useful in response assessment although the level of agreement with pathological endpoints is fair/good rather than excellent.

5.8 Raw data tables

Table 1. mrTRG cut-off for T stage pathology

mrTRG	Sensitivity(%)	Specificity(%)
mrTRG1 vs. mrTRG 2-5	92.1	9.7
mrTRG1&2 vs. mrTRG 3-5	85.5	60.0
mrTRG1-3 vs. mrTRG 4&5	81.6	83.9
mrTRG1-4 vs. mrTRG 5	52.6	93.5

Table 2. mrTRG cut-off for Tumour regression grade pathology

mrTRG	Sensitivity(%)	Specificity(%)
mrTRG1 vs. mrTRG 2-5	93.5	13.0
mrTRG1&2 vs. mrTRG 3-5	87.3	58.6
mrTRG1-3 vs. mrTRG 4&5	71.7	87.0
mrTRG1-4 vs. mrTRG 5	43.5	91.3

6 MRI detected tumour response for locally advanced rectal cancer and survival outcomes

6.1 Introduction

In rectal cancer, long course radiotherapy or preoperative combination chemoradiotherapy together with total mesorectal excision surgery (TME) surgery has been associated with improved curative surgery rates and reduced local recurrence (Kapiteijn, Marijnen et al. 2001). As discussed in 1.54-1.57 MRI enables appropriate selection of patients based on assessment of locally advanced disease and the relationship of tumour to the potential resection margin (Brown, Richards et al. 1999).

Assessment of treatment efficacy normally relies on histopathology after the tumour has been resected. Pathology studies have shown that in assessment of irradiated specimens, post treatment T and N stage (ypT and ypN) can predict local recurrence, disease free survival and overall survival (Capirci, Valentini et al. 2008). The pathological Dworak tumour regression grading system (pTRG) (Dworak, Keilholz et al. 1997; Wheeler, Warren et al. 2002) has also been shown to predict overall survival and is considered to be an important prognostic predictor for disease free survival (Vecchio, Valentini et al. 2005).

High resolution MRI has been used to assess tumour response prior to surgical resection. To date all studies have compared MRI assessment with pathology, the relevance of post treatment MRI assessment in predicting survival outcomes has not been investigated. Furthermore, by applying the principles of histopathology grading and exploiting the characteristic MRI low signal intensity appearances of fibrosis, it has been possible to develop a similar MRI based tumour regression grading system as well as refinement of T and N staging and CRM assessment post chemoradiation (Chapter 4).

In 2002, the MERCURY prospective study evaluated the diagnostic accuracy MRI staging in a consecutive series of patients with biopsy proven rectal cancer undergoing TME surgery with histopathology as the reference standard. The 5 year follow-up of this cohort was completed in December 2008. This chapter reports a planned subgroup analysis of post treatment MRI scan parameters and survival outcomes of patients enrolled in this study (MERCURY 2006).

6.2 Aims

In chapters 4 and 5, it was observed that grouped MRI based tumour regression grading system as well as grouped post treatment MRI T staging showed statistically significant correlation with pathological endpoints. Favourable correlation between node negative MRI and node negative pathology as well as circumferential resection margin clearance and pathology was also observed. Overall diagnostic performance of mrTRG and ymrT was good and fair respectively, with neither factor showing an excellent diagnostic accuracy vs. pathology.

Therefore, the aim of this analysis was to evaluate the prognostic relevance, as judged by overall survival, disease free survival and local recurrence of post neoadjuvant therapy MRI assessment of tumour stage, nodal status, CRM and MRI tumour regression grading system in patients undergoing neoadjuvant therapy and TME surgery in the MERCURY study. Assessment of pathological, N and CRM involvement against outcome was also investigated.

6.3 Methods & Materials

6.3.1 Patients, recruitment, preoperative treatment and surgery

The background of the study was detailed in section 4.2:
Recruitment- including inclusion and exclusion criteria is summarised in section 4.2.2 and figure 4.1 (Trial progress flowchart).
Preoperative treatment and surgery details were also described in sections 4.2.3 and 4.2.4.

6.3.2 MRI assessment

A one day imaging workshop for specialist gastrointestinal radiologists participating in the study was held prior to recruitment in 2002 to ensure standardisation of scan acquisition techniques (section 3.2.1) and image interpretation prior to the study according to published criteria (Brown, Richards et al. 1999; Brown, Radcliffe et al. 2003; Brown, Davies et al. 2004). All scans were single-read by each investigating centre radiologist, with 5-15 years GI radiology experience.

T staging of tumour post treatment (ymrT) was based on interpretation of local extent of persistent tumour signal intensity relative to the layers of bowel wall on T2 weighted images as discussed in section 4.3.5.

Nodal stage post treatment was based on interpretation of lymph node border characteristics and signal intensity (Koh, Chau et al. 2008). A node was regarded as positive if either an irregular border or mixed signal intensity was demonstrated.

Post treatment MRI scans were also evaluated for predicted circumferential resection margin status (ymrCRM). A predicted clear circumferential resection margin was defined if the distance of intermediate signal tumour to the mesorectal fascia was greater than or equal to 1 mm on MRI, as discussed in section 4.2.7. For lower third rectal tumours, the definition of predicted ymrCRM involvement was tumour within 1mm of the levator muscle. If the tumour was present at or below the level of the puborectalis sling, the ymrCRM was predicted involved if there was invasion into the intersphincteric plane or beyond. The ymrCRM status was recorded prospectively in the study by each participating radiologist. When a post-treatment scan was not performed, the CRM at baseline was entered as CRM status. All MRI-assessed T, N, and CRM staging data were obtained prospectively by workshop trained radiologists.

6.3.2.1 MRI tumour regression grading

Of 111 patients undergoing preoperative therapy, 90 also underwent post treatment MRI before surgery. Sixty–six of 90 (73%) pre and post treatment scans were available for MRI TRG grading. MRI scans were anonymised and centrally reviewed by a radiologist with 14(GB) years experience in MRI assessment of rectal cancers using previously defined criteria (Brown, Chau et al. 2003).

In order to assess the reproducibility of the MRI TRG system, pre and post treatment scans were reviewed independently by 2 radiologists (CDG and HE) with 5-15 years experience in MRI staging of rectal cancers and compared with the central reviewer.

6.3.3 Histopathological assessment

After TME, the specimen was axially sectioned into 3-5 mm slices, as described by Quirke et al (Quirke, Durdey et al. 1986). A clear pCRM was defined as greater than, or equal to, 1 mm between the tumour and the resection margin. Eighteen pathologists, with 5-25 years experience in gastrointestinal pathology, evaluated specimens for the post treatment T and N stage ypT, ypN and circumferential margin status (pCRM).

6.4 Statistics

6.4.1 Grouping of data

Tumours were categorised into "good" and "poor" responders to enable binary comparison by multivariate analysis. mrTRG, ymrT, ymrN and ymrCRM as well as ypT, ypN and pCRM were grouped as discussed in section 4.1.1.

6.4.2 Follow-up

Patients were followed according to local protocols, typically this comprised outpatient assessment at three-monthly intervals for two years then six monthly for five years. Clinical follow up comprised physical examination, routine blood tests and yearly CT of the thorax, abdomen and pelvis. Histopathological confirmation of local and distant recurrences was sought when feasible. Surgical data included; date of operation, procedure performed and quality of the specimen. Date of enrolment, last follow-up, date of disease progression, date and cause of death were also prospectively collected. The presence of distant metastatic disease or local recurrence at the time of death was recorded as a rectal cancer specific death.

6.4.3 Analysis

Local recurrence was measured from date of original trial enrolment until local progression; disease free survival was measured from date of enrolment until progression at any site or death from any cause; patients who were alive and disease free were censored at last follow-up or death.

Cox proportional hazard models were used to analyse the effect on local recurrence, disease free and overall survival by preoperative MRI staging variables (ymrT, ymrN, ymrCRM and mrTRG) and pathological variables (ypT, ypN, pCRM). Other potential factors age, sex, type of surgery (Total mesorectal excision or Abdominoperineal resection with TME approach), tumour height (≤5cm or >5cm) and treatment (chemoradiation or long course radiation) were included in the multivariate analysis for each MRI/pathology staging variable. Survival curves were calculated using the Kaplan Meier product limit method and differences between survival curves were tested using the Univariate Log-rank test.

Agreement between the two observers grading mrTRG was determined by the kappa statistic. ($\kappa < 0$, poor agreement; $\kappa = 0$–0.20, slight agreement; $\kappa = 0.21$–0.40, fair agreement; $\kappa = 0.41$–0.60, moderate agreement; $\kappa = 0.61$–0.80, substantial agreement; and $\kappa = 0.81$–1.00, almost perfect agreement).

6.5 Results

Eighty-one of 111 patients (73%) were considered to have potential ymrCRM involvement prior to neoadjuvant therapy, this reduced to 47/111 (42%) after treatment. The number of mrT3c, T3d and T4 tumours reduced from 82/111 to 53/111. Table 6.1 shows demographic characteristics and survival outcomes of 111 patients included in the analysis. As of December 2008, surviving patients had been followed for a median of 50 months (range: 0.6-71 months). All 111 patients had evaluable post operative pathology and complete follow-up data. During the follow-up period 54 patients died, 40 died of cancer related causes, 5 non cancer deaths, 4 peri/post operative and in 3 patients the cause of death was unknown. Fifty patients had disease progression, 42 patients recurred with metastatic disease and 8 relapsed with local recurrence only.

Table 6.2 summarises the results of multivariate analysis of known clinical variables: age, sex, height of tumour from anal verge, type of preoperative treatment, and type of operation, according to each of the MRI preoperative staging variables and survival outcomes. mrTRG was significant for overall survival and disease free survival; hazard ratios were 4.40 (95% CI 1.65-11.7) and 3.28 (95% CI 1.22-8.80) respectively.

Overall survival at five years for poor mrTRG patients was 27% (95% CI 8-47%) compared with 72% (95% CI 56-88%) for good mrTRG patients (p=0.001 Univariate log-rank analysis). Disease free survival at five years for poor mrTRG patients was 31% (95% CI 13-49%) compared with 64% (95% CI 47-82%) for good mrTRG patients (p=0.007 Univariate log-rank analysis). This is illustrated in figures 6.1 and 6.2.

On multivariate analysis post treatment prediction of ymrCRM was significant for local recurrence. The hazard ratio for predicted involved ymrCRM and local recurrence was 4.25 (95% CI 1.45-12.51). The local recurrence rate at five years for predicted involved ymrCRM patients was 28% (95% CI 13-44%) compared with 12% (95% CI 3-22%) for predicted clear ymrCRM patients (p=0.013 univariate log-rank analysis).

On multivariate analysis post treatment prediction of ymrN showed borderline statistical significance for overall and disease free survival but was not significant for local recurrence; hazard ratios were 1.89 (95% CI 1.006-3.58) and 2.09 (95% CI 1.06-4.15) for OS and DFS respectively.

Table 6.3 summarises multivariate analysis results of the association between overall survival, disease free survival and time to local recurrence of known clinical variables: age, sex, height of tumour from anal verge, type of preoperative treatment, and type of operation, according to each of the histopathology staging variables. On multivariate analysis, ypT remained significant for overall survival, disease free survival and local recurrence; hazard ratios for poor ypT and OS, DFS and local recurrence were 4.59 (95% CI 2.16-9.78), 5.63 (95% CI 2.45- 12.9) and 9.78 (95% CI 2.29- 41.8) respectively. Kaplan Meier survival curves according to ypT stage are shown in figures 6.3 and 6.4.

The 5 year overall survival for patients with poor ypT was 39% (95% CI 26-51%) compared with 76% (95% CI 62-89%) for good ypT response (p=0.0001 Univariate log-rank analysis). The 5 year disease free survival for patients with poor ypT was 38% (95% CI 25-51%) compared with 84% (95% CI 72-96%) good ypT response (p=0.0001 Univariate log-rank analysis). The 5 year local recurrence rate was 27% (95% CI 14-40%) for patients with poor ypT compared with 6% (95% CI 0-15%) for good ypT response (p=0.018 Univariate log-rank analysis).

On multivariate analysis pCRM was significant for overall, disease free survival and local recurrence; hazard ratios were 2.99 (95% CI 1.64-5.47), 2.17 (95% CI 1.14- 4.13) and 8.80 (95% CI 2.99- 25.91) respectively.

The five year overall survival for pCRM involved patients was 30% (95% CI 10-49%) compared with 59% (95% CI 49-70%) for pCRM clear (p=0.001 Univariate log-rank analysis). The five year disease free survival for patients with involved pCRM was 28% (95% CI 7-50%) compared with 62% (95% CI 51-73%) for clear pCRM (p=0.023 Univariate log-rank analysis). The five year local recurrence rate was 56% (95% CI 30-83%) for patients with involved pCRM compared with 10% (95% CI 3-18%) for clear pCRM (p=0.0001 Univariate log-rank analysis).

ypN did not predict for any of the survival outcomes. The linear kappa between radiologists GB and CDG, was 0.65 (0.44-0.86), indicating moderate- to substantial agreement. The linear kappa between radiologists GB and HE was 0.6 (0.31-0.89), indicating moderate agreement.

Table 6.1. Patient demographics and survival outcomes in 111 patients undergoing preoperative therapy in the MERCURY study

		Frequency	OS, (95% CI)	DFS, (95% CI)	LR, (95% CI)
Age (years)	<65	49	58(43-72)	51(36-66)	21(8-35)
	≥65	62	49(36-62)	60(47-73)	16(6-27)
Sex	Male	69	49(37-62)	48(35-61) p=0.04	21(9-33)
	Female	42	59(44-74)	68(53-83) p=0.04	16(4-28)
Treatment	Long course	58	53(39-66)	53(39-67)	19(8-31)
	Chemo & RT	53	54(40-68)	58(44-72)	18(5-30)
Tumour height	> 5cm	59	49(35-62)	52(37-66)	17(5-30)
	≤ 5cm	52	57(44-71)	60(46-74)	21(8-33)
Operation	TMEAnterior resection	62	50(37-63)	51(37-64)	14(4-25)
	TME+AP excision	49	56(42-70)	62(47-76)	24(10-38)
Baseline MRI T stage	T1/T2	10	78(58-97) p=0.048	72(51-93)	13(0-31)
	T3a	8			
	T3b	11	49(38-60) p=0.048	51(40-63)	19(10-29)
	T3c	29			
	T3d	16			
	T4	37			
MR Node stage	N0	68	52(36-69)	56(38-73)	22(7-38)
	N1/N2	41	54(42-66)	54(42-66)	17(7-27)
	Missing	2			
yMR T stage	T0	6	73(54-92)	72(52-91)	20(2-38)
	T1/T2	13			
	T3a	3			
	T3b	14	48(35-60)	50(37-64)	16(6-27)
	T3c	24			
	T3d	8			
	T4	22			
	No post Tx MRI	21			
yMR Node stage	N0	50	61(47-76)	63(49-78) p=0.027	18(5-33)
	N1/N2	40	45(29-61)	46(29-63) p=0.027	17(3-32)
	Missing	21			
CRM baseline	CRM clear	30	N/A		
	CRM involved	81			
ymrCRM	CRM clear	55	59(46-71)	58(46-71)	12(3-22) p=0.013
	CRM clear baseline only	9			
	CRM involved	37	46(31-61)	51(35-67)	28(13-44) p=0.013
	CRM involved baseline only	10			
MRI TRG	MRTRG good	32	72(56-88) p=0.001	64(47-82) p=0.007	14(1-27)
	MRTRG poor	34	27(8-47) p=0.001	31(13-49) p=0.007	29(8-49)

	Missing	45			
ypT stage	T0	5	76(62-89) p=0.0001	84(72-96) p=0.0001	6(0-15) p=0.023
	T1	2			
	T2	25			
	T3a	9			
	T3b	20	39(26-51) p=0.0001	38(25-51) p=0.0001	27(14-40) p=0.023
	T3c	30			
	T3d	4			
	T4	16			
ypN stage	N0	67	56(43-68)	64(52-77)	16(6-26)
	N1/N2	44	48(33-64)	42(26-58)	77(61-93)
Pathology CRM	Clear	88	59(48-70) p=0.001	62(51-73) p=0.023	10(3-18) p=0.0001
	CRM Involved	23	30(10-49) p=0.001	28(7-50) p=0.023	56(30-83) p=0.0001

Table 6.2. Multivariate analysis preoperative factors, Data presented as Hazard ratios

	Post Rx mr T stage				Post Rx mr Node stage				mrTRG stage				Post Rx ymr CRM			
		OS	DFS	LR		OS	DFS	LR		OS	DFS	LR		OS	DFS	LR
MRI Variable	ymrT good	1	1	1	MR N-	1	1	1	MRTRG good	1	1	1	yMR CRM-	1	1	1
	ymrT poor	2.27	1.82	0.91	MR N+	1.89 § (1.006 -3.58)	2.09 §§ (1.06-4.15)	1.08	MRTRG Poor	4.40 *** (1.65-11.7)	3.28 * (1.22-8.80)	3.71	yMR CRM+	1.76	1.08	4.25 ††† (1.45-12.51)
Age	<65 years	1	1	1	<65 years	1	1	1	<65 years	1	1	1	<65 years	1	1	1
	≥65 years	1.48	0.88	0.59	≥65 years	1.58	1.01	0.61	≥65 years	1.46	0.98	0.65	≥65 years	1.57	0.93	1.10
Sex	Male	1	1	1	Male	1	1	1	Male	1	1	1	Male	1	1	1
	Female	0.88	0.59	0.931	Female	0.78	0.53	0.92	Female	0.70	0.67	0.80	Female	0.76	0.46† (0.24-0.89)	1.16
Treatment	Chemo & RT	1	1	1	Chemo & RT	1	1	1	Chemo & RT	1	1	1	Chemo & RT	1	1	1
	LCRT	0.98	0.93	0.99	LCRT	1.20	1.07	0.94	LCRT	0.69	0.69	0.41	LCRT	0.86	0.89	0.51
Operation	Anterior Resection	1	1	1	Anterior Resection	1	1	1	Anterior Resection	1	1	1	Anterior Resection	1	1	1
	AP excision	1.36	0.85	2.69	AP excision	1.24	0.83	2.75	AP excision	0.81	0.58	1.69	AP excision	0.99	0.56	2.05
Height from anal verge	>5cm	1	1	1	>5cm	1	1	1	>5cm	1	1	1	>5cm	1	1	1
	≤5cm	0.92	1.37	0.95	≤5cm	0.88	1.26	0.97	≤5cm	1.05	1.19	0.99	≤5cm	0.73	1.30	1.08

*** p=0.003 §p=0.048 ††† p=0.009
* p=0.019 §§p=0.033 †p=0.022

Table 6.3. Multivariate analysis histopathologic factors, Data presented as Hazard ratios

	Pathology T stage				Pathology N stage				Pathology CRM			
		OS	DFS	LR		OS	DFS	LR		OS	DFS	LR
Pathology Variable	yp T good	1	1	1	ypN -	1	1	1	pCRM -	1	1	1
	yp T poor	4.59*** (2.16-9.78)	5.63*** (2.45-12.9)	9.78*** (2.29-41.8)	ypN +	1.53	1.71	1.49	pCRM +	2.99*** (1.64-5.47)	2.17†† (1.14-4.13)	8.80*** (2.99-25.91)
Age	<65 years	1	1	1	<65 years	1	1	1	<65 years	1	1	1
	≥65 years	1.98†† (1.12-3.52)	1.32	1.37	≥65 years	1.49	0.97	0.91	≥65 years	1.74	0.98	1.65
Sex	Male	1	1	1	Male	1	1	1	Male	1	1	1
	Female	0.87	0.58	1.18	Female	0.68	0.44§§ (0.23-0.85)	0.82	Female	0.67	0.44†† (0.23-0.85)	0.85
Treatment	Chemo & RT	1	1	1	Chemo & RT	1	1	1	Chemo & RT	1	1	1
	LCRT	0.67	0.49† (0.26-0.94)	0.31§ (0.55-6.70)	LCRT	1.06	0.99	0.73	LCRT	0.93	0.87	0.61
Operation	Anterior Resection	1	1	1	Anterior Resection	1	1	1	Anterior Resection	1	1	1
	AP excision	1.04	0.63	1.91	AP excision	1.05	0.62	1.91	AP excision	0.86	0.51	1.48
Height from anal verge	>5cm	1	1	1	>5cm	1	1	1	>5cm	1	1	1
	≤5cm	1.41	2.02	2.62	≤5cm	0.92	1.37	1.33	≤5cm	1.02	1.42	1.65

*** p=0.001 §§ p=0.01 † p=0.03
§ p=0.04 †† p=0.02

Figure 6.1. mrTRG and overall survival

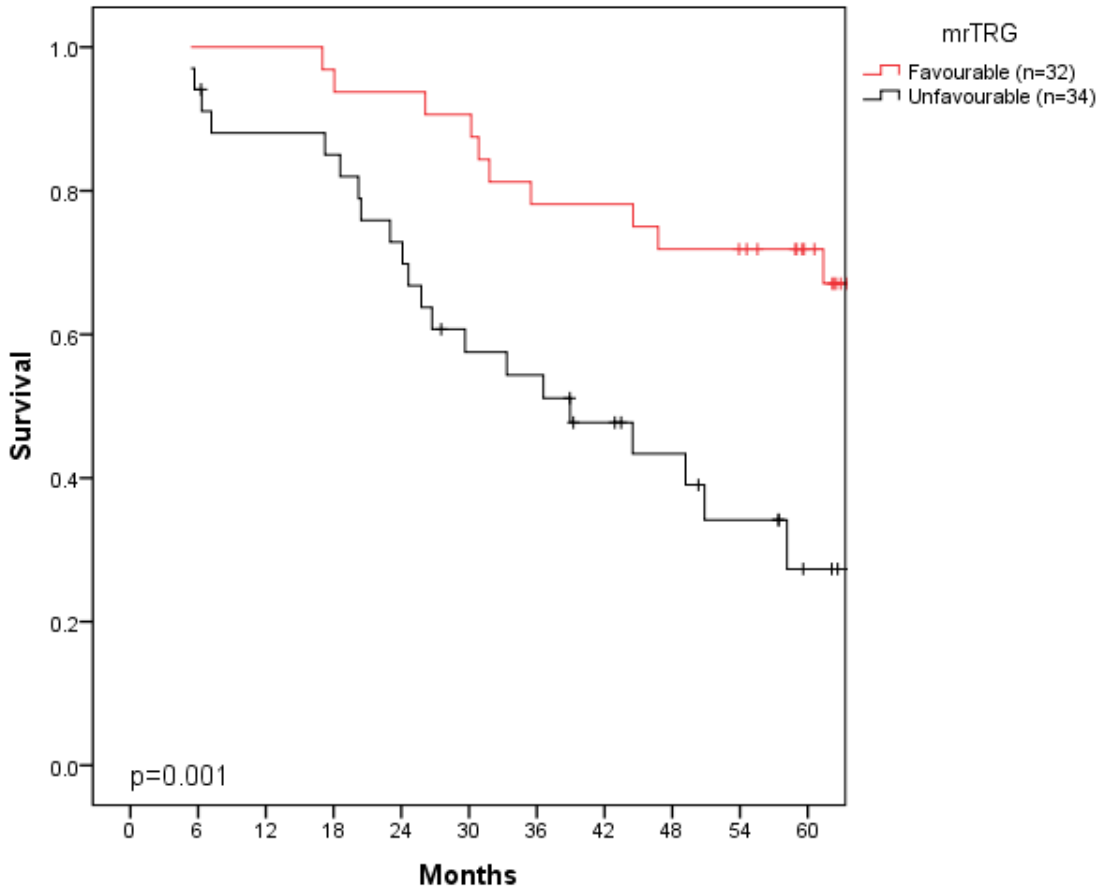

Figure 6.2. mrTRG and disease free survival

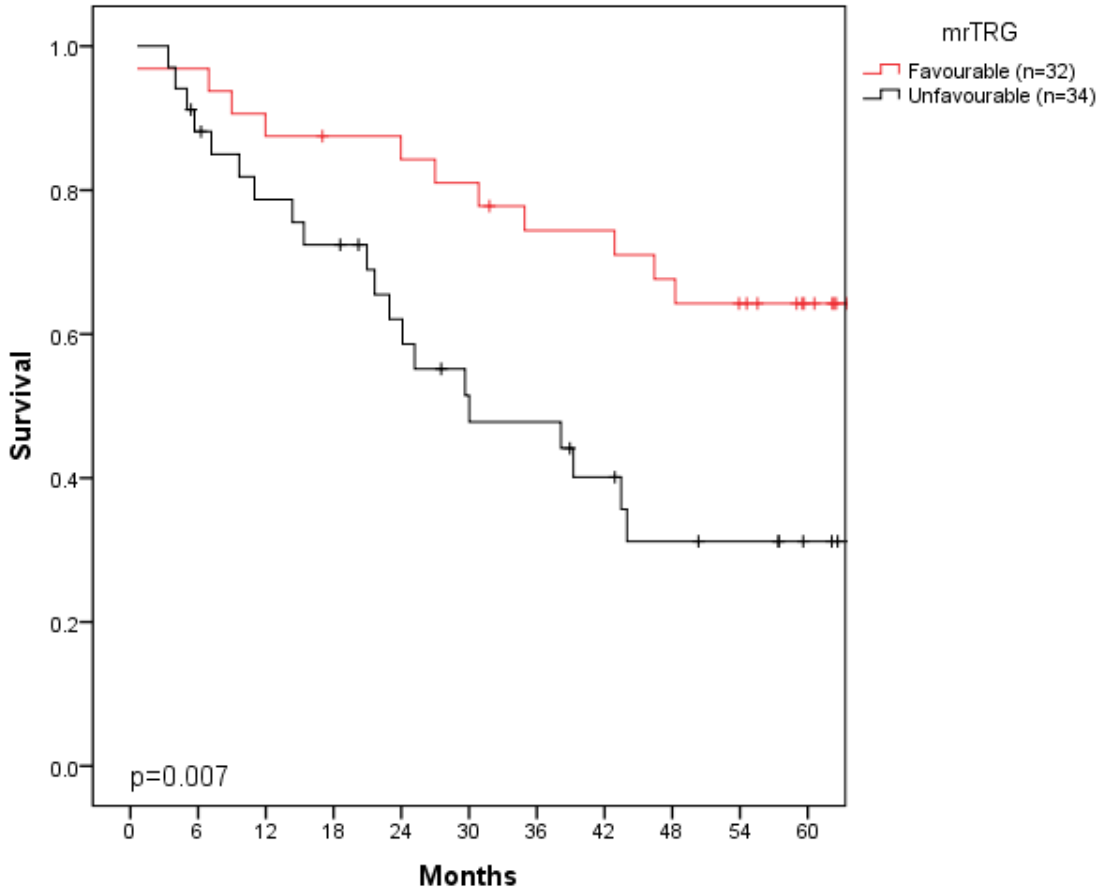

Figure 6.3. ypT and overall survival

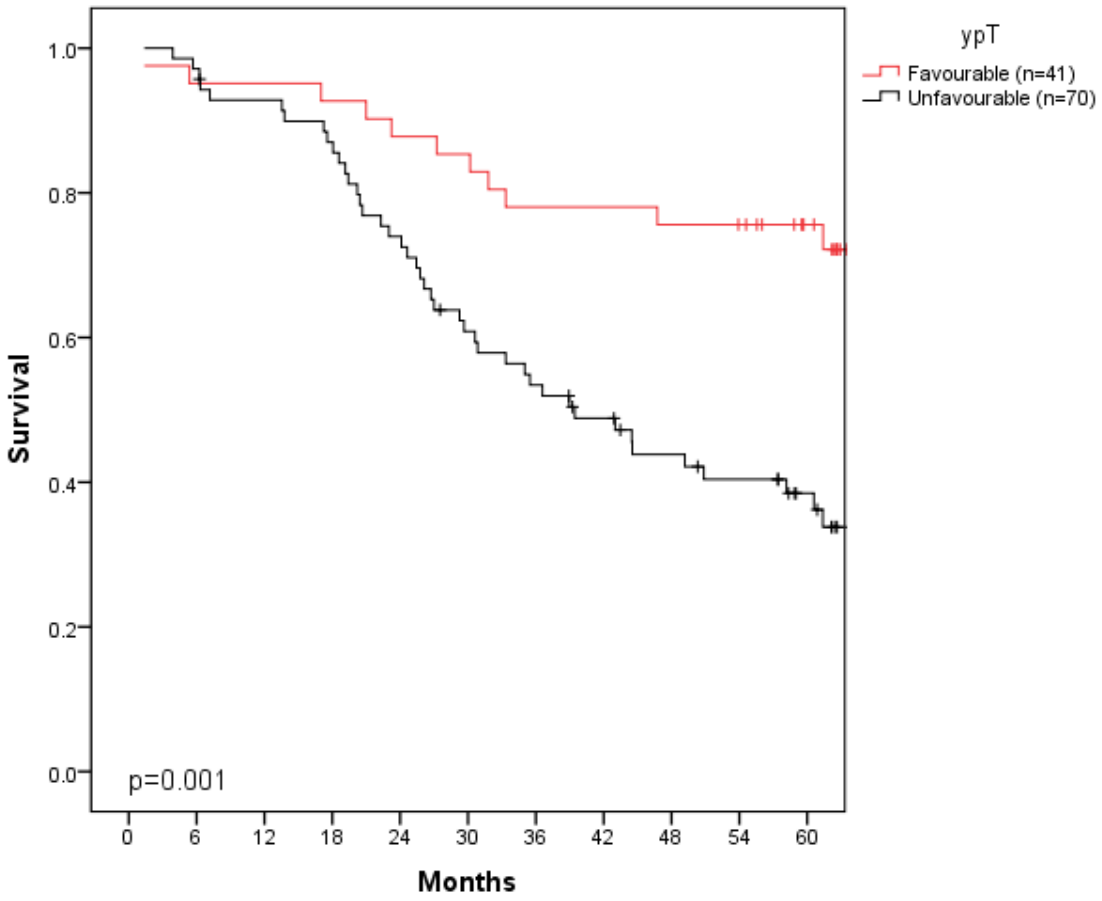

Figure 6.4. ypT and disease free survival.

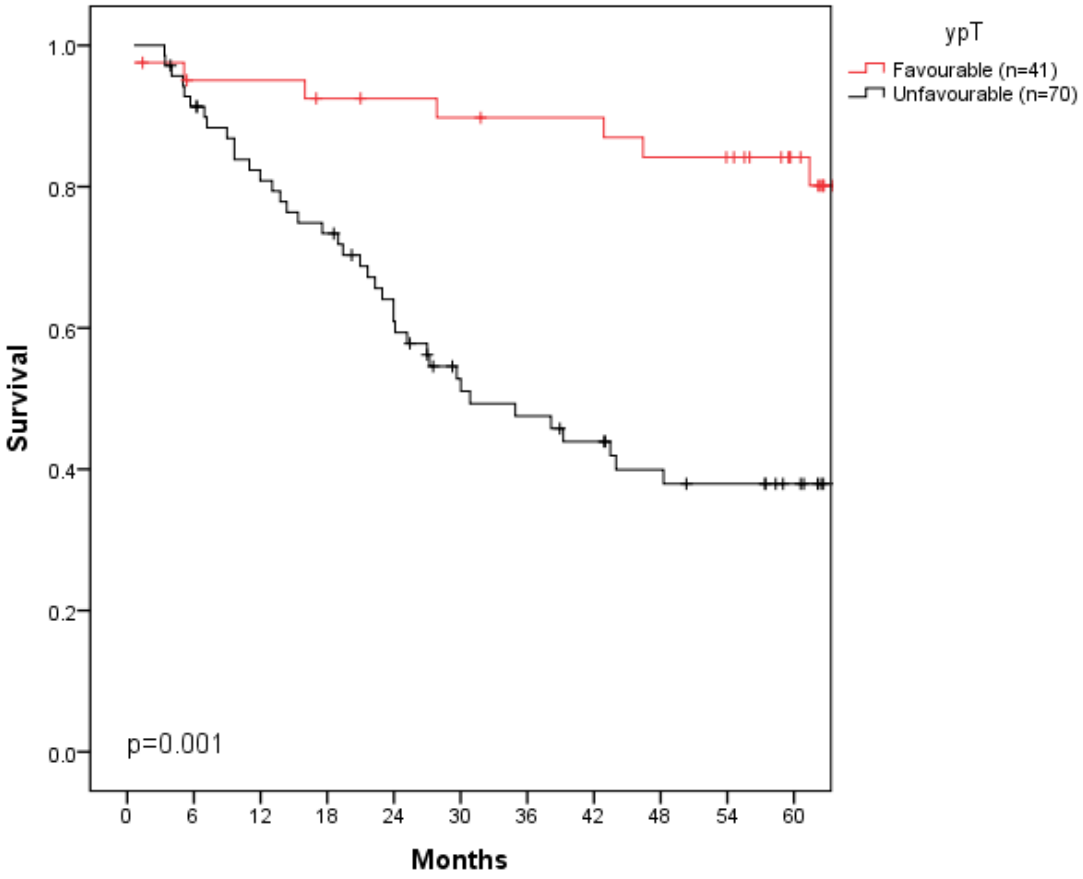

6.6 Discussion

This study has shown that MRI assessment of tumour regression grade after preoperative therapy predicts disease free survival and overall survival and thus patient prognosis prior to definitive surgery. Post treatment MRI prediction of circumferential resection margin involvement also gives important prognostic information regarding the risk of local recurrence.

There are several pathology TRG systems (such as those proposed by Dworak,(Dworak, Keilholz et al. 1997) and Mandard(Vecchio, Valentini et al. 2005)), each based on the relative proportion of fibrosis present in the resected specimen. The relationship between pathological tumour regression grade and outcome has been considered important in previous studies (Rodel, Martus et al. 2005; Suarez, Vera et al. 2008), with for example pathology TRG predicting overall survival and seeming to be an important prognostic predictor for disease free survival (Vecchio, Valentini et al. 2005). Applying similar principles using MRI we have now shown that it is possible to assess tumour regression prior to surgery.

It is notable that neither histopathological nor MRI assessment of nodal status following radiotherapy or chemoradiotherapy predicted local recurrence. This differs from previously published studies (Moran, James et al. 1992; Bujko, Michalski et al. 2007). Studies from the pre TME era convincingly demonstrate the strong relationship between node positivity and pelvic recurrence which has been attributed to mesorectal tissue containing nodes and deposits left behind in the pelvis (Gunderson, Jessup et al. 2010). However, incomplete TME specimens are also associated with 20% pelvic recurrence rates for node positive patients compared with only 6% for complete TME specimens (Shihab, Moran et al. 2009). In the MERCURY study, the TME specimen quality was audited and an incomplete rate of only 5% was observed which is significantly better than previously published series (Nagtegaal, van de Velde et al. 2002; MERCURY 2006; Shihab, Moran et al. 2009). This may explain the observed lack of an effect on outcome by involved lymph nodes after preoperative therapy.

The strengths of this study are that it represents high quality radiological, pathological and surgical data ensured by training workshops. The prospective nature of the study also represents a large series of patients who have undergone baseline and post CRT MR imaging as well as outcome data. However, there are potential limitations of this study, Firstly, 73% (66/90) post treatment MRI scans were available for a retrospective review of mrTRG. Despite this, a representative sample were reviewed and interobserver agreement was moderate to substantial (κ=0.6 and κ=0.65), indicating that this technique is reproducible. A further limitation was the lack of standardisation of neoadjuvant therapy and the use of both CRT/RT treatment approaches. This could have influenced outcomes as it would be expected that patients receiving long course radiotherapy would have responded less well. However, on multivariate analysis the type of treatment did not materially influence the outcomes and the prognostic importance of mrTRG and ypT are independent of the type of treatment received.

This is the first time that a prospective study has demonstrated a correlation between radiologically determined tumour response and long term outcomes. The fact that this is achieved prior to surgical resection provides evidence for the design of future studies that could alter patient therapy based on response assessment. It also allows the identification of good and poor responding patient groups and different approaches that could be adopted after completion of CRT. For example, the role of systemic non cross resistant chemotherapy could be tested in poor responding patients in a randomised controlled trial against the current surgical standard of care. On the other hand, the evaluation of the timing or even deferral of surgical resection could be investigated in patients with a good response (mrTRG1 and 2) (O'Neill, Brown et al. 2007).

6.7 Conclusion

Post treatment MRI tumour regression grading and CRM evaluation gives the multidisciplinary team a window of opportunity to refine treatment plans prior to definitive surgical treatment.

6.8 Supplementary analysis

6.8.1 Histopathological and post treatment MRI factors vs. survival

Table 6.4 summarises multivariate analysis assessing the association between significant histopathological & MRI preoperative staging variables with overall survival, disease free survival and time to local recurrence.

Pathological post treatment Circumferential Resection Margin Status (pCRM) was significant for overall survival, disease free survival and local recurrence; hazard ratios for involved pCRM for OS, DFS and local recurrence were 4.19 (95% CI 1.49-11.8), 2.43 (95% CI 1.01- 7.75) and 4.6 (95% CI 1.03- 20.54) respectively. Post treatment pathological T stage and pathological nodal status were not statistically significant.

MRI tumour regression grade (mrTRG) was significant for overall survival with a hazard ratio of 4.46 (95% CI 1.3-15.27). Post treatment MRI Nodal status and MRI Circumferential resection margin status were not significant.

6.8.2 Discussion

Histopathological T stage and CRM involvement both predicted overall survival, disease free survival and local recurrence on initial analysis in table 6.3. In this further analysis of significant post treatment MRI and histopathological factors pCRM was the only significant pathological factor.

pCRM has previously been described as a crucial prognostic factor after treatment (Nagtegaal, Gosens et al. 2007). The data shows of the 23/111 patients that had a positive CRM on histopathology, 21/23 (91%) were also staged as ypT poor (>ypT3a). Thus, the two variables are highly interdependent with nearly all those patients with involved

resection margins part of the larger poor prognosis group (n=70) with more advanced pathological T stage. This may explain the absence of a significant effect for ypT in this analysis.

Of the 66 patients scored for post treatment mrTRG, 34 had unfavourable grades 4 and 5. The majority (20/34), 58% also had a potentially involved circumferential resection margin on post treatment MRI. Therefore, these two variables appear to partly overlap and may explain the absence of a significant effect for post treatment MRI CRM in this analysis.

mrTRG appears to be the imaging parameter with the strongest relationship to outcome. As mrTRG can be assessed preoperatively this gives an opportunity for the multi-disciplinary team (MDT) to modify treatment prior to surgery.

Table 6.4. Multivariate analysis MRI and histopathologic factors, Data presented as Hazard ratios

	Overall Survival, n=63		Disease Free Survival, n=63		Local Recurrence, n=63	
ypT	Good	1	Good	1	Good	1
	Poor	1.3	Poor	2.37	Poor	17.45
ypN	Good	1	Good	1	Good	1
	Poor	1.80	Poor	1.77	Poor	0.25
pCRM	Negative	1	Negative	1	Negative	1
	Positive	4.19 (1,49-11.80)***	Positive	2.43 (1.01-7.75) "	Positive	4.60 (1.03-20.54) $
MRTRG	Good	1	Good	1	Good	1
	Poor	4.46 (1.30-15.27)**	Poor	2.01	Poor	0.33
ymrN	Good	1	Good	1	Good	1
	Poor	1.55	Poor	1.71	Poor	0.41
ymrCRM	Negative	1	Negative	1	Negative	1
	Positive	0.38	Positive	0.54	Positive	0.93

***=0.007
**=0.017
*=0.049
$=0.045

7 Comparison ymrT and mrTRG to histopathological response to chemotherapy in 'intermediate risk' rectal cancer

7.1 Introduction

Most centres worldwide offer preoperative chemo-radiotherapy (CRT) to patients with locally advanced, T3, T4 rectal adenocarcinoma threatening the potential anatomical planes of resection. Preoperative CRT has been shown to be beneficial in reducing local recurrence rates, and has become a standard of care for locally advanced rectal cancer. However, preoperative CRT has not been shown to improve overall survival rates (Sauer, Becker et al. 2004). This is presumably due to the preoperative CRT not controlling distant disease development (Glynne-Jones, Anyamene et al. 2012).

It is well established that baseline MRI staging can identify potential CRM involvement therefore enabling selection of patients at high risk of local recurrence and candidates for CRT (MERCURY 2006). More recently it has been found that baseline MRI also enables the risk of distant failure to be assessed; with the presence of advanced T and N stage as well as extramural venous invasion identified as increasing the probability of distant metastasis (Smith 2008; Smith, Barbachano et al. 2008).

Systemic chemotherapy has been shown to be an effective treatment of both the primary colorectal tumour as well as secondary liver metastasis. For example Gervaz et al reported the results of 29 patients with colorectal cancer and synchronous liver metastases. Patients received neoadjuvant chemotherapy prior to liver surgery and resection of the primary tumour. Histopathological tumour regression grading showed complete or predominant fibrosis in 10/29 colorectal samples and 11/29 liver specimens (Gervaz, Rubbia-Brandt et al. 2010).

A study by Chau et al showed a high primary tumour response rate to systemic induction chemotherapy, followed by chemoradiotherapy and TME in MRI defined high risk patients. MR restaging using change in tumour length showed no patients with progressive disease, 84% with a MRI partial response, 12% with MRI stable disease, and 4% with MRI complete response (Chau, Brown et al. 2006).

Three recent small studies have investigated the use of chemotherapy alone in the treatment of rectal cancer (Table 7.1). The studies have shown systemic chemotherapy can provide primary tumour control as judged by pathological complete response and pathological clear margin rates. Only Schrag et al restaged tumours, using endoscopic ultrasound, with regression observed in all 27 patients that had completed chemotherapy (Schrag 2010).

Therefore in a subgroup of patients with baseline MRI markers for increased risk of distant disease but low risk for local recurrence initial neoadjuvant systemic chemotherapy maybe useful in treating both the primary tumour and preventing distant metastasis.

Table 7.1. Chemotherapy alone in the treatment of rectal cancer

	Eligibility	Imaging	Pathology	R0
Ishii (Ishii, Hasegawa et al. 2010) n=26	T3/T4 N0-2	MRI for baseline staging. No restaging	pCR =1/26 T downstaging 12/26 N downstaging 13/26	Not stated
Schrag (Schrag 2010) n=31	Clinical stage II-III	EUS used to re-stage post chemotherapy	2 patients withdrawn pCR= 8/29 All patients showed regression.	100% (29/29)
Cerek (Cercek 2010) n=26	RT contraindicated or metastatic disease	Not stated	pCR=9/26	Not stated

Tumour regression grading has been considered important as tumour predominating in the stoma is considered unfavourable pathological tumour regression (Dworak 0&1) and is associated with poor survival, while fibrosis predominating in the stoma, favourable tumour regression (Dworak 2,3,4), is associated with good survival. Rodel et al showed 63% disease free survival (DFS) for TRG0+1, 75% DFS for intermediate TRG groups 2+3 and 86% DFS for favourable TRG 4 .

Several methods/criteria for assessing response on MRI post chemoradiotherapy have been investigated by this thesis. These include post treatment T staging (ymrT), tumour regression grading (mrTRG) and length change assessment. The accuracy of these criteria in restaging rectal cancer post chemotherapy alone is uncertain.

7.2 Aims

The aim of this study was to compare which of the available MRI imaging methods can identify good vs. poor responders to neoadjuvant chemotherapy compared with the histopathological reference standard of pTRG. The reproducibility of ymrT, mrTRG and length change assessment across 7 observers was also investigated.

This analysis takes place in the context of a prospective phase II non randomised multicentre clinical trial investigating the use of neoadjuvant systemic chemotherapy (Oxaliplatin, Capecitabine and Bevacizumab) in patients with MRI defined ‘intermediate’ risk rectal cancer – low risk of local recurrence but high risk of distant failure.

7.3 Methods & Materials

7.3.1 Patients

This prospective study was approved by the institutional review board, and informed consent was obtained from all patients. Patients who were scheduled to undergo preoperative chemoradiotherapy were eligible to be included in this study. Enrolment was between July 2009-May 2011. Eleven centres from 1 country took part in the study. Twenty eight patients underwent combination neoadjuvant chemotherapy prior to surgery.

Eligibility

Inclusion criteria:

All enrolled patients had biopsy proven rectal cancer and were candidates for complete surgical resection (R0) with sphincter preservation surgery, prior to the administration of any therapy.

Baseline MRI showed:
A tumour ≥ 1 mm from the mesorectal fascia and
Either:
T3 stage or the presence of extramural venous invasion.

Exclusion criteria:

Patients with Stage T4 or a tumour with an intraperitoneal distal edge, metastatic disease. Tumour presenting initially in a low location and judged, prior to any treatment, to require abdominoperineal resection. Previous chemotherapy for colorectal cancer, incomplete recovery from previous major surgery and patients who had received previous pelvic radiotherapy.

7.3.2 Treatment

XELOX (Oxaliplatin and Capecitabine) /Bevacizumab were administered for 3 cycles, each lasting 3 weeks, for a total of 9 weeks. XELOX without Bevacizumab was then administered during an additional 3 week cycle.

The XELOX regimen consisted of intravenous Oxaliplatin, 130 mg/m2 (day 1 of each cycle for a total of 4 cycles), followed by oral Capecitabine, 1000 mg/m2 twice a day (from the afternoon of day 1 until the morning of day 15). Bevacizumab was administered at a dose of 7.5 mg/kg during 30 minutes on day 1 of each 3-week cycle, during 3 cycles.

Restaging MRI was undertaken after the conclusion of the 4th cycle of XELOX.

Responders/Stable disease by MRI RECIST length analysis proceeded to surgical resection. Those with MRI RECIST length progression proceeded to chemoradiotherapy. The total

radiation dose was 52.5 Gy administered in two series. In the first series, a dose of up to 45 Gy, was distributed into 25 daily sessions of 180 cGY (5 sessions per week during 5 weeks for a total of 25 sessions), The second series (concomitant boost) was administered during the last 5 days of treatment at a rate of 1.5 Gy x 5 days, up to a dose of 750 cGY. Capecitabine 825 mg/m2/12 hrs a day was administered for the duration of radiotherapy according to a regimen of administration of 2 daily doses, 7 days a week.

7.3.3 Surgery

Surgery was performed in the week after the period of recovery from neoadjuvant therapy ended. This period was 3-4 weeks after neoadjuvant chemotherapy or 6-8 weeks after neoadjuvant chemotherapy and radiation, depending on the case.

Surgical options included standard total mesorectal excision (TME) plane surgery or extended TME (TME with adjacent visceral resection) with or without sphincter preservation according to a standardised technique.

After recovering from surgery, patients were evaluated by their oncologist for consideration of postoperative treatment. The regimen used was at the discretion of the oncologist, although 4 additional cycles of XELOX was recommended.

7.3.4 MRI imaging technique and image interpretation

Each centre in the trial employed the imaging protocol described in 3.2.1
Two imaging workshops for the gastrointestinal radiologists participating in the study were held to ensure standardisation of image interpretation. All MR images were analysed independently by each of the seven experienced radiologists. Three of the seven readers had >10 years experience in gastrointestinal MR imaging. The remaining 4 readers had at least 10 years experience in cross-sectional imaging

T stage post CRT, MRI tumour regression grading and MRI length assessment was undertaken. Baseline and Post treatment MRI scans were also evaluated for predicted circumferential resection margin status. A predicted clear circumferential resection margin was defined if the distance of tumour to the mesorectal fascia is greater than or equal to 1 mm on MRI (MERCURY 2006). Extramural venous invasion was defined on both baseline and post treatment MRI as the presence of intermediate signal intensity within vessels with accompanying nodular expansion of the vessel or irregular vessel contour (Smith 2008; Smith, Shihab et al. 2008).

7.3.4.1 T stage post CRT

ymrT was based determined by the extent of persistent tumour signal intensity relative to the layers of bowel wall on T2 weighted images. Comparison was made with pre-treatment images. Tumour response manifested as either replacement of tumour signal by low signal intensity fibrosis (dark stroma) or the development of high signal intensity mucin pools -

such areas where not considered as tumour as did not contribute to T stage. ymrT staging criteria was the same as baseline MRI T staging (section 4.2.7).

Based on known histopathological outcomes according to ypT stage and along the same lines to other chapters in this thesis, the patient's ymrT was divided into favourable and unfavourable response to enable binary comparison. Favourable regression was defined as stages ymrT0,1,2, and 3a, while unfavourable grading was defined as ymrT3b,c,d and 4 (Willett, Badizadegan et al. 1999).

7.3.4.2 MRI tumour regression grading

The MRI scans were anonymised and separately reviewed by two radiologists with 14 (GB) and 5 (UBP) years experience in MRI assessment of rectal cancers using the previously defined criteria in Table 1.6.

Good MRI tumour regression grade was defined as grades 1, 2 and 3 with poor defined as stages 4 and 5. This binary division was chosen as per the chapter 4.

7.3.4.3 MRI modified RECIST

Maximum tumour length was measured on sagittal images pre and post treatment. Complete disappearance of tumour was defined as a complete response. Percentage change in tumour length was classified using RECIST criteria with complete disappearance of tumour being defined as complete response. Partial response to treatment was defined as at least a 30% decrease in tumour length, taking as reference the baseline tumour length. Progression of disease was defined as at least a 20% increase in tumour length, stable disease was defined as neither sufficient shrinkage to qualify for partial response nor sufficient increase to qualify for progression of disease (Therasse, Arbuck et al. 2000). For the analysis partial response was categorised as favourable, while stable or progression of disease was unfavourable.

7.3.5 Histopathology

After surgical resection, the specimen was fixed and sampled as described in 4.2.5. Each specimen was graded by degree of tumour regression, according to the Dworak system (Dworak, Keilholz et al. 1997). A clear pCRM was defined as greater than, or equal to, 1 mm between the tumour and the resection margin.

7.4 Statistics

7.4.1 ROC analysis

As well as grading and staging by the 5 point pTRG (Dworak, Keilholz et al. 1997) a simplified pathological grading of favourable and unfavourable pathology was also undertaken. Favourable pathology was defined as pTRG stages 3 and 4, while unfavourable pathology was defined as pTRG stages 0, 1, and 2.

The area under the ROC was used in two analyses; the first assessed the diagnostic accuracy of mrTRG against the favourable and unfavourable pathological TRG classification above. The second analysed the diagnostic accuracy of ymrT against favourable and unfavourable pathological TRG. The area under the ROC curve was classified as follows: 0.9-1=excellent, 0.8-0.9=good, 0.7-0.8=fair, 0.6-0.7=poor, 0.5-0.6=fail.

Calculations were performed using Statistical Package for Social Sciences program, version 15.0 (SPSS, Chicago, Illinois, USA). P values of less than 0.05 were considered significant.

7.4.2 MRI modified RECIST Analysis

The Mann-Whitney U test was used to assess if there was a significant difference between the Sum of Ranks of favourable and unfavourable mrRECIST scores.

7.4.3 Univariate logistic regression

Univariate logistic regression analysis was used to analyse the association between MRI parameters (ymrT, mrTRG and tumour length assessment) and pathologic TRG. This enabled calculation of odds ratios for the probability of unfavourable pathological outcome.

7.4.4 Intra-observer agreement

Agreement between the seven observers grading MR variables was determined by Krippendorff's alpha calculation. ($\alpha < 0$, poor agreement; $\alpha = 0$–0.20, slight agreement; $\alpha = 0.21$–0.40, fair agreement; $\alpha = 0.41$–0.60, moderate agreement; $\alpha = 0.61$–0.80, substantial agreement; and $\alpha = 0.81$–1.00, almost perfect agreement).

7.5 Results

Twenty four patients had evaluable imaging and 27 had final pathology (3 did not undergo restaging MRI and 1 died during the trial). All patients showed response or stable disease by post treatment MRI length assessment, therefore no patients were referred for preoperative chemoradiation. This is summarised in Figure 7.1.

Figure 7.1. Trial progress flowchart

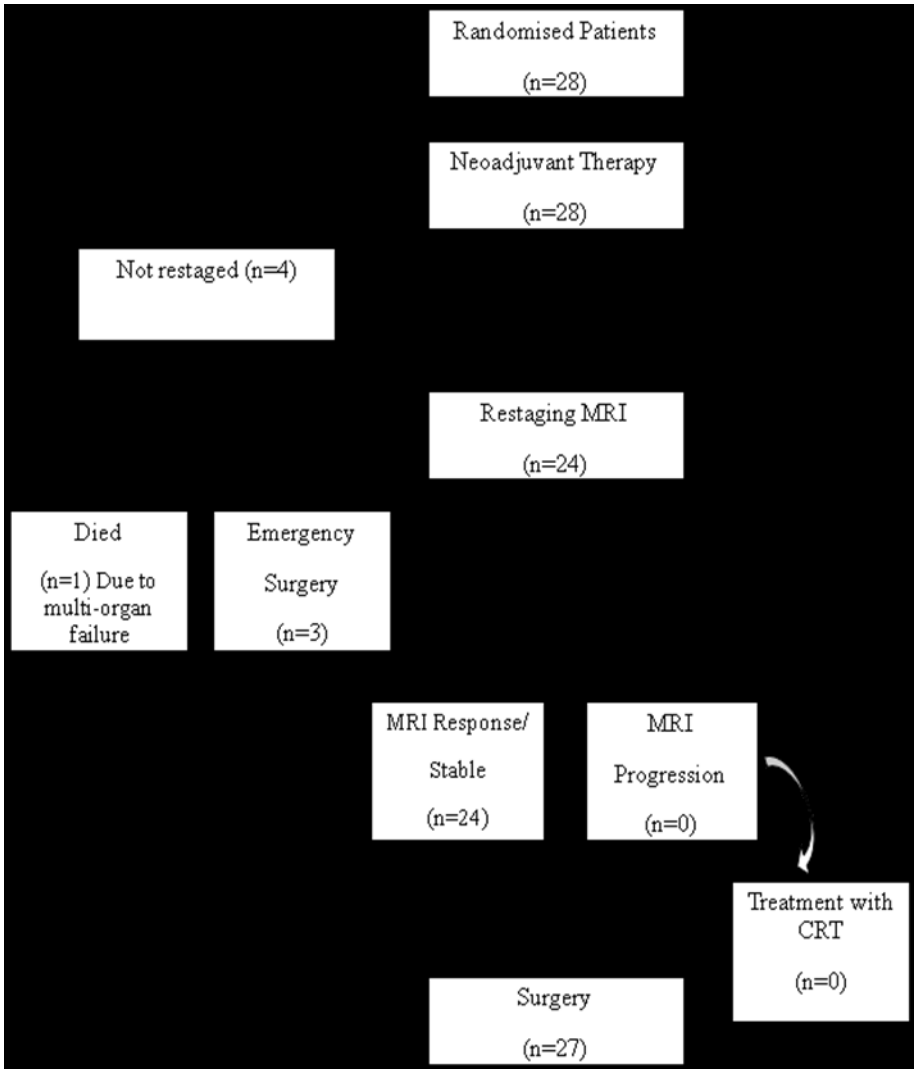

Table 7.2 shows the baseline demographics of the 28 patients who were eligible for this study. The mean baseline tumour length was 4.4cm, standard deviation 1.08 cm. The mean post treatment tumour length was 2.05cm, standard deviation 2.05 cm. The mean tumour length change was -54.06% (standard deviation 22.45%). T stage downstaging was observed; at baseline 27/28 patients had ≥T3b stage, while post treatment 12/24 patients were re-staged as ≥T3b.

Table 7.2. Patient characteristics of patients with full imaging and pathology

		No of patients.
Age:	<65 years	9
	≥65 years	19
Sex	Male	18
	Female	10
Tumour stage at baseline on MR Central r/v:	mrT3a	1
	mrT3b	18
	mrT3c	7
	mrT3d	2
Extra mural vascular invasion on baseline MR:	None	8
	Minimal	7
	Intermediate	7
	Severe/ Large vessel	3
	Not assessed	4
Tumour stage post CRT on MR (ymrT) Central r/v:	ymrT0	2
	ymrT1	2
	ymrT2	4
	ymrT3a	4
	ymrT3b	9
	ymrT3c	2
	ymrT3d	1
	Not restaged	4
Tumour regression grade on MR (mrTRG) Central r/v:	mrTRG1	0
	mrTRG2	13
	mrTRG3	6
	mrTRG4	5
	mrTRG5	0
Extra mural vascular invasion on post treatment MR:	None	13
	Minimal	9
	Intermediate	2
	Severe/ Large vessel	0
	Not restaged	4
CRM on post treatment MR:	Potentially clear	24
	Potentially involved	0
Modified MR RECIST Central r/v:	Partial response	20
	Stable disease	4
	Progression	0
	Not restaged	4
Pathological TRG:*	pTRG 0	3
	pTRG 1	5
	pTRG 2	6
	pTRG 3	6
	pTRG 4	4
Pathological CRM	Clear	23
	Involved	1

*Includes pathology of 4 patients that did not complete neoadjuvant treatment and undergo MRI restaging.

7.5.1 Correlation of MRI parameters and pathological TRG

7.5.1.1 MRI tumour regression grade post CRT

Table 7.3 shows the histopathological tumour regression grade of the patient by individual mrTRG grade. ROC analysis was undertaken to calculate the area under the curve (AUC) and is illustrated in figure 7.2. The area under the ROC curve (AUC) is 0.84; indicating mrTRG has a good diagnostic accuracy for TRG pathology.

Table 7.3. Raw data table for mrTRG vs. pathological TRG

		Pathological TRG						
		0	1	2	3	4	5	Total
mrTRG	1							
	2		1	5	3	4		13
	3	1	2	1	2	0		6
	4	2	2	0	1	0		5
	5							
	Total	3	5	6	6	4		24

Figure 7.2. mrTRG vs. pathological TRG

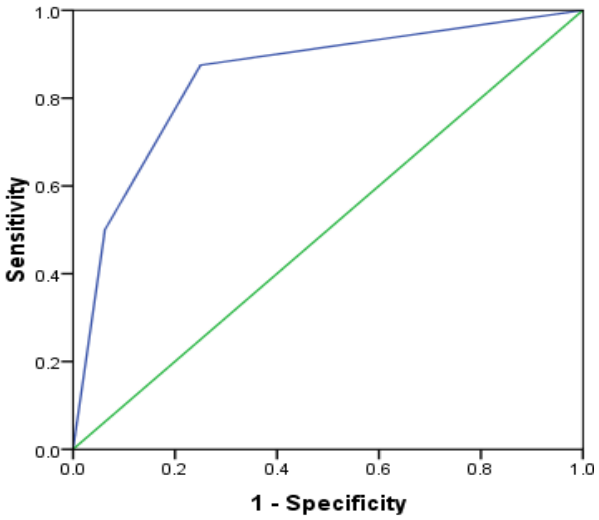

Area	Std. Error	95% Confidence Interval	
.848	.090	.672	1.023

7.5.1.2 MRI T stage post CRT

Table 7.4 shows the histopathological tumour regression grade of the patient by individual ymrT stage. ROC analysis was undertaken to calculate the area under the curve (AUC) and is illustrated in figure 7.3. The area under the ROC curve (AUC) is 0.77; indicating ymrT has a fair diagnostic accuracy for TRG pathology.

Table 7.4. Raw data table for ymrT vs. pathological TRG

		Pathological TRG					
		0	1	2	3	4	Total
ymrT	0	0	0	1	1	0	2
	1	0	0	1	0	1	2
	2	0	0	1	2	1	4
	3.1	1	0	1	1	1	4
	3.2	2	4	2	1	0	9
	3.3	0	1	0	1	0	2
	3.4	0	0	0	0	1	1
	Total	3	5	6	6	4	24

Figure 7.3. ROC analysis for ymrT vs. pathological TRG

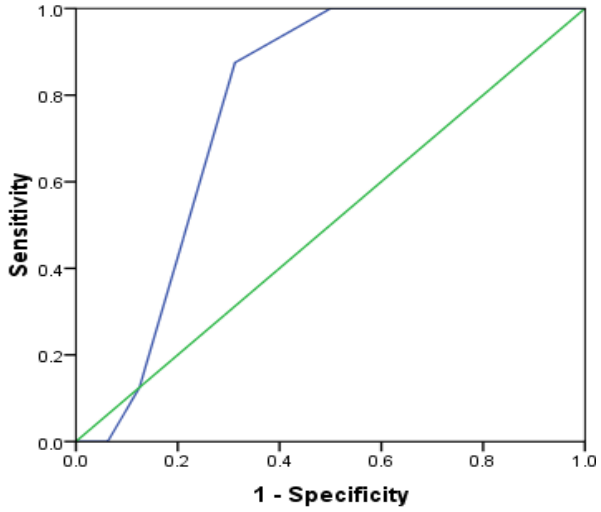

Area	Std. Error	95% Confidence Interval	
.773	.096	.586	.961

7.5.1.3 MRI RECIST post CRT

The Mann-Whitney U test calculation was performed to assess if there was a difference between the Sum of Ranks between the Partial Response MRI group and the Stable Disease MRI group. No significant difference (p=0.17) was found between the MRI partial response group and the MRI Stable disease group. The raw data is shown in table 7.5; the Mann-Whitney U test is shown in table 7.6

Table 7.5. MRI RECIST vs. Pathological TRG

	Pathological Tumour Regression Grade						
		0	1	2	3	4	Total
MR RECIST	Partial Response	1	5	5	5	4	20
	Stable/ Progression	2	0	1	1	0	4

Table 7.6. Mann-Whitney U test results for MRI RECIST and TRG pathology

Modified MRI RECIST	N	Mean Rank	Sum of Ranks	Test Statistic
Partial response	20	13.35	267.00	p=0.178
Stable disease/Progression	4	8.25	33.00	

7.5.1.4 Univariate logistic regression

Table 7.7 shows the TRG histopathology status of patients by mrTRG, ymrT and mrRECIST. Significantly more patients with mrTRG stage 1-3 had favourable pathology (15/19), compared with mrTRG stage 4&5 (1/5); p=0.03; OR 15.00 (95% CI 1.3-174.3). Furthermore, significantly more patients with ymrT stage T0-T3a had favourable pathology (11/12), compared with ymrT stage T3b-4 (5/12); p=0.022; OR 15.4 (95% CI 1.5-160.9). No significant relationship was shown for MRI length analysis and pathology TRG.

Table 7.7. TRG pathology status by MRI parameters

	pTRG good (3,4)	pTRG poor (0,1,2)	OR (95% CI)	P value
mrTRG Central r/v 1-3 4-5 Not restaged n=4	 15 1	 4 4	 1.00 15.00 (1.3-174.3)	0.03
ymrT Central r/v T0-T3a T3b-4 Not restaged n=4	 11 5	 1 7	 1.00 15.4 (1.5-160.9)	0.022
MRI length analysis Partial Response Stable/ Progression Not restaged n=4	 14 2	 6 2	 1.00 2.33(0.3-20.7)	0.45
	pCRM clear	pCRM involved		
MRI CRM clear MRI CRM involved Not restaged n=4	23 0	1 0		

7.5.1.5 Interobserver agreement

Interobserver agreement was calculated between the 7 radiologists.

324 pairs of observations were used for mrTRG. There was a moderate level of agreement for mrTRG Krippendorff's α=0.41.

335 pairs of observations were used for ymrT. There was a fair level of agreement for ymrT Krippendorff's α=0.25.

381 pairs of observations were used for tumour length assessment. There was a slight level of agreement for tumour length assessment Krippendorff's α=0.13.

7.5.2 Examples of treatment response

Both acellular mucinous change (figure 7.4) and fibrosis (figure 7.5) were observed.

Figure 7.4. Acellular mucinous response post neoadjuvant chemotherapy

A) Axial T2 weighted post treatment image shows a high signal mucinous area (Circled) with no intermediate signal within it. This was interpreted as treatment response.
B) Corresponding photomicrograph (H&E strain) shows multiple areas of acellular mucin (black stars).

A) B)

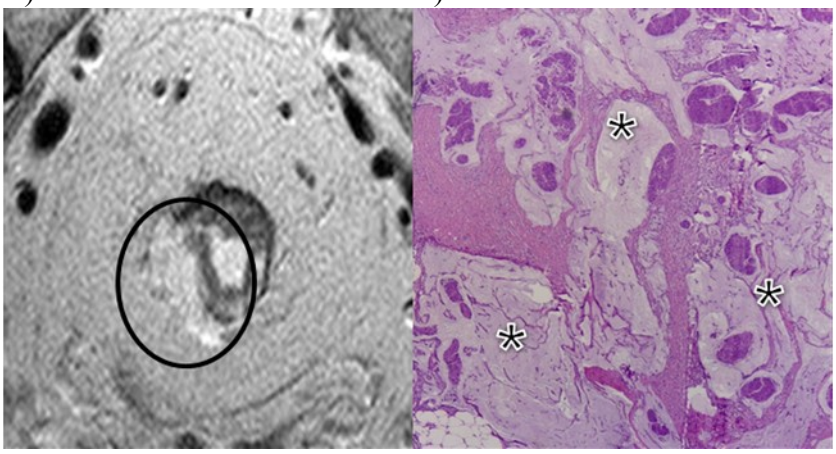

Figure 7.5. Fibrosis post neoadjuvant chemotherapy

A) Axial baseline T2 weighted image shows a semiannular intermediate signal tumour between the 9‘o’clock to 3‘o’ clock positions.
B) Axial post treatment image shows a low signal area between the 12‘o’clock to 2 ‘o’clock position, (Circled).
C) Corresponding photomicrograph (H&E strain) shows area of mural fibrosis (arrow).
Star indicates extramural fat.

A)

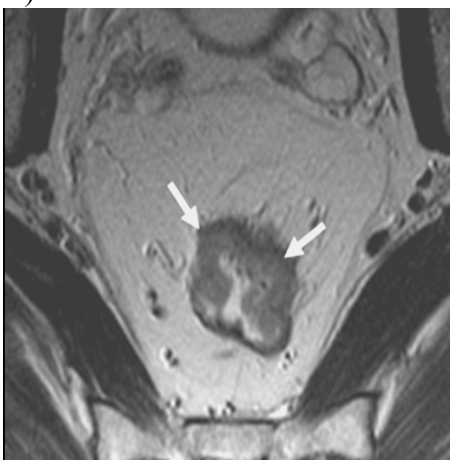

B)



C)

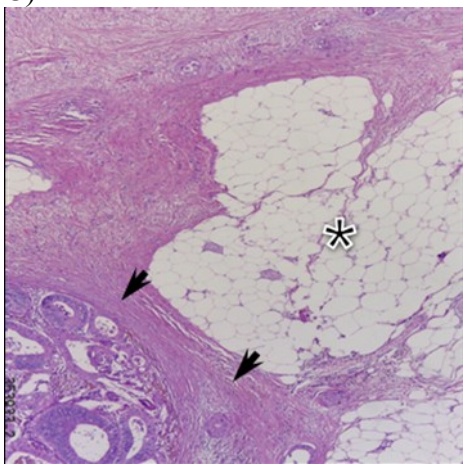

7.5.3 CRM positive case

One case in this study had pathological CRM involvement. This was due to an involved lymph node at the mesorectal fascia. This is illustrated in figure 7.6. This patient underwent adjuvant chemoradiation.

Figure 7.6. Coronal T2 weighted MRI image showing involved lymph node (black arrowhead), at the potential CRM (white arrows).

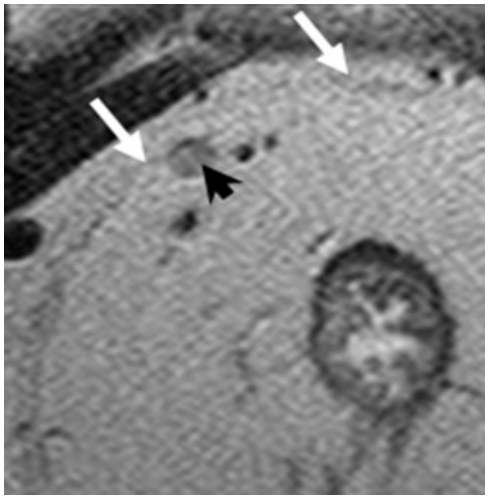

7.6 Discussion

This multicentre multiobserver study has afforded the opportunity to evaluate a number of imaging measures of primary tumour response to chemotherapy. Of these mrTRG assessment gave a good diagnostic accuracy as indicated by the area under the ROC curve. ymrT showed a fair diagnostic accuracy on ROC analysis, with logistic regression analysis showing a statistically significant relationship with histopathological tumour regression grade for both parameters. No significant relationship was shown for MRI length analysis and pathological TRG.

The level of reproducibility between 7 radiologists for each MRI parameter was also assessed, mrTRG was the most reproducible parameter, (α=0.41), ymrT was less reproducible in this analysis at α=0.25, with slight agreement for length measurement at α=0.13.

This is the first study to use MRI to select a subgroup of 'intermediate risk' rectal tumours (MRI CRM clear, EMVI + or T3 tumour) (Smith, Barbachano et al. 2008), at high risk of distant relapse but relatively low risk of local recurrence. In many American centres T3 tumours are treated with preoperative chemoradiation (Minsky 2011); while in the UK short course radiation or chemoradiation is considered by most centres (NICE 2011). The approach used in this study has potential advantages over these regimes as possible distant micrometastases are treated by systemic chemotherapy- decreasing the risk of distant relapse and the morbidity of pelvic radiation is avoided- as the risk of local recurrence is low.

One patient in this trial had pathological CRM involvement due to an involved encapsulated lymph node at the mesorectal fascia. There has been debate regarding if such cases constitute an involved margin, with some proposing a pathologically involved node within 1 mm of the CRM (pCRM+ by definition) is unlikely to result in tumour recurrence due to the protective effect of the nodal capsule and intact mesorectal fascia (Cecil, Sexton et al. 2004). A recent study by Shihab et al supports this view, 31 of the 396 patients in this study had suspicious nodes on MRI 1 mm or less from the CRM. Subsequently none of these patients had a positive CRM owing to nodal involvement. Therefore caution is needed when recommending neoadjuvant/adjuvant therapy based solely on a suspicious MRI detected involved lymph node close to the potential circumferential resection margin (Shihab, Quirke et al. 2010).

Pathological observations such as fibrosis and acellular mucin seen in this study are in line to those observed in rectal cancer treated with chemoradiation (Puppa, Sonzogni et al. 2010). The results are also in agreement with Poultsides et al, who described pathologic fibrosis and acellular mucin in colorectal liver metastases resected post chemotherapy (Poultsides, Bao et al. 2012). Furthermore, oesophageal and stomach adenocarcinoma are often treated with chemotherapy alone prior to surgery, with the Mandard pathological tumour regression system, based on the degree of fibrosis versus tumour, used by pathologists to assess response (Mandard, Dalibard et al. 1994). The Mandard system is similar to the Dworak pathological system used in this analysis (Dworak, Keilholz et al. 1997).

It is known that one of the key cellular mediators of fibrosis is the myofibroblast, which when activated serves as the primary collagen producing cell. Myofibroblasts are activated by a variety of mechanisms, such as paracrine signals derived from lymphocytes and macrophages and autocrine factors secreted by myofibroblasts themselves (Wynn 2008). Whether the immunological/histological pathways of fibrosis development differ between chemoradiation and chemotherapy treatment is unclear, however from this analysis it appears that fibrosis development is a common endpoint from both treatment pathways. The mechanism of chemotherapy induced fibrosis versus radiotherapy induced fibrosis remains poorly understood and topic for future study.

Although the pathological CRM positive rate suggests patients in this study have a low risk of local recurrence, long term follow-up data is needed to confirm this. Further follow-up of this cohort is also needed to evaluate the rate of distant failure. However this study suggests radiotherapy can potentially be avoided in a group of patients carefully selected by MRI. This will need to be confirmed in a future phase three trial.

7.7 Conclusions

A subgroup of MRI defined intermediate risk patients- at higher risk of distant metastasis and low risk of local recurrence are likely to benefit from neoadjuvant chemotherapy and avoid morbidity associated with radiotherapy. mrTRG has a good diagnostic accuracy and ymrT has a fair diagnostic accuracy for the post chemotherapy assessment of rectal tumours.

8 Serial ADC Measurements in Rectal Cancer Patients Deferring Surgery Following Chemoradiotherapy—Detecting Residual Disease, Complete Response and Tumour Regrowth

8.1 Introduction

Preoperative long course chemoradiotherapy is used to downstage locally advanced rectal tumours prior to surgery (Sauer, Becker et al. 2004). Up to 25% of patients show an excellent response to CRT, with no tumour found on post operative pathology- a pathological complete response (Hartley, Ho et al. 2005). Such rates of complete pathological response have prompted patients and clinical teams to seek the option of avoiding surgery, particularly when this can lead to avoidance of a permanent stoma, but only if complete response to treatment can be safely identified and monitored.

Previously published observational data has indicated that patients with clinical complete response may avoid surgery (Habr-Gama, Perez et al. 2004). However, identifying and monitoring such patients is a challenge as it may be difficult to determine when it is appropriate to biopsy and how predictive a small sample of the scar is for overall tumour status is uncertain. Moreover, assessment that relies on luminal biopsy or excision of the tumour scar inevitably risks underestimating persistent extramural disease.

Based on the initial experience of patients that wished to avoid surgery, The Royal Marsden Hospital set up two prospective trials in 2006 to enrol patients with low rectal tumours (tumours arising within 5cm of the anal verge or within 1-2 cm of the anorectal junction), who wished to avoid a permanent stoma by deferring surgery and undergo monitoring of the treated tumour site (Yu, Brown et al. 2011).

For the deferral of surgery trial, high resolution MRI is used for assessment of eligibility and surveillance. This technique has the advantage of assessing extramural disease. The main parameters used to assess eligibility are MR T stage and tumour regression grade. Both these parameters are significantly linked with favourable and unfavourable pathology (Chapters 4&5 analysis) and in the case of mrTRG with survival outcomes (Chapter 6). Furthermore, we have observed that if post treatment MR imaging shows predominant low signal intensity fibrosis with no visible or minimal intermediate signal intensity (mrTRG1 or 2) at the treated tumour site, this is strongly associated with complete or near complete regression of tumour on histology. For example in Chapter 4, 7 cases of ypT0/1 were graded as mrTRG 1/2, such patients would be eligible for consideration for deferral of surgery.

In addition to the signal and morphological characteristics seen on high resolution T2 weighted MRI, it is also possible to use MRI to quantify the structural composition of treated tumour using diffusion weighted imaging (Gu, Khong et al. 2011; Reischauer, Wilm et al. 2011). The technique measures movement of water molecules using different magnetic field gradients. The degree of movement is dependent on tissue structure and has

been exploited to distinguish malignant from non malignant tissue (Gu, Khong et al. 2011; Reischauer, Wilm et al. 2011). A particular region of interest can be quantified for diffusivity as the apparent diffusion coefficient value(ADC). Although ADC measurements have been shown to identify complete responders at the end of chemoradiotherapy (Kim, Lee et al. 2009), its usefulness in the setting of surveillance after an apparent complete has never been tested.

8.2 Aims

The aims for this study of patients undergoing deferral of surgery with MR imaging surveillance were:

1) To determine whether ADC values differ between patients with residual/recurrent tumour and those patients in clinical, radiological and biopsy confirmed complete response.

2) To identify an ADC threshold for the optimal sensitivity and specificity for predicting residual tumour/tumour re-growth on an individual patient basis.

8.3 Materials and methods

8.3.1 Patients

Patients were enrolled into one of two studies: the deferral of surgery or alternative deferral of surgery studies which were both approved by our institutional review board. Informed consent was obtained from all patients.

Eligibility criteria for both studies were determined following completion of chemoradiotherapy (CRT) and were as follows:

Group 1- Deferral of surgery study:

Patients were enrolled if they had either:

1) MRI defined complete response: low signal intensity fibrotic scar tissue only and no visible disease in the mesorectum seen at MRI performed 4 weeks after long-course CRT, confirmed at 8-12 week MRI.
2) MRI defined incremental response; evidence of fibrosis predominating over residual tumour signal at 4-6 weeks following CRT MRI which continued to show an incremental response at 8-12 week MRI.

Group 2 – Alternative deferral of surgery trial.

All patients in this group had MRI defined good response, as there was evidence of fibrosis predominating over residual tumour signal, but without a complete or near complete radiological response. The indication for surveillance in the alternative deferral of surgery group was to monitor disease control in the rectum/mesorectum in patients that had no plans for immediate surgery because of:

Synchronous metastasis at presentation.
Refusal of surgery on completion of CRT.
Medical comorbidity and therefore unsuitable for aggressive treatment.
Those with incomplete local tumour excision and subsequent CRT.

8.3.2 Treatment

All patients had received preoperative treatment with radiotherapy prior to entry into the study. The majority of patients received neo-adjuvant chemotherapy in combination with radiotherapy. The majority of patients received radiation therapy at a dose of at least 50Gy to the primary rectal tumour in two phases: 1. Pelvis: 45 Gy in 25 fractions at 1.8Gy per fraction. 2. Boost: 5.4-9 Gy in 3-5 fractions at 1.8 Gy per fraction (the smaller dose was administered if there was concern about the volume of small bowel included in the boost field). Patients with co-morbidities received a radiation dose of at least 45Gy with or without concomitant chemotherapy. The date of completion of radiotherapy was recorded in relation to the MRI scan timing. Any patient with MRI defined node positive disease at

baseline was offered adjuvant 5FU based combination chemotherapy upon entering the deferral study.

8.3.3 Surveillance schedule

Both groups were followed according to protocol as detailed in table 8.1.

Patients in both groups were considered for surgery if there was evidence of tumour growth or regrowth on surveillance. If the patient was unsuitable/refused surgery then further palliative treatment was offered.

The following imaging characteristics were documented for all baseline and surveillance MRIs: ymrT substage, ymrN stage, mrTRG, potential resection margin status.

At the time of each surveillance MRI scan, disease status based on clinical and T2 imaging findings was recorded as residual tumour or absence of tumour.

MRI based TRG (mrTRG) was used to assess imaging. As described in chapter 4, the entire tumour was assessed to determine whether fibrous signal intensity or tumour signal intensity predominated, mrTRG was graded as described in table 1.6.

Radiological complete response or near complete response was defined mrTRG 1/2. Incremental radiological was defined as the regression grade improving to TRG 1/2. Tumour regrowth/residual tumour was defined as persistent or new intermediate signal intensity either at the site of the treated tumour or as tumour deposits within mesorectum.

8.3.4 MRI Imaging technique

MRI scans were performed using either of two 1·5-T whole-body MR image systems made by Phillips and Siemens. The scan parameters and sequences are detailed in section 3.2.

Diffusion weighted scans were performed as an additional investigation when patients consented into either of the deferral of surgery studies. Therefore scans with diffusion weighted imaging were undertaken at variable time points following completion of preoperative radiotherapy depending on time of entry into the study.

All MR images were analysed separately by two experienced radiologists (GB and DMK) with 15 and 13 years of experience in gastrointestinal MR imaging, respectively. Both radiologists were blinded to biopsy results and clinical examination findings.

8.3.5 MRI Diffusion weighted imaging analysis

The T2 axial image slice best showing the tumour or treated tumour was used as a reference to select a region of interest (ROI) on an equivalent single slice of the ADC map. The ADC map slice, with ROI outlined upon it was imported into Diffusion View™ software to generate mean ADC values for each ROI.

8.3.6 Surgical and Pathology assessment

Biopsies were performed if there was either clinical or radiological suspicion of recurrence. Biopsy samples were centrally reviewed for the presence of tumour cells by an experienced gastrointestinal pathologist (AW with 15 years experience). Tumour status was recorded at the time of biopsy during the course of surveillance.

For patients with tumour regrowth, surgery was performed by standard TME plane surgery or extended TME (TME beyond the planes of the mesorectal fascia) with or without sphincter preservation.

After surgical resection, the radial cut surface of the surgical specimen was inked, the unopened specimen fixed in formalin for a minimum of 48 hours and sectioned into 3-5 mm slices. The entire area rectum containing the treated tumour was embedded with multiple step sections taken. Tumour was staged according to the Royal College of Pathologists Guidelines (TNM version 5) (Sobin 1997). A clear circumferential resection margin (pCRM) was defined as greater than, or equal to, 1 mm between the tumour and the inked radial margins. An experienced gastrointestinal pathologist (AW) evaluated specimens for the post treatment T and N stage and circumferential margin status.

Table 8.1. Trial surveillance protocol

Time from CRT completion.	Clinical exam including DRE*	CEA**	Imaging	Endoscopy
4 weeks	Y	Y	MRI	
8 weeks	Y	Y	MRI, PET	
12 weeks	Y	Y	MRI	Flexible Sigmoidoscopy
16 weeks	Y	Y	MRI, PET	
6 months	Y	Y	MRI	Flexible Sigmoidoscopy
9 months	Y	Y	MRI	Flexible Sigmoidoscopy
1 year	Y	Y	MRI,PET,CT	Colonoscopy
15 months	Y	Y		
18 months	Y	Y	MRI	Flexible Sigmoidoscopy
21 months	Y	Y		
2 years	Y	Y	MRI,CT	Flexible Sigmoidoscopy
2.5 years	Y	Y		
3 years	Y	Y	MRI,CT	Flexible Sigmoidoscopy
3.5 years	Y	Y		
4 years	Y	Y	MRI	Flexible Sigmoidoscopy
4.5 years	Y	Y		
5 years	Y	Y	MRI	Colonoscopy
6 years	Y	Y	MRI	Flexible Sigmoidoscopy
7 years	Y	Y	MRI	Flexible Sigmoidoscopy
8 years	Y	Y	MRI	
9 years	Y	Y	MRI	
10 years	Y	Y	MRI	Colonoscopy

*= Digital rectal examination.
**= Carcinoembryonic antigen.

8.4 Statistics

The ADC data generated from each ROI was categorised into one of two groups (tumour present/ tumour absent), based on biopsy results nearest to time of MRI scan and T2 weighted imaging findings on MRI scan. Linear mixed effects modelling was used to investigate if there was a significant difference in ADC values between scans coded as showing complete response vs. tumour (Linstrom and Bates 1989).

The mixed effects model employed ADC values as the dependant variable. Independent variables were: the patient (classified as a random factor), time (a numeric variable) and presence or absence of tumour. The ADC values were regressed as a factor of time, with presence or absence of tumour regressed as the independent variable.

Each radiologist's data was analysed separately.

Receiver operating curve (ROC) analysis was used to define the mean ADC cut-off value in discriminating the tumour group from complete response group and to investigate the level of agreement between the two observers.

The Lowess smooth curve of best fit is presented in the figures showing Time of scan /Number of days post CRT completion on x axis and ADC value on the y axis. Lowess stands for **Lo**cally **we**ighted **s**catterplot **s**moother**.** The curve is placed by multiple "local" regressions. This approach ensures the subset of observations which lie closest to a given evaluation point along the x axis of a graph have more influence on the placement of the local regression line than observations that fall farther away from that local (Jacoby 2000).

P values of less than 0.05 were considered significant.
All statistical analysis was undertaken using STATA 10 software (StataCorp. 2007. Stata Statistical Software: Release 10. College Station, TX: StataCorp LP).

8.5 Results

8.5.1 Patients

The demographic, baseline and post treatment imaging characteristics are summarised in table 8.2. A total of 26 patients were enrolled into the formal deferral of surgery trial and a further 15 in the alternate deferral study, 26 of 41 patients were recruited between 2009 and 2011.

The mean interval between CRT completion and 1st MRI post CRT completion was 40.09 days (SD 22.29, range 20-146 days). The mean length of follow-up post CRT completion was 686.42 days (SD 20.6, range 2.2-105 months).

At 6 weeks following completion of chemoradiotherapy, there were 16 patients with mrTRG 3 or 4, 8 patients showed regression on the subsequent MRI scan and a further 3 patients showed regression on later scans. Therefore, 11 patients showed incremental mrTRG response to CRT on MRI (table 8.2 & figure 8.1). The mean interval between CRT completion and complete response (mrTRG1/2) in this group was 81.00 days (SD 52 range 24-181) with 9 patients in this group showing continued response beyond the conventional 6 weeks post CRT completion.

Thirty-six patients were monitored after radiological and clinical complete response (initial and incremental response) in the alternative and deferral of surgery studies, 10 of these patients subsequently showed regrowth of disease. Table 8.3 details the MRI findings at the time of regrowth and pathology for each patient. Eight patients had intramural/submucosal tumour regrowth on MRI during the surveillance period. One patient had extramural relapse within the mesorectum, which was detected on MRI but not palpable on digital rectal examination or visible on sigmoidoscopy. In one case where MRI findings were negative for tumour regrowth and recurrent disease was detected clinically. The mean time to regrowth was 446.2 days post CRT completion (SD 271.21 range 103-1104 days). Figures 8.2 and 8.3 show examples of tumour regrowth.

Five patients in the alternative deferral study had continued follow up with residual tumour seen on MRI and were followed for evidence of progressive tumour growth. Three of these patients eventually underwent surgery, 2 remained medically unfit to undergo surgery despite tumour growth and continued to be followed up.

Table 8.2. Baseline, pre-treatment, post treatment and tumour characteristics of 41 patients undergoing deferral of surgery following chemoradiotherapy for rectal cancer

		No (%)		
Age (years)	<65	20 (48%)		
	≥65	21 (51%)		
Sex	Male	25 (61%)		
	Female	16 (39%)		
Tumour height	≤ 5cm	36 (88%)		
	> 5cm -10cm	5 (12%)		
	≥10cm	0		
Adjuvant chemotherapy		24 (59%)		
	5FU/Capecitabine	5		
	5FU/Capecitabine+Oxaliplatin	16		
	5FU/Capecitabine+Irinotecan	1		
	Other	2		
	None	17 (41%)		
Deferral of surgery trial		26 (63%)		
Alternative Deferral of surgery		15 (37%)		
	Refused surgery	3		
	Medical comorbidity precluding radical treatment	5		
	Metastatic disease	3		
	Incomplete local excision	4		
		MRI baseline	***1st MRI post CRT***	***2nd MRI post CRT***
MRI T stage	ymrT0	0	20	31
	ymrT1	1	4	2
	ymrT2	9	7	5
	ymrT3a	5	3	1
	ymrT3b	11	5	2
	ymrT3c	8	2	0
	ymrT3d	4	0	0
	ymrT4	3	0	0
MR N stage	N0	20	38	40
	N1/N2	21	3	1
mrCRM involved	No	15	36	40
	Yes	26	5	1
mrTRG	1	0	13	16
	2	0	12	17
	3	0	14	8*
	4	0	2	0
	5	0	0	0

*3/8 patients with mrTRG3 showed continued response on subsequent MRI scans.
5/8 patients with mrTRG3 were followed up according to protocol with residual tumour.

Table 8.3. Characteristics of 10 patients that relapsed during surveillance

Patient	Days post CRT	Site of regrowth on T2 MRI	Pathology		
			ypT	ypN	pCRM
1	103	Intraluminal/ submucosal	2	0	Negative
2	232	Submucosal	Medically unfit for surgery.		
3	308	Extramural deposit	3*	0	Negative
4	330	Intraluminal/ submucosal	2	0	Negative
5	398	Submucosal	2	0	Negative
6	414	Intraluminal/ submucosal	2	0	Negative
7	462	Intraluminal on clinical biopsy only	3	0	Negative
8	503	Submucosal	2	0	Negative
9	608	Submucosal	2	0	Negative
10	1104	Submucosal	Medically unfit for surgery.		

*Focus of discontinuous tumour <3mm classified in accordance with TNM version 5 as T3 rather than N1

Figure 8.1. Incremental response to CRT during follow-up

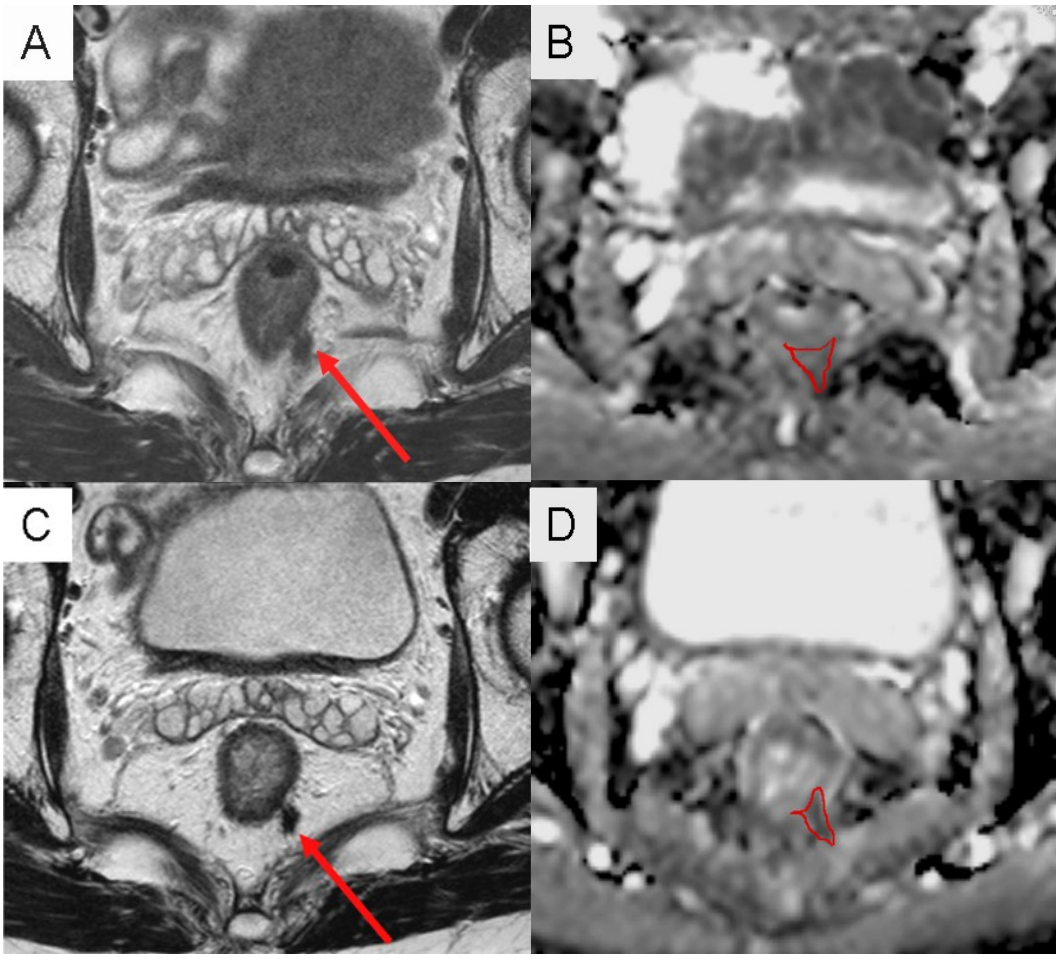

A: Axial T2 weighted MRI scan 23 days post CRT completion.
Intermediate signal compatible with tumour (arrow) is noted at the 5'o'clock position extending extramurally.
B: Corresponding axial slice of ADC map. Region of interest is outlined.
ADC= 1.1 $X10^{-3}/mm^2/sec$.
C: Axial T2 weighted MRI scan 99 days post CRT completion.
Extramural area of low signal compatible with fibrosis; mrTRG 2 (arrow) is noted at the 5 'o'clock position.
D: Corresponding axial slice of ADC map. Region of interest is outlined.
ADC= 1.3 $X10^{-3}/mm^2/sec$.

Figure 8.2. Extramural relapse during surveillance

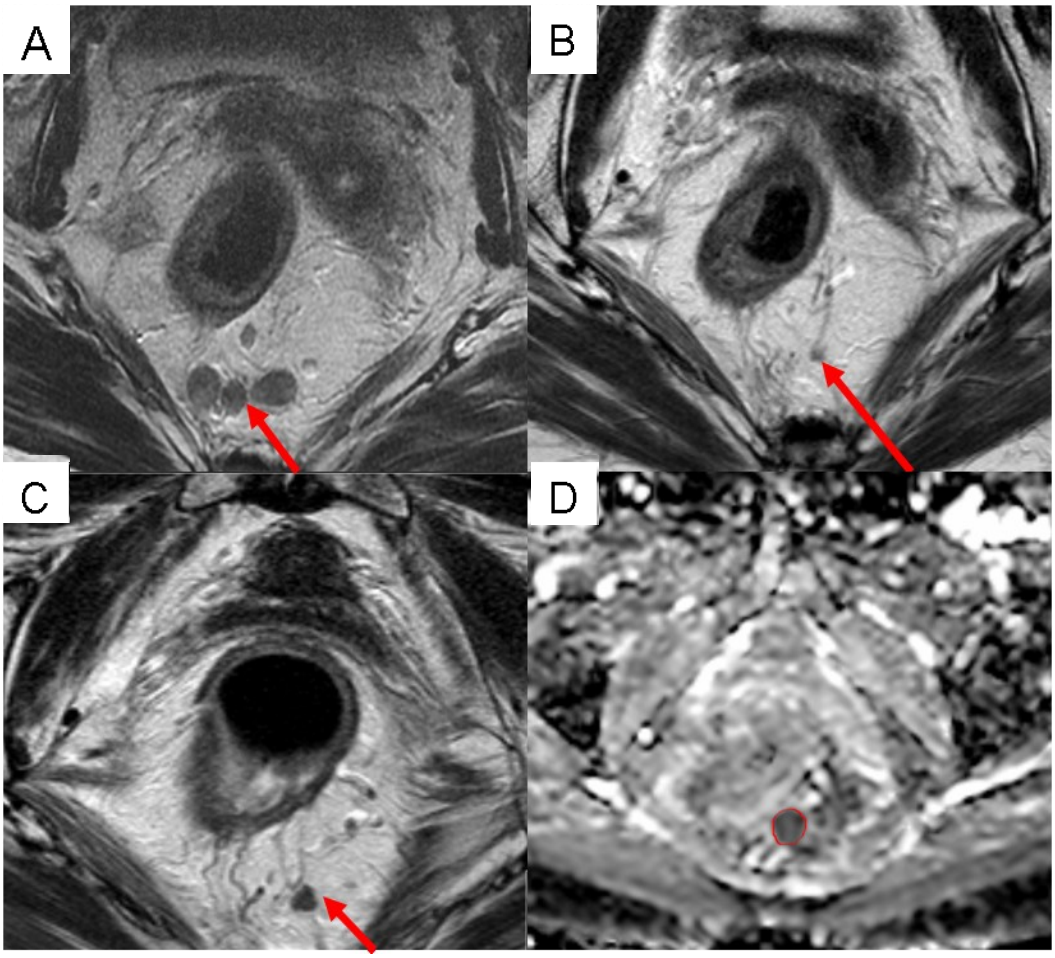

A: Axial T2 weighted MRI scan at baseline.
Intermediate signal within 3 lymph nodes within the mesorectum (arrow) compatible with tumour involvement.
B: Axial T2 weighted MRI scan 154 days post CRT completion.
One remaining lymph node shows homogenous signal intensity and appears benign (arrow).
C: Axial T2 weighted MRI scan 308 days post CRT completion.
The previously noted benign lymph node now appears more suspicious with heterogeneous signal (arrow).
D: Corresponding axial slice of ADC map. Region of interest is outlined.
ADC= 0.9 $X10^{-3}/mm^2/sec$.

Figure 8.3. Subtle submucosal regrowth during follow-up

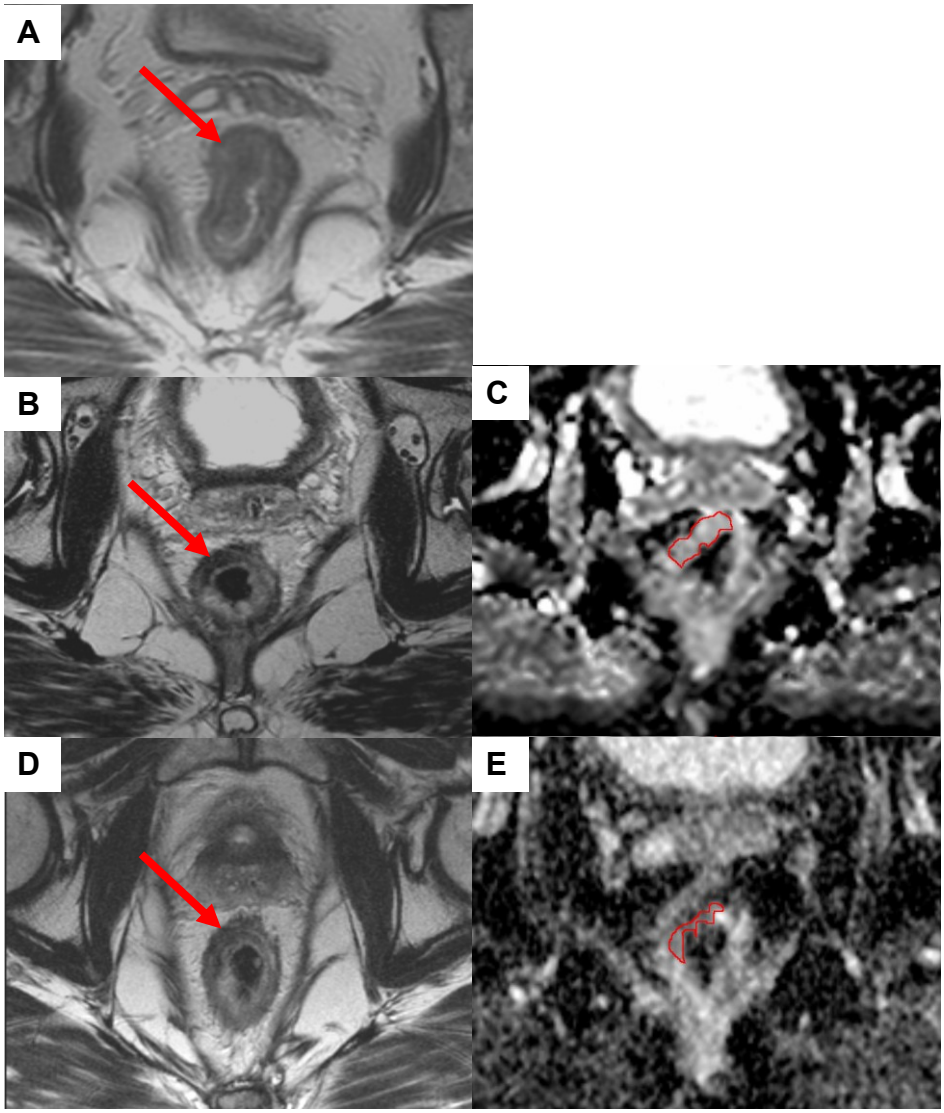

A: Axial T2 weighted MRI scan at baseline.
Intermediate signal tumour is noted anteriorly between 9 'o' clock and 1 'o' clock, extending extramurally at the 11 'o'clock position (arrow)
B: Axial T2 weighted MRI scan 522 days post CRT completion.
Murally based low signal between the 9'o'clock and 12'o'clock position compatible with fibrosis (arrow).
C: Corresponding axial slice of ADC map. Region of interest is outlined. ADC= 1.5 X10^{-3}/mm^2/sec.
D: Axial T2 weighted MRI scan 608 days post CRT completion.
The previously noted mural fibrosis appears similar, with slightly more intermediate signal observed (arrow).
E: Corresponding axial slice of ADC map. Region of interest is outlined. ADC= 1.1 X10^{-3}/mm^2/sec. biopsy was undertaken which confirmed submucosal tumour regrowth.

8.5.2 ADC results

Both readers evaluated 223 scans from 41 patients in both deferral and alternative deferral studies. Sixteen scans from 3 patients were not evaluable due to hip replacement artefact. Overall, there were 152 scans coded as complete response and 55 scans coded as tumour.

Using linear mixed effects modelling, a significant difference was found between ADC values from those in complete response and those with tumour (Table 8.4). For reader 1 those in complete response had an ADC value of 1.513 $X10^{-3}/mm^2/sec$ (95% CI 1.404-1.623) compared to tumour $1.09X10^{-3}/mm^2/sec$ 95% CI (95% CI 0.976-1.222) in those with residual tumour p=0.0001. Similar significant results were seen for reader 2.

Raw ADC data for reader 1 are shown in Table 8.5. Figures 8.4 and 8.5 show serial ADC results for patients initially in complete response, ADC results for those initially showing incremental response are shown in Figure 8.6, with patients followed up with tumour throughout shown in Figure 8.7. The Lowess smooth curve of best fit is presented in relevant figures.

Table 8.4. ADC results

Reader 1.				
	Number of scans	Mean ADC $X10^{-3}/mm^2/sec$	95% CI	p=
Complete response	152	1.51	(1.40-1.62)	
Tumour	55	1.01	(0.98-1.22)	0.001
Reader 2.				
	Number of scans	Mean ADC $X10^{-3}/mm^2/sec$		p=
Complete response	152	1.47	(1.40-1.55)	
Residual tumour	55	1.10	(1.01-1.19)	0.001

Table 8.5 Raw ADC data for reader 1, n=38

Patient and description		4 weeks	8 weeks	12 weeks	16 weeks	6 months	9 months	1 yr	15 months	18 months	21 months	2 yrs	2.5 yrs	3 yrs	3.5 yrs	4 yrs	4.5 yrs	5 yrs	6 yrs	>7 yrs
1	Complete Rx				1.45	1.70	1.44													
2	Complete Rx	1.54		1.42	1.73	1.77	1.28	1.70		1.73		1.21								
3	Complete Rx		1.46			1.33	2.11	1.56	1.64	1.66		1.23	1.85		1.56	1.57				
4	Complete Rx	1.46		1.29				1.52												
5	Complete Rx	1.18		1.33		1.58	1.69	1.38	1.25	1.46		1.92	1.40							
6	Complete Rx				1.17	1.54	1.40	1.69												
7	Complete Rx					1.37	1.94	1.37	1.59	1.31	1.27									
8	Complete Rx																1.43	1.46	1.57	1.39
9	Complete Rx	1.80		1.81		1.33														
10	Complete Rx									1.76	1.86	1.65	1.64	1.56	1.68	2.04			1.81	
11	Complete Rx												1.28	1.50						
12	Complete Rx						1.65	1.72	1.23	1.66	1.37			1.21	1.39	1.65	1.23			
13	Complete Rx										1.37		1.35							
14	Complete Rx			1.78		1.75														
15	Complete Rx							1.26												
16	Complete Rx					1.47	1.50	1.86												
17	Complete Rx	1.90		1.82	1.84	2.07	1.54	1.47	1.31	1.82										
18	Complete Rx					1.23	1.46													
19	CR->regrowth	1.19		1.19	1.19	1.62	1.22	0.99												
20	CR->regrowth						1.25				0.94									
21	CR->regrowth									1.52	1.14	1.56								
22	CR->regrowth		1.26	1.28	1.59	1.74	1.56	1.40	0.94											
23	Inc. Rx	1.14		1.37	1.26	1.31	1.35	1.21			1.45	1.55								
24	Inc. Rx	0.82	0.62		1.79	1.88	1.85	2.11	1.37		1.33	1.88								
25	Inc. Rx										1.07	1.52	1.45	1.68	1.41	1.55	1.62			
26	Inc. Rx			1.61	1.28	1.61	1.58	1.40	1.42		1.63		1.32							

Patient and description		4 weeks	8 weeks	12 weeks	16 weeks	6 months	9 months	1 yr	15 months	18 months	21 months	2 yrs	2.5 yrs	3 yrs	3.5 yrs	4 yrs	4.5 yrs	5 yrs	6 yrs	>7 yrs
27	Inc. Rx	1.27	1.31	1.34	1.54	1.41		1.28	1.38											
28	Inc. Rx	0.82	1.45	1.61	1.51	1.41														
29	Inc. Rx->regrowth	1.01	0.97	1.55	1.58	1.57						1.40	1.44	1.30						
30	Inc. Rx->regrowth								1.03											
31	Inc. Rx->regrowth	1.26		1.29			1.42	1.24	1.20	1.08	1.23									
32	Inc. Rx->regrowth	1.56	1.24		0.88	0.78														
33	Inc. Rx->regrowth	1.20	1.27	1.45	1.81	1.55		1.81	1.48	1.29										
34	Tumour			0.77		0.86	1.07	1.23		1.18	1.50	0.91	0.96							
35	Tumour	1.01	0.44	1.34	1.19	1.33	1.18													
36	Tumour	1.19	1.16	1.24		1.08	1.50	1.08												
37	Tumour	1.26		1.11																
38	Tumour			1.16	1.35	1.13	1.03	1.08	1.13	1.00	0.75									

Units= $10^3/mm^2/sec$
Highlighted= Scans coded as tumour.

Figures 8.4-8.7. Serial ADC measurements for reader 1, n=38

Key:
Each coloured line represents an individual patient.
Red dots= Tumour regrowth.
Solid red line=Lowess line of best fit
Dotted black line= Threshold value, ADC= 1.3 $X10^{-3}/mm^2/sec$.

Figures 8.4 & 8.5. Serial mean ADC measurements in 22 patients with clinical and T2 MRI complete response initially

4 patients subsequently had tumour regrowth (black star=1 patient had ADC imaging only at time of relapse).

Figure 8.4.

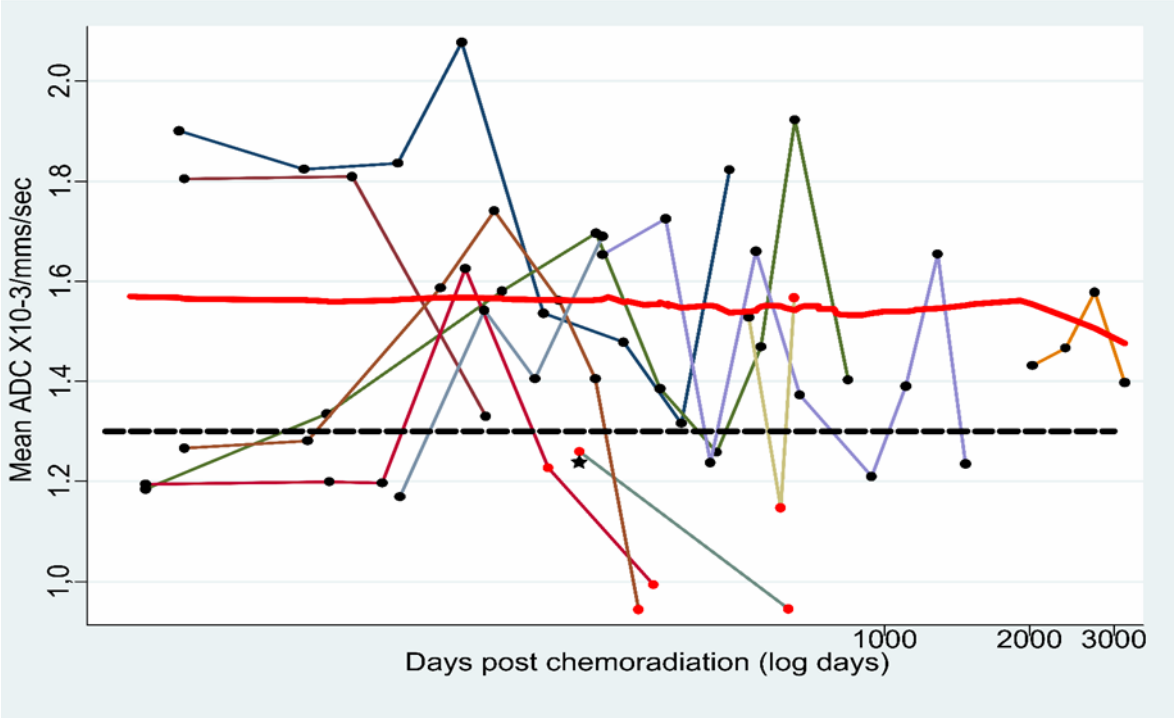

Figure 8.5.

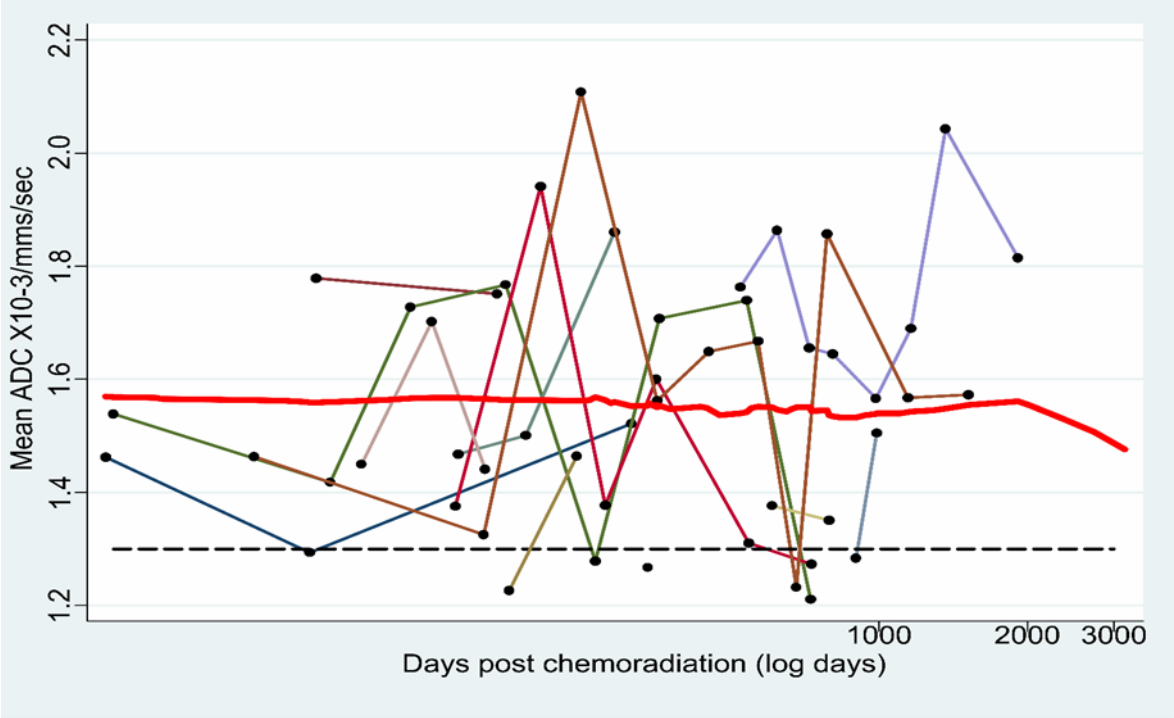
Mean ADC X10-3/mms/sec
1.2
1.4
1.6
1.8
2.0
2.2
1000
2000
3000
Days post chemoradiation (log days)

Figures 8.6. Serial mean ADC measurements in 11 patients with clinical and T2 MRI incremental response

5 patients subsequently had tumour regrowth.
5 patients had incremental response on T2 imaging but DWI was not carried out at the time.

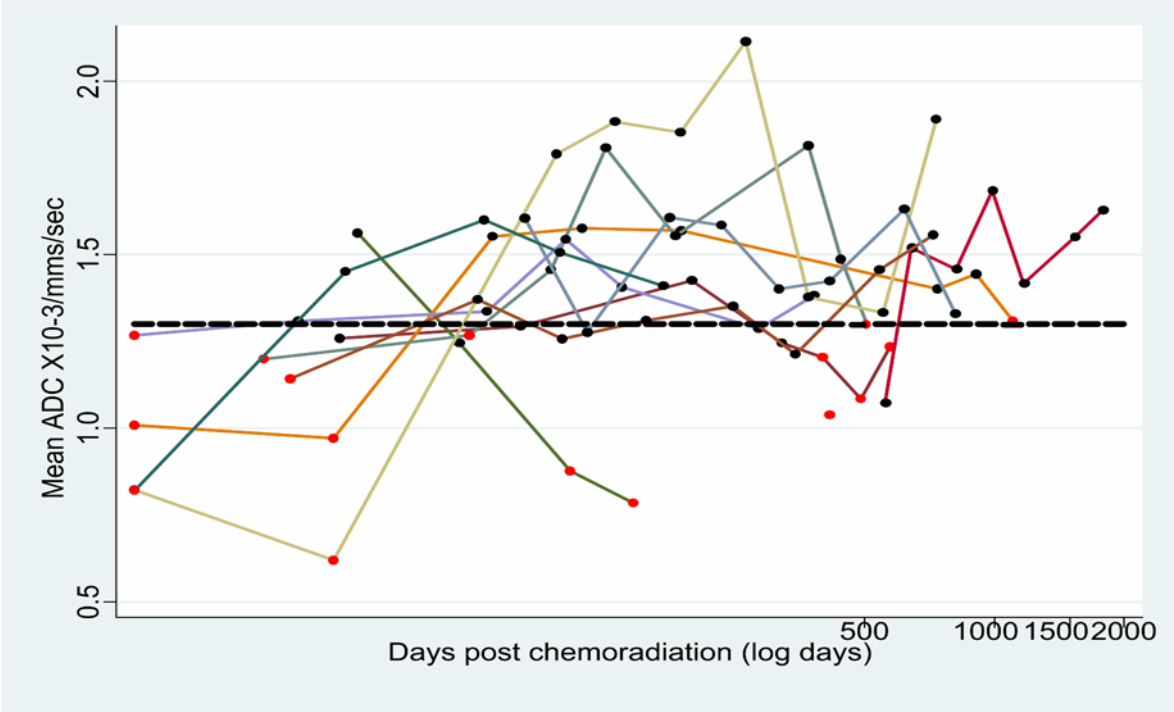

Figure 8.7. Serial mean ADC measurements in 5 patients with clinical and T2 MRI of residual tumour throughout the trial

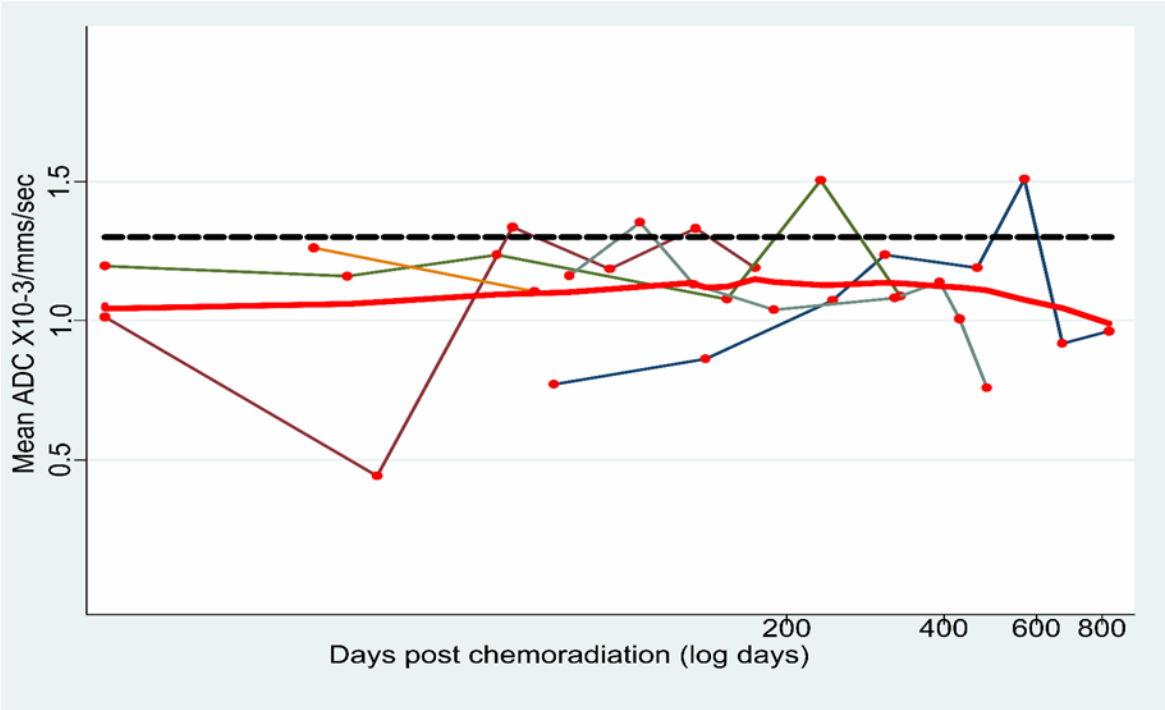

8.5.3 Receiver operating characteristic analysis

A Receiver operating characteristic (ROC) curve was calculated using mean ADC values of patients with biopsy confirmed complete response and mean values of patients with residual/tumour regrowth. Figure 8.8 shows each reader's ROC curve. The area under reader 1's ROC curve was 95% and reader 2 was 92%. There was no significant difference between the two observers ROC curves using the De Long method (DeLong, DeLong et al. 1988) (p=0.27).

The ADC cut-off calculated from both readers data was 1.281 $X10^{-3}/mm^2/sec$ with 86% sensitivity and 87% specificity for tumour presence. Table 8.6 details the accuracy of different ADC cut-offs. Of the 152 scans undertaken in patients with sustained complete response, 28 scan measurements showed ADC values of less than $1.3X10^{-3}/mm^2/sec$ despite the absence of any residual tumour. On the other hand, of the 55 scan measurements in patients with subsequent biopsy confirmed tumour, ADC values greater than $1.3X10^{-3}/mm^2/sec$ were observed in 6/55 scans.

Table 8.6. Sensitivity and Specificity for tumour at different ADC pixel values

ADC pixel value 95% CI $X10^{-3}/mm^2/sec$	Sensitivity %	Specificity %
1.50	100	0
1.42	94	65
1.33	92	77
1.28	86	87
1.23	72	91
1.19	64	95
1.15	59	96
1.11	49	97
1.00	38	98
0.97	26	99
0.76	0	100

Figure 8.8. ROC curve used to evaluate optimum cut-off between complete response and residual/ regrowth of tumour

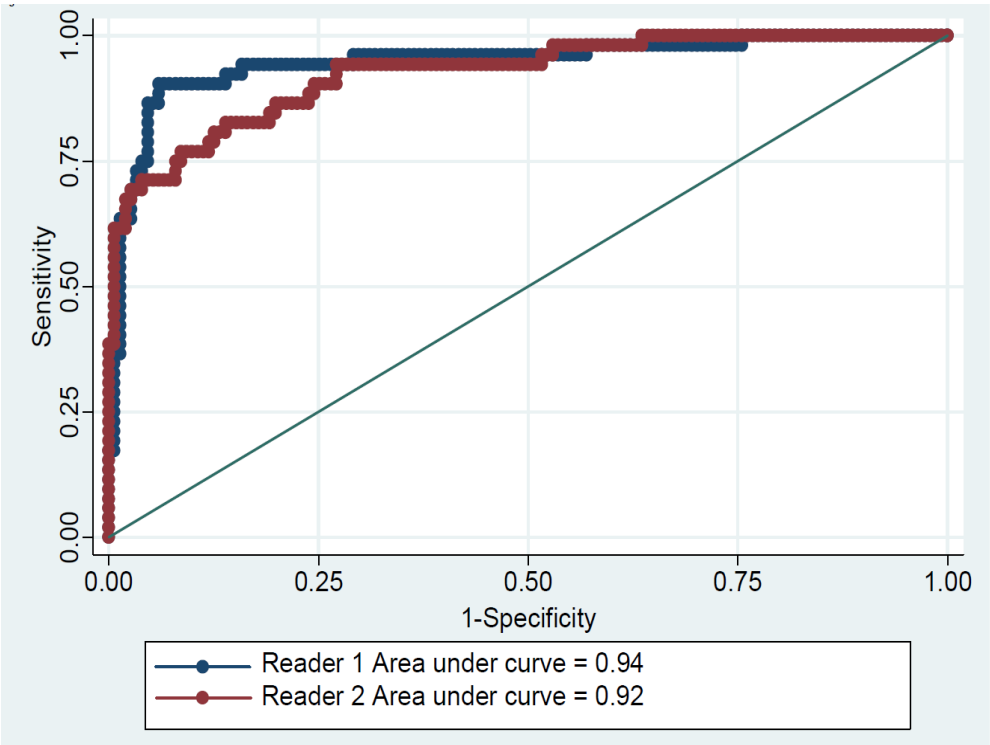

8.6 Discussion

This analysis has shown that in a patient group being carefully monitored by a combination of serial MR imaging, clinical assessment and biopsy, ADC monitoring can provide useful additional information that can potentially detect patients with tumour regrowth.

An ADC measurement cut-off of 1.3 $X10^{-3}/mm^2/sec$ gave the optimum sensitivity and specificity for detection of tumour, with values of $<1.3X10^{-3}/mm^2/sec$ giving an 86% sensitivity for tumour regrowth. The less than 100% sensitivity and specificity is due to inherent fluctuation in ADC values in patients with sustained complete response. For example 18% (28/152) of the scans undertaken in patients with sustained complete response showed ADC values of less than $1.3X10^{-3}/mm^2/sec$ despite the absence of any residual tumour. On the other hand in 11% (6/55) of scans in patients with biopsy confirmed tumour regrowth ADC values were above the proposed cut off of $1.3X10^{-3}/mm^2/sec$. Therefore a consistently elevated ADC value is of reassurance in the context of serial monitoring but an ADC value of $<1.3X10^{-3}/mm^2/sec$ should alert the clinical team to the possibility of tumour regrowth and consider a biopsy of the lesion.

This study also demonstrates that both mrTRG and ADC values continue to change long after completion of radiotherapy. If we had only entered patients that were in definite initial complete response, 27% (11/41) patients would not have been enrolled. Therefore our data supports the hypothesis that complete response can occur at a variable time period following completion of chemoradiotherapy and therefore early biopsy is not helpful in predicting eventual complete response (Evans, Tait et al. 2011).

One of the limitations of this study is the variable treatment given and time taken to refer the patient to our institution for follow-up. This reflects the inherent delays between completion of preoperative therapy and seeking an opinion as an alternative to surgery. Furthermore, not all referring centres in this study employed diffusion weighted imaging in their initial tumour assessment.

In this study T2-weighted high resolution images were used to identify the site of tumour and to guide the placement of region of interest on ADC images, diffusion weighted imaging and high resolution T2-weighted scans were not directly compared. However, since diffusion weighted imaging is a non anatomical technique it does not permit assessment of T and N stage. Therefore we cannot recommend this DWI to replace anatomic staging methods. The two independent observers in this study used T2 weighted imaging to guide ROI placement on ADC maps and achieved similar performance for area under ROC curves. Therefore this technique appears reproducible.

8.7 Conclusions

Patients eligible for deferral of surgery approach can be identified using the mrTRG grading system. Using incremental mrTRG response as selection criteria enables many more patients, who would otherwise have missed the opportunity to avoid surgery, to be identified. This study presents encouraging results using the combination of imaging, clinical assessment and biopsy in detecting regrowth. It has been shown that the early identification of patients who may have tumour regrowth could be assisted by utilising ADC values to alert the clinical team and undertake biopsy accordingly.

Based on the results; in patients with an apparent radiological and clinical complete response an ADC measurement of 1.3 $X10^{-3}/mm^2/sec$ or less should prompt a biopsy of the region of interest since this was associated with tumour regrowth in 86% of cases.

9 Overall discussion

9.1 Study endpoints

Many studies referenced in this thesis have focused on the identification of complete pathological response (Maretto, Pomerri et al. 2007; Curvo-Semedo, Lambregts et al. 2011). However, looking only for pCR may underestimate the benefit of treatments as it is also clear from chapter 6 that patients with a good response that falls short of pathological complete response also have equally good survival outcomes. Pathological pCR maybe a controversial endpoint as sampling between studies is not undertaken using a standardised protocol. Therefore this thesis has focused on distinguishing good and poor response rather than identifying complete pathological response and also used survival as an endpoint in Chapter 5.

9.2 Post treatment MRI TRG, T stage, N stage and CRM assessment

Several approaches to accurately restage residual tumour/fibrosis post CRT have been investigated by this thesis. The background review had shown that the definitions of residual tumour, treatment response and treatment effects showed promise, but needed further characterisation. Furthermore, the accuracy of any proposed refined system of T, N and CRM assessment had not been assessed against pathology or survival endpoints in a multicentre multireader setting. The accuracy of post chemoradiation MRI tumour regression system had not been assessed against histopathological or survival endpoints or compared against the existing standard of T staging.

9.2.1 Observational findings

In chapter 4 pathological slides were matched to post treatment MRI images, this confirmed several proposals: low signal on T2 MRI represents fibrosis, intermediate signal- tumour, high signal with intermediate components-mucinous tumour and uniform high signal mucinous response. This observational data characterising fibrosis has subsequently been supported by Franklin et al (Franklin, Anderson et al. 2012). In this retrospective analysis of 168 patients treated with neoadjuvant chemoradiation 20 patients had complete pathological response. Seven/twenty had no visible tumour on post treatment MRI, in 11 patients the tumour was replaced by a region of at least 50% low signal on MRI, 8/20 having >80% low signal, and 3 with 100% low signal.

Degrees of treatment response and residual tumour form the basis of the MRI tumour regression grading system, while relation of residual tumour to the bowel wall and CRM enable MRI T staging and potential CRM involvement assessment respectively. Nodal assessment criteria based on MRI signal heterogeneity and border characteristics had already been proposed by Koh et al (Koh, Chau et al. 2008).

9.2.2 mrTRG and ymrT assessment

9.2.2.1 mrTRG

mrTRG showed good diagnostic accuracy against T stage pathology in ROC analysis conducted in chapters 4, 5 and 7, with the area under the curve in these analyses 0.85, 0.82 and 0.84 respectively. Kappa agreement between post MRI T stage and T stage pathology in chapters 4 and 5 was fair. Likewise ROC analysis showed a fair degree of diagnostic accuracy of post treatment MRI T stage and pathological TRG. When post-treatment T stage was broadly grouped into favourable and unfavourable categories, a significant relationship was observed using logistic regression analysis.

Overall, mrTRG showed a good, but not excellent, diagnostic accuracy against pathology. However, in Chapter 6 when MRI parameters were evaluated against survival; MR assessment of TRG predicted survival outcomes for good and poor responders before definitive surgery. Furthermore, mrTRG remained significant in multivariate analysis against pathological measures.

The reason for mrTRG's strong relationship with outcome measures but good relationship with pathological endpoints maybe due to pathological sampling. Chetty et al have recently suggested sampling as a source of inconsistency in pathological TRG assessment, with the authors' proposing a cumulative regression score, taking into account all sections from the tumour bed, to accurately reflect treatment response (Chetty, Gill et al. 2012). Improving pathological sampling may improve radiological-pathological correlation given MR images the entire tumour volume.

As discussed in section 1.2.6, difficulties also arise in interpretation and coding of pathological appearances particularly with regard to distinguishing extra mural vascular invasion from nodal and tumour deposits. Although all trials in this thesis used TNM 5 criteria to ensure standardisation, how an extramural nodule should be coded is uncertain and may be a source of discrepancy between pathology and survival endpoints.

9.2.2.2 ymrT

ymrT was not significantly associated with survival outcomes, In chapter 6, more cases were assessed as favourable by mrTRG but unfavourable by ymrT and this is likely to have made the difference in survival outcomes. The possible reason for this is small foci of extramural tumour within larger areas of fibrosis being assessed as unfavourable by ymrT but favourable by mrTRG.

A recent 2012 retrospective study by Nougaret et al investigated the relationship between MRI parameters and survival outcomes. This study (n=58) grouped ymrT 0-T3b as favourable (n=38) and ymrT3c-4 as unfavourable (n=20). On univariate analysis favourable ymrT was associated with improved disease free survival; hazard ratio 5.2 (95% CI 1.60-11.61); p=0.038, this was not a significant factor on multivariate analysis (Nougaret, Rouanet et al. 2012). Regrouping the MERCURY ymrT data using this classification (Appendix 1), shows no significance for outcome measures. These differences may be due to the MERCURY ymrT analysis taking place prospectively by each local centres radiologist while the Nougaret analysis was retrospective with two central reviewers.

9.2.3 MRI Nodal status and CRM assessment

Chapter 4 also showed post treatment MRI's ability to identify node negative disease and a potentially clear CRM was high, however ability to predict involved nodes and potentially involved CRM was lower at 60% and 49% respectively. In chapter 6, a significant relationship between MRI nodal status with overall and disease free survival was seen on multivariate analysis with hazard ratios of 1.89 and 2.09 respectively. However the lower limits of the confidence intervals were 1.006 and 1.06 respectively. Therefore nodal status maybe less important as high quality TME surgery removes mesorectal nodes.

Despite MRI showing a relatively low ability to predict a potentially involved CRM post CRT in chapter 4, ymrCRM independently predicted local recurrence on multivariate analysis in chapter 6. Nougaret et al reported similar results, with the 49 patients with a predicted clear CRM on MRI post CRT showing improved disease free survival compared

to the 9 patients with potentially involved CRM on MRI post treatment [HR 3.9 (95% CI 1.79-17.56); p=0.003] (Nougaret, Rouanet et al. 2012). The discrepancy between poor post treatment MRI CRM prediction versus pathology but ymrCRM being a significant survival factor may again be due to inadequate pathological sampling techniques leading to false negative pathological CRM. Future studies matching pathological tumour cell density with MRI images may improve interpretation.

9.2.4 Summary

Across the analysis presented in this thesis mrTRG has shown a good diagnostic accuracy verses pathology and is a significant survival parameter. Grouping post treatment T stage was significantly associated with pathology but not survival. Overall, as a result of this work it is recommended that mrTRG, ymrCRM, ymrT and ymrN parameters are evaluated by multivariate analysis in prospective multicentre trials using survival outcomes. In the meantime it is recommended that mrTRG, ymrCRM as well as ymrT are evaluated by experienced radiologists in a multidisciplinary team format.

While awaiting further studies mapping MRI fibrosis at resection margins with pathology, it is recommended that fibrosis at the potential CRM on MRI, using the criteria defined in this thesis, should be fully resected.

9.3 MRI volume and length response assessment methods

As well as ymrT and mrTRG, rectal cancer volume and length reduction post treatment have been proposed to assess response. Prior to this thesis there had been no studies comparing the diagnostic accuracy of post chemoradiation volume reduction post treatment and modified RECIST length measurement with more established techniques such as T staging or other proposed approaches such as MRI tumour regression grading.

For the analysis undertaken in Chapter 5, a single slice method previously described by Torkzad and Dresden et al (Torkzad, Lindholm et al. 2007; Dresen, Beets et al. 2009) was used to assess tumour volume. Tumours showing a reduction in length and volume assessment were more likely to have a favourable pathological outcome compared to tumours showing a lesser reduction/stability. However when MRI length data was assessed according to favourable and unfavourable pathological groups, the two distributions showed considerable overlap. A similar pattern was also seen for MRI volume data.

While this thesis was being undertaken, several groups have published data correlating tumour volume change using workstation based techniques against both pathology and survival outcomes (tables 9.1 and 9.2).

Table 9.1. Studies Correlating workstation calculated tumour volume change against pathology

Authors, Patient Number, Recruitment Dates	Pathology results. (Absolute numbers of patients).	Volume vs. pathology results.
(Yeo, Kim et al. 2009). n=405 May 2002-Dec 2007	pCR=58 ypT0–2 =189 ypT3-4 =216 pTRG3-4=120 pTRG1-2=285	Classifications; ypT0-T2 vs. ypT3-T4, Good regression (TRG 3-4 vs. TRG 1-2), Complete regression (TRG 4 vs. TRG 1-3). Tumour volume reduction ratio (TVRR) of >60% (n=140), was significantly associated with favourable ypT0-T2; (p=0.009). TVRR of >80% (n=42) was significantly associated with favourable pTRG3-4; (p=0.002). A tumour volume reduction ratio >80% (n=25) correlated with pathological complete response (p = 0.002).
(Kang, Kim et al. 2010). n=84 May 2002-Dec 2007	pCR=16 ypT0=18 , ypT1=2, ypT2=15, ypT3= 45 ypT4=4 pTRG1=18,pTRG2=29 pTRG3=15,pTRG4= 20 pTRG5= 2	TVRR>75% (n=12), correlated with pathological complete response (p = 0.01), but not favourable ypT or pTRG response.
(Sun, Zhang et al. 2010). n=37 Dec 2005- Nov 2008	The end point was tumour downstaging; defined as pathological T stage lower than initial MRI T stage Downstaged = 17 Nondownstaged = 20	The absolute tumour volume in the downstaged group was significantly lower than that in the nondownstaged group- Presurgery volumes 2.77 Vs. 6.94 cm^3 ;(p= 0.022). The mean percentage rate of tumour volume reduction was not significantly different in the two groups; (p = 0.276).
(Lambrecht, Vandecaveye et al. 2012). n=20 Recruitment dates not stated	pCR=6 ypT0–2 =11 ypT3-4 =9	TVRR between baseline and mid CRT correlated significantly with pathological complete response; (p=0.015) and ypT0–2 stage; (p=0.0039), TVRR of >45% allowed for a prediction of pCR with a sensitivity of 83%, a specificity of 71%. (Absolute figures not given). Volume reduction between baseline and CRT completion correlated significantly with pathological complete response only (p=0.012). A cutoff value of >77%, yielded a sensitivity of 83%, a specificity of 86%.

Table 9.2. Studies Correlating workstation calculated tumour volume change against survival

Authors, Patient Number, Recruitment Dates	Pathology & Survival absolute number of patients	Volume vs. survival results
(Nougaret, Rouanet et al. 2012). n=58 May 2004-May 2008	ypT0=9, ypT1/2 =25, ypT3 =21, ypT4 =3 pTRG1=21, pTRG2=13, pTRG3=15, pTRG4=9 Mean follow-up 52 months +/- 20. Metastatic disease at diagnosis; n=5, lost to follow-up; n=2. Therefore n=51; 16/51 had local recurrence after a median 20 months +/- 10.	Significantly improved disease free survival in those with a tumour volume reduction of at least 70% (n=30/51) vs. those with a TVRR of less than 70% (n=21/51) [HR 13.7: 95% CI 3.98-31.93; (p <0.0001)]. Absolute survival rates not given. TVRR of at least 70% (n=25/58) was found to be significantly associated with good histologic regression grade (pTRG3/4); (p <0.0001). Correlation against ypt data not stated. Unclear why number of patients with TVRR of at least 70% is 30 for the survival results and 25 for the pathology results.
(Yeo, Kim et al. 2012). n=340 May 2002-March 2008*	ypT0=68, ypTis= 6 ypT1 =21, ypT2 =112 ypT3 =208, ypT4 =15 At 5 years; disease recurrence developed in 99 patients after a median 18 months (range, 3–77 months), 55 patients died	Multivariate analysis results; Disease free survival was significantly better in patients with TVRR ratio of ≥45% (n = 62) than in those with total volume reduction ratio of <45% (n = 37; p < 0.001). Overall survival was also significantly better in patients with TVRR ≥45% (n = 34) than in those with TVRR <45% (n = 21; p < 0.001)

*Retrospective analysis using some of the same patients as the 2009 study.

Overall workstation based studies have several limitations; firstly no prospective, multicentre study has directly compared workstation volume measurement with RECIST and other MRI assessment approaches. Secondly the use of a workstation has not been proven superior to a single slice based technique. Thirdly some studies enrolled a high proportion of T3/4 tumours that at baseline had a relatively low volume. This may affect the generalisability of the results into clinical practice. For example in Yeo et al's study 204/408 patients had a baseline tumour volume of <14cm^3, while in the chapter 3 dataset, baseline tumour volume was 58cm^3 (Yeo, Kim et al. 2012). Finally, as table 9.1 and 9.2 show, a variety of cut off values of volume reduction have been proposed by different authors.

Given the additional time consumed in manually tracing tumour volumes on workstation and varying cut-off values proposed in the literature it is suggested a multivariate analysis

is carried out comparing volume with other parameters. Given the level of reproducibility of MRI RECIST observed in this thesis, this method of assessment is best used in a trial setting with an experienced single central reviewer.

9.4 Tumour response for rectal cancer treated with chemotherapy

MRI's ability to identify good and poor responders to chemotherapy, using histopathological reference standards, had not been tested at the beginning of this thesis.

In chapter 7 a prospective comparison was undertaken of mrTRG and ymrT and MRI RECIST measurements to determine which of these modalities best predicted final histopathology following preoperative chemotherapy and which was the most reproducible parameter. ROC analysis showed mrTRG had a good diagnostic accuracy for pathological TRG, while ymrT's accuracy was fair. The results are similar to chapters 4&5. No association between pathological TRG and MRI RECIST measurement was found.

This analysis also showed mrTRG to have a moderate level of reproducibility at 0.41 between the 7 reading radiologists, this is lower than demonstrated in chapter 4 (mrTRG κ=0.55). ymrT was less also reproducible in this analysis at 0.25, lower than demonstrated in chapter 4 (ymrT κ=0.41). The reasons for the lower level of reproducibility maybe due to the relatively small number of patients in this study as well as 4 of the readers not being specialist GI radiologists.

This is the first study to show that 'intermediate risk' rectal tumours can respond to chemotherapy alone, and radiotherapy can be selectively used in those with progressive disease on MRI. MRI ymrT and mrTRG can be used to predict pathological response in this setting. This approach can be analysed further in phase II trials with MRI defined high risk patients and phase III trials with MRI defined intermediate risk patients.

For example BACCHUS (Bevacizumab and Combination Chemotherapy in Rectal Cancer until Surgery) is a randomised phase II study investigating the efficacy, toxicity and feasibility of two different chemotherapy regimes in patients with resectable rectal cancer where preoperative MRI suggests adverse features such as EMVI, but the CRM is not threatened. Radiotherapy is not planned unless the patient has progressed on restaging MRI (Glynne-Jones, Anyamene et al. 2012). Given the degree of MRI monitored downstaging observed in the present study with intermediate risk patients, a future trial by the GEMCAD group aims to investigate the efficacy of neoadjuvant chemotherapy in MRI defined high risk patients, this study will be the first to use mrTRG to restage, with selective use of radiotherapy in those with MRI poor response (figure 9.1). If the efficacy and safety of this approach is proven, there will a substantial change in the treatment of rectal cancer patients.

Figure 9.1. Neoadjuvant chemotherapy for MRI defined high risk rectal cancer

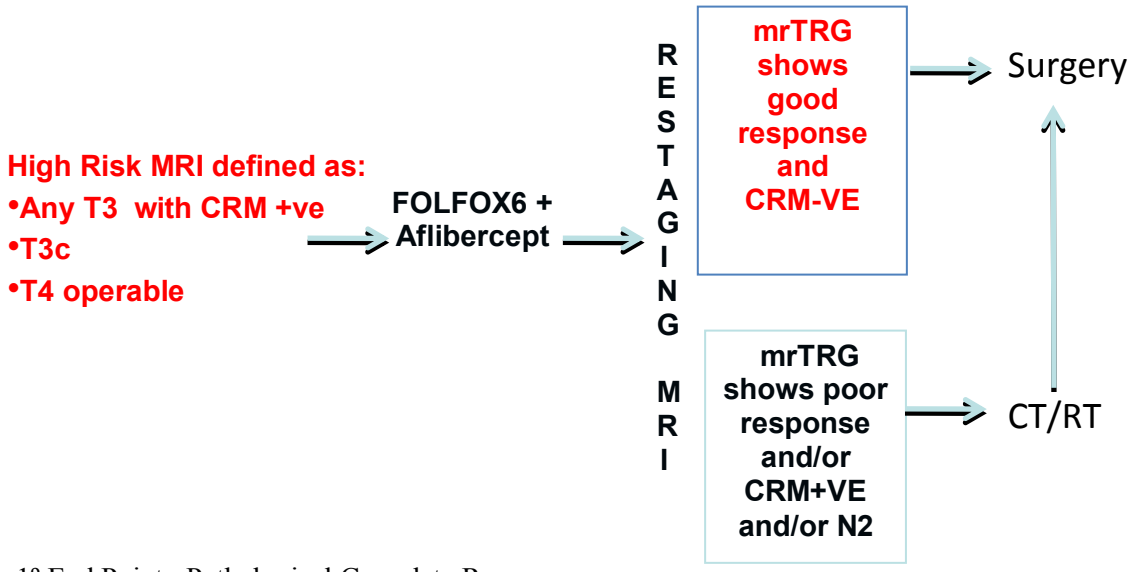

1º End Point: Pathological Complete Response.
2º End Points: mrTRG, % Patients spared radiotherapy, 3 and 5 year Local recurrence, toxicity, 3yr disease free survival.

This thesis has shown that rectal tumours can respond to chemotherapy alone, and radiotherapy can be selectively used in those with progressive disease on MRI. The safety of this approach can be assessed in phase III trials with MRI defined intermediate risk patients. Neoadjuvant chemotherapy's ability to provide disease control in MRI defined high risk patients can also evaluated in future phase II trials. It is recommended that mrTRG, ymrCRM as well as ymrT are evaluated by experienced radiologists in these future studies.

9.5 The role of MRI in patients deferring surgery following good response to chemoradiation

9.5.1 Clinical considerations

To date the criteria used to identify patients for entry into a possible deferral of surgery program has largely been based on clinical and biopsy assessment at an unspecified time after completion of chemoradiotherapy (Habr-Gama, Perez et al. 2004). The role of imaging in identifying and monitoring patients had not been explored at the inception of this thesis. Futhermore, although diffusion weighted imaging indices appear to change during treatment, (Dzik-Jurasz, Domenig et al. 2002) , there had not been any investigation of the role for diffusion weighed imaging in surveillance.

The Royal Marsden Hospital deferral of surgery study uses imaging to guide eligibility. Given good correlation with pathology, survival and high reproducibility in other analysis, mrTRG is used for eligibility assessment. Eligibility is assessed by serial post CRT imaging, with those showing incremental tumour response considered. Those with nodal disease are also eligible. These criteria enabled 41 patients to be recruited between 2006-2011; with 11/41 patients showing continued response 6-8 weeks post CRT completion.

Results from a Dutch deferral of surgery cohort have recently been published. The inclusion criteria for this trial included: 1) Substantial tumour downsizing with no residual tumour or with fibrosis only on restaging MRI performed 6 to 8 weeks after CRT, 2) No suspicious nodes on post CRT MRI, 3) No residual tumour at endoscopy with negative biopsies, and 4) No palpable tumour at digital rectal examination when palpable at primary presentation. The eligibility criteria for this study are narrower than the Royal Marsden Study and has led to a lower rate of patient recruitment, with 21 patients enrolled between 2004-2010.

The follow up schedules between the cohort enrolled in this thesis and the Dutch study also vary, with more frequent use of clinical examination, CEA and MRI for The Royal Marsden group, particularly in the first two years when 90% (9/10 cases) of tumour regrowth in was observed.

Due to relatively wide criteria 10 patients showed tumour regrowth in The Royal Marsden Group, while 1 patient has relapsed in the Dutch cohort. One patient in The Royal Marsden Group had extramural relapse within the mesorectum which was not palpable/visible on digital rectal examination or sigmoidoscopy. This pattern of relapse has not been previously described and emphasises the importance of combining imaging with clinical surveillance in deferral of surgery patients.

The data presented in this thesis is part of an ongoing trial evaluating the safety and efficacy of a deferral strategy in patients who are not necessarily in complete response at time of recruitment. The safety and efficacy of this approach will only be known when the results of long-term follow-up are available. When the initial phase II trial of the study is

complete, a logical future Phase III trial could investigate eligibility criteria for deferral of surgery; patients could be randomised between clinical assessment and selection based on negative biopsy versus imaging assessment of mrTRG1-2 and serial imaging. Potential endpoints could be overall stoma free survival and the number of patient successfully deferred at 3, 5 and 10 years.

9.5.2 Diffusion weighted imaging

In the chapter 8 analysis, the mean ADC value of scans coded as complete response during surveillance was significantly higher than scans showing residual/recurrent tumour. An ADC threshold of $<1.3\ X10^{-3}/mm^2/sec$ give a high sensitivity and specificity for tumour detection. Several groups have recently published investigations into how rectal cancer ADC values change during chemoradiation. These are summarised in table 9.3.

The data from Sun and Barbaro et al is supportive of the observations of this thesis, with favourable pathological responders showing higher mean ADC values/ greater mean percentage increase in ADC values than nonresponders (Sun, Zhang et al. 2010; Barbaro, Vitale et al. 2012). The proposed ADC cutoffs presented by Barbaro and Kim et al, in cohorts of patients not deferring surgery, are surprisingly consistent and supportive of the ADC cut off value of $1.3\ X10^{-3}/mm^2/sec$ proposed in this thesis especially considering the differences in parameters and technique used (Kim, Lee et al. 2009; Barbaro, Vitale et al. 2012).

However, caution is advised in using pretreatment ADC values/ increases in ADC during CRT / applying an ADC threshold to a one-off post treatment MRI scan for the selection of patients for surveillance. Instead, as up to 27% of enrolled patients in Chapter 8, show an evolving response beyond the conventional 6-8 week window, it is proposed that tumour response is monitored, and patient eligibility for deferral of surgery is assessed by serial post CRT imaging. Employing serial monitoring is likely to enable a substantially greater rate of recruitment of initially advanced cancers.

Combining DWI data with mrTRG T2 weighted imaging is likely to be useful in determining eligibility for deferral of surgery as recent studies have shown improvement in the ability of radiologists to select pathological complete responders compared with standard T2 weighted MRI only (Kim, Lee et al. 2009; Lambregts, Vandecaveye et al. 2011). This question could not be assessed in this thesis as most referring centres did not use diffusion weighted imaging sequences and is a topic for future investigation.

As shown in chapter 8, fluctuations in ADC values occur during surveillance, it is therefore recommended that an ADC value of <1.3X10-3/mm2/sec should alert the clinical team to the possibility of tumour regrowth and biopsy of the lesion is considered. The utility of this strategy could be employed in future trials investigating deferral of surgery strategies.

Table 9.3. Studies investigating tumour ADC change pre and post chemoradiation

Authors, Patient Number, Scan timing.	Pathology endpoints.	Results.
(Kim, Lee et al. 2009). n=40 Imaged at 2 timepoints before and after CRT.	pCR=11 Non pCR=29	Mean ADC (1.62 +/-0.36X 10^{-3} mm^2/s) of the pCR group (n=11) was significantly higher than that (1.04 +/- 0.24X10^{-3} mm^2/s) of the non-CR group (n=29) (p=0 .0001). A cut off ADC value of 1.2X10^{-3}/mm^2/sec after CRT had an accuracy of 85% in distinguishing those with pCR vs. non pCR.
(Sun, Zhang et al. 2010). n=37 4 timepoints Before CRT, At the end of the 1st & 2nd weeks of CRT, after CRT	The end point was downstaging; defined as pathological T stage lower than initial MRI T stage. Downstaged = 17 Nondownstaged=20	At the end of the 1st week of CRT, the mean tumour ADC increased significantly in the downstaged group vs. the nondownstaged group (mean ADC, 1.32X10^{-3} mm^2/s vs. 1.22 10^{-3} mm^2/s; p=0 .001). At the end of the 2nd week of CRT, a further increase in ADCs was seen in both groups. Before surgery, the ADC decreased slightly in both groups. The overall mean percentage tumour ADC change was significantly different between the two groups (p=0.001).
(Barbaro, Vitale et al. 2012). n=62 Imaged at 3 timepoints Before, During (10-14 days after initiation) After CRT.	Histopathologic downstaging and Mandard tumour regression grade. pTRG1/pCR=16 pTRG2=13 pTRG3=21 pTRG4=12 Downstaged=37 Nondownstaged=25	Low pretreatment ADCs (<1.0 X10^{-3} mm^2/s) were correlated with pTRG4 (p=0.0011), but not downstaging. During treatment, the mean percentage increase in tumour ADC was significantly higher in those downstaged vs. those with stable disease (p < 0.0001). The mean percentage ADC increase in the pTRG 1 and 2 groups was significantly greater than the pTRG 3 and 4 groups (p= 0.011). The preoperative ADC was significantly different (p= 0.0012) between the downstaged group vs. the nondownstaged group. A cutoff value of 1.4X10^{-3} mm^2/s had a PPV of 79%, a NPV of 62%, and an accuracy for response assessment of 68%
(Lambrecht, Vandecaveye et al. 2012). n=20	pCR=6 ypT0–2 =11 ypT3-4 =9 T downstaging=12 Nondownstaged=8	The mean tumour ADC value before treatment was significantly lower in patients with pCR vs. no pCR (0.94 +/- 0.12 X10^{-3} mm^2/s and 1.19 +/- 0.22 X 10^{-3} mm^2/s, p = 0.003). Both during and early after CRT a significantly higher ADC change was found in patients with pCR compared with non pCR patients. No significant correlation between ADC and pathological T0-T2 or T downstaging.

10 Final Conclusions

This thesis has characterised the imaging appearances of post treatment response and residual tumour and validated different MRI assessment methods of response evaluation against histopathology and survival outcomes. From the work presented in this thesis the following conclusions can be made;

By matching MRI with pathology slides, pathological fibrosis correlates with low signal on MRI and tumour corresponds to intermediate signal. mrTRG was a significant factor in overall and disease free survival but in three different datasets mrTRG showed a good, but not excellent, diagnostic accuracy for pathological endpoints. This discrepancy maybe due to difficulties in accurate pathological sampling and coding.

ymrT showed only a fair level of diagnostic accuracy against pathology, which improved with grouping of ymrT into favourable and unfavourable categories, but was not a significant factor in survival.

Negative ymrN and potentially clear ymrCRM correlated with negative ypN and negative pCRM respectively. Despite the fair level of agreement between a potentially involved margin on MRI and a pathologically involved margin, post chemoradiation MRI CRM was an important outcome measure. Post treatment nodal status was a borderline outcome measure.

Length and volume assessment showed less significant correlation with pathology than other parameters. However, recent studies have shown tumour volume reduction and ymrT to be a significant outcome measures.

Serial MRI based monitoring using diffusion weighted imaging was useful in detecting tumour recurrence in patients enrolled into a deferral of surgery trial. The performance and reproducibility of mrTRG, ymrT, CRM assessment as well as length and volume assessment maybe improved by combination with qualitative/quantitative diffusion weighted imaging data.

mrTRG and ymrCRM appear to be the most important parameters to evaluate in post treatment MRI imaging. Grouped post treatment T stage may also be useful. Slice by slice workstation tumour volume calculation using workstations is time consuming and should be compared against other approaches. Potential improvement in interpretation using diffusion weighted imaging can also be investigated in further studies.

Post chemoradiation MRI has an important role in patient management, as assessing treatment response prior to surgery gives the multidisciplinary team an opportunity to tailor treatment. mrTRG and ymrCRM could be linked with clinical practice by the following approach; Patients with mrTRG1/2 and ymrCRM negative, may be offered inclusion into a surveillance programme as presented in chapter 8. Intermediate patients (mrTRG3 and ymrCRM negative) could proceed to TME plane surgery. Individuals with a potentially

involved CRM post treatment and/or more advanced mrTRG grades would be eligible for further chemotherapy or exenteration surgery.

11 Bibliography

Office for National Statistics (2011), Cancer Statistics registrations: Registrations of cancer diagnosed in 2010. **Series MB1**

Adam, I. J., M. O. Mohamdee, et al. (1994). "Role of circumferential margin involvement in the local recurrence of rectal cancer." Lancet **344**(8924): 707-711.

Allen, S. D., A. R. Padhani, et al. (2007). "Rectal carcinoma: MRI with histologic correlation before and after chemoradiation therapy." AJR Am J Roentgenol **188**(2): 442-451.

Andreola, S., E. Leo, et al. (1997). "Distal intramural spread in adenocarcinoma of the lower third of the rectum treated with total rectal resection and coloanal anastomosis." Dis Colon Rectum **40**(1): 25-29.

Astler, V. B. and F. A. Coller (1954). "The prognostic significance of direct extension of carcinoma of the colon and rectum." Ann Surg **139**(6): 846-852.

Barbaro, B., C. Fiorucci, et al. (2009). "Locally advanced rectal cancer: MR imaging in prediction of response after preoperative chemotherapy and radiation therapy." Radiology **250**(3): 730-739.

Barbaro, B., R. Vitale, et al. (2012). "Diffusion-weighted magnetic resonance imaging in monitoring rectal cancer response to neoadjuvant chemoradiotherapy." Int J Radiat Oncol Biol Phys **83**(2): 594-599.

Beets-Tan, R. G., G. L. Beets, et al. (2001). "Accuracy of magnetic resonance imaging in prediction of tumour-free resection margin in rectal cancer surgery." Lancet **357**(9255): 497-504.

Bjerkeset, T., I. Morild, et al. (1987). "Tumor characteristics in colorectal cancer and their relationship to treatment and prognosis." Dis Colon Rectum **30**(12): 934-938.

Blomqvist, L., M. Machado, et al. (2000). "Rectal tumour staging: MR imaging using pelvic phased-array and endorectal coils vs endoscopic ultrasonography." Eur Radiol **10**(4): 653-660.

BMJGuidelines. (2012, 7.3.12). "Best Practice Guidelines on Colo-rectal Cancer http://bestpractice.bmj.com/best-practice/monograph/258/treatment/details.html." Retrieved 1.3.12, 2012.

Brown, G. (2005). "Thin section MRI in multidisciplinary pre-operative decision making for patients with rectal cancer." Br J Radiol **78 Spec No 2**: S117-127.

Brown, G., I. Chau, et al. (2003). "MRI of rectal cancer enables accurate patient selection for chemoradiotherapy and post-therapy prediction of tumour free resection margins " ASCO Annual Meeting Proc Am Soc Clin Oncol 22: 2003 (abstr 1120)

Brown, G., S. Davies, et al. (2004). "Effectiveness of preoperative staging in rectal cancer: digital rectal examination, endoluminal ultrasound or magnetic resonance imaging?" Br J Cancer **91**(1): 23-29.

Brown, G., A. Kirkham, et al. (2004). "High-resolution MRI of the anatomy important in total mesorectal excision of the rectum." AJR Am J Roentgenol **182**(2): 431-439.

Brown, G., A. G. Radcliffe, et al. (2003). "Preoperative assessment of prognostic factors in rectal cancer using high-resolution magnetic resonance imaging." Br J Surg **90**(3): 355-364.

Brown, G., C. J. Richards, et al. (2003). "Morphologic predictors of lymph node status in rectal cancer with use of high-spatial-resolution MR imaging with histopathologic comparison." Radiology **227**(2): 371-377.

Brown, G., C. J. Richards, et al. (1999). "Rectal carcinoma: thin-section MR imaging for staging in 28 patients." Radiology **211**(1): 215-222.

Bujko, K., W. Michalski, et al. (2007). "Association between pathologic response in metastatic lymph nodes after preoperative chemoradiotherapy and risk of distant metastases in rectal cancer: An analysis of outcomes in a randomized trial." Int J Radiat Oncol Biol Phys **67**(2): 369-377.

Bujko, K., M. P. Nowacki, et al. (2006). "Long-term results of a randomized trial comparing preoperative short-course radiotherapy with preoperative conventionally fractionated chemoradiation for rectal cancer." Br J Surg **93**(10): 1215-1223.

Capirci, C., V. Valentini, et al. (2008). "Prognostic value of pathologic complete response after neoadjuvant therapy in locally advanced rectal cancer: long-term analysis of 566 ypCR patients." Int J Radiat Oncol Biol Phys **72**(1): 99-107.

Cecil, T. D., R. Sexton, et al. (2004). "Total mesorectal excision results in low local recurrence rates in lymph node-positive rectal cancer." Dis Colon Rectum **47**(7): 1145-1149; discussion 1149-1150.

Cercek, A., Weiser, MR, Goodman, KA . (2010). "Complete pathological response in the primary of rectal or colon cancer treated with FOLFOX without radiation." J Clin Oncol **28 (15S Suppl, May 20 Supplement):** (297s (Abstr 3649).).

Chau, I., M. Allen, et al. (2003). "Neoadjuvant systemic fluorouracil and mitomycin C prior to synchronous chemoradiation is an effective strategy in locally advanced rectal cancer." Br J Cancer **88**(7): 1017-1024.

Chau, I., G. Brown, et al. (2006). "Neoadjuvant capecitabine and oxaliplatin followed by synchronous chemoradiation and total mesorectal excision in magnetic resonance imaging-defined poor-risk rectal cancer." J Clin Oncol **24**(4): 668-674.

Chen, C. C., R. C. Lee, et al. (2005). "How accurate is magnetic resonance imaging in restaging rectal cancer in patients receiving preoperative combined chemoradiotherapy?" Dis Colon Rectum **48**(4): 722-728.

Chessin, D. B., J. Hartley, et al. (2005). "Rectus flap reconstruction decreases perineal wound complications after pelvic chemoradiation and surgery: a cohort study." Ann Surg Oncol **12**(2): 104-110.

Chetty, R., P. Gill, et al. (2012). "Pathological grading of regression: an International Study Group perspective." Journal of Clinical Pathology **65**(10): 865-866.

Chung, C. K., J. A. Stryker, et al. (1983). "Patterns of failure following surgery alone for colorectal carcinoma." J Surg Oncol **22**(1): 65-70.

Cohen, A. M., W. C. Wood, et al. (1980). "Pathological studies in rectal cancer." Cancer **45**(12): 2965-2968.

Cohen, S. M., L. Brown, et al. (1981). "Multiple metaplastic (hyperplastic) polyposis of the colon." Gastrointest Radiol **6**(4): 333-335.

Curvo-Semedo, L., D. M. Lambregts, et al. (2011). "Rectal cancer: assessment of complete response to preoperative combined radiation therapy with chemotherapy--conventional MR volumetry versus diffusion-weighted MR imaging." Radiology **260**(3): 734-743.

de Haas-Kock, D. F., C. G. Baeten, et al. (1996). "Prognostic significance of radial margins of clearance in rectal cancer." Br J Surg **83**(6): 781-785.

de Lange, E. E., R. E. Fechner, et al. (1992). "Rectal carcinoma treated by preoperative irradiation: MR imaging and histopathologic correlation." AJR Am J Roentgenol **158**(2): 287-292.

DeLong, E. R., D. M. DeLong, et al. (1988). "Comparing the areas under two or more correlated receiver operating characteristic curves: a nonparametric approach." Biometrics **44**(3): 837-845.

Devries, A. F., J. Griebel, et al. (2001). "Tumor microcirculation evaluated by dynamic magnetic resonance imaging predicts therapy outcome for primary rectal carcinoma." Cancer Res **61**(6): 2513-2516.

Dinter, D. J., K. Horisberger, et al. (2009). "Can dynamic MR imaging predict response in patients with rectal cancer undergoing cetuximab-based neoadjuvant chemoradiation?" Onkologie **32**(3): 86-93.

Doyle, V. J. and A. C. Bateman (2012). "Colorectal cancer staging using TNM 7: is it time to use this new staging system?" J Clin Pathol **65**(4): 372-374.

Dresen, R. C., G. L. Beets, et al. (2009). "Locally advanced rectal cancer: MR imaging for restaging after neoadjuvant radiation therapy with concomitant chemotherapy. Part I. Are we able to predict tumor confined to the rectal wall?" Radiology **252**(1): 71-80.

Dukes, C. E. (1932.). "The classification of cancer of the rectum." J Pathol **35**: 323.

Dworak, O., L. Keilholz, et al. (1997). "Pathological features of rectal cancer after preoperative radiochemotherapy." Int J Colorectal Dis **12**(1): 19-23.

Dzik-Jurasz, A., C. Domenig, et al. (2002). "Diffusion MRI for prediction of response of rectal cancer to chemoradiation." Lancet **360**(9329): 307-308.

Evans, J., D. Tait, et al. (2011). "Timing of surgery following preoperative therapy in rectal cancer: the need for a prospective randomized trial?" Dis Colon Rectum **54**(10): 1251-1259.

Fernandez-Martos, C., C. Pericay, et al. (2010). "Phase II, randomized study of concomitant chemoradiotherapy followed by surgery and adjuvant capecitabine plus oxaliplatin (CAPOX) compared with induction CAPOX followed by concomitant chemoradiotherapy and surgery in magnetic resonance imaging-defined, locally advanced rectal cancer: Grupo cancer de recto 3 study." J Clin Oncol **28**(5): 859-865.

Firbank MJ, Harrison RM, et al. (2000). " Quality assurance for MRI: practical experience." Br J Radiol **73**(868):376-83.

Francois, Y., C. J. Nemoz, et al. (1999). "Influence of the interval between preoperative radiation therapy and surgery on downstaging and on the rate of sphincter-sparing surgery for rectal cancer: the Lyon R90-01 randomized trial." J Clin Oncol **17**(8): 2396.

Franklin, J. M., E. M. Anderson, et al. (2012). "MRI features of the complete histopathological response of locally advanced rectal cancer to neoadjuvant chemoradiotherapy." Clin Radiol **67**(6): 546-552.

Futterer, J. J., D. Yakar, et al. (2008). "Preoperative 3T MR imaging of rectal cancer: local staging accuracy using a two-dimensional and three-dimensional T2-weighted turbo spin echo sequence." Eur J Radiol **65**(1): 66-71.

Gabriel, W. and H. Bussey (1935). "Lymphatic spread in cancer of the rectum. ." Br J Surg **23**: 395-413.

Gerard, J. P., T. Conroy, et al. (2006). "Preoperative radiotherapy with or without concurrent fluorouracil and leucovorin in T3-4 rectal cancers: results of FFCD 9203." J Clin Oncol **24**(28): 4620-4625.

Gervaz, P., L. Rubbia-Brandt, et al. (2010). "Neoadjuvant chemotherapy in patients with stage IV colorectal cancer: a comparison of histological response in liver metastases, primary tumors, and regional lymph nodes." Ann Surg Oncol **17**(10): 2714-2719.

Glynne-Jones, R., N. Anyamene, et al. (2012). "Neoadjuvant chemotherapy in MRI-staged high-risk rectal cancer in addition to or as an alternative to preoperative chemoradiation?" Ann Oncol.

Goldstein, N. S. and J. R. Turner (2000). "Pericolonic tumor deposits in patients with T3N+MO colon adenocarcinomas: markers of reduced disease free survival and intra-abdominal metastases and their implications for TNM classification." Cancer **88**(10): 2228-2238.

Gray, R., J. Barnwell, et al. (2007). "Adjuvant chemotherapy versus observation in patients with colorectal cancer: a randomised study." Lancet **370**(9604): 2020-2029.

Grinnell, R. S. (1966). "Lymphatic block with atypical and retrograde lymphatic metastasis and spread in carcinoma of the colon and rectum." Ann Surg **163**(2): 272-280.

Gu, J., P. L. Khong, et al. (2011). "Quantitative assessment of diffusion-weighted MR imaging in patients with primary rectal cancer: correlation with FDG-PET/CT." Mol Imaging Biol **13**(5): 1020-1028.

Guillem, J. G., J. A. Diaz-Gonzalez, et al. (2008). "cT3N0 rectal cancer: potential overtreatment with preoperative chemoradiotherapy is warranted." J Clin Oncol **26**(3): 368-373.

Gunderson, L. L., J. M. Jessup, et al. (2010). "Revised tumor and node categorization for rectal cancer based on surveillance, epidemiology, and end results and rectal pooled analysis outcomes." J Clin Oncol **28**(2): 256-263.

Habr-Gama, A., R. O. Perez, et al. (2004). "Operative versus nonoperative treatment for stage 0 distal rectal cancer following chemoradiation therapy: long-term results." Ann Surg **240**(4): 711-717; discussion 717-718.

Habr-Gama, A., R. O. Perez, et al. (2011). "Nonoperative approaches to rectal cancer: a critical evaluation." Semin Radiat Oncol **21**(3): 234-239.

Halvorsen, R. A., Jr. and W. M. Thompson (1989). "Gastrointestinal cancer: diagnosis, staging, and the follow-up role of imaging." Semin Ultrasound CT MR **10**(6): 467-480.

Hartley, A., K. F. Ho, et al. (2005). "Pathological complete response following pre-operative chemoradiotherapy in rectal cancer: analysis of phase II/III trials." Br J Radiol **78**(934): 934-938.

Heald, R. J. (1988). "The 'Holy Plane' of rectal surgery." J R Soc Med **81**(9): 503-508.

Heald, R. J., E. M. Husband, et al. (1982). "The mesorectum in rectal cancer surgery--the clue to pelvic recurrence?" Br J Surg **69**(10): 613-616.

Heald, R. J. and R. D. Ryall (1986). "Recurrence and survival after total mesorectal excision for rectal cancer." Lancet **1**(8496): 1479-1482.

Hermanek P, H. D., Hutter RVP, Sobin LH . (1993). UICC TNM supplement 1993. A commentary on uniform use. UICC TNM supplement 1993. B. H. N. Y. Springer.

Hermanek, P., D. Henson, et al. (1993.). TNM Supplement. NY Inc, Springer-Verlag.

Hoffmann, K. T., B. Rau, et al. (2002). "Restaging of locally advanced carcinoma of the rectum with MR imaging after preoperative radio-chemotherapy plus regional hyperthermia." Strahlenther Onkol **178**(7): 386-392.

Howarth, S., J. Morgan, et al. (2006). "The new (6th edition) TNM classification of colorectal cancer: A stage too far." Gut **A21**(Suppl 3).

Hughes TG, J. E., Poulos E. (1983). "Intramural spread of colon carcinoma. A pathologic study." American Journal of Surgery **146**(6): 697-699.

Hunter, C. J., A. Garant, et al. (2012). "Adverse features on rectal MRI identify a high-risk group that may benefit from more intensive preoperative staging and treatment." Ann Surg Oncol **19**(4): 1199-1205.

Hussain, S. M., E. K. Outwater, et al. (1999). "Mucinous versus nonmucinous rectal carcinomas: differentiation with MR imaging." Radiology **213**(1): 79-85.

Iafrate, F., A. Laghi, et al. (2006). "Preoperative staging of rectal cancer with MR Imaging: correlation with surgical and histopathologic findings." Radiographics **26**(3): 701-714.

Ishii, Y., H. Hasegawa, et al. (2010). "Medium-term results of neoadjuvant systemic chemotherapy using irinotecan, 5-fluorouracil, and leucovorin in patients with locally advanced rectal cancer." Eur J Surg Oncol **36**(11): 1061-1065.

Jacoby, W. G. (2000). " Loess: a nonparametric, graphical tool for depicting relationships between variables." Electoral Studies **19**(1): 577–613.

Janjan, N. A., C. Crane, et al. (2001). "Improved overall survival among responders to preoperative chemoradiation for locally advanced rectal cancer." Am J Clin Oncol **24**(2): 107-112.

Jass, J. R., W. S. Atkin, et al. (1986). "The grading of rectal cancer: historical perspectives and a multivariate analysis of 447 cases." Histopathology **10**(5): 437-459.

Jass, J. R., S. B. Love, et al. (1987). "A new prognostic classification of rectal cancer." Lancet **1**(8545): 1303-1306.

Kang, J. H., Y. C. Kim, et al. (2010). "Tumor Volume Changes Assessed by Three-Dimensional Magnetic Resonance Volumetry in Rectal Cancer Patients After Preoperative Chemoradiation: The Impact of the Volume Reduction Ratio on the Prediction of Pathologic Complete Response." Int J Radiat Oncol Biol Phys **76**(4): 1018-1025.

Kapiteijn, E., C. A. Marijnen, et al. (2001). "Preoperative radiotherapy combined with total mesorectal excision for resectable rectal cancer." N Engl J Med **345**(9): 638-646.

Kim, D. J., J. H. Kim, et al. (2010). "Restaging of Rectal Cancer with MR Imaging after Concurrent Chemotherapy and Radiation Therapy." Radiographics **30**(2): 503-516.

Kim, H., J. S. Lim, et al. (2010). "Rectal cancer: comparison of accuracy of local-regional staging with two- and three-dimensional preoperative 3-T MR imaging." Radiology **254**(2): 485-492.

Kim, N. K., S. H. Baik, et al. (2006). "Oncologic outcomes after neoadjuvant chemoradiation followed by curative resection with tumor-specific mesorectal excision for fixed locally advanced rectal cancer: Impact of postirradiated

pathologic downstaging on local recurrence and survival." Ann Surg **244**(6): 1024-1030.

Kim, S. H., J. M. Lee, et al. (2009). "Locally advanced rectal cancer: added value of diffusion-weighted MR imaging in the evaluation of tumor response to neoadjuvant chemo- and radiation therapy." Radiology **253**(1): 116-125.

Knutsen, A., G. Adell, et al. (2006). "Inflammatory infiltration, fibrosis, necrosis and mucinous content in relation to clinicopathological and molecular factors in rectal cancers with or without preoperative radiotherapy." Oncol Rep **16**(2): 321-327.

Koh, D. M., G. Brown, et al. (2006). "Nodal staging in rectal cancer." Abdom Imaging **31**(6): 652-659.

Koh, D. M., G. Brown, et al. (2007). "Diagnostic accuracy of rim and segmental MRI enhancement of colorectal hepatic metastasis after administration of mangafodipir trisodium." AJR Am J Roentgenol **188**(2): W154-161.

Koh, D. M., G. Brown, et al. (2005). "Distribution of mesorectal lymph nodes in rectal cancer: in vivo MR imaging compared with histopathological examination. Initial observations." Eur Radiol **15**(8): 1650-1657.

Koh, D. M., G. Brown, et al. (2004). "Rectal cancer: mesorectal lymph nodes at MR imaging with USPIO versus histopathologic findings--initial observations." Radiology **231**(1): 91-99.

Koh, D. M., I. Chau, et al. (2008). "Evaluating mesorectal lymph nodes in rectal cancer before and after neoadjuvant chemoradiation using thin-section T2-weighted magnetic resonance imaging." Int J Radiat Oncol Biol Phys **71**(2): 456-461.

Koh, D. M. and A. R. Padhani (2006). "Diffusion-weighted MRI: a new functional clinical technique for tumour imaging." Br J Radiol **79**(944): 633-635.

Konishi, K., Y. Akita, et al. (2003). "Evaluation of endoscopic ultrasonography in colorectal villous lesions." Int J Colorectal Dis **18**(1): 19-24.

Kremser, C., W. Judmaier, et al. (2003). "Preliminary results on the influence of chemoradiation on apparent diffusion coefficients of primary rectal carcinoma measured by magnetic resonance imaging." Strahlenther Onkol **179**(9): 641-649.

Kuo, L. J., M. C. Chern, et al. (2005). "Interpretation of magnetic resonance imaging for locally advanced rectal carcinoma after preoperative chemoradiation therapy." Dis Colon Rectum **48**(1): 23-28.

Kuo, L. J., M. C. Liu, et al. (2007). "Is final TNM staging a predictor for survival in locally advanced rectal cancer after preoperative chemoradiation therapy?" Ann Surg Oncol **14**(10): 2766-2772.

Lambrecht, M., V. Vandecaveye, et al. (2012). "Value of diffusion-weighted magnetic resonance imaging for prediction and early assessment of response to neoadjuvant radiochemotherapy in rectal cancer: preliminary results." Int J Radiat Oncol Biol Phys **82**(2): 863-870.

Lambregts, D. M., V. Vandecaveye, et al. (2011). "Diffusion-weighted MRI for selection of complete responders after chemoradiation for locally advanced rectal cancer: a multicenter study." Ann Surg Oncol **18**(8): 2224-2231.

Lee, J. H., H. S. Jang, et al. (2012). "Lymphovascular invasion is a significant prognosticator in rectal cancer patients who receive preoperative chemoradiotherapy followed by total mesorectal excision." Ann Surg Oncol **19**(4): 1213-1221.

Linstrom, M. and D. Bates (1989). "Newton-Raphson and EM algorithms for linear mixed-effects models for repeated-measures data. ." Journal of the American Statistical Association **83**: 1014-1022.

Maas, M., D. M. Lambregts, et al. (2012). "T-staging of rectal cancer: accuracy of 3.0 Tesla MRI compared with 1.5 Tesla." Abdom Imaging **37**(3): 475-481.

Madsen, P. M. and J. Christiansen (1986). "Distal intramural spread of rectal carcinomas." Dis Colon Rectum **29**(4): 279-282.

MagneticResonanceTechnologyInformationPortal. (2007). "Sinerem." Retrieved 5.6.12, 2012.

Mandard, A. M., F. Dalibard, et al. (1994). "Pathologic assessment of tumor regression after preoperative chemoradiotherapy of esophageal carcinoma. Clinicopathologic correlations." Cancer **73**(11): 2680-2686.

Maretto, I., F. Pomerri, et al. (2007). "The potential of restaging in the prediction of pathologic response after preoperative chemoradiotherapy for rectal cancer." Ann Surg Oncol **14**(2): 455-461.

Marzouk O., S. J. (2011). "Review of Histopathological and Molecular Prognostic Features in Colorectal Cancer." Cancers **3**(2): 2767-2810.

Mayr, N. A., W. T. Yuh, et al. (2006). "Serial therapy-induced changes in tumor shape in cervical cancer and their impact on assessing tumor volume and treatment response." AJR Am J Roentgenol **187**(1): 65-72.

Mehta, S., R. J. Johnson, et al. (1994). "Staging of colorectal cancer." Clin Radiol **49**(8): 515-523.

MERCURY (2006). "Diagnostic accuracy of preoperative magnetic resonance imaging in predicting curative resection of rectal cancer: prospective observational study." BMJ **333**(7572): 779.

MERCURY (2007). "Thin section magnetic resonance imaging: Extramural depth of tumour invasion in patients with rectal cancer: results of the MERCURY study." Radiology **243**(1): 132-139.

Messerini, L., F. Cianchi, et al. (2006). "Incidence and prognostic significance of occult tumor cells in lymph nodes from patients with stage IIA colorectal carcinoma." Hum Pathol **37**(10): 1259-1267.

Michelassi, F., J. J. Ayala, et al. (1991). "Verification of a new clinicopathologic staging system for colorectal adenocarcinoma." Ann Surg **214**(1): 11-18.

Michelassi, F., S. Leuthner, et al. (1987). "Ras oncogene p21 levels parallel malignant potential of different human colonic benign conditions." Arch Surg **122**(12): 1414-1416.

Minsky, B. D. (2011). "Counterpoint: long-course chemoradiation is preferable in the neoadjuvant treatment of rectal cancer." Semin Radiat Oncol **21**(3): 228-233.

Moran, M. R., E. C. James, et al. (1992). "Prognostic value of positive lymph nodes in rectal cancer." Dis Colon Rectum **35**(6): 579-581.

Nagtegaal, I. D., M. J. Gosens, et al. (2007). "Combinations of tumor and treatment parameters are more discriminative for prognosis than the present TNM system in rectal cancer." J Clin Oncol **25**(13): 1647-1650.

Nagtegaal, I. D., Marijnen CAM (2008). "The future of TNM staging in rectal cancer: The era of Neoadjuvant therapy." Current colorectal cancer reports. **4**: 147-154.

Nagtegaal, I. D. and P. Quirke (2010). "Revised staging: is it really better, or do we not know?" J Clin Oncol **28**(23): e397-398; author reply e399-400.
Nagtegaal, I. D., T. Tot, et al. (2011). "Lymph nodes, tumor deposits, and TNM: are we getting better?" J Clin Oncol **29**(18): 2487-2492.
Nagtegaal, I. D., C. J. van de Velde, et al. (2002). "Macroscopic evaluation of rectal cancer resection specimen: clinical significance of the pathologist in quality control." J Clin Oncol **20**(7): 1729-1734.
Nakagawa, W. T., B. M. Rossi, et al. (2002). "Chemoradiation instead of surgery to treat mid and low rectal tumors: is it safe?" Ann Surg Oncol **9**(6): 568-573.
Nascimbeni, R., L. J. Burgart, et al. (2002). "Risk of lymph node metastasis in T1 carcinoma of the colon and rectum." Dis Colon Rectum **45**(2): 200-206.
Ngan, F., Goldstein (2010). A randomized trial comparing local recurrence (LR) rates between short course (SC) and long course (LC) radiotherapy (RT) for clinical T3 rectal cancer: an Intergroup (TROG, AGITG, CSSANZ, RACS). Proc Am Soc Clin Oncol. **28:** 15.
NICE. (2011). "Colorectal cancer: The diagnosis and management of colorectal cancer http://publications.nice.org.uk/colorectal-cancer-cg131/guidance." Retrieved 13.3.12, 2012.
Nougaret, S., P. Rouanet, et al. (2012). "MR Volumetric Measurement of Low Rectal Cancer Helps Predict Tumor Response and Outcome after Combined Chemotherapy and Radiation Therapy." Radiology **263**(2): 409-418.
O'Neill, B. D., G. Brown, et al. (2007). "Non-operative treatment after neoadjuvant chemoradiotherapy for rectal cancer." Lancet Oncol **8**(7): 625-633.
Ono, C., K. Yoshinaga, et al. (2002). "Discontinuous rectal cancer spread in the mesorectum and the optimal distal clearance margin in situ." Dis Colon Rectum **45**(6): 744-749; discussion 742-743.
Palmer, J. A., C. P. Vernon, et al. (1983). "Gracilis myocutaneous flap for reconstructing perineal defects resulting from radiation and radical surgery." Can J Surg **26**(6): 510-512.
Petersen, S. H., H. Harling, et al. (2012). "Postoperative adjuvant chemotherapy in rectal cancer operated for cure." Cochrane Database Syst Rev **3**: CD004078.
Pettersson, D., B. Cedermark, et al. (2010). "Interim analysis of the Stockholm III trial of preoperative radiotherapy regimens for rectal cancer. ." Br J Surg **97**: 580-587.
Pihl, E., R. C. Nairn, et al. (1980). "Mucinous colorectal carcinoma: immunopathology and prognosis." Pathology **12**(3): 439-447.
Poultsides, G. A., F. Bao, et al. (2012). "Pathologic Response to Preoperative Chemotherapy in Colorectal Liver Metastases: Fibrosis, not Necrosis, Predicts Outcome." Ann Surg Oncol.
Pricolo, V. E. (2011). "Rectal cancer: the good, the bad, and the ugly." Arch Surg **146**(5): 544.
Pricolo, V. E., A. Abodeely, et al. (2010). "Distal margins in radical resections for rectal cancer after chemoradiation therapy: how short is long enough?" Dig Surg **27**(3): 185-189.
Puppa, G., A. Sonzogni, et al. (2010). "TNM staging system of colorectal carcinoma: a critical appraisal of challenging issues." Arch Pathol Lab Med **134**(6): 837-852.

Quirke, P., C. Cuvelier, et al. (2010). "Evidence-based medicine: the time has come to set standards for staging." J Pathol **221**(4): 357-360.
Quirke, P. and M. F. Dixon (1988). "The prediction of local recurrence in rectal adenocarcinoma by histopathological examination." Int J Colorectal Dis **3**(2): 127-131.
Quirke, P., P. Durdey, et al. (1986). "Local recurrence of rectal adenocarcinoma due to inadequate surgical resection. Histopathological study of lateral tumour spread and surgical excision." Lancet **2**(8514): 996-999.
Quirke, P. and E. Morris (2007). "Reporting colorectal cancer." Histopathology **50**(1): 103-112.
Quirke, P., G. T. Williams, et al. (2007). "The future of the TNM staging system in colorectal cancer: time for a debate?" Lancet Oncol **8**(7): 651-657.
Ratto, C. and R. Ricci (2011). "Potential pitfalls concerning colorectal cancer classification in the seventh edition of the AJCC Cancer Staging Manual." Dis Colon Rectum **54**(8): e232.
Reischauer, C., B. J. Wilm, et al. (2011). "High-resolution diffusion tensor imaging of prostate cancer using a reduced FOV technique." Eur J Radiol **80**(2): e34-41.
Rodel, C., P. Martus, et al. (2005). "Prognostic significance of tumor regression after preoperative chemoradiotherapy for rectal cancer." J Clin Oncol **23**(34): 8688-8696.
Rutten, H., D. Sebag-Montefiore, et al. (2006). "Capecitabine, oxaliplatin, radiotherapy, and excision (CORE) in patients with MRI-defined locally advanced rectal adenocarcinoma: Results of an international multicenter phase II study." ASCO Meeting Abstracts **24**: 3528.
Saclarides, T. J., A. K. Bhattacharyya, et al. (1994). "Predicting lymph node metastases in rectal cancer." Dis Colon Rectum **37**(1): 52-57.
Sasaki, O., W. S. Atkin, et al. (1987). "Mucinous carcinoma of the rectum." Histopathology **11**(3): 259-272.
Sauer, R., H. Becker, et al. (2004). "Preoperative versus postoperative chemoradiotherapy for rectal cancer." N Engl J Med **351**(17): 1731-1740.
Schofield, J. B., N. A. Mounter, et al. (2006). "The importance of accurate pathological assessment of lymph node involvement in colorectal cancer." Colorectal Dis **8**(6): 460-470.
Schrag, D., Weiser MR, Goodman KA et al (2010). "Neoadjuvant FOLFOX-bev, without radiation for locally advanced rectal cancer." J Clin Oncol **28 (15S Suppl)** (263s (Abstr 3511).).
Secco, G. B., R. Fardelli, et al. (1994). "Primary mucinous adenocarcinomas and signet-ring cell carcinomas of colon and rectum." Oncology **51**(1): 30-34.
Seierstad, T., K. H. Hole, et al. (2009). "MR-guided simultaneous integrated boost in preoperative radiotherapy of locally advanced rectal cancer following neoadjuvant chemotherapy." Radiother Oncol **93**(2): 279-284.
Shia, J., M. McManus, et al. (2011). "Significance of acellular mucin pools in rectal carcinoma after neoadjuvant chemoradiotherapy." Am J Surg Pathol **35**(1): 127-134.
Shihab, O. C., B. J. Moran, et al. (2009). "MRI staging of low rectal cancer." Eur Radiol **19**(3): 643-650.

Shihab, O. C., P. Quirke, et al. (2010). "Magnetic resonance imaging-detected lymph nodes close to the mesorectal fascia are rarely a cause of margin involvement after total mesorectal excision." Br J Surg **97**(9): 1431-1436.

Shirouzu, K., H. Isomoto, et al. (1991). "A prospective clinicopathologic study of venous invasion in colorectal cancer." Am J Surg **162**(3): 216-222.

Smith, N. J., Y. Barbachano, et al. (2008). "Prognostic significance of magnetic resonance imaging-detected extramural vascular invasion in rectal cancer." Br J Surg **95**(2): 229-236.

Smith, N. J., O. Shihab, et al. (2008). "MRI for detection of extramural vascular invasion in rectal cancer." AJR Am J Roentgenol **191**(5): 1517-1522.

Smith, N. J., Y. Barbachano, A. R. Norman, R. I. Swift, A. M. Abulafi and G. Brown (2008). " Prognostic significance of magnetic resonance imaging-detected extramural vascular invasion in rectal cancer." Br J Surg **95**(2): 229-236.

Sobin, L. and C. Wittekind (2009). International Union Against Cancer (UICC). TNM classification of malignant tumours., Wiley.

Sobin, L. H., C. A. Compton, et al. (2010). "'Evidence-based medicine: the time has come to set standards for staging'. Is a radical overhaul really needed?" J Pathol **221**(4): 361-362.

Sobin, L. H. and F. L. Greene (2001). "TNM classification: clarification of number of regional lymph nodes for pN0." Cancer **92**(2): 452.

Sobin, W. C. (1997). TNM Classification of Malignant Tumours. New York, John Wiley & Sons, Inc.

Spratt JA, S. H. (1967). "Prevalence and prognosis of carcinoma of the colon and rectum." Cancer **20**: 1976-1985.

Suarez, J., R. Vera, et al. (2008). "Pathologic response assessed by Mandard grade is a better prognostic factor than down staging for disease-free survival after preoperative radiochemotherapy for advanced rectal cancer." Colorectal Dis **10**(6): 563-568.

Sugimura, K., B. M. Carrington, et al. (1990). "Postirradiation changes in the pelvis: assessment with MR imaging." Radiology **175**(3): 805-813.

Sun, Y. S., X. P. Zhang, et al. (2010). "Locally advanced rectal carcinoma treated with preoperative chemotherapy and radiation therapy: preliminary analysis of diffusion-weighted MR imaging for early detection of tumor histopathologic downstaging." Radiology **254**(1): 170-178.

SwedishRectalCancerTrial (1997). "Improved survival with preoperative radiotherapy in resectable rectal cancer. Swedish Rectal Cancer Trial." N Engl J Med **336**(14): 980-987.

Taylor, F. G., P. Quirke, et al. (2011). "Preoperative high-resolution magnetic resonance imaging can identify good prognosis stage I, II, and III rectal cancer best managed by surgery alone: a prospective, multicenter, European study." Ann Surg **253**(4): 711-719.

Taylor, F. G., R. I. Swift, et al. (2008). "A systematic approach to the interpretation of preoperative staging MRI for rectal cancer." AJR Am J Roentgenol **191**(6): 1827-1835.

Theodoropoulos, G., W. E. Wise, et al. (2002). "T-level downstaging and complete pathologic response after preoperative chemoradiation for advanced rectal cancer

result in decreased recurrence and improved disease-free survival." Dis Colon Rectum **45**(7): 895-903.

Therasse, P., S. G. Arbuck, et al. (2000). "New guidelines to evaluate the response to treatment in solid tumors. European Organization for Research and Treatment of Cancer, National Cancer Institute of the United States, National Cancer Institute of Canada." J Natl Cancer Inst **92**(3): 205-216.

Tominaga, K., Y. Nakanishi, et al. (2005). "Predictive histopathologic factors for lymph node metastasis in patients with nonpedunculated submucosal invasive colorectal carcinoma." Dis Colon Rectum **48**(1): 92-100.

Torkzad, M. R., J. Lindholm, et al. (2007). "MRI after preoperative radiotherapy for rectal cancer; correlation with histopathology and the role of volumetry." Eur Radiol **17**(6): 1566-1573.

Ueno, H., A. M. Jones, et al. (2004). "Histological categorization of fibrotic cancer stroma in advanced rectal cancer." Gut **53**(4): 581-586.

Ueno, H., H. Mochizuki, et al. (2012). "Optimal colorectal cancer staging criteria in TNM classification." J Clin Oncol **30**(13): 1519-1526.

Ueno, H., H. Mochizuki, et al. (2007). "Extramural cancer deposits without nodal structure in colorectal cancer: optimal categorization for prognostic staging." Am J Clin Pathol **127**(2): 287-294.

Valentini, V., C. Coco, et al. (2002). "Does downstaging predict improved outcome after preoperative chemoradiation for extraperitoneal locally advanced rectal cancer? A long-term analysis of 165 patients." Int J Radiat Oncol Biol Phys **53**(3): 664-674.

Vecchio, F. M., V. Valentini, et al. (2005). "The relationship of pathologic tumor regression grade (TRG) and outcomes after preoperative therapy in rectal cancer." Int J Radiat Oncol Biol Phys **62**(3): 752-760.

Vliegen, R. F., G. L. Beets, et al. (2008). "Mesorectal fascia invasion after neoadjuvant chemotherapy and radiation therapy for locally advanced rectal cancer: accuracy of MR imaging for prediction." Radiology **246**(2): 454-462.

Vogl, T. J., W. Pegios, et al. (1997). "Accuracy of staging rectal tumors with contrast-enhanced transrectal MR imaging." AJR Am J Roentgenol **168**(6): 1427-1434.

Wheeler, J. M., B. F. Warren, et al. (2002). "Quantification of histologic regression of rectal cancer after irradiation: a proposal for a modified staging system." Dis Colon Rectum **45**(8): 1051-1056.

Willett, C. G., K. Badizadegan, et al. (1999). "Prognostic factors in stage T3N0 rectal cancer: do all patients require postoperative pelvic irradiation and chemotherapy?" Dis Colon Rectum **42**(2): 167-173.

Williams, G., P. Quirke, et al. (2007) "Dataset for colorectal cancer (2nd edition)." http://www.rcpath.org/Resources/RCPath/Migrated%20Resources/Documents/G/G049-ColorectalDataset-Sep07.pdf.

Wittekind, C., D. Henson, et al. (2003). TNM Supplement: A Commentary on Uniform Use. 3rd ed. . New Jersey, John Wiley & Sons.

Wittekind, C., D. Henson, et al. (2002). TNM Supplement: A Commentary on Uniform Use, 2nd Edition.

Wu, Y., Y. Y. Wu, et al. (2011). "TEM and conventional rectal surgery for T1 rectal cancer: a meta-analysis." Hepatogastroenterology **58**(106): 364-368.

Wynn, T. A. (2008). "Cellular and molecular mechanisms of fibrosis." J Pathol **214**(2): 199-210.

Yeo, S. G., D. Y. Kim, et al. (2009). "Tumor Volume Reduction Rate Measured by Magnetic Resonance Volumetry Correlated with Pathologic Tumor Response of Preoperative Chemoradiotherapy for Rectal Cancer." Int J Radiat Oncol Biol Phys.

Yeo, S. G., D. Y. Kim, et al. (2010). "Tumor volume reduction rate measured by magnetic resonance volumetry correlated with pathologic tumor response of preoperative chemoradiotherapy for rectal cancer." Int J Radiat Oncol Biol Phys **78**(1): 164-171.

Yeo, S. G., D. Y. Kim, et al. (2012). "Tumor volume reduction rate after preoperative chemoradiotherapy as a prognostic factor in locally advanced rectal cancer." Int J Radiat Oncol Biol Phys **82**(2): e193-199.

Yu, S., G. Brown, et al. (2011). "Deferral of rectal surgery following a continued response to preoperative chemoradiotherapy (Watch and Wait) study: A phase II multicenter study in the United Kingdom." ASCO J Clin Oncol 29: 2011 (suppl 4; abstr 489)

Zeestraten, E. C., P. J. Kuppen, et al. (2012). "Prediction in rectal cancer." Semin Radiat Oncol **22**(2): 175-183.

Zerhouni, E. A., C. Rutter, et al. (1996). "CT and MR imaging in the staging of colorectal carcinoma: report of the Radiology Diagnostic Oncology Group II." Radiology **200**(2): 443-451.

12 Appendix 1 Regrouping of MERCURY survival data

Re-Grouping of chapter 6, MERCURY data, with ymrT 0-T3b considered favourable and ymrT3c-T4 considered unfavourable as per Nougaret et al (Nougaret, Rouanet et al. 2012). Twelve cases were recoded.

No significant difference between favourable and unfavourable ymrT groups by overall survival, p=0.63 (figure 1), disease free survival p=0.1 or local recurrence p=0.9. Log rank test used.

Figure 1. Recoded ymrT and overall survival

