STUDIES ON ISOSPORAN COCCIDIA OF MAMMALS, INCLUDING MAN

by

Miles Berkeley Markus, B.Sc., M.Sc. (Pretoria),
M.Sc. (Medical Parasitology) (London)

Thesis submitted in fulfilment of the requirements for the degree of Doctor of Philosophy of the University of London

Imperial College Field Station,
Ashurst Lodge,
Sunninghill,
Ascot,
Berkshire

November 1975

To my parents

ABSTRACT

Toxoplasma, Sarcocystis and Isospora are three of the six described genera of Coccidia (Phylum Protozoa, Subphylum Sporozoa or Apicomplexa) having oocysts of the "isosporan" type, containing two sporocysts, each with four sporozoites. Aspects of the life-cycles and transmission of these organisms that have not previously been studied or have received scant attention were examined in relation to human infections and infections in other mammals. Part I of the thesis deals with the parasite outside the host and Part II with the parasite inside the host.

Toxoplasma gondii and Isospora felis were isolated from soil in urban areas, emphasising the key role played by the oocyst in transmission. Experiments were conducted on the survival of I. felis in soil. It was found experimentally that coccidian oocysts of vertebrates can pass undamaged through the digestive tracts of invertebrates; and that wild flies can carry isosporan oocysts. These observations, together with others on the movement of coprophagous flies in the field have thrown new light on ways in which oocysts might reach animals and man. The discussion includes a section on the risk of human infection by Toxoplasma oocysts.

The results of attempted infection of cats (successful) and chimpanzees (unsuccessful) with Sarcocystis are discussed in conjunction with a review of the life-cycle and relationships of Sarcocystis. Phenomena hitherto unexplained are clarified and taxonomic comments are made.

The causative organisms in an outbreak of disease in a herd of cattle in Canada in the early 1960's (named "Dalmeny disease") and unidentified Protozoa involved in some other infections of mammals recorded in the literature, are considered to have been Sarcocystis spp.

It is concluded that insufficient information is currently available on antibody production in Sarcocystis infections to enable serological tests to be used for diagnosis of intestinal infections in man or carnivorous mammals, as has been attempted by some workers. The question of common antigenicity between Toxoplasma and other isosporan coccidia is discussed in relation to the interpretation of serological tests for human toxoplasmosis.

Studies of I. felis in cats and in normal and immunosuppressed mice and chickens have elucidated aspects of the life-cycle: small mammals and birds might serve as intermediate hosts; and infection of cats can take place through carnivorism.

Twenty-one printed contributions on various subjects, written subsequent to the author's registration for the Ph.D. degree, are submitted as subsidiary matter.

CONTENTS

	Page
Abstract	3
Acknowledgements	7
Introduction	9
Materials and Methods	11
Part I: Survival and dissemination of oocysts in the environment	
Historical review	21
Environmental contamination by isosporan oocysts	21
Invertebrates as transport hosts for coccidian oocysts	25
Results	29
Isolation of *Toxoplasma gondii* from soil	29
Isolation of *Isospora felis* from soil	40
Survival of *Isospora felis* in soil in the laboratory	50
Infectivity of oocysts from the gut of earthworms and worm casts	52
Survival of sporocysts of *Sarcocystis* in flies in the laboratory	55
Occurrence of oocysts in wild-caught flies	56
Movements of flies in relation to the transport of oocysts	61
Movement to human food from cat faeces	61
Movement to cattle from dog/human faeces	62
Discussion	67
Significance for man of the occurrence of oocysts of *Toxoplasma gondii* in the environment	67
Earthworms and *Toxoplasma gondii* oocysts	73
The role of filth flies in the transmission of bovine sarcosporidiosis and other coccidial infections	75
Part II: Development of *Sarcocystis* and *Isospora* in tissues of their vertebrate hosts	
Historical review	92
Life-cycle of *Sarcocystis*	92
Intestinal isosporan coccidia of non-human Primates	112
Development of coccidia of mammals in "abnormal" hosts	115

Page

Results 120

Prevalence of Sarcocystis in cattle, sheep, swine and horses in Britain 120

Sporocysts of Sarcocystis of cattle in cats 122

Attempted infection of chimpanzees with cattle Sarcocystis ... 134

Attempted infection of mice with sporocysts of cattle Sarcocystis from cat faeces 136

Isospora felis in the mesenteric lymph node of the cat ... 142

Isospora felis in normal and immunosuppressed mice and chickens 143

Discussion 162

Susceptibility of different hosts to intestinal infection with cattle Sarcocystis 162

Life-cycle of Sarcocystis 163

Systematic relationship of Sarcocystis to Hammondia, Besnoitia, Frenkelia and Toxoplasma 181

Identification of coccidia in the faeces of naturally infected cats and dogs 184

Serology of human sarcosporidiosis 189

Specificity of serological tests for human toxoplasmosis ... 193

Extra-intestinal infections of Isospora felis 196

References 197

Subsidiary matter 244

ACKNOWLEDGEMENTS

I am most grateful to Dr. E. U. Canning, my supervisor, for her encouragement and support; and for critically reading Part I of the manuscript. I am also indebted to Prof. P. C. C. Garnham, Dr. R. Killick-Kendrick and other colleagues for their interest in this work. Facilities at the Field Station were kindly provided by the Director, Prof. T. R. E. Southwood.

In addition to persons mentioned in Markus et al., 1974 (see "Subsidiary Matter", No. 18), I wish to thank the following:-

Prof. J. K. A. Beverley (Dept. of Medical Microbiology, University of Sheffield), for providing comparative material of Toxoplasma.

Dr. C. C. Draper and Mr. S. Thaver (Ross Institute, London School of Hygiene and Tropical Medicine), for bleeding the chimpanzees and for assistance in carrying out the indirect fluorescent antibody tests.

Dr. R. Fayer (Animal Parasitology Institute (U.S. Dept. of Agriculture), Beltsville) and Dr. A. J. Johnson (Division of Pathology, Walter Reed Army Institute of Research, Washington, D.C.), who kindly provided Prof. P. C. C. Garnham with comparative material of Sarcocystis for use in Markus et al., 1974, the photomicrographs from which have been included here.

Dr. D. G. Fleck (Public Health Laboratory, St. George's Hospital), for carrying out the dye-tests for Toxoplasma.

Dr. L. P. Joyner (Central Veterinary Laboratory, Weybridge), for supplying Eimeria tenella oocysts.

The Meat Inspectors (Reading Abattoir), for their cooperation.

Mr. J. P. Nicholas (Imperial College Field Station), for the patience he showed in holding cats and in assisting with proof-reading over the past few years.

Mr. A. C. Pont (Department of Entomology, British Museum (Natural History)), for assistance with the identification of flies.

I am grateful to Carole Collins for her efficient typing of the thesis; and to Glynis Carter for transferring many of the references for the thesis from my reprints on to sheets for subsequent alphabetical arrangement. Dr. R. Killick-Kendrick and Antonia Reeve kindly assisted with the printing of photomicrographs.

This work was supported by the South African Medical Research Council, The British Council and the S.A. Council for Scientific and Industrial Research (travel grant).

INTRODUCTION

Sporulated oocysts of the "isosporan" type contain two sporocysts, each with four sporozoites, and have been known for many years to occur in the faeces of vertebrates. The mammals in which these disporocystid, tetrazoic oocysts are formed, are mainly carnivorous. Until the discovery by Hutchison et al. (1969, 1970, 1971), Frenkel et al. (1970), Dubey et al. (1970a) and other authors of an isosporan phase in the life-cycle of Toxoplasma gondii, coccidial infections in which isosporan oocysts were produced had been regarded as restricted to the intestines of the hosts. The discovery of the oocyst of T. gondii indicated the probability that coccidian - type gametogony would also be found to occur in closely related genera. It was soon shown (Rommel et al., 1972) that Sarcocystis had an intestinal phase culminating in production of isosporan oocysts. Besnoitia also undergoes gametogony in carnivorous mammals (Peteshev et al., 1974; Wallace and Frenkel, 1975). It would seem, from the descriptions of Besnoitia oocysts given by these authors, that oocysts found in experimental cats and dogs by Rommel (1975) were those of Besnoitia. To date, an oocyst stage of the related Frenkelia has not been reported,* although attempts have been made to ascertain whether gametogony take place (Tadros, 1970). Closer study of small isosporan oocysts in faeces of carnivores resulted in the isolation in the U.S.A. of undescribed organisms from cat faeces which showed similarities to both Toxoplasma and Sarcocystis (Wallace, 1973a, 1974, 1975; Frenkel et al., 1974) and have been designated as a new genus, Hammondia (see Frenkel, 1974; Frenkel and Dubey, 1975a, b).

The fact that T. gondii can cause serious disease in animals and man, including both fatal congenital and post-natally acquired infections, is well-known. Whether Toxoplasma - like organisms such as Hammondia are pathogenic for man, has yet to be established. Because of the pantropism

---

* Since discovered by Rommel and Krampitz (1975).

of the recently discovered schizonts of Sarcocystis in bovines (Fayer and Johnson, 1973; 1974) and sheep (Gestrich et al., 1974; Munday et al., 1975) and the fact that man is now known to shed Sarcocystis (i.e. Isospora hominis) oocysts and sporocysts after eating raw beef and pork, this protozoon has assumed a new medical and veterinary significance. The long-term effects of chronic infections of Isospora - type coccidia are largely unknown and the pathogenicity in acute cases may sometimes be greater than hitherto suspected - e.g. Dalmeny disease, the causative organism of which is now considered to have been Sarcocystis (see Markus et al., 1974). On these grounds alone, this group is worthy of study.

The knowledge that T. gondii and Sarcocystis have stages in the faeces of carnivores has made it easier to understand how extra-intestinal infections are so frequently acquired by animals and man. Whereas the high prevalence of Sarcocystis in old cattle and sheep can be largely explained by their close contact with dogs, it is more difficult to explain outbreaks of toxoplasmosis in sheep in open pastures, where they appear to have relatively little contact with the feline hosts to which the isosporan stages of T. gondii are restricted. Having recognised the essential part played by the oocyst in the epizootiology of toxoplasmosis, several authors have attempted to correlate the prevalence of active toxoplasmosis or of antibodies to T. gondii or seroconversion in man with the ownership of, or degree of contact with, cats. In this investigation, however, the oocyst has been studied in its natural environment of soil and water and consideration has been given to ways in which oocysts might reach animals and man. Some aspects of the development of Sarcocystis and Isospora in their respective hosts have also been studied.

The results are presented and discussed in two sections: the first part of the thesis deals with the parasite outside the host and the second with the parasite inside the host.

MATERIALS AND METHODS

Experimental animals

Day-old, coccidia-free Ranger or Apollo cockerels were obtained from Ross Poultry Limited, Andover. They were placed in metal cages and given water ad lib. and chick starter mash No. 508 (which is coccidiostat-free) from British Oil and Cake Mills Limited (B.O.C.M.).

Swiss LACA mice originally obtained as *category 4 specific pathogen-free (S.P.F.) animals from the Medical Research Council's (M.R.C.) Laboratory Animals Centre, Carshalton, were kept as a breeding stock under ordinary laboratory conditions at the Imperial College Field Station. Caesarian derived T.O. mice were supplied direct by A. Tuck & Son Limited, Rayleigh (M.R.C. accredited breeders and recognised suppliers) and the animals used had not been bred at the Field Station. Mice were maintained by normal laboratory methods. The caging of mice following infection is described in the "Results" section of Part I.

The basic diet of chimpanzees at the London School of Hygiene and Tropical Medicine (those used belonged to this institution) was apples, oranges, grapes, bananas, water and milk, supplemented by food such as eggs.

Conventionally reared kittens were bought from pet shops. *Category 3 S.P.F. kittens were supplied by Hill Grove Family Farm Limited, Minster Lovell, Oxford (M.R.C. accredited breeders and recognised suppliers).

---

*Manual Series No. 1, The Accreditation and Recognition Schemes for Suppliers of Laboratory Animals (July 1969), Medical Research Council Laboratory Animals Centre, M.R.C. Laboratories, Woodmansterne Road, Carshalton, Surrey.

Precautions were taken to maintain S.P.F. cats coccidia-free. These were successful. A heated (thermostatically controlled) room in which cats had not previously been kept was thoroughly washed down and treated with ammonia solution and boiling water to kill any oocysts present. Cats were housed in metal cages, which had been sterilized in the same way, on a large table in the centre of the room. While they were being maintained coccidia-free, the cats were allowed to exercise (often for long periods) only on the table. As the room had a filtered air supply, an inner door was frequently kept closed. The outer door was locked. All cat maintenance was carried out by the author and no other person was permitted to enter the inner room. Special shoes and laboratory coats were used in the room. Cats were handled with disposable rubber gloves. White river sand was used for litter trays and was sterilized several times before being stored in the cat room. The sand was heated to approximately 250°F. for about half an hour each time in a Camplex electric soil sterilizer, $\frac{1}{4}$ cubic yard capacity (manufactured by The Simplex Dairy Equipment Company Limited, Horticultural Division, Cambridge).

Cats were fed "International" tinned full cream evaporated milk (International Stores Limited, Mitre Square, London) mixed with water and "Kit-e-Kat" (Pedigree Petfoods Limited, Melton Mowbray). Litter trays were emptied at least once a day and washed with "Task" (British Hydrological Company, London), a detergent sterilizer which "kills all bacteria, including the micro-organisms which contaminate food". Fresh sawdust was placed in cat cages daily.

Faecal samples and oocysts

An excess of 2.5% potassium dichromate (w/v) was poured into plastic dishes containing fresh faecal samples. In addition to having a bacteriostatic action, the $K_2Cr_2O_7$ solution reduced faecal odour. Faeces were

broken up and sieved through muslin to get rid of large particles and the oocysts or sporocysts in the filtrate were harvested by centrifugal flotation, using a saturated sodium chloride solution. In Berlin, Dr. A.-O. Heydorn and the author compared a saturated NaCl solution for the recovery of sporocysts of Sarcocystis with the NaCl-$ZnCl_2$ solution used by the German workers (see Part II, "Historical Review"). No difference was detected.

Isospora felis oocysts were obtained from the faeces of a naturally infected kitten that did not have a concomitant I. rivolta or any other detectable coccidial infection. Oocysts were passaged in coccidia-free, conventionally reared cats four times and, finally, in a coccidia-free S.P.F. cat. Oocysts from the S.P.F. cat were used in the experiments reported in Part II of the thesis.

Gloves were always worn when the faeces of chimpanzees were being handled. Containers, Pasteur pipettes, applicator sticks, etc., that had been in contact with chimpanzee faeces were subsequently placed in a 1% solution of "Hycolin", a wide spectrum synthetic phenol disinfectant, described by the manufacturers as being 100% effective against all common pathogens and skin fungi (William Pearson Limited, Clough Road, Hull).

Detection of Sarcocystis in fresh meat

Fresh heart was scraped with a scalpel blade and the muscle fibres mixed with a drop of 0.85% saline on a microscope slide. A coverslip was pressed down to rupture cysts and the preparation was scanned under the microscope for cystozoites. Skeletal muscle was also examined in this way, as well as macroscopically (see first subsection of "Results", Part II).

Collection of sera

Mice were bled by heart puncture after being anaesthetized with ether.

Cats were bled under anaesthesia from a vein in the hind leg. Saffan anaesthetic injection, previously known as CT 1341, was used (Glaxo Laboratories Limited, Greenford, Middlesex) by the intramuscular route. The active ingredients in Saffan are two pregnanedione derivatives solubilised in saline by 20% w/v polyoxyethylated castor oil. The steroid anaesthetics are alphaxalone (3a-hydroxy-5a-pregnane-11, 20 dione) and alphadolone acetate (21-acetoxy-3a hydroxy-5a-pregnane-11, 20-dione). The latter has about half the activity of the former, and is included to improve the solubility of the alphaxalone.

Blood was allowed to clot at room temperature and carefully loosened from the sides of the tube with a sterile hypodermic syringe needle. Centrifugation was often not necessary. Serum samples were duplicated and stored at -20°C. and -60°C., respectively.

Staining of impression smears

Impression smears were air-dried, fixed in absolute methyl alcohol for 1-1½ minutes and stained with 10% Giemsa's stain, using distilled water buffered at pH 7.2. The staining time varied between 30 minutes and 1½ hours. The staining period for extraintestinal stages of Isospora felis, however, was usually 12-15 hours (sic!) in 10% Giemsa (resulting in over-staining of the nuclei of cells of the host animal). On removal from the stain, smears were rinsed momentarily in running tap water and left to dry.

Histological techniques

Small pieces of tissue, usually not larger than about 6 mm. cubes, were fixed in Carnoy's or Bouin's (aqueous) fluids or in neutral buffered formol-saline. Helly's fixative was used on a few occasions (Markus, 1973c). The tissues were taken through a graded series of distilled water/ethyl alcohol mixtures for dehydration. Cedarwood oil was normally used as the

clearing agent. Tissues were embedded in paraffin wax or paraplast. Sections were stained with Ehrlich's haematoxylin and eosin, Heidenhain's iron haematoxylin (Drury and Wallington, 1967) or Giemsa' stain (Bray and Garnham, 1962).

Heidenhain's iron haematoxylin and orange G was the preferred method for tissues known to contain parasites, having previously been used by the author in unrelated work (to show details of nuclear activity in avian gonads - Markus, 1967, 1968).

Isolation of sarcocysts from bovine cardiac muscle

Intact sarcocysts were recovered from cattle heart by a modification of the Baermann funnel method (for the isolation of nematodes) used by Mandour (1965a). A funnel was set up (Figures 1 and 2) with a stainless steel wire netting household strainer resting in it. The strainer was lined with a single layer of nylon mosquito cage gauze, i.e. netting with a mesh coarser than that of muslin, which would only have let through the smaller sarcocysts and held back many of the desired size. Infected bovine heart free of as much fat and connective tissue as possible was minced in a household mincer, mixed with 0.85% saline in a beaker and poured on top of the netting into the funnel. More saline was then poured on the meat, to fill the funnel to above the level of the minced heart. The apparatus was left for about an hour, during which period the material in the sieve was gently stirred from time to time to let sarcocysts through, which sank to the bottom. Sarcocysts and muscle which came to rest at the neck of the funnel were released by tapping it or by gently agitating the saline in that area with a Pasteur pipette, so that the particles sank down the stem of the funnel. From about 15 minutes after placing material in the apparatus, the clip on the tube underneath the funnel was released periodically and the suspension collected in small glass bottles, which were left on the

Figures 1 and 2. Isolation of intact sarcocysts from bovine cardiac muscle. (Photos: R. Killick-Kendrick)



Figure 1



Figure 2

laboratory bench. The sarcocysts and pieces of cardiac muscle sank to the bottom within a few minutes, leaving a relatively clear supernatant. When hearts of older animals were used, a single drop of concentrate from the bottom of the bottle usually contained 10-20 sarcocysts.

This method was found not be satisfactory for the separation of sarcocysts from skeletal muscle.

Indirect fluorescent antibody test for sarcosporidiosis

This test was used in an attempt to detect antibodies to Sarcocystis in animal and some human sera. The tests were performed in Dr. C. C. Draper's laboratory in the Ross Institute, London School of Hygiene and Tropical Medicine. Approximately half the tests were run by the author and the remainder by Mr. Sherali Thaver. All slides were read under the ultra-violet fluorescence microscope by Mr. Thaver.

Antisera labelled with fluorescein isothiocyanate were supplied by Wellcome Reagents Limited, Beckenham, Kent or by Nordic Immunological Laboratories Limited, Maidenhead, Berkshire. Phosphate-buffered saline (PBS) (pH 7.2), foetal calf serum and/or sera that had previously given a negative reaction were used as "negative" controls. "Positive" control sera were sera of animals known to have been infected with Sarcocystis and/or which had previously shown a "positive" reaction and/or serum from the same bull from which the antigen had been obtained.

Antigen was collected by the author by extracting macroscopic sarcocysts from the diaphragm of an infected bull. The cysts were washed in PBS, crushed and diluted by Mr. Thaver and applied by the author to individual wells of polytetra fluoroethylene-coated slides (16 wells per slide) prepared by the technique described by Thaver (1974). Antigen slides were dried and packed as described by Thaver (op. cit.) and stored at -20°C.

On the day of testing, the required number of slides were removed from the freezer and left (for 10 minutes or more) to warm to room temperature in a desiccator containing calcium chloride. Antigen slides were fixed in acetone at room temperature for 5-10 minutes.

Serum samples of 10 µl. were used in a microtitration plate, with dilutions prepared at 1:16, 1:64, 1:256, 1:1024, etc. The methodology, set out by Thaver (op. cit.), may be summarized as follows:-

1. Sera applied to antigen slides; incubated in a moist chamber for half an hour at room temperature.

2. Slides placed back to back in a Coplin jar and rinsed twice with PBS; then left in the Coplin jar filled with PBS on a shaker, to agitate for half an hour.

3. Slides rinsed once more in PBS, excess moisture shaken off and slides transferred to a humid chamber.

4. Slides flooded with diluted conjugate to which Evans blue at a dilution of 0.1% had been added, to reduce non-specific fluorescence.

5. Slides washed again as in steps 2 and 3.

6. Slides dipped in acetone for a few seconds to remove excess Evans blue, then rinsed once only in PBS to remove excess acetone.

7. Slides mounted in 90% glycerol buffered at pH 8.6; covered with two no. 1 coverslips, 22 x 50 mm. and 22 x 22 mm.

8. Slides examined under fluorescent microscope.

Additional Materials and Methods are given in the "Results" sections of Parts I and II.

PART I: SURVIVAL AND DISSEMINATION OF OOCYSTS IN THE ENVIRONMENT

HISTORICAL REVIEW

Environmental contamination by isosporan oocysts

After a woman in Britain and her two children had developed lymphadenopathic toxoplasmosis, Fleck et al. (1972) produced infections of Toxoplasma gondii in mice by inoculation of a concentrate from soil samples taken from a sand pit in the family's garden.

The occurrence of T. gondii in soil has also been reported from a suburb of San José, Costa Rica (Ruiz et al., 1973). The locality was inhabited by numerous cats and oocysts of T. gondii had been seen in the faeces of some of the kittens. Soil samples were collected from sites which varied in the extent to which they were exposed to the sun. T. gondii was isolated from four of 15 soil samples, taken from three of 12 different sites. The isolations were from soil that was moist and which tended to be shaded for most of the day by vegetation or by a corrugated iron fence.

In many countries, cats are commonly kept on farms to keep down rodents in barns (Figures 3 and 4), if not as pets, and have access to bags and bins in feed rooms. Penkert (1973) reported that he had frequently observed cat faeces in feed in hog houses and cattle barns. He thought that measures should be taken to prevent cats from defaecating directly on to the feed of farm animals.

Recently, three kangaroos in the Budapest Zoo contracted toxoplasmosis. Oocysts of T. gondii were found in both fresh and dry cat faeces in the room where food for the kangaroos had been prepared (Dobos-Kovács et al., 1974a, 1974b). Mice were successfully infected with these oocysts and it was concluded that the food of the kangaroos had been contaminated by T. gondii oocysts.

Figures 3 and 4. A barn on a farm in Sussex, England. The domestic cat, a final host of Toxoplasma, Hammondia, Sarcocystis and Besnoitia, lives in close association with farm animals in many countries. (Photos: A. N. Markus).



Figure 3



Figure 4

There have been a few reports of outbreaks of overt congenital ovine toxoplasmosis in housed sheep, where cats were kept in food stores for rodent control (Hartley and Munday, 1974; Plant et al., 1974). When a practice was made of storing grain in silos instead of bags on a property where ovine toxoplasmosis was a problem, this appeared to prevent sheep from acquiring new infections (Plant et al., op. cit.).

Invertebrates as transport hosts for coccidian oocysts

Before the life-cycle of T. gondii was determined, a number of authors had suggested that toxoplasmosis might be transmitted in nature by haematophagous arthropods. Little consideration has, however, been given to the possible role of coprophagous invertebrates in transmission. Experimental evidence has shown that coccidian oocysts of vertebrates can pass undamaged through the digestive tracts of invertebrates.

Earthworms

Lund (1970) transmitted coccidia to turkeys by feeding each of a number of poults one washed earthworm from "house-yard" enclosures in which turkeys had been kept for most of the preceding four years. The enclosures had last been occupied by adult birds about six to eight weeks before the earthworms were dug up. The frequency with which the birds fed earthworms contracted coccidial infections was a half to one third of the frequency in poults kept on soil in the enclosures where the earthworms were obtained. Lund (op. cit.) concluded that earthworms transmit coccidia and that coccidiosis may have been acquired by the birds largely through the consumption of earthworms.

Dubey et al. (1970b) studied the transportation of T. gondii oocysts in soil by earthworms Allolobophora caliginosa. They found that oocysts in faeces buried beneath a layer of soil and sand were brought to the surface by earthworms and were infectious to mice for at least 117 days.

Frenkel et al. (1975) pointed out that earthworms, which can ingest large numbers of T. gondii oocysts in soil, could constitute heavy inocula for birds.

Flies

Wenyon and O'Connor (1917) found a single oocyst of a species of Eimeria, measuring 28 x 20 µm, after examination of three of five Musca domestica droppings that had been passed by a fly during a period of two hours immediately following its capture.

Metelkin (1935) studied Eimeria exigua (= perforans) and E. irresidua of rabbits in several species of flies in the laboratory: M. domestica, Stomoxys calcitrans, Calliphora erythrocephala, Lucilia caesar, Cynomyia mortuorum and Phormia groenlandica. Oocysts were not affected by their journey through the gut of the fly. They were passed for at least 24 hours, beginning five to ten minutes after being ingested, and completed sporulation when placed in 2.5% potassium dichromate.

Using laboratory-bred M. domestica and blowflies Chrysomya megacephala, caught in traps baited with cat faeces, Wallace (1971a) showed that filth flies are capable of contaminating human food with viable T. gondii for one to two days after contact with sporulated oocysts in cat faeces. Caged flies which had been starved for 16 hours were allowed to feed on infectious cat faeces for three to five hours and were then given access, over a period of two or three days, to skim milk for three or four hours. After exposure to the flies, aliquots of milk were fed to mice by stomach tube. The resultant infections showed that flies of both species had contaminated milk for approximately 24 hours, while C. megacephala had carried oocysts of T. gondii for about 48 hours (Wallace, op. cit.).

Cockroaches

After preliminary investigations using laboratory-bred Madeira cockroaches Leucophaea maderae and American cockroaches Periplaneta americana

had shown that these insects will deposit viable T. gondii oocysts even after a few days, Wallace (1972) conducted three more carefully designed experiments over a period of several months. Cockroaches were starved and exposed in groups to oocyst-containing cat faeces. The contents of the digestive tracts of the cockroaches, or their faeces collected at various intervals, were inserted into mice by stomach tube. The results showed that cockroaches are capable of harbouring and shedding viable T. gondii oocysts for several days. T. gondii was isolated from the digestive tract of one cockroach as long as seven days after exposure to infective cat faeces; and from cockroach faeces as long as nine to ten days after the insect's last contact with cat faeces containing T. gondii oocysts.

Wallace (1973c) supplemented his earlier observations on the retention of oocysts of T. gondii by starved cockroaches. L. maderae were allowed access to oocysts in cat faeces. After contact with oocysts, cockroaches were killed at intervals and T. gondii isolated by oral inoculation, in water, of the contents of the alimentary canals into mice. T. gondii was isolated up to 20 days after having been ingested by cockroaches.

Dung Beetles

Dung beetles which had been caught in the vicinity of feeding troughs for wild boars Sus scrofa in a reserve in Czechoslovakia were examined for coccidian oocysts by Zajíček and Páv (1972). Oocysts of the swine coccidium Eimeria debliecki were located in the gut contents of 10 of 117 Geotrupes stercorarius but were not seen in at least 7 other species of dung beetle. It was found that both sporulated and unsporulated oocysts of E. debliecki could pass undamaged through the digestive tract of G. stercorarius.

Molluscs

Galuzo *et al.* (1972) established that oocysts of *T. gondii* were not damaged by passage through the alimentary canals of molluscs. Land snails *Caracolus caracolla*, which had been fed *T. gondii* oocysts, passed them in their faeces for two days, but the tissues of the snails did not become infected (Miller *et al.*, 1972).

RESULTS

Isolation of *Toxoplasma gondii* from soil

Particular attention was paid to small gardens in built-up areas known to be frequented by cats. Cat faeces were not detected in any of the soil samples studied. Attempts were made to isolate *Toxoplasma gondii* by subjecting samples of moist topsoil to centrifugal flotation, using a saturated sodium chloride solution. After flotation, the supernatant was washed in water and aliquots of a concentrate from it were either fed to mice by stomach tube or injected intraperitoneally in 0.85% saline. In view of the small size of *T. gondii* oocysts, concentrate was not normally examined microscopically for the presence of oocysts before inoculation into mice.

When concentrate was given to mice *per os*, only one of the control mice was caged together with them. The other controls were kept in an adjacent cage in the animal house. This was done because some oocysts of *T. gondii* pass through the digestive tracts of mice given oral inocula and most of those that do so are still viable (Frenkel, 1971; Dubey and Frenkel, 1973). This can result in other mice ingesting oocysts (Dubey and Frenkel, *op. cit.*). In cases where mice were sacrificed at five days post inoculation, the control mouse killed was one of those that had been caged separately. If mice were injected intraperitoneally, all controls except one were kept apart in an adjacent cage for 72 hours, during which time the sawdust in the cage housing the experimental mice plus one control was changed frequently. The object of separating most control mice temporarily was to reduce the possibility of their becoming infected following leakage at injection sites, as was sometimes found to happen when mice were injected with *T. gondii* oocysts by Dubey and Frenkel (1973). After 72

hours, all experimental mice and controls were placed in one cage.

Whenever possible, peritoneal fluid and tissue from mice that died were passaged into further mice. Mice were checked for toxoplasmosis by the screening of sera in the dye test and/or by searching their brains for cysts. Dye-testing was carried out by the Public Health Laboratory, St. George's Hospital, London S.W.17. Brain tissue was examined fresh and/or in stained sections of formol-saline or Carnoy-fixed material. T. gondii was isolated from one of twelve soil samples.

In some experiments, one of the experimental mice and a control were killed at five days post inoculation, when smears from the peritoneal cavity* and impression smears of mesenteric lymph mode were prepared. The latter were examined for stages of Isospora rivolta and I. felis (see Part II), both common coccidia of cats. I. felis was recovered from one soil sample by inoculation of mice, but may have been overlooked in earlier samples that were not studied in this way.

Soil sample 1: 1,500 g of moist soil from underneath a shrub growing next to the East wall of a flower garden in Earl's Court, London S.W.5, February 1972. Two adult cats were seen in the garden at the time that the soil sample was taken and a third was observed nearby.

Three LACA mice (approx. 20 g) each received .15 ml. of concentrate per os. Two control mice were fed .15 ml. of water each. The brains of all the mice were fixed after $7\frac{1}{2}$ weeks. Twenty sections from different regions of the brains of two of the experimental mice were examined. Five sections of the brain of the third mouse were scanned. The brains of the

---

*Although T. gondii may not occur at this time in mice given oral inocula of oocysts, smears were nevertheless prepared.

control mice were not examined. Result of experiment: negative.

Soil sample 2: 800 g of moist soil (not shaded) from a flower garden in Woodford, London E.18, May 1972. No cats were seen but it was understood that there were several strays in the immediate vicinity, at least one of which used to visit the garden sampled.

Two LACA mice (approx. 20 g) were each given .15 ml. of concentrate intraperitoneally. Two control mice were both injected with .15 ml. of sterile saline. All mice were sacrificed at 10 weeks post inoculation. No cysts were seen in 15 sections (selected at random) of the brains of either of the experimental mice. The brains of the control mice were not sectioned. Result of experiment: negative.

Soil sample 3: 1,100 g of moist soil from a flower garden in Putney, London S.W.15, August 1972. The soil was partly shaded by vegetation. This sample was taken about two yards from where a kitten approximately two months old was seen to defaecate.

Three mice of unknown strain (approx. 30 g) were each fed .2 ml. of concentrate. Two controls were both given the same amount of water. Eight weeks later all the mice were killed. Four fresh preparations of the brains of each of the inoculated mice were scanned. Pieces of brain of each experimental and control mouse were fixed but were not studied histologically. Result of experiment: negative.

Soil sample 4: 1,500 g of moist soil from a well-shaded flower garden in Hampstead, London N.W.3, December 1972. Two kittens approximately three months old belonged to the household. There were, in addition, some stray cats in the area.

Three LACA mice (approx. 25 g) were fed .2 ml. of concentrate each and the same amount of water was given to both of two controls. Four fresh brain preparations from each inoculated mouse were examined at 10 weeks. Pieces of brain of all five mice were fixed but were not sectioned. Result of experiment: negative.

Soil sample 5: 800 g of mud from the edge of a stream, Sunninghill, Berkshire, April 1973. The stream runs through large gardens in the area, at least one of which was frequented by cats.

Two T.O. mice (approx. 20 g) each received .15 ml. of concentrate intraperitoneally and three controls received the same quantity of sterile saline each. One of the inoculated mice died six days later. After a smear of peritoneal fluid had been taken, this and pieces of lung, spleen, liver, kidney and brain were ground in a tissue grinder, together with 1 ml. of sterile 0.85% saline. .2 ml. of the suspension was inoculated intraperitoneally into each of three T.O. mice (approx. 20 g), while three control mice were each injected with .2 ml. of sterile saline. A control mouse was killed, a smear prepared from its peritoneal cavity, and passage carried out in the same way. In addition to smears of peritoneal fluid, imprints of various tissues were prepared from the two mice autopsied on day six. All mice used in passage as well as the original surviving ones were sacrificed 12 weeks later. The brains of the experimental mice were thoroughly examined for cysts by means of fresh brain suspensions. In addition, a few stained smears of each were scanned. Serum from the surviving mouse that received the concentrate and pooled sera of the three that were injected with tissues and peritoneal fluid from the mouse that died, were found to be seronegative in the dye test for T. gondii. Protozoa were not seen in the peritoneal fluid or tissue smears from the last-mentioned individual. Result of experiment: negative.

Soil sample 6: 1,000 g of mud from a stream in Virginia Water, Berkshire, June 1973. No data are available concerning the presence or absence of cats in the area. Two T.O. mice (approx. 25 g) were each injected intraperitoneally with .1 ml. of concentrate, whilst two controls each received the same amount of sterile saline. One of the mice into which concentrate had been injected was found dead on day five, in an advanced state of decomposition. Material was not passaged. The other mouse died on day seven. One of the controls was killed and after smears of peritoneal fluid and tissues had been prepared from this mouse and the one that died on day seven, passage from the latter individual was carried out as in the case of the mouse that died after having been fed concentrate prepared from soil sample no. 5. Three mice were used, with two more as controls. All mice were killed at 10 weeks and material examined as before (see soil sample no. 5), except that as neither mouse had survived the initial injection, only the pooled sera of the three mice that had received tissues and peritoneal fluid were dye-tested. Result of experiment: negative.

Soil sample 7: 1,200 g of moist soil from a flower garden in Golders Green, London N.W.11, September 1973. The soil was partly shaded by flowers. There were several young cats in the area - mostly strays, according to local residents.

Three T.O. mice (approx. 30 g) were each given .2 ml. of concentrate intraperitoneally and three controls the same amount of sterile saline. Between day 15 and day 18 post inoculation, one mouse died and was found in an advanced state of decomposition. At 10 weeks post inoculation the surviving mice were bled and killed and pieces of brain were fixed.

The combined sera of the two surviving experimental mice were positive for T. gondii at a dye test titre of 1:1024. The pooled serum sample of

the three controls was negative. Several cysts morphologically indistinguishable from those of T. gondii were found in a few sections of the brains of both the mice that survived the feeding of concentrate (Figures 5 and 6). The largest cyst seen measured about 42 µm in diameter. No cysts were found in many sections of the brains of the three control mice.

Using the criteria of Frenkel and Dubey (1975a, b), the high dye-test titre for T. gondii, the large size of some of the brain cysts and, in particular, the relatively large number of brain cysts, indicated that the organism isolated was T. gondii, not Hammondia sp.

All six mice used in this experiment were from the same batch and had been kept in the same cage from the time they were purchased (when they weighed 10-15 g) until the time of the experiment. After inoculation, one control mouse was caged with the three experimental mice immediately. The other two controls remained in an adjacent cage for 72 hours, after which all six mice were housed together.

A second attempt was made to isolate T. gondii from the same place (see soil sample no. 11) but this was unsuccessful.

Soil sample 8: 1,000 g of moist soil from a vegetable garden in Kilburn, London N.W.6, March 1974. The soil was not shaded. A number of young cats were seen in the vicinity.

Three T.O. mice (approx. 30 g) were fed .2 ml. of concentrate each. Two controls received the same amount of water. One of the three mice and a control were killed at five days. Impression smears were made from the peritoneal cavities and mesenteric lymph nodes. Pieces of mesenteric lymph node and other organs were fixed. Three months after the feeding of concentrate, all mice were killed. Brain specimens were fixed and touch

Figures 5 and 6. *Toxoplasma gondii* cysts in the brains of two mice, 10 weeks after intraperitoneal injection of concentrate derived from soil sample no. 7 (x 1,600). Haematoxylin and eosin.

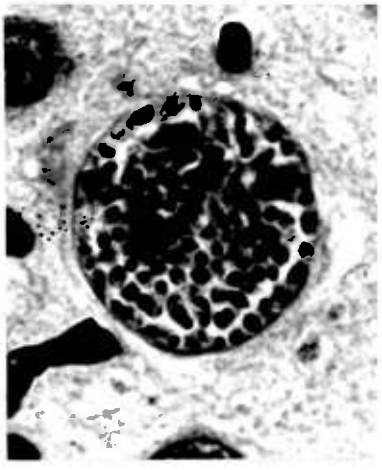

Figure 5

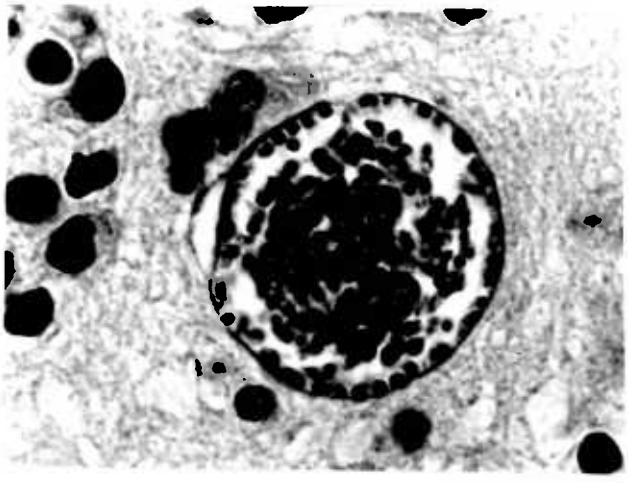

Figure 6

smears of mesenteric lymph node were made. The combined serum sample of the two remaining mice that had been fed concentrate proved to be dye test negative and their brains were not examined histologically. No Protozoa were seen in the peritoneal or mesenteric lymph node smears prepared from the mice killed on day five or in the mesenteric lymph node smears taken from the remaining experimental mice at autopsy. Result of experiment: negative.

Soil sample 9: 1,500 g of moist soil from a vegetable garden in Balham, London S.W.12, May 1974. The soil was not shaded. A domiciled cat was in the habit of defaecating in the vegetable garden.

Three T.O. mice (approx. 25 g) were each given .15 ml. of concentrate and three controls the same amount of water each. On day five, one of the three mice that received concentrate was sacrificed, together with a control. Smears of peritoneal fluid and mesenteric lymph node were prepared. The remaining mice were killed at 10 weeks. The brains were examined by means of fresh preparations. Pieces of brain were also fixed, touch smears of mesenteric lymph node were prepared, and the mice were bled. No Protozoa were seen in the smears from the mice sacrificed on day five or at the end of the experiment in the mice that had received concentrate. As no brain cysts had been seen, it was decided not to have a combined serum sample from the two experimental mice killed at 10 weeks tested. Result of experiment: negative.

Soil sample 10: 1,000 g of moist soil from a flower garden in Slough, Buckinghamshire, May 1974. The soil was not shaded. Two cats were seen in the garden, both of which appeared to be younger than six months.

Three T.O. mice (approx. 25 g) were each fed .2 ml. of concentrate. Three controls were each given the same amount of water. On day five, one

inoculated and one control mouse were killed for examination of smears of peritoneal fluid and mesenteric lymph node. Pieces of the latter were also fixed. At 11 weeks post inoculation all the remaining mice were killed. Impression smears of mesenteric lymph node were taken and pieces of brain were fixed. Three fresh brain preparations from each of the experimental mice were scanned for cysts. The smears taken from the experimental mouse on day five and the mesenteric lymph node smears from the two experimental mice killed after 11 weeks were also examined. Result of experiment: negative.

Soil sample 11: 2,500 g of moist soil (being four smaller samples combined) were collected from within an area of approximately two square metres in the same part of the flower garden in Golders Green, London N.W.11 where soil sample no. 7 was obtained (and from which T. gondii had been isolated). Sample collected in August 1974.

Microscopic examination of a sample of the concentrate revealed no coccidian oocysts. Six T.O. mice (approx. 30 g) were each injected intraperitoneally with .2 ml. of concentrate and each of six controls with the same amount of sterile saline. Four mice were killed on day five - two that had received concentrate, and two controls. Pieces of most tissues and organs were fixed after impression smears had been prepared. Post-mortems were carried out on the remaining eight mice at seven weeks post inoculation. The autopsies included examination of fresh brain preparations. The pooled sera of the four experimental mice killed after seven weeks were negative for T. gondii in the dye test. No Protozoa were seen in the peritoneal fluid or mesenteric lymph nodes of any of the mice, or in several sections of the brains of two of the four experimental mice killed at the end of the experiment (the brains of the other two mice were not examined histologically).

This attempt to isolate T. gondii from soil in which it had been found eleven months previously was, therefore, unsuccessful.

Soil sample 12: 2,500 g of moist soil from a flower garden in Islington, London N.1, August 1974. The soil was shaded to some extent by flowers. The garden in which the soil sample was collected was frequented by at least five kittens about three or four months old.

Three T.O. mice (approx. 30 g) were each fed .2 ml. of concentrate. The same number of control mice were each given .2 ml. of water. Five days later, one mouse from each group was killed for the preparation of smears of peritoneal fluid and mesenteric lymph node. Post-mortems were carried out on the remaining mice at seven weeks post inoculation. The pooled sera of the two experimental mice kept for seven weeks did not show antibodies to T. gondii in the dye test. Cysts were not seen in their brains, which were examined as fresh suspensions. No Protozoa were detected in the peritoneal fluid of these or of the other experimental mouse sacrificed at five days.

Isospora felis was found in all three experimental mice but not in the control mice (see following section).

Isolation of Isospora felis from soil

Attempts were made to find out whether viable oocysts of Isospora felis or I. rivolta had been present in five of the twelve soil samples discussed in the previous section by searching impression smears of mesenteric lymph node for stages of these isosporan parasites which occur there (see Part II). Isospora was isolated from one of the soil samples for which this was done, viz. soil sample no. 12 in the previous section, collected from a small flower garden on a small property inhabited by several young cats.

Three T.O. mice (approx. 30 g) were each given .2 ml. of concentrate per os, while three controls each received the same amount of water. Five isosporan organisms were found in a mesenteric lymph node smear of an experimental mouse killed on day five (Figures 7 and 8) and four and seven organisms, respectively, were seen in smears of the mesenteric lymph nodes of the other two experimental mice (Figures 9 and 10) which were sacrificed at seven weeks post inoculation. Five of the better specimens in the three smears measured: 21.0 x 9.6, 21.0 x 7.8, 18.0 x 11.4, 18.0 x 7.8 and 16.2 x 10.8 µm. These measurements are similar to those for I. felis (see Part II); and from which the parasites could not be distinguished morphologically. Organisms were not seen in the smear from the peritoneal cavity of the mouse killed on day five nor in peritoneal fluid brain, kidney, lung, liver or spleen imprints from the other two mice (one smear from each organ of each mouse was scanned). No organisms were found in a smear of the mesenteric lymph node of the control mouse sacrificed on day five nor, after an exhaustive search, in a number of smears of the mesenteric lymph nodes of the other control mice.

The six mice used in this experiment were from the same batch and had been purchased when about 10-15 g in weight. Since purchase they had been

Figures 7 and 8. Isosporan stages in impression smear of the mesenteric lymph node of a mouse, five days after having been fed concentrate derived from soil sample no. 12 (x 1,600). Giemsa's stain.



Figure 7



Figure 8

Figures 9 and 10. Isosporan parasites in impression smears of the mesenteric lymph nodes of two mice, seven weeks after they had been fed concentrate derived from soil sample no. 12 (x 1,600). Giemsa's stain.

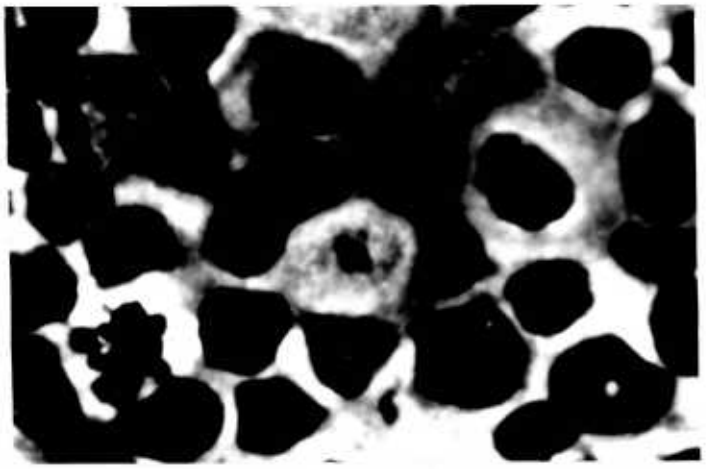

Figure 9



Figure 10

kept in the same cage until when the experiment took place. Following inoculation, one control was kept with the experimental mice and the other two in a separate cage.

Brain, kidney, lung, liver, spleen and mesenteric lymph node of both the experimental mice kept for seven weeks following inoculation were fed (in "Kit-E-Kat") to one of two specific pathogen - free cats, both housed in the same room. The other cat served as a control and ate tissues of the control mice. Apart from having had experimental Sarcocystis infections, these cats had remained coccidia-free (faecal examinations were carried out at least once a week) since they were purchased in mid-August 1973 as kittens two and three months old, respectively. The faeces of both cats were carefully screened each day for one week immediately prior to the feeding of tissues of the mice. No sporocysts of Sarcocystis or other coccidia were seen. On day 6 the cat that had ingested tissues of the experimental mice started to shed oocysts of Isospora felis (Figures 11 to 14). Twenty-five oocysts measured 33.0 - 45.6 x 27.6 - 36.0, with a mean of 38.6 x 30.6 µm. The dimensions of 25 sporocysts were 18.0 - 24.0 x 16.8 - 21.6, with a mean of 21.4 x 18.7 µm.

It is concluded that the parasites seen in the mesenteric lymph nodes of the mice were I. felis.

The faeces of the control cat were searched daily for oocysts for 3½ weeks. During this period the cat did not pass I. felis oocysts. Contamination from the infected cat was prevented by removal of infected faeces before sporulation of oocysts could take place. The control cat did, however, become infected with I. felis when subsequently given oocysts in connection with an unrelated experiment.

Figures 11 to 14. Isospora felis, isolated by oral inoculation of mice with concentrate derived from soil sample no. 12, followed by feeding of mouse tissues to a specific pathogen-free cat (x 1,600). Fresh preparations. 11. Freshly passed oocyst with zygote. 12. Oocyst with zygote beginning cleavage. 13. Oocyst with sporocysts. 14. Sporulated oocyst.

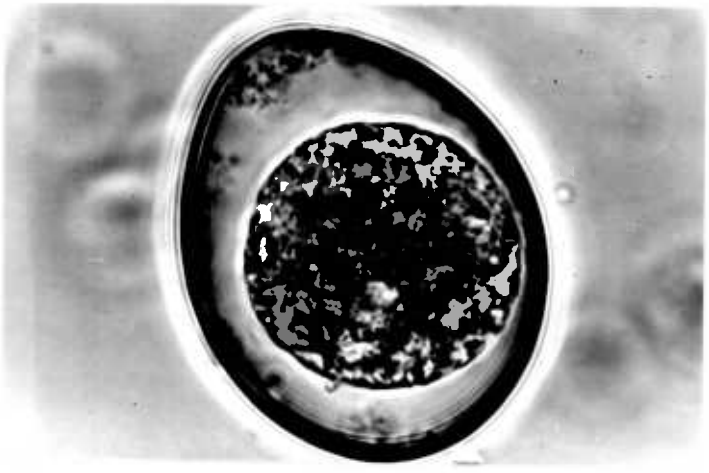

Figure 11

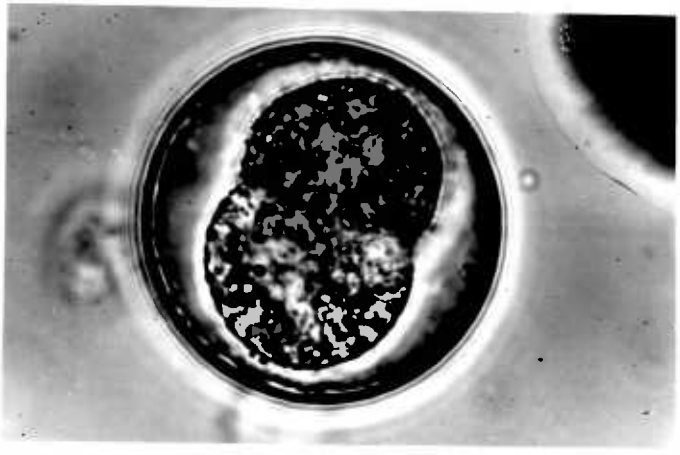

Figure 12

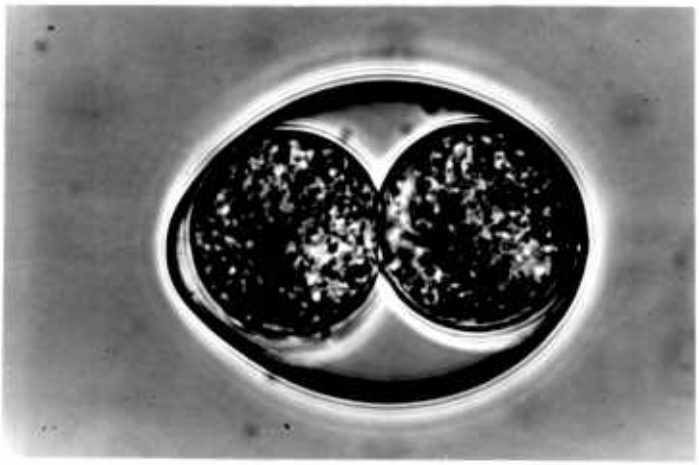

Figure 13

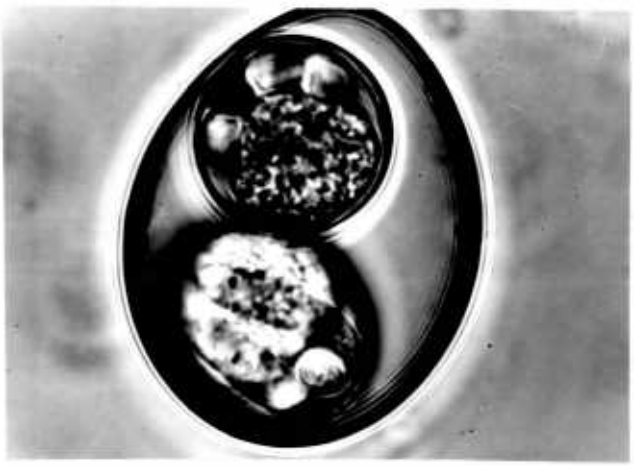

Figure 14

A second visit was paid, in October 1974, to the garden where the soil had been collected. The flower bed had in the meantime been cultivated. Microscopic examination of the concentrate derived from 2,000 g of moist soil did not reveal any I. felis oocysts. Mouse inoculation was not performed a second time.

Survival of *Isospora felis* in soil in the laboratory

Preliminary observations were made on the survival of *I. felis* in soil. Three million freshly sporulated *I. felis* oocysts were mixed with a 3 cm. layer of garden topsoil in a plastic dish 10 cm. in diameter at the top and tapering to 9 cm. at the base. The dish was covered and stored in darkness in the laboratory, where the temperature varied between 18°C. and 24°C. during the experimental period. The soil was kept moist by the addition of tap water from time to time. Soil was subjected to centrifugal flotation at intervals (Table 1), approximately one sixth of the contents of the container being removed on each occasion. Oocysts recovered were fed in .1, .15 or .2 ml. of tap water to T.O. mice by stomach tube. Control mice which received tap water were caged separately but alongside the mice given the concentrate. Mice were killed at 12 days post inoculation. Giemsa-stained impression smears from their mesenteric lymph nodes were examined for stages of *I. felis*. As this work was conducted towards the end of the period during which laboratory investigations concerning isosporan coccidia were carried out, observations on the infectivity of *I. felis* in soil were terminated after three months.

The results, presented in Table 1, show that *I. felis* oocysts can remain viable in soil in the laboratory for at least three months.

TABLE 1

Occurrence of viable oocysts in

Isospora felis - contaminated soil

kept in the laboratory

Weeks elapsed since oocysts were mixed with soil	Presence of organisms in mesenteric lymph nodes of mice fed oocysts	Control mice given water
0	2/2*	0/2
3	2/2	0/2
6	2/2	0/2
9	2/2	0/2
12	2/2	0/2

*Number of mice in which infection detected/number fed oocysts.

Infectivity of oocysts from the gut of earthworms and worm casts

During the course of enquiries as to the food eaten by stray and domiciled cats in the area of north London where T. gondii was isolated from soil, it became apparent that cats in this urban area regularly catch and consume wild birds. Birds were observed feeding on earthworms in gardens following rainy periods when the soil was moist and worms came to the surface.

As antibody detectable by the dye test frequently does not develop in birds infected with T. gondii oocysts (Miller et al., 1972; Wallace, 1973c), it was decided to investigate the infectivity of coccidian oocysts in earthworms and worm casts in regard to birds by using Eimeria tenella. It was thought that although the survival of T. gondii oocysts in earthworms would not necessarily be analogous to that of E. tenella, the experiment with E. tenella would nevertheless provide at least some indication of the possible survival of T. gondii oocysts.

455,000 freshly sporulated oocysts of the Weybridge strain of E. tenella were mixed with a 1 cm. layer of soil moistened with tap water, in the bottom of each of a number of sealed plastic containers 9 cm. in diameter. One specimen of Lumbricus terrestris, weighing approximately 1.5 g, was introduced into each container. The containers were kept in darkness at room temperature for one week, after which the worms were carefully rinsed with water and placed in new dishes containing a 3 cm. layer of humid soil, into which they burrowed. Worms were washed again at intervals, dissected and the gut contents of each administered per os in water with a pipette to a 3 - day-old Apollo cockerel. Earthworm casts were also fed to chicks.

The results are summarized in Table 2, the figures being based on two replicates of the experiment. There was no indication that the passage of coccidian oocysts through earthworms affected their viability. Chicks that did not die showed blood in their faeces at about 96 hours and examination of stained smears from the caeca showed haemorrhage resulting from schizogony. Direct microscopic examination of faecal material after seven days usually revealed the presence of oocysts in chicks that had been fed the gut contents of earthworms eight or twelve hours after their last contact with contaminated soil. The faeces of some chicks, however, were examined by centrifugal flotation as "later" infections tended to be light. This can be ascribed to the fact that material in burrowing L. terrestris takes about 12 hours to pass through the alimentary canal. When the worms are not ingesting soil through burrowing, the earth does not move through the gut as quickly and its journey probably takes about 20 hours (Parle, 1963). Microscopically the oocysts in earthworm casts did not differ from fresh oocysts.

TABLE 2

Isolation of viable Eimeria tenella

in earthworms and worm casts

Hours after contact with soil containing oocysts	Worm	Positive soil control	Negative soil control
0	6/6*	6/6	0/6
4	6/6	6/6	0/6
8	5/6	6/6	0/6
12	5/6	6/6	0/6
Earthworm casts	6/6	6/6	0/6

*Number of chicks in which infection detected/number fed material.

Survival of sporocysts of *Sarcocystis* in flies in the laboratory

Sixty-five laboratory-bred blowflies *Calliphora erythrocephala* were starved for 15 hours and then allowed to feed for six hours on fresh faeces from an experimental cat with an intestinal infection of *Sarcocystis fusiformis*. The faeces were slightly moistened with milk. Twenty hours after their last contact with cat faeces, the flies were killed with chloroform and 50 of them were washed with distilled water and partially dissected. The contents of the hindgut region of each fly were mixed with two drops of water. In each case a drop of the suspension was examined microscopically. Sporocysts were found in two flies. When an amount of fresh faeces equivalent to that in the flies was screened, the impression was gained that there was no difference between the concentration of sporocysts in the posterior portions of the digestive tracts of the 50 flies (collectively) and that in the faeces of the cat.

This experiment showed that sporocysts of *S. fusiformis* can be carried internally in flies and still remain intact. It is not known whether such sporocysts are viable.

Occurrence of oocysts in wild-caught flies

The posterior portions of the digestive tracts of a number of filth flies trapped on dog faeces were examined individually or collectively (in groups of five of the same species) for coccidian oocysts. In addition, the containers in which flies were kept for marking and releasing were, on 17 occasions, washed out with distilled water. This was then subjected to centrifugal flotation so that it could be checked for the presence of oocysts. In the field, small amounts of distilled water were placed in containers to be kept for possible examination, to prevent the contents from drying out.

In most cases faeces on which flies were feeding when caught was not examined: an absence of oocysts in the faeces would not have indicated whether or not the flies were carrying oocysts ingested with some other dog faeces, possibly two days previously. However, when puppies were seen to defaecate and flies visiting the excreta were subsequently captured, a faecal sample was carefully screened, as it was thought that there would be more likelihood of the faeces of puppies containing oocysts than those of older animals. Faeces were examined on 14 such occasions. Ova of Toxocara canis were seen the faeces of nine of the puppies and coccidian oocysts in three - sporocysts of Sarcocystis and oocysts of Isospora bigemina in one sample and oocysts of I. rivolta in two others.

Flies were caught on dog faeces during the summer months on pavements, public footpaths and parks in London, Berkshire, Buckinghamshire and Surrey. Flies to be dissected were killed in the field with chloroform. Each fly was washed with distilled water in the laboratory and material was removed from the posterior portion of the digestive tract and mixed with two drops of water on a slide. Proportionally greater volumes of water were used

when groups of five flies were examined together. One drop of the suspension was searched microscopically for oocysts. It was not always possible to examine all the flies the same day or evening that they were collected, in which case they were kept overnight at 4°C in a sealed container.

The flies dissected are listed in Table 3. No coccidian oocysts were seen but most of the dog faeces on which the flies had fed were probably coccidia-free, in addition to which the number of flies studied was very small, when the size of the fly populations in nature is taken into consideration.

On one occasion coccidia were found in a container which had been used to house flies trapped for marking and releasing. A puppy was seen to deposit a small amount of faeces. Flies which visited this were caught and later the puppy faeces were collected for examination. After a few sporulated sporocysts (morphologically indistinguishable from experimentally-produced sporocysts of Sarcocystis) and unsporulated coccidian oocysts (identified as Isospora bigemina) had been recovered from the faeces by centrifugal flotation, a container in which the flies had been kept was washed out with distilled water. The following were located in the supernatant after flotation: two free isosporan sporocysts measuring 15.0 x 8.7 and 15.2 x 10.0 µm; and three unsporulated oocysts measuring 11.2 x 10.0, 11.5 x 10.0 and 11.7 x 10.5 µm. Cleavage of the zygotes did not take place before the preparations dried out. The sporocysts are considered to have been Sarcocystis (see Heydorn and Rommel, 1972a; Rommel et al., 1974; Fayer, 1974a) and the oocysts those of the "small race" of I. bigemina (see Heydorn, 1973).

TABLE 3

Flies trapped on dog faeces and examined for coccidian oocysts in the hindgut*

Fly		Number dissected
Anthomyiidae:	Hylemya strenna	122
Muscidae:	Dasyphora cyanella	38
	Mydaea urbana	25
	Myospila meditabunda	48
	Orthellia caesarion	28
	Phaonia signata	3
Calliphoridae:	Calliphora erythrocephala	3
	Lucilia sericata	32
	Lucilia spp.	20
	Pollenia intermedia	3
	Pollenia rudis	7
	Sarcophaga carnaria	3
Scatophagidae:	Scatophaga stercoraria	27**
	TOTAL	359

*Oocysts were not found in any of the flies.

**It is thought that dog faeces were not present in these flies.

About half an hour after the flies (Table 4) had been trapped, they were transferred to a clean container, where they remained for approximately another half hour before they were marked and released. This second retaining container is the one which was checked; and it is possible that the coccidia could have passed through the alimentary tracts of the flies. However, it is not known whether the flies were carrying the coccidia internally or externally or both.

TABLE 4

Filth flies in a group found to be carrying coccidia from faeces of an infected puppy*

Fly	Number
Hylemya strenna	4
Dasyphora cyanella	5 (approx.)
Myospila meditabunda	3
Lucilia sericata	3
Scatophaga stercoraria	4
Unidentified small flies	10 (approx.)
TOTAL	29 (approx.)

*Coccidia were recovered by washing out a container, in which the flies had been kept, with distilled water, which was then subjected to centrifugal flotation.

Movements of flies in relation to the transport of oocysts

Of particular interest was the possibility that flies might ingest oocysts of Toxoplasma gondii and Sarcocystis while feeding on faeces of carnivores and facilitate dispersal of the coccidia in the environment of non-carnivorous hosts. The potential role of flies as transport hosts of T. gondii has been investigated in the laboratory by Wallace (1971a) but no work has hitherto been carried out in the field. During the course of the present studies concerning isosporan coccidia of mammals, preliminary observations were made on the movement of flies from cat faeces to human food and from dog and human faeces in the vicinity of cattle.

Flies were marked by gently shaking them up in coloured, powdered blackboard chalk. Although flies would subsequently clean off a lot of the chalk, some usually remained dorsally on the thorax for at least a day. Observations on fly movement were never continued beyond nine hours after marking, so that the use of chalk was satisfactory. It is thought that there may have been some mortality amongst the flies. However, it did not matter if some flies died after being released: the purpose of the study was to ascertain whether or not certain movements took place and not to determine relative numbers of marked flies recovered.

Movement to human food from cat faeces

Totals of 40 Musca domestica and 19 Calliphora sp. were trapped at the Imperial College Field Station, Ascot, Berkshire on the contents of emptied indoor cat litter trays from cages housing experimental cats. The flies were marked and released. On two of 18 occasions on which this was done, a single marked M. domestica was seen on food in an upstairs kitchen approximately 30 metres from the point of release. The times which had elapsed since marking were approximately $2\frac{1}{2}$ and $4\frac{1}{2}$ hours respectively.

Movement to cattle from dog/human faeces

To see whether movement from faeces of carnivores to grazing or resting cattle would occur, flies were caught for marking on fresh dog (and occasionally human) faeces on public footpaths or in fields adjoining pastures supporting cattle in Berkshire, Buckinghamshire, Surrey and Sussex. Artificially placed faeces were usually put in the fields in which the cattle were living. Similarly, flies were trapped both on cattle dung and cattle to obtain some idea of the movements of flies between the dung and the animals themselves. The dog excrement on which flies were trapped had almost always been deposited "naturally"* but this was not the case with the human faeces, which were transported to the fly capture sites. The fly fauna studied by marking and releasing is shown in Table 5.

Usually only one individual of a marked group of flies was ever observed in the vicinity of nearby cattle, although two and three but never more were sometimes located. Numbers of flies marked on any one occasion varied considerably, depending on how many were caught.

The species of flies which visited dog and human faeces were found to be similar. Human faeces were, however, used only a few times. Fly movement relevant to possible transportation of sporocysts of Sarcocystis was of two types: 1) from dog faeces to bovine dung (Table 6) and 2) between dung of cattle and the animals themselves (Table 7). Additional comments of a general nature are made in the discussion.

Direct movement of flies between dog faeces and cattle was observed only once: a marked Calliphora erythrocephala was seen to alight briefly on

---

*On a number of occasions, however, it was necessary to move the dog faeces closer to the cattle.

TABLE 5

Fly species marked and released after capture on cattle or on dog, human or bovine dung

Fly	Approximate number marked
Anthomyiidae:	
Hylemya strenna	375
Muscidae:	
Dasyphora cyanella	400
Graphomya maculata	30
Hydrotaea irritans	900
Mesembrina meridiana	34
Morellia simplex & *Morellia* sp.	2,800
Musca autumnalis	950
Mydaea urbana	85
Myospila meditabunda	300
Orthellia caesarion	160
Polietes albolineatus & *Polietes* sp.	2,300
Stomoxys calcitrans	1,500
Calliphoridae:	
Calliphora erythrocephala	35
Lucilia sericata & *Lucilia* spp.	475
Scatophagidae:	
Scatophaga stercoraria	225
Miscellaneous:	
Small flies, including *Azelia* spp., *Hebecnema umbratica*, *Hydrotaea albipuncta* and *Hylemya partita*	4,000

TABLE 6

Flies which moved from dog faeces to cattle dung*

Fly	Movement recorded (number of occasions)	Approximate distance in metres	Minimum time elapsed since marking (in hours)
Hylemya strenna	7/85	25; 30; 30**; 35; 38; 40; 55	2; 1**; 1½; 3; 3¼; 2; 4
Dasyphora cyanella	1/30	38	2
Mydaea urbana	1/34	30	2¾
Myospila meditabunda	2/62	38; 160	1; 2½
Orthellia caesarion	1/16	65	2
Lucilia sericata	1/18	210	¾
Scatophaga stercoraria	9/73	20; 30; 30; 30**; 38; 40; 45; 80; 125	1¾; 3; 2½; 3**; 2½; 2¼; 4; 2¼; 3

*Whilst all these flies were common to dog and bovine faeces, none were ever seen on cattle.

**Movement from human faeces (used instead of dog faeces).

TABLE 7

Flies which moved from bovine dung to cattle*

Fly	Number of occasions
Hydrotaea irritans	3/8
Morellia simplex/*Morellia* sp.	12/32
Musca autumnalis	6/20
Polietes albolineatus/*Polietes* sp.	8/24
Stomoxys calcitrans	2/2
Unidentified small flies	3/65

*Flies were always marked on fresh dung near cattle (usually in the immediate vicinity). Flies marked on cattle were seen more frequently on bovine dung than *vice versa* but as this information is not relevant to the question of possible transportation of *Sarcocystis*, the results are not given here.

the leg of a cow, in which two other, unmarked individuals were also showing an interest. There were no C. erythrocephala on several other cows in the field but a second marked individual was found sitting on grass. The marked fly that visited the cow had been trapped and released approximately 30 metres away about 1½ hours previously. This species of fly was not attracted to cattle on other occasions during the study. From the appearance of the coat of the cow, it seemed that the animal had been lying either in mud or some dog faeces. On the other hand, if the cow had come into contact with a pile of garbage that was in the field, this may have been what had attracted the flies.

DISCUSSION

Significance for man of the occurrence of oocysts of Toxoplasma gondii in the environment

Oocysts of Toxoplasma gondii were isolated from soil during the present investigation. It will be seen elsewhere in this discussion how opportunities arise for vertebrates other than man to ingest oocysts of T. gondii. Because of the importance of human toxoplasmosis, the significance in practical terms of the shedding by cats of T. gondii into the environment (vide antea) will be discussed in this subsection from the point of view of human infection. The often serious consequences of congenital toxoplasmosis and, usually, milder effects of post-natally acquired toxoplasmosis (Markus, 1973a) have been known for some time. In recent years, however, T. gondii has been proving to be an opportunistic and lethal pathogen in cancer and organ transplant patients (Cohen, 1970; Stinson et al., 1971; Gleason and Hamlin, 1974; Frenkel et al., 1975; Townsend et al., 1975; Viens and Morisset, 1975; Whiteside and Begent, 1975), with encephalitis as the most typical symptom. Involvement of the brain leading to clinical symptoms probably occurs in acquired toxoplasmosis even in "normal" adult persons more often than is realized (Bamford, 1975; Hussey, 1975; Greenlee et al., 1975).

Since the oocyst stage of T. gondii was discovered in cats, the faeces of various vertebrates have been examined, following experimental infection with T. gondii. However, oocysts have not been seen in animals other than domestic cats and certain wild felids (Dubey et al., 1970a; Bicknell, 1972; Galuzo et al., 1972; Janitschke and Werner, 1972; Jewell et al., 1972; Kühn et al., 1972; Miller et al., 1972; Zaman, 1972; Draper et al., 1971; Beverley et al., 1975). Some indirect evidence (obtained by inoculation of

mice) of the occurrence of T. gondii in the faeces of a woman (Abbas and Barrada, 1971) and in two dogs (de Roever-Bonnet, 1974) is dubious and requires confirmation. Oocysts of T. gondii have been detected in the faeces of naturally infected stray and domiciled cats in various parts of the world (Jacobs, 1967; Piekarski and Witte, 1971; Wallace, 1971b; Janitschke and Kühn, 1972; Werner and Walton, 1972; Anwar and Ghorbani-Samim, 1973, unpublished - see Siim, 1974; Kühn et al., 1973; Nery-Guimarães and Lage, 1973; Pampiglione et al., 1973; Ruiz et al., 1973; Wallace, 1973b; Čatár, 1974a; Boch et al., 1974; de Roever-Bonnet, 1974; Ito et al., 1974; Sasaki et al., 1974). It seems that felines must play a major role in the epidemiology of toxoplasmosis as the presence of domestic cats or wild felids in an area appears to be necessary for T. gondii to exist there (Wallace, 1969; Jewell et al., 1972; Munday, 1972a; Peterson et al., 1972; Wallace et al., 1972; Wallace, 1973b; Peterson et al., 1974; Wallace et al., 1974). However, the role of felids in the transmission and life-cycle of T. gondii has not yet been clearly defined.

The association of T. gondii with cat faeces led to several enquiries being conducted into the consequences of contact with cats. Whilst some of these authors found a greater number of positive sera amongst persons who had direct contact with pedigree or other cats than amongst those who did not (Price, 1969; Peterson et al., 1972; Mason et al., 1974; *Ulmanen and Leinikki, 1974), most investigators failed to find any correlation between the prevalence of antibody to T. gondii (or the occurrence of seroconversion) and having a pet cat in the family (Berger and Piekarski, 1973; Braveny et

---

* Ulmanen and Leinikki's results for owners of pedigree cats and owners of non-pedigree cats, differed.

al., 1973; Comstock and Ganley, 1973; Fisher and Reid, 1973; Stagno and Thiermann, 1973; *Ulmanen and Leinikki, 1974). Similarly, no significant differences were detected in this respect between veterinarians, their assistants and veterinary students on the one hand and persons not closely associated with the veterinary profession on the other (Behymer et al., 1973; Riemann et al., 1974; Swanepoel et al., 1974). This is hardly surprising, since the time when oocysts are most likely to adhere to the fur of a cat is when it defaecates; and unlike oocysts of species of Sarcocystis, those of T. gondii are not immediately infective on being shed. A person who frequently has direct contact with cats is perhaps just as likely to pick up infective oocysts on his/her hands by working in the garden as through stroking a cat that is shedding T. gondii oocysts. For a cat to have infective oocysts adhering to its fur, the faeces from which they came would have to be a day or more old. One would, furthermore, expect that in communities with high standards of hygiene, young children are liable to ingest oocysts more frequently than are most adults.

Oocysts of T. gondii will sporulate in moist soil within 1 - 5 days, though sporulation can take longer if the weather is cold (Dubey et al., 1970a). The results of a study by Yilmaz and Hopkins (1972), in which oocysts were kept under various conditions, both out of doors and in the laboratory, suggest that since cats bury their faeces, oocysts may remain infective in soil for about a year in warm climates and for longer periods in cool climates. Wallace's unpublished observations (see Wallace et al., 1974) also suggest that oocysts of T. gondii will survive in the environment for "months" or "years". Frenkel and Dubey (1973) investigated the results of freezing on the viability of T. gondii oocysts. The indications are that the viability of sporulated oocysts in soil will not be affected to any extent by temperatures below freezing during winter; and sporulated

---

* See footnote on previous page.

T. gondii oocysts survive even at -20°C. for 28 days. Constant or intermittent freezing of sporulated oocysts of T. gondii to -6°C. does not affect their viability to any extent, but the deleterious effect is greater after freezing to -21°C. Unsporulated oocysts are killed at both -6°C. and -21°C. by constant freezing for between 1 and 7 days. Both unsporulated and sporulated oocysts survive fluctuating temperatures better than constant freezing (Frenkel and Dubey, op. cit.). In subsequent experiments, T. gondii oocysts in soil under natural conditions were found to be viable after 12 - 18 months (Frenkel et al., 1975). The natural occurrence of oocysts in soil in Britain and South America is documented above. The fact that T. gondii could be isolated from soil in Britain is perhaps more readily understood when it is considered that ova of Toxocara canis of dogs and Toxocara cati of cats were present in approximately 25% of 800 soil samples collected from public places all over the country (Borg and Woodruff, 1973).

In contrast to owners of non-pedigree cats, it was found that sera of owners of pedigree cats were more often positive for T. gondii antibodies than sera of other persons tested (Mason et al., 1974; Ulmanen and Leinikki, 1974). It is not yet clear why this should be so. Unfortunately these authors gave no details concerning the degree of contact owners had with their pedigree cats. Relevant factors would be, for example, whether pedigree cats are used to a greater extent for breeding purposes than ordinary cats; and how often they are provided with litter trays which owners have to clean, as T. gondii oocysts are more likely to be shed by cats in their first year. The handling of raw meat by owners of pedigree cats and owners of non-pedigree cats also needs to be studied and compared.

Lest cats should come to be regarded as undesirable pets, it is important to note that most human toxoplasmosis is subclinical and that

cats with acquired antibody to T. gondii show a high degree of immunity under experimental conditions, at least to the homologous strain of T. gondii. They will shed T. gondii oocysts infrequently (at most) during their lifetime (Sheffield and Melton, 1974; Dubey and Frenkel, 1974). This will happen for a period of 1-3 weeks at a time. Sheffield and Melton (op. cit.) suggest that cats frequently develop toxoplasmosis without shedding oocysts and that circulating antibody does not provide immunity to any extent to oocyst-producing reinfection. However, once a cat has produced oocysts, resistance to reinfection at the intestinal level is stimulated. Oocysts will not be formed again in the cat for some time; and an animal might even retain "intestinal" immunity for life.

At an international medical conference it was resolved that pregnant women should be tested* and retested for toxoplasmosis (see Scott and Swinburne, 1973). The practicality of this recommendation was questioned by Fleck (1974a). Others also consider it debatable as to whether serological testing is necessary or desirable as a routine, unless a woman should develop fever, rash or lymphadenopathy during her pregnancy (Frenkel and Dubey, 1972b; Krogstad et al., 1972; Desmonts and Couvreur, 1974). In any case, for demonstration of a rising titre, which is diagnostic, an earlier serum sample would have to be available. Perhaps sera could be frozen when blood samples are taken in early pregnancy for other purposes. In cases where seroconversion or a rising titre is observed in tests for toxoplasmosis, maternal therapy could be considered (Jones, 1974) and treatment of the infant instituted in cases where congenital toxoplasmosis is suspected or proved (Desmonts and Couvreur, 1974; Hogan, 1975). In

---

* The interpretation of serological tests for toxoplasmosis is discussed by Karim and Ludlam (1975a, b) and Ludlam and Karim (1975).

Britain, the incidence (as opposed to the prevalence) of human infection with T. gondii is low and it is not yet clear how man acquires toxoplasmosis in the U.K., where raw meat is not often eaten (Fleck, 1974b). There is some inconclusive evidence that three human infections in Britain were the result of contact with oocysts in soil (Fleck et al., 1972; Feldman, 1974). As toxoplasmosis is primarily a danger to the foetus, women should take care to avoid obvious potential sources of infection while they are pregnant, particularly if it is known that they do not have serum antibodies to T. gondii. In addition to not consuming raw or lightly cooked meat, pregnant women should always wash vegetables, fruit and their hands before eating, as they could easily become contaminated by oocysts from soil. If precautions such as these are taken, it is doubtful whether antenatal care need include serological testing and retesting of expectant mothers, as has been carried out on a large scale in France (Marc et al., 1974; Moulinier et al., 1974).

In conclusion, it may be said that the domestic cat does not in fact seem to be, per se, a great hazard to man. On the other hand, oocysts in soil are an obvious source of human T. gondii infection. The oocysts are highly infectious and cause seroconversion in persons swallowing small numbers of them (Miller et al., 1972). However, experimental infection of other mammals such as chimpanzees, mice and swine (Draper et al., 1971; Wallace, 1973c; Durfee et al., 1974; Sasaki et al., 1974) suggests that ingestion of large numbers of oocysts by man may normally be necessary to produce acute clinical toxoplasmosis. Nevertheless, measures to control oocyst transmission of toxoplasmosis should be considered where practicable (Joyner, 1975).

Earthworms and *Toxoplasma gondii* oocysts

Enquiries in the part of London where *T. gondii* was isolated from soil and where birds were seen feeding on earthworms after it had been raining, revealed that cats in that area catch and eat wild birds. During the present investigation it was shown experimentally that coccidian oocysts in, or that had passed through the gut of earthworms, were infective for birds (Markus, 1974a). Frenkel *et al* (1975) found that earthworms become heavily contaminated with *T. gondii* oocysts. Thus earthworms would constitute heavy inocula for birds.

The natural life-cycle of *T. gondii* in stray domestic cats is dependent on small avian and mammalian intermediate hosts that form their prey: it has been shown that the oocyst stage of *T. gondii* is not "efficient" in producing the complete oocyst-to-oocyst cycle in domestic or wild felines (Dubey *et al.*, 1970a; Wallace, 1973b). Furthermore, only the extra-intestinal or tissue phase of the developmental cycle takes place in non-feline hosts when tissue cysts in uncooked meat or infective oocysts are ingested (Dubey, 1973; Frenkel, 1973a; Wallace, 1973c). Most small mammals and birds easily become infected with the oocyst stage of *T. gondii* and survivors function as long-term carriers of the parasite (Miller *et al.*, 1972; Dubey and Frenkel, 1973; Wallace, 1973c). Natural *T. gondii* infections in wild birds in Europe appear to be common (e.g. Poelma and Zwart, 1972; Čatár, 1973, 1974a, b).

Markus (1974a) suggested that in areas of human habitation with large cat populations and small vegetable and flower gardens, a cat - earthworm - bird - cat cycle would contribute to contamination of soil with *T. gondii* oocysts. These are transmissible to man (Fleck *et al.*, 1972; Miller *et al.*, 1972) and small animals (Miller *et al.*, 1972; Dubey and Frenkel, 1973;

Wallace, 1973c) via the mouth and possibly even by inhalation (Beverley, 1973). Mammals could accidentally ingest oocysts (e.g. during grooming) that have been moved to the surface by earthworms. Some mammals actually consume earthworms, e.g. foxes (Jefferies, 1974). The omnivorous Rattus rattus and other small mammals are well-known reservoirs of T. gondii (e.g. Rifaat et al., 1973; Čatár, 1974a; Doby et al., 1974) and will become infected after ingesting small numbers of oocysts (Wallace, 1973c).

It has been found that many T. gondii oocysts pass through the alimentary tracts of experimentally infected mice and sheep without excysting and are still viable after being shed in the faeces (Dubey and Frenkel, 1973; Beverley et al., 1975). If something similar happens when birds ingest unusually large amounts of T. gondii - contaminated soil through eating earthworms, birds would play a role in the dispersal of T. gondii oocysts (Markus, 1974b), a situation reminiscent of that of birds as disseminators of helminth ova (Silverman and Griffiths, 1955).

The role of filth flies in the transmission of bovine sarcosporidiosis and other coccidial infections

Filth flies are known to carry a variety of pathogenic organisms that do not undergo any development in the flies, including protozoan cysts and helminth eggs. Although such organisms may be carried externally on the flies for limited periods (Heinz and Brauns, 1955), contamination of, for example, human food can also take place when a fly deposits a pathogen by regurgitation or in its excreta. The part played by insects such as flies in the transmission of human pathogens varies according to local conditions of hygiene. This is not, however, true to nearly the same extent of infections that are transmitted to animals through the agency of flies.

Round (1961) is of the opinion that filth flies may play an important role in the epizootiology of bovine cysticercosis in Kenya, by making Taenia saginata eggs in human faeces available to cattle. In rural areas in Kenya, sanitation is "primitive or almost non-existent" and even on farms, where latrines are available, human faeces are deposited indiscriminately (Round, op. cit.). This situation is the norm in Africa as a whole (as in many other parts of the world) and where both bovine sarcosporidiosis and Isospora hominis are common (Elsdon-Dew and Freedman, 1953; Young and van den Heever, 1969; Thornton, 1972), transmission of sarcosporidiosis of cattle would presumably also be facilitated by flies in exactly the same way as cysticercosis can be.

The recent discovery that Sarcocystis fusiformis* has an oocyst which

---

* Although Sarcocystis fusiformis Railliet, 1897 is not necessarily the correct or only name for sarcosporidia of cattle (see Part II), the name S. fusiformis is used in this discussion for the sake of convenience.

is shed in the faeces of some carnivorous mammals (see Part II) does not entirely explain the remarkably high prevalence of bovine sarcosporidiosis in, for example Britain, where it is almost 100% in old cattle (see Part II). In the U.K. (and elsewhere), farmers having cattle (and sheep) very often keep dogs as well. It was noticed that during the summer months, filth flies were numerous on dog faeces and in the vicinity of cattle. No information is available, for Britain or elsewhere, as to whether flies that have fed on dog faeces will move towards grazing cattle. In considering the life-cycle of S. fusiformis, it seemed important to know something of the movements of flies. This aspect was, therefore, studied in the field in order to determine whether filth flies might act as transport hosts.

Movement of flies between dog faeces and cattle themselves was very limited. On the other hand, several kinds of flies regularly flew from dog faeces to fresh bovine dung. When disturbed, many of these flies would rest on blades of grass, often in the immediate vicinity of grazing cattle. Thus, sporocysts of Sarcocystis spp. could be dispersed in the environment of cattle and ingested by them, a hypothesis supported by the actual discovery of flies carrying Sarcocystis sp. Oocysts of a coccidium that was thought to be the "small race" of Isospora bigemina of the dog* were also being carried by the flies. Furthermore, sporocysts of Sarcocystis spp. might in turn be transferred to cows from fly spots on cow dung by a second group of flies, which were found to move regularly between bovine dung and cattle. These flies were, primarily, Morellia spp., Musca

---

* This parasite forms tissue cysts in cattle and the dog is the definitive host (Heydorn, 1973). It may be a species of Hammondia (Frenkel, 1974; Frenkel and Dubey, 1975a, b).

autumnalis and Polietes spp. They would frequently alight on the body of an animal where it had licked itself but settled mainly on the muzzle (Figures 15 and 16), clustering around the eyes, often together with Hydrotaea irritans. As cattle frequently lick the coat and the nostril area, sporocysts deposited there could easily be ingested.

It is thought that the general pattern which emerged during this study might be much the same throughout most of Europe. Mydaea urbana and *Myospila meditabunda have been found on dog faeces in Holland and Germany (casual observation by the writer). In Denmark the kinds of flies most commonly associated with cattle (Hammer, 1941) were similar to those recorded in the vicinity of cattle during the course of the present investigation.

Wallace et al (1972) stated that on an atoll in the western Pacific, "flies were observed feeding on cat faeces that had been deposited near cooking houses". During the present study, movement was observed of Musca domestica from cat faeces to a kitchen (Markus, 1974b). M. domestica may, therefore, play a role in the transmission of T. gondii to man.

The present results on movement of house flies from the contents of emptied indoor cat litter trays are similar to previous findings concerning movement from human faeces. Sporocysts of Isospora hominis (= Sarcocystis), which might on occasions cause extraintestinal infections in man (Markus et al., 1974), could perhaps be carried by M. domestica. It has been established that M. domestica will fly from the vicinity of human faeces to kitchens. For example, flies seen walking over food by Vaughan (1900)

---

* M. meditabunda has also been collected on both cow dung and human faeces in the U.S.A. (Coffey, 1966).

Figures 15 and 16. Typical appearance of a bovine muzzle during the summer. The flies in the photographs are Morellia simplex, Musca autumnalis and Polietes albolineatus.



Figure 15



Figure 16

could be recognised as having visited faeces in pits because of the fact that lime which had been sprinkled over the contents of the pits had adhered to the flies. In a controlled experiment, Peppler (1944) trapped M. domestica where they were breeding alongside a sewage plant that was undergoing repair and sprayed them with baker's yeast. Contaminated flies, identified by culture of yeast, were recovered on food at the army camp three miles away, where there had been an outbreak of gastro-enteritis. Similarly, Shura-Bura (1952), using flies tagged with a radioactive isotope, recorded their dispersal from outside privies. This technique was also used by Zaidenov (1960) to study the movements of house flies over a route between kitchen/canteen and privy. Zaidenov (op. cit.) stated that such movements by M. domestica take place constantly. House flies marked with coloured chalk were found to move from privies to kitchens by Murvosh and Thaggard (1966), thus again confirming their potential as carriers of certain pathogens.

The natural occurrence of protozoan cysts in flies

The suggestion made here that flies might frequently transport sporocysts of S. fusiformis is supported by the work of earlier authors who examined wild-caught flies for pathogens infecting man. Protozoan cysts of sizes similar to or larger than the sporocysts of S. fusiformis were found in the gut of flies (or on flies).

Wenyon and O'Connor (1917) were the first authors to locate protozoan cysts in flies. They trapped M. domestica in an Egyptian village where conditions were unsanitary. The intestines of 18 flies out of a total of 229 contained helminth eggs and/or cysts of Entamoeba histolytica, E. coli and Giardia lamblia. One fly harboured large numbers of G. lamblia cysts - 36 were counted in a single dropping. Another fly was carrying an oocyst

of Eimeria sp., measuring 28 x 20 µm.

As no house flies were trapped away from houses on either fresh dog faeces or on the dung of cattle during the present study, it was concluded that away from sewage disposal works at least, M. domestica is not an important carrier of S. fusiformis to British cattle. In this regard a comment by Buxton (1920) may be relevant: in 1,027 M. domestica examined at a locality in Iraq, he "never found a cyst or egg of any parasite of dog or ox or horse" but did recover human intestinal parasites, including the protozoa E. histolytica, E. coli and G. lamblia, from over 4% of the flies dissected. As protozoan cysts can easily escape detection, the actual prevalence was probably higher. Buxton (op. cit.) thought that what appeared to be faeces in 63% of his flies was of human origin and considered that in an appropriate area one might expect to find any intestinal protozoon infecting man in M. domestica "if only one looks long enough". It may be noted that in Denmark and Egypt, M. domestica rarely laid eggs in pure cow dung (Thomsen and Hammer, 1936; Hafez, 1941b). Thus, house flies would not be important carriers of Sarcocystis in such a situation. On the other hand, oviposition by M. domestica took place to a greater extent in cow dung in Hungary (see Thomsen and Hammer, op. cit.).

The habits of M. domestica are not, therefore, the same in all localities. The finding in the present study that this species would not be important in the transmission of bovine Sarcocystis in the areas where field work was carried out does not exclude the possibility that M. domestica might transport Isospora hominis (= Sarcocystis) in other regions, making the parasite available to grazing cattle.

Harris and Down (1946), Coutinho et al (1957) and Federov (1962) added Iodamoeba butschlii to the list of protozoan cysts known to be carried by

M. domestica. Endolimax nana was recorded in house flies by Yao et al (1929) and Frye and Meleney (1932); and in addition to other cyst-forming protozoa, Harris and Down (op. cit.) found Chilomastix mesnili in M. domestica. Protozoan cysts of man have been found also in Chrysomya, Sarcophaga and Lucilia (Metelkin, 1935; Sukhova, 1951).

Yao et al (op. cit.) compared the recoveries of protozoal cysts from the external surfaces and intestines of wild-caught flies. Cysts were present in the intestines of flies in several batches but in surface washings of only one batch. This difference is easily understood when it is considered how soon marked flies (present investigation) tended to clean off much of the powdered chalk with which they had been dusted. Studies in the laboratory by other authors, e.g. Pipkin (1949), have also shown that external carriage of protozoan cysts by flies is relatively unimportant compared with the part played by regurgitation and excretion. Ingestion of S. fusiformis by flies would, therefore, probably be more important than contamination of the external surface by sporocysts.

Size of oocyst or sporocyst that could be ingested

The structure of the mouthparts and manner of feeding of most filth flies is such that large particles will not be ingested. A few authors have studied the ability of flies to take in and retain helminth eggs and protozoan oocysts or cysts of different sizes. The results of these experiments suggest that larger flies ingest larger particles.

Nicoll (1911), who used helminth eggs in his experiments, concluded that Calliphora erythrocephala will not convey eggs larger than about 50 µm in diameter in its alimentary canal. He considered that the upper particle size limit for the smaller M. domestica was about 40 µm. If narrower, longer eggs were to be swallowed by M. domestica, they would have to be

sucked in lengthwise.

Jausion and Dekester (1923) recorded a selective uptake of cysts of G. lamblia by house flies when G. lamblia and the larger E. histolytica were present in human faeces in equal numbers. The ratio of ingested cysts was 50 of G. lamblia : 1 of E. histolytica. Roberts (1947) found that only 40% of Eimeria acervulina oocysts (diameter approximately 22 - 25 µm) in an emulsion were taken into the gut of M. domestica, there having been a filtering off of larger particles by the flies. Using cysts of E. histolytica and E. coli and oocysts of E. acervulina, she investigated the sizes of organisms which reappeared in the vomit-drop, after having been ingested by M. domestica. It was found that particles were held back during regurgitation and that protozoan cysts, particularly ones larger than the small cysts of E. histolytica, tended to occur infrequently in vomit-drops. Roberts (op. cit.) believed that cysts of E. histolytica which entered the crop of the fly at approximately the same time, individually completed their passage through the gut at widely varying intervals.

Thus, the dimensions of the sporocysts of S. fusiformis (see Part II) are such that they could be transported in the alimentary tracts of most of the species of flies that were marked in the field during the present investigation.

Length of time that oocysts or sporocysts would be retained in the gut of flies

Factors affecting gut motility, such as temperature, diet and frequency of feeding, determine the period for which protozoan cysts remain in the gut of flies. Minimum times that have been recorded are remarkably short, viz. one and five minutes for E. histolytica in M. domestica (Sieyro, 1942; Roberts, 1947). Usually, however, cysts are retained for

longer periods. Root (1921) compared the survival times of cysts, as judged by their staining reactions, of E. histolytica, E. coli, G. lamblia, E. nana and C. mesnili in flies, and related the different survival times to differences in the thicknesses of the cyst walls of the five parasites. The cysts of C. mesnili survived the longest. After 36 hours in the fly, 50% of the C. mesnili parasites were dead. The last living C. mesnili cysts were observed after 80 hours. Wallace (1971a) found that T. gondii oocysts were carried by experimental filth flies. He recovered viable oocysts of T. gondii from M. domestica for about 24 hours and from Chrysomya megacephala for about 48 hours.

The data on S. fusiformis in C. erythrocephala in the present report, together with that mentioned above for other protozoan cysts in filth flies, show that there is ample time for flies to disseminate coccidia under natural conditions, considering their mobility (discussed below).

Movements of flies in relation to the dissemination of Sarcocystis fusiformis or Toxoplasma gondii

Amongst factors which will determine the potential importance of a species of fly in the dissemination of coccidian oocysts are (a) the range of flight and (b) the rate of dispersal. These two factors vary according to (inter alia) the weather conditions, the habitat and perhaps in some cases the strain of fly in a given geographical region (see Lucilia sericata below). Fly dispersal was studied only over short distances during the present investigation, which gave no indication of the flight range of the flies. However, something is known about long-distance movements of some of the fly species marked during the present study. It is necessary to take such work by other authors into account in order to appreciate the potential of flies as transport hosts of isosporan coccidia.

Musca domestica

Many authors have tried to ascertain the flight range of M. domestica, as this aspect of its behaviour has been considered to be of much importance in relation to the transport of various bacterial and other pathogens of man. Some of the work on movements of M. domestica was done in Britain, where the present investigation was carried out. Copeman et al (1911) liberated flies at a refuse tip just outside Postwick, "a small village situated about five miles East of Norwich, just off the main road to Yarmouth". Flies were recaptured at a distance of 800 yards from the point of release in as little as 35-45 minutes. When it is considered that M. domestica can carry viable oocysts of T. gondii for 24 hours (Wallace, 1971a), it is clear that the house fly could be an important disseminator of toxoplasmosis if it regularly covers long distances in such a short time. The maximum dispersal distance recorded by Copeman et al (op. cit.) was about one mile. Hindle and Merriman (1913), in comparing the results of their study in Cambridge with the work of Copeman et al (op. cit.), concluded that in towns, house flies do not travel as far as they do in open country. The maximum dispersal distance in Cambridge, where food and shelter for flies was plentiful, was 700 yards, partly across some open land. Nash (1913), also working in the U.K., found that environment is the main factor affecting the distance that house flies will travel: where houses were numerous, newly-emerged individuals did not fly much more than ½ a mile from the breeding place; and when the weather was warm, they moved from house to house (Nash, op. cit.).

In studies outside Britain even greater distances covered by M. domestica were recorded. In Phoenix, Arizona (Schoof et al., 1952), house flies were recovered within 24 hours at ½ a mile and one mile, in 48 hours at two and three miles and in 72 hours up to four miles away. Quarterman

et al (1954) discussed urban fly dispersal in the city of Savannah, Georgia. Flies were trapped at the same point at which they were to be released after marking. Dispersal was rapid and continuous and took place in all directions. Although most of the M. domestica were recovered within ½ a mile of where they had been released, more than half the house flies recaptured during one experiment had travelled at least a mile. This study emphasized the ability of house flies to move freely within a range of four miles or more in urban areas.

The maximum dispersal distance recorded for M. domestica appears to be just over 13 miles from the point of release (Bishopp and Laake, 1921). One of the specimens marked by these authors was caught 7.1 miles away within 24 hours.

From the above it is clear that if M. domestica were to visit cat faeces containing sporulated oocysts of T. gondii - such as the faeces from an emptied indoor litter tray, on which M. domestica was trapped during the present study - oocysts could very easily be transported to kitchens and deposited on food. The prevalence of T. gondii oocysts in the faeces of cats in Britain has not been determined, but oocysts probably occur mainly in the faeces of young cats.

Lucilia sericata

Both Quarterman et al (1954), working in an American city, and Norris (1959), who marked flies in a pastoral area in Australia, recovered marked L. sericata 3½ miles away from the respective release points after 48 hours. In a more restricted rural study area in the U.K., a laboratory-bred specimen of L. sericata was recovered ¾ of a mile away from the point of release within 48 hours (MacLeod and Donnelly, 1958). Other dispersal studies which give the distance covered by L. sericata (e.g. Lindquist et

al., 1951) do not mention the dispersal rate. Another blowfly, Chrysomya megacephala, carried T. gondii oocysts for at least 48 hours (Wallace, 1971a). This can be taken to indicate that L. sericata is potentially a "good" carrier of Sarcocystis, if flies feed on faeces in addition to coming to oviposit (Cragg, 1956). Mihályi (1966) found that L. sericata is one of the flies most commonly encountered on human faeces in Hungary. Apparently they do feed, since he writes: "They fill their abdomen with it till it is ready to burst, staining afterwards everything with their regurgitated food and excretions". Mihályi (op. cit.) did not record egg-laying by L. sericata in human faeces. Although L. sericata will visit human, dog and cow dung in the U.S.A. (Coffey, 1966) and Britain (present study), the extent to which this species carries ovine or bovine Sarcocystis spp. could differ in different regions. In Australia, for example, where the now cosmopolitan L. sericata was perhaps introduced through human agency, the chemo-sensory reaction to wool differs markedly from that of the British strain of L. sericata, which has a much stronger "wool reaction" (Cragg and Cole, 1956). In Egypt, L. sericata rarely oviposits in the dung of cattle (Hafez, 1941a). In the U.K., egg-laying has been observed in fresh "tripe-dung" (presumably faeces expressed from the intestines) at an abattoir (Green, 1951).

Other Calliphorinae

MacLeod and Donnelly (1958), working on an upland area of sheepwalks on the Roxburg-Dumfries border, Scotland, thought the immediate reaction of members of a group of caged blowflies (*Lucilia caesar and Calliphora

---

* A number of unidentified Lucilia marked during the present study are thought to have been of this species.

erythrocephala) on being released was to fly aimlessly in any direction. This may reflect normal behaviour in natural populations. There was no evidence that valley slopes affected dispersal in any way. Individuals apparently dispersed in a random pattern and it was suggested that the speed of movement in different directions was influenced by sources of attraction encountered by the flies. Both species overcame obstacles with ease, as was shown by their ability to fly up an incline of approximately 45°, rising to a vertical height of 500 ft. above the point of release (MacLeod and Donnelly, op. cit.). These authors also conducted experiments (MacLeod and Donnelly, 1960) to see what effect a belt of trees and an expanse of water would have on the movements of blowflies. Numbers of both L. caesar and C. erythrocephala readily crossed a 200 yard-width of water offered by the River Eden just before it enters the Solway estuary, U.K. Vegetation encountered after a flight which had commenced over open terrain did not represent a barrier either. Both species (as well as L. sericata) either flew over or entered, moved through and emerged from a 90-yard wood belt (MacLeod and Donnelly, 1960).

Many specimens of C. erythrocephala were collected on board the light-ship "Noord Hinder" when it was lying West of Flushing, Netherlands, approximately 70 miles away from the nearest land (Lempke, 1962). Shorter dispersal distances have been recorded on land for marked C. erythrocephala. Shura-Bura et al (1958) found the maximum flight range in a rural area in Russia to be five km., whilst in a trapping area in Britain, more limited in extent, the recorded flight range was ¾ of a mile (MacLeod and Donnelly, 1960).

The maximum distance of dispersal of laboratory-bred L. caesar in a Russian study was 6.2 km. (Shura-Bura et al., 1958), while the same species was recorded ¾ of a mile away from the point of release by MacLeod and

Donnelly (1960) in a limited trapping area in Britain.

In the present study, C. erythrocephala was rarely seen on fresh dung. The species has been found feeding on human faeces in Hungary (Mihályi, 1966) and on cow dung in the U.S.A. (Coffey, 1966). In Egypt, C. erythrocephala rarely oviposits in the dung of cattle (Hafez, 1941a).

Non-calliphorine flies

Dispersal studies which have been conducted by previous authors on species of flies which were marked during the present study, included species which are very closely associated with cattle. If such flies are caught and released where there are no cattle, it seems likely that both the subsequent rate and distance of dispersal will be greater than would normally be the case once the flies have encountered cattle for the first time, after emerging from the pupae. In one study of the dispersal of Musca autumnalis, several flies were recovered after 24 hours two miles from where they had been released while other individuals were found further away after longer periods (Killough et al., 1965). Although it has been suggested that M. autumnalis carries certain pathogens, there is as yet no actual proof of this (Teskey, 1960). Eddy et al (1962) collected Hydrotaea irritans from a herd of dairy cattle. After marking, flies were released in open country about 24 hours later. Trapping stations were set up at distances of one and five miles from the release site. H. irritans was recovered at both one and five miles. Similar studies were conducted by Tugwell et al (1966), who after a few hours recaptured H. irritans almost a mile away from the place of release. Hoelscher et al (1968) found that this species has a rapid and extensive host-seeking capacity and that it moves mainly at night. As H. irritans is haematophagous and was not found on the faeces of carnivorous mammals during the present study, the

species is thought not to play a role in the transmission of Sarcocystis to cattle.

The species of flies caught 70 miles out at sea (Lempke, 1962) included, in addition to C. erythrocephala (see above), two more species which were marked during the present investigation, viz. Scatophaga stercoraria and *Polietes landarius. These records provide an indication of the flight potential of the flies in relation to the possible transport of isosporan coccidia.

Conclusion

Taking several factors into consideration - the long patent period of Sarcocystis in e.g. canines; the fact that Sarcocystis occurs already sporulated in fresh dog faeces; the large dog populations in many countries; the proven flight propensity of muscid and calliphorid flies, amongst others; the finding of flies which were carrying sporocysts of Sarcocystis; and the sometimes rapid movement of flies from dog faeces to cattle in the vicinity - it can be seen how flies could contribute to the prevalence of bovine sarcosporidiosis.

As a result of these preliminary studies, it is concluded that dissemination of some coccidia by flies, e.g. sporocysts of Sarcocystis shed in the faeces of carnivores, is inevitable. The importance of flies as transport hosts of such coccidia is still to be assessed.

---

* A number of unidentified Polietes marked during the present study are thought to have been of this species.

PART II: DEVELOPMENT OF *SARCOCYSTIS* AND *ISOSPORA* IN TISSUES OF THEIR VERTEBRATE HOSTS

HISTORICAL REVIEW

Life-cycle of *Sarcocystis*

Introduction

Most of the experimental work on *Sarcocystis* prior to 1972 consisted of attempts to transmit the organism between mammals that commonly develop cysts in their muscles, or to birds. There are more than 20 reports claiming success in infecting such animals by feeding tissue cysts to them or by injecting tham with the cystozoite stage. References to these experiments are, or will be found in, the following papers: Scott, 1943; Spindler *et al.*, 1946; Šebek, 1960, 1962; El-Afifi *et al.*, 1963; Breuer, 1966; Panasyuk *et al.*, 1971; Sominskii *et al.*, 1971; Rommel *et al.*, 1972; Awad, 1973; Martínez-Fernández *et al.*, 1975. In the light of the recently elucidated life-cycle of *Sarcocystis*, to be reviewed below, it is clear that a number of the earlier experiments were not accompanied by adequate controls. In several experiments, cages must have become contaminated with oocysts or sporocysts.

Scott (1943) discussed "some of the more flagrant errors made in the study of Sarcosporidia", such as observations unrelated to the sarcosporidial infections, crude techniques and erroneous interpretations. Frenkel (1973b) considered that many of the reports concerning the life-cycle of *Sarcocystis* were of doubtful accuracy. He commented that some of the "detailed descriptions from sheep must be considered a mixture of stages from *Sarcocystis*, *Toxoplasma*, and *Aspergillus*, compounded by error and imagination".

Coccidial nature of *Sarcocystis*

The supposition that *Sarcocystis* was a fungus persisted even until

recently (Purohit and D'Souza, 1973) but ultrastructural studies of the tissue cysts and cystozoites* have demonstrated clearly that the organism is a sporozoon: Ludvík, 1963; Simpson, 1966; Zeve et al., 1966; Sénaud, 1967; Akao, 1970; Mandour, 1971, 1972a; Zaman and Colley, 1972; Mehlhorn and Scholtyseck, 1973; Scholtyseck et al., 1973; Simpson and Forrester, 1973; Mehlhorn and Scholtyseck, 1974a; Mehlhorn et al., 1974; Porchet-Henneré and Ponchel, 1974; Scholtyseck et al., 1974; Mehlhorn, 1975; Mehlhorn and Sénaud, 1975; Mehlhorn et al., 1975; Porchet-Henneré, 1975.

Fayer (1970, 1972a) observed gametogony of Sarcocystis in tissue culture. At about the same time, Rommel et al. (1972) showed that a disporocystid, tetrazoic oocyst stage occurs in the life-cycle, thus revealing the Isospora-like nature of Sarcocystis.

Sexual stages of Sarcocystis

Fayer (1970) studied the behaviour in cell cultures of Sarcocystis from cysts in skeletal muscle of wild grackles Quiscalus quiscula, birds in which this infection is very common (Fayer and Kocan, 1971). Cystozoites developed in six avian and mammalian cell types. The formation of "cyst-like bodies" was seen and their similarity to the oocyst stage of Eimeria noted. The significance of the cyst-like bodies was not, however, understood at the time, as sexual stages were not identified. During the course of subsequent work on the development of Sarcocystis of Q. quiscula in embryonic bovine kidney cell line cultures and embryonic bovine tracheal cells, Fayer (1972a) recognised both macrogametogony and microgametogony and again observed cyst-like bodies. Sporulation of the cyst-like forms

---

* This term was introduced for Toxoplasma gondii by Hoare (1972); "bradyzoite" is the name coined by Frenkel (1973b) for the same stage.

was attempted at laboratory temperature but was not successful. Fayer nevertheless suggested that the bodies "may be equivalent to the oocyst stage of coccidia". Of particular interest in Fayer's second paper (1972a) are the excellent photomicrographs of microgametocytes and microgametes: so far these stages have not been identified with certainty *in vivo* by subsequent workers. Fayer (*op cit.*) observed multinucleate immature microgametocytes 24 hours after inoculation of cultures (coverslips were examined at 24, 30, 42, 48 and 72 hours), a fact which will be returned to below. Five of 17 of the microgametocytes present at 30 hours contained mature microgametes. No microgametocytes or microgametes were seen after 48 hours. It is not clear from the paper whether they were present at 42 hours.

Rommel *et al.* (1972) fed ovine *Sarcocystis* to cats and dogs. In the first of four experiments using cats, six 8-week-old specific pathogen-free (SPF) animals were given, on three consecutive days, finely chopped sheep oesophagus containing "microscopic"* cysts of *Sarcocystis*. Five of the cats shed oocysts morphologically indistinguishable from those of *Toxoplasma gondii* and showed seroconversion in the dye test for *T. gondii*. The oocysts proved to be *T. gondii* after inoculation of mice. No other coccidia were recorded in the faeces of the cats but the authors could not exclude the possibility of their having been some amongst the large numbers of *T. gondii* oocysts. In a second experiment, excised macroscopic sarcocysts from sheep oesophagus were eaten by six 8-week-old SPF cats on

---

* In this review, "macroscopic" ovine *Sarcocystis* refers to the large, characteristic "*Sarcocystis tenella*" cysts sometimes seen in the oesophagus of old sheep. "Microscopic", as used by previous authors, is a relative term: see comment under the first subheading of the "Results" section.

three separate occasions. All six cats shed sporocysts containing sporozoites (and, more rarely, sporulated oocysts) from the 12th day after the first feed for 42-53 days. Fifty sporocysts measured 10.8-13.9 (12.4 ± 0.8) x 7.7-9.3 (8.1 ± 0.5) µm. Sporocysts morphologically identical to those obtained in the second experiment were passed in the third experiment by five of six cats, aged between four months and two years, after they had been given macroscopic sheep sarcocysts as before, on one occasion only. The faeces of one experimental cat remained sporocyst-free (though not coccidia-free, as all but one of the cats had been shedding oocysts of Isospora felis and/or I. rivolta at the beginning of the experiment). Sporocysts were recovered from the faeces from the 12th day onwards (from the 13th day in the case of one cat), for 8-41 days. A fourth experiment using five mature, conventionally reared cats again confirmed the coccidial nature of Sarcocystis. Prepatent periods were 12 days (two cats) and 13 days (two cats), with a patent period of 4-39 days. From the 20th to the 22nd day, a few sporocysts were found in faeces of a fifth experimental cat, which had vomited after eating sarcocysts. Eight cats from the second and third experimental groups were given macroscopic sarcocysts after shedding of sporocysts had stopped. None were found to be immune: all passed sporocysts after 12-16 days for 25-47 days.

Five germ-free dogs, four 8-week-old SPF puppies and one conventionally reared dog were fed macroscopic sarcocysts from sheep oesophagus in three separate experiments by Rommel et al. (op. cit.). No sporocysts were shed.

The work reported in the above paper was followed up by Heydorn and Rommel (1972a). In two experiments, twelve 3-month-old dogs ate, on four consecutive days, minced cattle oesophagus containing "microscopic" sarcocysts. They all passed Sarcocystis 9-10 days after the first feed and continued to do so for 57-71 days. Fifty sporocysts measured 13.9-17.0

(15.9 ± 1.0) x 6.2-10.8 (8.3 ± 1.1) µm. On the 15th day of patency the only dog that had not been shedding canine coccidia other than Sarcocystis, was sacrificed for examination of the intestine. Fully sporulated sporocysts lying in pairs, a few macrogametes and possibly microgametes were found in the lamina propria of the distal halves of villi in the posterior two-thirds of the jejunum and, to a lesser extent, in the ileum. There were no schizonts. Sporocysts lying in the lamina propria are illustrated in a photomicrograph. This was the first experimental observation of the site of gametogony and oocyst formation of Sarcocystis, a fact which has been overlooked by some subsequent authors. After cessation of sporocyst excretion, seven dogs were reinfected. They shed sporocysts for several weeks, beginning 10-12 days after the first feed.

Eight cats aged three months to one year (and which had been passing I. felis and I. rivolta) became infected after being fed cattle sarcocysts in the same way as the dogs. Shedding of sporocysts by the cats began on the 7th, 8th or 9th day after the first feed. The patent period lasted for six weeks in one cat and in the others it was at least nine weeks. Fifty sporocysts measured 10.8-13.9 (12.5 ± 0.8) x 6.9-9.3 (7.8 ± 0.6) µm.

At this early stage in the study of gametogony of Sarcocystis spp., differences (Table 8) were already apparent: whilst the dimensions of ovine and bovine sporocysts in the cat were similar, they had different prepatent periods. That of bovine Sarcocystis in the cat was about 3-6 days shorter and was more or less the same as that of bovine Sarcocystis in the dog. The bovine sporocysts in the dog were, on average, 3.5 µm larger than the others. There also appeared to be differences in the frequency with which intact oocysts were shed in early patency (Heydorn and Rommel, op. cit.).

The experimental finding of sporocysts of Sarcocystis in man was mentioned in the discussion in Heydorn and Rommel (1972a). Details, however, were not given in this paper.

Rommel and Heydorn (1972) described an experiment in which two persons started to shed sporocysts, morphologically indistinguishable from Isospora hominis, approximately nine days after each had eaten, together with onions and seasoning, 500 g of raw, minced bovine diaphragm containing Sarcocystis. One hundred sporocysts (50 from each person) measured 13.1-17.0 (14.7 ± 0.8) x 7.7-10.8 (9.3 ± 0.5) µm. They were still being shed 40 days later (when the paper went to press). In a second experiment, four persons each consumed 125 g of Sarcocystis-infected raw pork, with onions and seasoning. Three of the four persons subsequently passed sporocysts in their faeces. The sporocysts were morphologically indistinguishable from I. hominis. Measurements of 133 sporocysts (30, 50 and 53 from the three persons, respectively) were 10.8-13.9 (12.6 ± 0.8) x 7.7-10.8 (9.3 ± 0.5) µm. Although smaller than the bovine sporocysts in man, these swine sporocysts nevertheless fall within the size range given for I. hominis by previous authors. The prepatent period could be precisely determined in one person only: it was 10 days. Thirty days later, at the time the paper went to press, sporocysts were still occurring in the faeces of all three persons. Clinical symptoms were not observed other than a severe influenza-type infection with fever and slight diarrhoea in one person.

Rommel and Heydorn (1972) did not observe any sporocysts in the faeces of three cats that had been fed pork infected with Sarcocystis.

Heydorn and Rommel (1972b) studied the endogenous development of Sarcocystis in the intestines of cats. Eight SPF animals, two months old, were given one meal of chopped cattle oesophagus containing "microscopic"

cysts of Sarcocystis. One kitten was sacrificed after four, six and eight hours and after 1, 2, 3, 4 and 5 days. Development of Sarcocystis took place underneath the intestinal epithelium and within the lamina propria of the villi of the whole of the small intestine. Macrogametes and immature and mature oocysts were found but the authors again (as in the dog intestine they sectioned - Heydorn and Rommel, 1972a) did not positively identify microgametocytes or microgametes. Schizogony was not observed. After about five days oocysts began sporulating in situ within the intestinal villi.

Rommel and Heydorn (1973, 1974) summarized their earlier work and reported some new findings. Thirteen dogs were fed sheep oesophagus containing "microscopic" cysts of Sarcocystis. After 8-10 days the animals shed sporocysts with a mean size of 14.8 x 9.9 µm, i.e. 2.4 µm longer than ovine Sarcocystis sporocysts in cat faeces. Cats and dogs failed to pass sporocysts during six weeks of observation after having been given, per os, sporocysts of ovine Sarcocystis from cat faeces (to 10 cats), bovine Sarcocystis from cat faeces (to 11 cats) and bovine Sarcocystis from dog faeces (to seven dogs) (Rommel and Heydorn, 1973).

The German workers' discovery of the sexual cycle of Sarcocystis spp. of cattle and sheep has subsequently been confirmed by other authors. Euzéby et al. (1972) fed "microscopic" sarcocysts in ovine oesophagus to the cat. Although the diagram on page 207 of their paper would seem to be of the sporocyst of Sarcocystis sp., the photomicrographs on page 208 are not of Sarcocystis but resemble I. felis. These authors erroneously considered the free sporocysts they found to be those of I. felis.

Durie (1973: reference given by Ford, 1975) found that oocyst formation of ovine Sarcocystis in Australia can take place in cats.

Fayer and Leek (1973) first saw sporocysts in the faeces of all of six experimental puppies 13 days after they had eaten an infective meal of minced raw cattle heart. Thirty sporocysts measured within 24 hours of being passed averaged 16.4 x 10.7 µm. Fayer et al. (1973), however, gave the prepatent period for 13 puppies infected in the same way as 9-13 days.

Mahrt (1973) saw and photographed free sporocysts, undoubtedly those of Sarcocystis, in the faeces of dogs which were receiving a daily ration of fresh, uncooked beef offal. However, his observations did not have an experimental basis, as some authors have implied.

Markus (1973b), using infected bovine diaphragm, confirmed the German findings concerning the development of Sarcocystis from cattle in the cat and published a photomicrograph of the sporocyst (Fayer did not succeed in producing infections in 25 cats by feeding them minced bovine heart containing sarcocysts - in litt. to M.B.M., 1973). The prepatent period was approximately seven days and 50 sporocysts measured 12.9 x 8.7 µm (11.6-14.9 x 8.2-10.4; standard deviation of both length and width = 0.6) (Markus, 1973b; Markus et al., 1974). Sporocysts were passed by one cat for at least three months.

Fayer (1974a) described intestinal stages of Sarcocystis in dogs which had been infected with bovine sarcocysts in minced heart. The prepatent periods ranged from 13-22 days and were similar (except for the long prepatent periods of 22 days in three dogs) to those recorded by Heydorn and Rommel (1972a). The patent period of 3-16 days, however, was shorter. Possible reasons for this are discussed by Fayer (op. cit.). Most of Fayer's other findings confirmed results obtained in Germany: 20 sporocysts measured 14.2-20.6 x 9.2-12.8 (average 15.7 x 9.9) µm; dogs could be reinfected easily; development occurred in the subepithelium of the villi

of the small intestine. However, it was slower than that recorded by Heydorn and Rommel (1972b) in the cat. Fayer (1974a) first found sporocysts on day 8 in the dog. Schizonts were not seen and "microgamonts were not positively identified". Dogs were given sporocysts by stomach tube in two experiments. Gametogony did not occur in their intestines during observation periods of 32 days in the first experiment and 18 days in the second. No stages were located in the extraintestinal tissues of dogs (examined in the first experiment).

Ford (1974) saw sporocysts of Sarcocystis in faeces of dogs and puppies infected with "microscopic"* ovine sarcocysts, thus confirming Rommel and Heydorn's earlier (1973) findings with regard to "microscopic" cysts. After 15 days, sporocysts were passed (Ford, op. cit.). Only small numbers were detected at two months and none after three months. The sporocysts were "very uniform in size, 15 μ long x 10 μ wide".

Gestrich (1974) and Gestrich and Heydorn (1974) found that Sarcocystis in beef would still undergo gametogony in cats after storage at 2°C. for 18 days. Storage at -20°C. for three days killed the parasites. Sarcocystis in steak was "killed with certainty only if the meat was heated to an internal temperature of 65-70°C.", the parasites still being viable in "medium done" steaks.

The writer found that Sarcocystis in beef is infective to cats for at least two days after refrigeration at 4°C. (Markus et al., 1974).

---

* In this paper it is stated that in preliminary trials, coccidia were shed by dogs fed macroscopic sarcocysts. However, these were attached to pieces of oesophagus which may have contained "microscopic" sarcocysts (Ford, personal communication, 1975).

Oocysts of ovine Sarcocystis were described underneath the intestinal epithelium of a cat that was killed on the ninth day following infection with macroscopic sarcocysts from sheep oesophagus(Mehlhorn and Scholtyseck, 1974b; Mehlhorn et al., 1974).

Munday and Corbould (1974) gave dogs "S. tenella infected mutton" (which, according to Munday and Rickard (1974) had contained both macroscopic and "microscopic" sarcocysts) for one week. "Commencing on day 14 to day 30 after cessation of mutton-feeding, all the pups excreted sporocysts which were approximately 14 x 9 µm". Observations did not extend beyond day 50 of the patent period, but sporocysts were still being located in the faeces at that time.

Rzepczyk (1974) found sporocysts in the faeces of naturally-infected carpet pythons Morelia spilotes variegata in Australia and Sarcocystis in the musculature of an indigenous species of rat, Rattus fuscipes. He showed experimentally that Sarcocystis in the rat gives rise to the sporocysts in the python (it did not do so in two kittens). Sporocysts produced stages in laboratory-bred Rattus norvegicus when fed to them.

Rommel et al. (1974) gave more details concerning the infection of dogs with "microscopic" sarcocysts from sheep than appeared in the abstracts of their two papers read at meetings (Rommel and Heydorn, 1973, 1974). All of 17 dogs shed sporocysts after a prepatent period of 8-9 days. One hundred sporocysts measured 13.1-16.1 (14.8 ± 0.8) x 8.5-10.8 (9.9 ± 0.7) µm. A human volunteer did not become infected after ingesting macroscopic sarcocysts from sheep (faeces were checked for three weeks). Eight dogs fed pork containing Sarcocystis passed sporocysts 9-10 days later, for at least six weeks. Six cats did not do so, in spite of two of them (together with four of the dogs) having been given heavily-infected meat from a pig

orally infected five months previously with swine sporocysts from dogs. The swine sporocysts in dogs were smaller (Table 8) than both bovine and ovine Sarcocystis in dogs, 50 measuring 10.8-13.8 (12.6 ± 0.6) x 9.2-10.8 (9.6 ± 0.5) μm. Beef containing Sarcocystis was fed to six wolves Canis lupus, four red foxes Vulpes vulpes, three hyaenas Hyaena hyaena, one brown bear Ursus arctos and, as controls, two dogs. Only the wolves, foxes and dogs shed sporocysts (9-10 days later, for at least six weeks). The dimensions of the sporocysts from the wild carnivores corresponded to those from dogs. Eight cats did not pass sporocysts after eating the following tissues from other cats which, six weeks earlier, had been given orally 40,000 sporocysts of ovine Sarcocystis from cat faeces: skeletal and heart muscle, lung, liver and spleen. In this paper, which in effect summarizes the German work with regard to gametogony of Sarcocystis spp., Rommel et al. (1974) gave a revised average prepatent period for macroscopic ovine cysts in the cat, viz. 11-14 days; and a revised mean size for bovine Sarcocystis in the dog, viz. 16.3 x 10.8 μm (Table 8).

Fayer (1974b) and Fayer and Johnson (1975) found that bovine Sarcocystis undergoes gametogony in the coyote Canis latrans.

Ruiz and Azab (according to Frenkel, 1974), working independently, saw sporulated sporocysts after feeding murine Sarcocystis to cats. Endogenous stages of S. muris have been studied in the cat intestine (Ruiz and Frenkel, in preparation - see Wallace and Frenkel, 1975). The macrogametes, like those of Toxoplasma and Hammondia, were smaller than Besnoitia macrogametes.

Mutton containing "large" and "small" sarcocysts was fed to cats and dogs by Munday and Rickard (1974). Sporocysts were first seen in the faeces of the animals after 10-30 days. The sporocysts from cats measured

12.5 x 8.0 µm and those from dogs 14.7 x 9.0 µm. These sporocyst dimensions are similar to those given previously (Table 8) by Rommel and Heydorn (1973, 1974) and Rommel et al. (1974). Munday et al. (1975) described the gut stages of Sarcocystis in dogs fed mutton containing either "microscopic" or both "microscopic" and "macroscopic" sarcocysts. Shedding of sporocysts in dogs not sacrificed before patency, started at 13-15 days. Gametogony and oocyst formation took place mainly in the lamina propria of the tips of villi in the proximal third of the small intestine, in contrast to the sexual stages of bovine Sarcocystis in dogs, which had been found to occur mainly in the posterior small intestine (Fayer, 1974a). Munday et al. (1975) saw stages that could possibly have been microgametocytes and microgametes. They suggested that the reason why previous authors had not observed microgametogony in vivo may have been because observations had been made too late in the infection - see page 94.

Sarcocystis in minced cattle heart from an abattoir survived "refrigeration" (presumably 4°C.) for at least three days, as judged by shedding of sporocysts of Sarcocystis by dogs (Fayer, 1975). Dogs fed minced beef purchased from a local grocery store also became infected, as did dogs given raw or rare patties made from minced beef bought in a large supermarket. The temperature in the centre of the rare patties had reached 37.8-53.3°C. Medium (60°C.) and well done patties (71.1-74.4°C.) did not give rise to infection in dogs. Minced beef from a supermarket was placed in the "freezer section of a refrigerator" (Fayer, op. cit.) for seven days, after which it was fed to dogs. The dogs did not pass sporocysts.

Ford (1975) established a sheep-dog-sheep cycle in the laboratory for "microscopic" ovine Sarcocystis, using specific pathogen-free animals.

Martínez-Fernández et al. (1975) infected cats with "S. tenella".

The prepatent period was 12-16 days and the dimensions of the sporocysts were 12.7 x 7.2 μm. Puppies infected with bovine Sarcocystis shed sporocysts 16.2 x 10.0 μm after 8-12 days, for 28-33 days. Repeated attempts were made to infect cats with bovine Sarcocystis, but without success.

Tadros and Laarman (1975a) studied the life-cycle of Sarcocystis of the vole Microtus arvalis and the weasel Mustela nivalis. The faecal stages in the weasel were shed in a sporulated state and as free sporocysts. These authors (1975b) reported seeing microgametocytes and macrogametocytes (but not schizonts) in scrapings of the small intestine of a naturally infected weasel.

Early asexual stages of Sarcocystis

Fayer and Johnson (1973) were the first authors to see schizonts of Sarcocystis in experimental animals fed sporocysts. Schizonts were located in all tissues taken from four of five calves during autopsy 26-33 days after having been fed 2.5×10^5 - 1.0×10^6 sporocysts of bovine Sarcocystis from the faeces of experimental dogs. The schizonts were reported to vary greatly in shape and it was thought that most were immature. The size of 25 schizonts was 3.8-13.3 x 7.6-26.6 (average 9.1 x 14.8) μm. Fayer and Johnson (op. cit.) found 3-50 nuclei (average 27.3) in 25 schizonts. Markus et al. (1974) recognised two different types of schizont in kidney, unstained sections of which were kindly provided by Drs Fayer and Johnson. A description and photomicrographs of schizonts in Fayer and Johnson's material are provided elsewhere in this thesis. In subsequent experiments (Fayer et al., 1973; Fayer and Johnson, 1974), schizonts were first found 20 days after sporocysts had been fed to calves and were not seen in animals 40, 46 and 54 days after ingestion. These authors postulated that the products of the schizogony in calves gave rise to sarcocysts in muscle.

Two schizonts were observed in a section of lymph node from a calf that had been given sporocysts recovered from the faeces of naturally infected coyotes Canis latrans (Fayer, 1974b; Fayer and Johnson, 1975).

Gestrich et al. (1974) found schizonts in all organs taken at autopsy from experimental lambs that had ingested sporocysts of ovine Sarcocystis from dog faeces.

Merozoites and schizonts in cattle infected with sporocysts of bovine Sarcocystis from dog and cat faeces were reported by Gestrich et al. (1975). The results with regard to bovine sporocysts from dogs in cattle were similar to those of Fayer and Johnson (1973, 1974).

Schizogony and pathological changes in calves resulting from oral inoculation with bovine sporocysts from canine faeces is described by Johnson et al. (1975).

Munday et al. (1975) gave an account of schizogony in lambs infected with ovine sporocysts of dog origin. This paper provides confirmation of the schizogony previously recorded by Gestrich et al. (1974).

Tadros and Laarman (1975a, b) saw schizonts in two voles Microtus arvalis after feeding them sporocysts from the faeces of a weasel Mustela nivalis that had been experimentally infected with vole Sarcocystis.

Host specificity of Sarcocystis and number of species occurring in large domestic meat animals

Observations on pathogenicity mentioned below were based on infection of experimental lambs or calves with large numbers of sporocysts.

Photomicrographs showing the structure of muscle cysts in calves fed Isospora hominis (= Sarcocystis) sporocysts were published in a short communication by Heydorn et al. (1974).

Free, sporulated sporocysts in the faeces* of wild coyotes Canis latrans in the U.S.A. apparently gave rise to schizogony and cyst formation in calves, in which the organism was pathogenic, but did not infect lambs (Fayer, 1974b; Fayer and Johnson, 1975). Bovine Sarcocystis from dogs that had ingested sarcocysts from non-experimental cattle did not infect lambs either (Fayer and Johnson, op. cit.). Dogs fed heart, diaphragm and other muscle from calves infected with coyote sporocysts shed these stages, indistinguishable morphologically from the original coyote inocula (Fayer, op. cit.). Coyotes given Sarcocystis-infected bovine heart from an abattoir, passed sporocysts indistinguishable from those found in the faeces of the naturally-infected coyotes. The authors inferred that S. fusiformis undergoes gametogony in dogs and coyotes and that the cattle sporocysts from these canines do not infect sheep.

Sporocysts of ovine and bovine origin from dog faeces were pathogenic in lambs and calves, respectively (Gestrich et al., 1974). Ovine Sarcocystis from cat faeces did not affect lambs and bovine Sarcocystis from cat faeces was only mildly pathogenic in calves. Sporocysts of bovine origin from dog faeces did not cause disease in lambs.

Munday and Rickard (1974) confirmed the German observations that macroscopic sarcocysts in sheep gave rise to oocyst formation in cats but not dogs; and that "microscopic" ovine sarcocysts infected dogs but not cats. This point had been stressed by Rommel and Heydorn (1973, 1974). Developing and mature sarcocysts were found with difficulty in lambs fed

---

* The coyote faeces were obtained from carcasses that had been frozen.

ovine sporocysts from cat faeces (see also Gestrich et al., 1975) but were easy to demonstrate in lambs that had ingested ovine sporocysts from dogs (Munday and Rickard, op. cit.). The pathogenic effect of canine sporocysts in lambs was noted. It was suggested in this paper and by Munday et al. (1975) that cats and dogs might be hosts for a single species of Sarcocystis occurring in both cattle and sheep. However, more recent results in press (Munday, personal communication, 1975) show that this is not, in fact, the case. This new view in Australia is in line with the findings of the German workers (Gestrich et al., 1974, 1975). Munday et al. (1975) commented that developing sarcocysts seen in sheep infected with ovine sporocysts from dogs differed from those studied by Fayer and Johnson (1974) in calves at about the same time after infection with bovine sporocysts from dog faeces: the sarcocysts in sheep lacked a distinct cyst wall.

Gestrich et al. (1975) gave additional details concerning work that had been summarized in a short communication (Gestrich et al., 1974) and presented new information. Clinical reaction resulting from the feeding of bovine sporocysts from man to calves was minimal. No schizonts or muscle cysts were found in lambs that had been given bovine sporocysts from dog faeces or in calves that had ingested ovine sporocysts from dogs. A puzzling finding was the fact that sarcocysts were not seen in lambs fed ovine sporocysts from cat faeces (cf. also Munday et al., 1975); and cats did not shed sporocysts when fed meat from the experimental lambs. As a result of these and other experiments, Gestrich et al. (1975) concluded that the ovine and bovine sporocysts shed by dogs belong to distinct species which are specific for the herbivore hosts. It was found that there are at least three species of Sarcocystis in cattle, which undergo gametogony in cat, canine and human hosts, respectively. The walls of muscle cysts in calves on the 98th day after infection with bovine

sporocysts from dogs were thin, measuring $< 0.5\ \mu m$. However, bovine sporocysts in cat and human faeces gave rise to thick-walled sarcocysts, measuring $> 3.8\ \mu m$ on day 98 post inoculation. The structure of the cyst wall might be of taxonomic value as the wall is not of host origin (Mehlhorn et al., 1975a, b). Variations in pathogenicity, tissue cyst morphology* and carnivore host specificity* were discussed by Gestrich et al. (1975) in conjunction with criteria discovered earlier (vide antea), viz. differences in prepatent period and sporocyst size (Table 8). Muscle cysts of species of Sarcocystis can differ ultrastructurally in various ways (Gestrich et al., 1975; Heydorn et al., 1975; Mehlhorn et al., 1975a, b).

Kaliner (1975) suggested that the "different morphology of the cyst and its wall may be more a function of the immunological status of the host, which will vary in the individual animal at different times and for different sarcosporidian species". He implied that if the structure of the cyst wall is to be used for taxonomic purposes, differences in technique will also have to be taken into account.

---

* Approximately 5% of bovine sarcocysts resulting from infection of calves with bovine sporocysts from cats, dogs and man, respectively, were not of the expected type (Mehlhorn et al., 1975b) and the 5% of tissue cysts were considered to be the result of natural, accidental infection of the experimental calves with a second (or third) type of sporocyst. Unexpected excretion of sporocysts by the "wrong" carnivore hosts fed meat from prey animals originally infected with sporocysts has also been ascribed to "contamination" (Munday and Rickard, 1974; Gestrich et al., 1975). This may be a valid explanation as tissue cysts have been found in uninfected control animals (e.g. Gestrich et al., op. cit.).

TABLE 8

Sporocysts in final hosts after ingestion of Sarcocystis - infected mutton, beef and pork*

Final host	Cysts in sheep				Cysts in cattle		Cysts in swine	
	Macroscopic cysts		"Microscopic" cysts					
	Prepatent period (days)	Sporocyst size (µm)	Prepatent period (days)	Sporocyst size (µm)	Prepatent period (days)	Sporocyst size (µm)	Prepatent period (days)	Sporocyst size (µm)
Cat	11-14	12.4 x 8.1	-	-	7-9	12.5 x 7.8	-	-
Dog	-	-	8-9	14.8 x 9.9	9-10	16.3 x 10.8	9-10	12.6 x 9.6
Man	-	-	?	?	9-10	14.7 x 9.3	10	12.6 x 9.3

* Data from Rommel et al. (1974).

- = sporocysts not shed.

? = not investigated

Miscellaneous

The fine structure of microgametogony, macrogametogony and oocyst formation of Sarcocystis of the grackle Quiscalus quiscula in cell culture greatly resembles that of Toxoplasma and Eimeria (Vetterling et al., 1973). Mehlhorn and Scholtyseck (1974b) and Mehlhorn et al. (1974) described the ultrastructure of the oocyst of S. tenella.

Ashford (1975) saw "young Sarcocystis cysts" in a canary, two months after it had been fed Isospora buteonis. This parasite is referred to in the "Discussion".

Dissanaike and Poopalachelvam (1975) described Sarcocystis booliati from the moon rat Echinosorex gymnurus in Malaysia, in which species an unidentified sporozoon also occurred. The latter parasite was thought not to be a part of the life-cycle of Sarcocystis of the moon rat and was named Octoplasma garnhami. It is most unlikely that the faecal stage of S. booliati will prove to be shed in the unsporulated state and to have the appearance of the canine isosporan oocyst depicted in the life-cycle diagram on page 183 of this paper.

Cystozoites of sheep Sarcocystis were found to enter embryonic sheep kidney cells in culture and round up (Dubremetz et al., 1975).

Šibalić (1975a) reported the apparent isolation of Sarcocystis by inoculation of blood and other material from suspected cases of human toxoplasmosis. Information concerning controls is insufficient to enable these equivocal results to be assessed.

Frenkelia has a Sarcocystis-like faecal stage in its life-cycle (Rommel and Krampitz, 1975). The oocysts of Hammondia and Besnoitia, however, are Toxoplasma-like (Frenkel, 1974; Peteshev et al., 1974; Frenkel

and Dubey, 1975a, b; Rommel, 1975; Wallace, 1975; Wallace and Frenkel, 1975).

Addendum

Vershinin (1973) studied macroscopic ovine Sarcocystis in the cat, confirming results obtained in Germany with regard to the prepatent period (found to be 13-15 days), subepithelial site of development in the intestine and absence of schizogony in cats sacrificed at three and 20 days post infection.

Intestinal isosporan coccidia of non-human Primates

Coccidia are rarely observed in the faeces of non-human Primates, even though examinations for intestinal parasites are frequently carried out (Rowland and Vandenbergh, 1965; Porter, 1972; Cummins et al., 1973; Ford and Speltie, 1973; Owen and Casillo, 1973; Arambulo et al., 1974; Keeling and McClure, 1974).

Six species of isosporan coccidia have been described from non-human Primates. An oocyst residuum and micropyle are absent in all six Isospora spp. A sporocyst residuum is present in all. A Stieda body occurs only in I. cebi.

Rodhain (1933) named Isospora arctopitheci from a captive white-eared marmoset Hapale jacchus penicillatus (now known as Callithrix jacchus). The oocyst dimensions were given as 25.5-30.5 x 23.2-25.5 µm and those of the sporocysts as 10.2 x 15.3 µm. Hendricks (1974) redescribed I. arctopitheci. Fifty sporulated oocysts from a naturally infected marmoset Saguinus geoffroyi in central America were 22.7-32.7 x 20.5-27.3 (mean 27.7 x 24.3) µm. Fifty sporocysts measured 13.1-20.5 x 9.8-15.9 (mean 17.6 x 12.5) µm. Hendricks (op. cit.) showed experimentally that I. arctopitheci can infect more than one genus of primate (see following section).

Poelma (1966) saw a parasite which closely resembled I. arctopitheci in the contents of the posterior portion of the digestive tract of a galago Galago senegalensis that had died in the Amsterdam zoo the day after importation from Africa.

Arcay-de-Peraza (1967) described I. scorzai from an Uakari monkey Cacajao rubicundus in the London Zoo. The oocysts were 23.4 x 19.5 µm and the sporocysts 14.3 x 9.1 µm. No information was given on the size range

or number of oocysts and sporocysts measured. I. scorzai is porbably a synonym of I. arctopitheci. A monkey belonging to a different genus was infected experimentally (see following section).

I. cebi Marinkelle, 1969 from the Colombian monkey Cebus albifrons measured 19.1-22.9 x 16.5-21.1 (mean 20.9 x 19.8) µm. The sporocyst dimensions were 12.1-16.8 x 9.0-13.9 (mean 11.2 x 14.9) µm. The morphology of I. cebi is different from that of all other isosporan coccidia of non-human Primates and is clearly a valid species.

I. papionis was described by McConnell et al., 1971 from scrapings and sections of the intestine of the chacma baboon Papio ursinus* in South Africa. Oocysts of I. papionis, which is considered by the present author to be Sarcocystis (see "Discussion"), were also found in skeletal muscle of baboons (McConnell et al., 1972, 1974). The dimensions of 100 sporocysts from the intestinal wall were 10-13 x 7-9 (mean 8.5 x 11) µm.

Rijpstra (1967) saw I. hominis-like sporocysts, which must have been those of Sarcocystis (see "Discussion"), in the faeces of a young, pet chimpanzee Pan troglodytes.

"Isospora sp." was found in faeces of a baboon Papio cynocephalus* in Kenya (Kuntz and Moore, 1973).

Two species of Isospora were described from captive Goeldi's marmosets Callimico goeldii in 1974, by different authors: I. endocallimici Duszynski and File and I. callimico Hsu and Melby. Fifty sporulated oocysts of the former species (from four host individuals) measured 25-31 x 21-27 (mean 27.8 x 24.0) µm and 16 sporocysts 10-13 x 5-6 (mean 11.3 x 5.4) µm. Fifty

---

* Papio ursinus and P. cynocephalus are considered conspecific by some authors (McConnell et al., 1974).

sporulated oocysts of I. callimico from the infected marmoset were 13.2-20.6 x 11.5-17.4 (mean 16.9 x 14.9) µm. Twenty-five sporocysts were 10.2-12.6 x 6.6-9.0 (mean 7.5 x 11.3) µm. I. endocallomici may be a synonym of I. arctopitheci. In view of the marked differences in size, I. endocallimici and I. callimico cannot be the same species.

Development of coccidia of mammals in "abnormal" hosts

Mice and chickens were infected with Isospora felis during the present study. Previous work concerning both Isospora sensu strictu and Eimeria spp. of mammals has been included in this section as the latter genus is similar to Isospora in that most Eimeria spp. are considered to be primarily "intestinal" parasites, unlike coccidia such as Toxoplasma and Sarcocystis.

Eimeria

Successful experimental transmission in the cases mentioned below, resulted in production of oocysts except where otherwise stated.

Eimeria mohavensis occurred in naturally infected rats Dipodomys panamintinus mohavensis but not in the sympatric D. merriami merriami. E. mohavensis could, however, be transmitted to D. m. merriami in the laboratory (Doran, 1953).

Cross infection experiments performed with Eimeria spp. of rodents were reviewed by Levine and Ivens (1965a), who found only one recorded instance in which transmission to a species of a different host genus had been achieved. Levine and Ivens (1970), after reviewing the relevant literature, concluded that transmission of Eimeria spp. of ruminants probably does not occur between members of different tribes.

Coccidial schizonts found in the intestines and enlarged mesenteric lymph nodes of goats fed mixed inocula of E. arloingi, E. faurei and E. ninaekohlyakimovae of sheep origin were "abnormal" in appearance and did not contain mature merozoites (Lotze et al., 1964). It should be noted, however, that sexual stages did not develop in the intestines of sheep fed large numbers of E. intricata either (Lotze and Leek, 1970). The sheep is

the natural host of E. intricata.

Eimeria nieschulzi of rats formed young schizonts in Mus musculus intestines but a mature first generation schizont was seen in a mouse only once (Marquardt, 1966).

Todd and Hammond (1968) found that E. callospermophili infects six species of ground squirrels (Spermophilus spp.) as well as the closely related prairie dog Cynomys leucurus. Todd et al. (1968) showed that E. bilamellata could be transmitted to four Spermophilus spp.

De Vos (1970) successfully transmitted E. chinchillae, originally described from Chinchilla laniger, to rodent species belonging to no less than seven genera.

Sporozoites of E. falciformis of mice did not appear to divide after entering epithelial cells in the caeca and upper colon of chickens (Haberkorn, 1970). On the other hand, E. tenella of the chicken formed some schizonts in intestines of mice. Complete schizogony of E. falciformis was seen in rats but no gametogony occurred. The life-cycle of E. contorta, a species described from rats by Haberkorn (1971), took place in the rodents Mus musculus and Mastomys natalensis.

Todd et al. (1971) found second generation schizonts of E. vermiformis (of Mus musculus) containing mature merozoites in dexamethasone-treated Rattus norvegicus. No sexual or extraintestinal stages were located in tissue sections from either these or untreated rats. However, a treated rat passed a few oocysts 11 days after having been given an oral inoculum. The oocysts failed to sporulate and could not be identified. Todd and Lepp (1972) reported completion of the life-cycle of E. vermiformis in dexamethasone-treated rats. Oocysts were not produced in untreated rats.

E. separata was transmitted from its normal host Rattus norvegicus to Mus musculus without the aid of an immunosuppressive agent (Mayberry and Marquardt, 1973). Oocyst production occurred in all five mice given oocysts.

Mayberry et al. (1975) adduced evidence that it is the genetic constitution or strain of the abnormal host that determines whether the coccidian parasite will complete its life-cycle.

Isospora (sensu strictu)

Sporulated oocysts of Isospora scorzai (possibly a synonym of I. arctopitheci) from a Uakari monkey Cacajao rubicundus in the London Zoo were fed to another neotropical monkey Cebus nigrivittatus from Venezuela. The experimental infections were successful, resulting in oocyst production (Arcay-de-Peraza, 1967). Hendricks and Walton (1974) and Hendricks (1974) showed experimentally that I. arctopitheci could infect both the white-faced capuchin monkey Cebus capucinus and the marmoset Saguinus geoffroyi. Oocysts were passed by both hosts. There may be other published reports of the completion of life-cycles of species of Isospora in "abnormal" hosts. This review, however, is concerned primarily with Isospora spp. of domestic carnivores.

Large isosporan coccidia which occur commonly in the faeces of cats and dogs have been thought to be host specific. For example, the feeding of oocysts of I. felis of the cat to dogs did not result in infections in which oocyst production could be demonstrated (Dubey et al., 1970a; Shah, 1970; Lage et al., 1974).

Frenkel and Dubey (1972a) gave oocysts of the feline coccidia I. felis and I. rivolta to mice per os and found "zoites" in mesenteric lymph nodes

during the first week, both free and within cells. Extracellular, "ensheathed" forms appeared after four or five days. The zoites of I. rivolta resembled those of I. felis but were smaller. The dimensions of 10 Giemsa-stained zoites of I. rivolta in tissue imprints were 10-13 x 5-8 µm. After development of the sheath, they were 10-15 x 7-10 µm, with the sheath measuring 14-20 x 7-11 µm. The sporozoites of I. rivolta that were ingested were only 6-8 x 3-4 µm. Ten "multiplying zoites" of I. felis were 7-10 x 6-8 µm and more ovoid in shape than the sporozoites ingested (13 x 3-4 µm). The size of ensheathed forms of I. felis was 13-26 x 6-11 µm, with the sheath measuring 21-35 x 7-14 µm.

Extraintestinal tissues of mice, rats and hamsters which had been fed I. rivolta and I. felis were infective for kittens after intervals ranging from 10-67 days (and would probably be infective after longer periods). The prepatent period of I. felis was 2-4 days shorter in kittens which had ingested tissues of infected mice than in kittens fed oocysts. Frenkel and Dubey (op. cit.) considered that the shorter prepatent period "correlated with the finding of active multiplication in mice" (I. felis occurred singly or in pairs). There was no difference between the two prepatent periods for I. rivolta, "which did not multiply materially in mice".

Cysts of Isospora in mice are not infective for other mice and the cyst of I. felis in the mesenteric lymph node of the mouse is known to persist for at least 15 months (Frenkel, 1974).

Other authors gave oocysts of Isospora spp. to mice, cats, dogs and chickens. These vertebrates became infected extraintestinally, as was shown indirectly by feeding tissues back to the "proper" hosts. This was done using I. rivolta of the dog in mice (Heydorn, 1973), I. arctopitheci of Primates in mice and chickens (Hendricks and Walton, 1974), I. canis

of the dog in cats and mice (Dubey, 1975) and I. felis of the cat in dogs (Dubey, op. cit.). In the above experiments, findings were that dogs began shedding I. rivolta oocysts five days after ingesting tissues; the 8-day prepatent period of I. arctopitheci in Primates was the same as in animals infected with oocysts; and the prepatent period for I. canis was slightly shorter in dogs given mouse tissues than in dogs fed oocysts.

Markus (1975) did not see Toxoplasma-like proliferation of I. felis in extraintestinal tissues of normal and immunosuppressed mice or birds and suggested that whilst such a parasite might infect man, it seems unlikely that it would be pathogenic.

The asexual proliferation that takes place in persisting primary or recrudescent human toxoplasmosis did not occur in cell cultures infected with Isospora spp. of mammals either, viz. I. felis and feline I. rivolta (Sheffield and Melton, 1970; Fayer, 1972b; Shibalova and Petrenko, 1972; Fayer and Thompson, 1974) and I. canis (Fayer and Mahrt, 1972).

RESULTS

Prevalence of *Sarcocystis* in cattle, sheep, swine and horses in Britain

Samples of heart or skeletal muscle from a number of large domestic animals slaughtered at abattoirs in South-East England were checked for *Sarcocystis* during this study, at a time when material for possible experimental use was being sought (see Table 9). Material was examined fresh, by the method described on page 13. It is considered that the figures in Table 9 do not show the true prevalence of sarcosporidiosis. Light infections will have been overlooked. The data in Table 9 also do not reflect possible seasonal variations in prevalence (e.g. Drost, 1974). No attempt was made to determine whether skeletal muscle was more frequently infected than cardiac muscle or *vice versa*.

In sheep and cattle commonly referred to by authors as being "microscopically" infected with *Sarcocystis*, small macroscopic cysts can often also be seen. In skeletal muscle of cattle, there are "fine, white, thread-like streaks running lengthwise; and up to about 1 centimetre long" (Markus, 1973b; Markus, unpublished observations in Berlin). Usually, however, they are much shorter. Cysts similar to those found in beef occur in both local and imported mutton in Britain. Such cysts in infected mutton and beef show up clearly against the polythene used to wrap meat in British supermarkets and others elsewhere.

TABLE 9

Prevalence of *Sarcocystis* in some animals slaughtered in S.E. England (see text)

Animal	Muscle examined	Age	Number infected/number examined
Cattle	skeletal and heart	all over 6 years	68/72
Sheep	oesophagus	all lambs	23/45
*Pigs	heart	?	0/14
**Horses	heart	all except three over 10 years and up to 30	0/20

*Thornton (1972) could not recall "ever having seen a case of sarcosporidiosis in pig carcases in Britain". This observation refers to macroscopic cysts. The pigs examined by the present author are thought not to have been free-ranging.

**Material kindly provided by Dr. Colin Ogbourne (Commonwealth Institute of Helminthology).

Sporocysts of Sarcocystis of cattle in cats

Eight kittens aged between six and twelve weeks and one cat aged about one year were fed Sarcocystis-infected beef (Figures 17 and 18), usually in conjunction with attempts to infect chimpanzees. It was intended that the cats should serve as "control" animals for the chimpanzee experiments. Both conventionally reared and specific pathogen-free cats (see pages 11-12) were used.

Cats fed infected muscle other than heart started to shed sporocysts (Figure 19) and, less often, intact oocysts (Figure 20) after 6-8 days. Sarcocystis was always passed for more than six weeks and in all except three cases, for at least two months. Fifty sporocysts from a single animal measured 12.9 x 8.7 µm (11.6 - 14.9 x 8.2 - 10.4; standard deviation of both length and width = 0.6). In two cats sacrificed during patency, sporocysts were located in the lamina propria of the small intestine (Figure 21). Schizonts were not observed, nor was microgametogony seen. Animals were probably examined too late in the infection for microgametocytes to be present. It is considered that they were not overlooked as the structures are conspicuous - cf. microgametocytes of Isospora sensu strictu, an example of which is an *Isospora sp. of the yellow mongoose Cynictis penicillata (Figures 22 - 27).

Three kittens fed bovine heart muscle only, did not become infected. One of these animals shed sporocysts when subsequently given infected

---

*This is probably a new species: see a review of Isospora spp. of mongooses by Levine and Ivens, in press, Proceedings of the Oklahoma Academy of Sciences. The mean size of 25 oocysts from C. penicillata was 33.8 x 30.0 µm. Twenty-five sporocysts averaged 19.0 x 15.0 µm.

Figure 17. Sarcocyst from bovine heart muscle (x 200). Fresh preparation. Whether the sarcocyst illustrated infects cats is not known.

Figure 18. Cystozoites of a Sarcocystis sp. of cattle, liberated from a sarcocyst isolated from cardiac muscle (x 1,500). Fresh preparation.



Figure 17

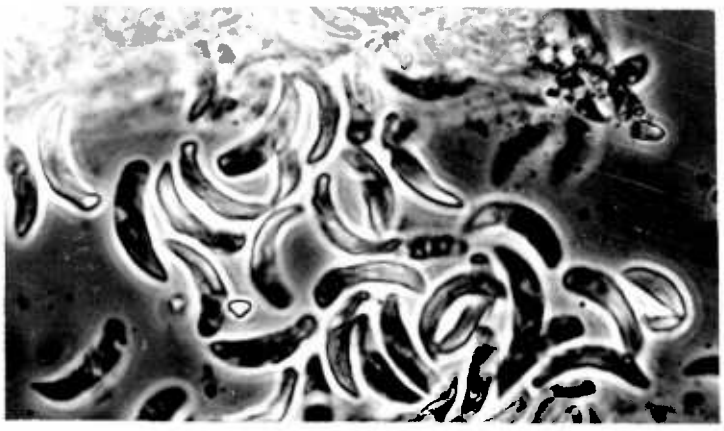

Figure 18

Figures 19 and 20. Bovine Sarcocystis from cat faeces (x 2,000). Fresh preparations. 19. Free sporocyst containing sporozoites. 20. Intact oocyst (note thin oocyst wall).

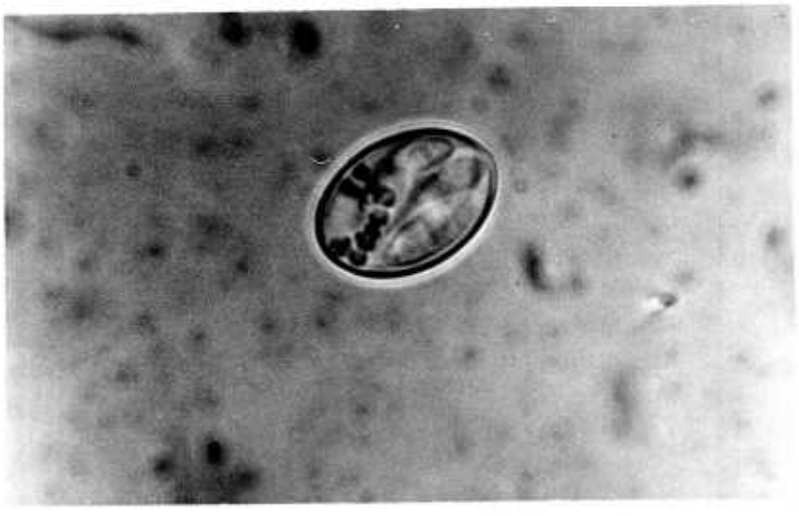

Figure 19



Figure 20

Figure 21. Comparison of the sites of development of Sarcocystis and Isospora felis in the small intestine of the cat (x 1,600) Giemsa's stain. Upper left: the nuclei of two sporozoites can be seen in a subepithelial location, in a sporocyst of a bovine Sarcocystis sp. Lower right: developing oocyst of I. felis in the intestinal epithelium.

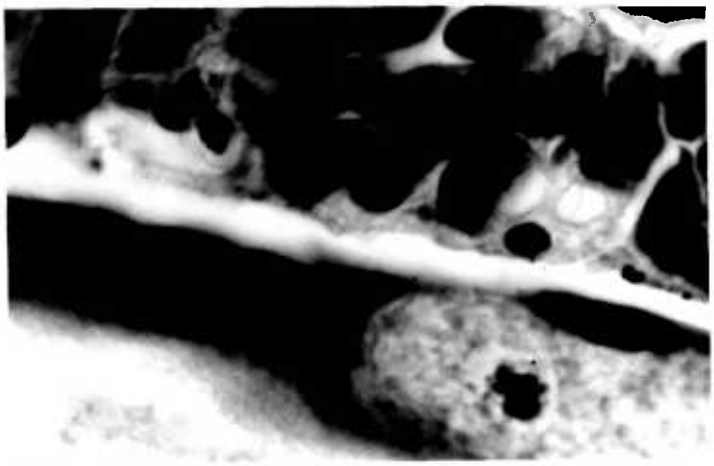

Figure 21

Figure 22. The yellow mongoose Cynictis penicillata, host of a new species of Isospora.

Figure 23. Location of a yellow mongoose colony in old bristly ground squirrel Xerus inauris burrows in semi-arid scrub country, W. Transvaal, S. Africa.



Figure 22



Figure 23

Figures 24-27. Microgametogony and sporulated oocyst of Isospora sp. of the yellow mongoose Cynictis penicillata. 24. Immature microgametocyte with fragmented nuclei and irregular fissures in the cytoplasm. Iron haematoxylin. 25. Later microgametocyte with partially invaginated surface. Haematoxylin and eosin. 26. Microgametocyte at a still later stage of development, containing dark, spherical nuclei. In other planes of focus the orientation of these nuclei was seen to be mainly peripheral. Haematoxylin and eosin. 27. Sporulated oocyst. Fresh preparation.

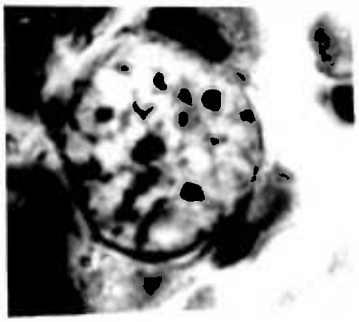

Figure 24

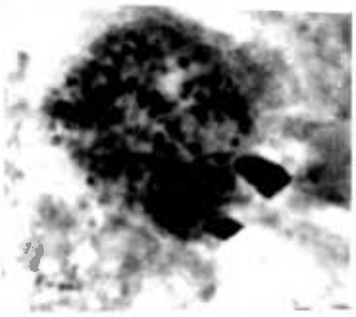

Figure 25



Figure 26

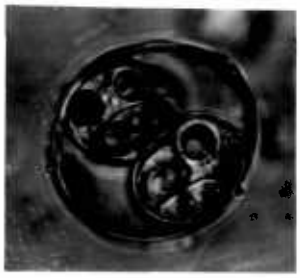

Figure 27

10 μm scale for 24-26: ⊢——⊣

10 μm scale for 27: ⊢—⊣

cattle diaphragm.

Three kittens that were passing oocysts of I. felis became infected when given meat containing Sarcocystis.

A cat that ate infected beef that had been stored at 4°C. for two days, passed sporocysts.

Serum from an experimental cat with an intestinal infection of Sarcocystis did not show antibodies to Sarcocystis in the indirect fluorescent antibody test (see pages 18 and 19) during a period of six months after infected meat had been ingested.*

The Sarcocystis infections in cats tended to be light and was probably related to the number of cystozoites infective for cats in the meat eaten. Beef heavily infected with the appropriate sarcocysts would presumably give rise to larger numbers of sporocysts in cats.

---

*It should be noted that experimental cats which become infected with related coccidia such as Toxoplasma sometimes do not develop demonstrable antibody; or show only low titres.

Attempted infection of chimpanzees with cattle Sarcocystis

As reported by Markus et al. (1974), the author attempted to infect four splenectomized chimpanzees (in five experiments at different times) with Sarcocystis-infected beef. It was hoped to obtain more information about the human infection by using a higher ape. Initially, heart in a suspension of saline (see pages 15-18) in milk was used and, later, minced diaphragm in banana and/or coated with sugar. A stomach tube was used on one occasion. Details of the amounts of meat eaten or number of cysts ingested were recorded, but as in the case of infections using cats, this information is of doubtful relevance. Other details regarding the attempted infection of chimpanzees are given by Markus et al. (1974).

No oocysts or sporocysts were detected in the faeces of the chimpanzees. A rising antibody titre was observed in one *chimpanzee, which was seronegative for the first 21 weeks after ingesting tissue cysts. In the 23rd week the titre was 1:16 and a week later had risen to 1:64, where it remained for a few weeks before falling to 1:16. The time of seroconversion coincided with the fortuitous finding by Mr. Sherali Thaver of a single "zoite" (about 10 μm in length) in a Giemsa-stained thick blood film. Unfortunately the zoite, not seen by the author but observed by Prof. P. C. C. Garnham, Prof. L. J. Bruce-Chwatt, Dr. C. C. Draper and Miss V. C. L. C. Wilson, was accidentally destroyed. As the time when the seroconversion occurred was not only when the zoite was seen but also when an experimental Plasmodium vivax infection became patent, the cause of the rising titre is not clear. The malaria parasite and Sarcocystis are both Sporozoa and the

*This animal had been given sarcocysts in saline by stomach tube, under anaesthetic administered for splenectomy.

possibility that there was some cross reaction must be considered.

Two muscle biopsies (triceps and latissimus dorsi) were performed 8 months after the feeding of Sarcocystis, i.e. 2 months after the organism was seen in the blood film. No parasites were found in the biopsy material. The zoite may have escaped from a muscle cyst that was punctured when the blood film was prepared from the ear of the chimpanzee. Another possibility is that it came from a ruptured schizont in the wall of a blood vessel. However, there is no proof that the presence of the zoite was the result of the chimpanzee having been fed tissue cysts of Sarcocystis. An autopsy is to be performed on this animal in due course.

A number of authors have reported apparent parasitaemia in Sarcocystis or Toxoplasma infections - e.g. Jacobs and Jones (1950); Jacobs and Hartley, (1964); Miller et al. (1969); Draper et al. (1971); Akoi (1973); Araujo et al., (1973); see Markus (1973a); Šibalić, (1975a, b, c); Wong et al. (1974).

Attempted infection of mice with sporocysts of cattle Sarcocystis from cat faeces

A number of T.O. mice (25 - 30 g) were each fed approximately 2,500 sporocysts of bovine Sarcocystis from cat faeces by stomach tube and were subsequently killed at intervals (Table 10). No schizonts were seen in stained sections of the following tissues, taken at autopsy: heart, skeletal muscle, lung, liver, spleen, brain and kidney. Pieces of intestine were also fixed. Only a small number of sections of intestine were examined (approximately five random sections of the intestine of each mouse). The results were similarly negative.

The bovine sporocysts from cat faeces did not appear to be infective for mice. A description of early asexual stages of Sarcocystis in a different "prey" animal (see "Discussion") will be given here. The description is from Markus et al. (1974) and is of schizonts in kidney of an experimental calf which had been given sporocysts of bovine Sarcocystis from dog faeces by Drs R. Fayer and A. J. Johnson.

Sections of kidney were very kindly sent to Prof. P. C. C. Garnham by Drs Fayer and Johnson. These were stained in Giemsa's stain (Markus et al., 1974). Two types of schizont were seen. One (Fig. 28) had densely stained discrete nuclei, occasionally arranged in a palisade at the periphery (Fig. 29). The schizonts were usually oval and the largest measured 34 x 15 µm. Merozoites in mature forms lay in one plane and were nearly always seen in cross section or cut tangentially (Fig. 29). In one schizont, however, the merozoites were cut in the plane in which they lay. They were then seen to be elongate, measuring 4 x 2 µm, with a single dense nucleus about 2 µm in diameter (Fig. 30). Fayer and Johnson (1973) found up to 50 merozoites in mature schizonts. The schizonts with these very

TABLE 10

Mice each fed approximately 2,500 sporocysts of bovine *Sarcocystis* from cat faeces*

Days elapsed since infection	Number of mice originally infected and subsequently sacrificed	Control mice**
5	2	2
10	2	2
20	2	2
35	2	2
50	2	2
180	2	2

*No schizonts or sarcocysts were found.

**The tissues of the control mice were not examined.

Figures 28-31. Schizonts in the kidney of an experimentally infected calf (x 1,500) (material by courtesy of R. Fayer and A. J. Johnson). Giemsa's stain. This species of Sarcocystis undergoes gametogony and oocyst formation in intestine of the dog. 28. Schizont approaching maturity, with deeply-staining nuclei. 29. Mature schizont with merozoites in transverse section and in palisade formation. 30. Mature schizont showing merozoites in longitudinal section. 31. A second type of schizont with small nuclei; almost mature.

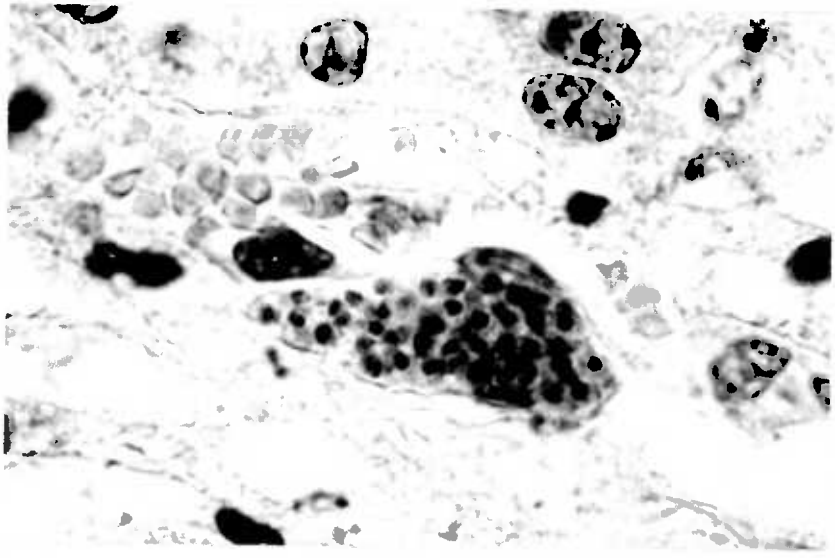

Figure 28

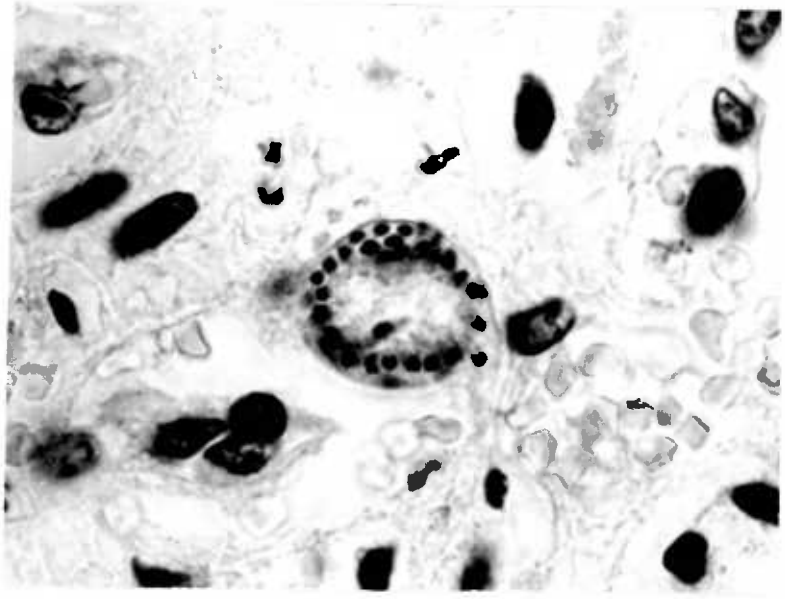

Figure 29

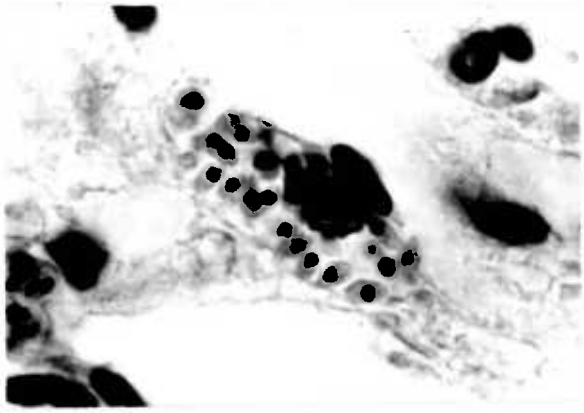

Figure 30

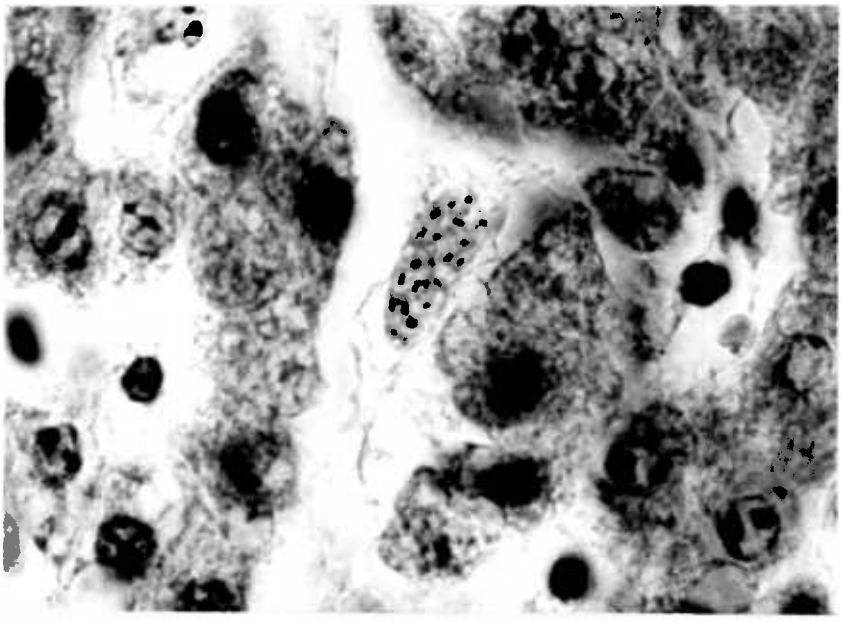

Figure 31

distinctive nuclei were in the tubules as well as in the glomeruli.

The second and less common form was seen only in the tubules. Schizonts of this kind, which perhaps represented an earlier generation, were smaller; the largest one seen measured only 15 x 6 μm. The merozoites of these forms were tiny bodies, measuring about 2 x 1 μm with nuclei about 1 μm in diameter (Fig. 31).

Isospora felis in the mesenteric lymph node of the cat

A search was made for extraintestinal stages in impression smears of mesenteric lymph node, spleen, liver, lung, kidney and brain of a cat sacrificed 54 hours after oral infection with 2¼ million oocysts of Isospora felis. The parasites (Figure 32) were seen only in lymph node, where they were sparsely distributed. These forms have previously been observed by Dubey and Frenkel (1972a).

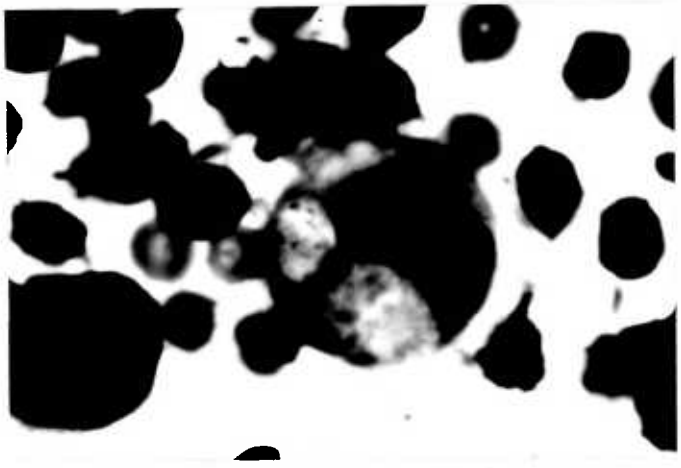

Figure 32. Extraintestinal stage of Isospora felis in impression smear of the mesenteric lymph node of a cat, 54 hours post infection (x 1,600). Giemsa's stain. Note the nucleus of the parasite, in the form of a band at right angles to the nucleus of the host cell.

Isospora felis in normal and immunosuppressed mice and chickens

Groups of normal and immunosuppressed* T.O. mice (30 - 40 g at autopsy) and chickens (two days old when infected) were given oral inocula of Isospora felis oocysts (see page 13). Mice were fed 470,000 or 630,000 oocysts and chicks received 2¼ million oocysts each. For details of the intervals at which mice were sacrificed, see Table 11. Immunosuppressed chicks all became ill and were killed at 48 hours and four days. Normal chicks were examined at 3 and 15 days. Full post mortems were conducted on the mice and chicks. Extraintestinal stages of parasites were studied in impression smears (no parasites were observed in mouse or chick intestines). As organisms tend to occur singly (schizogony apparently does not take place), it is more convenient to examine imprints than sections. Pieces of organs fixed have not yet been sectioned. Four conventionally maintained, coccidia-free kittens were each given 2¼ million I. felis oocysts and were also sacrificed at irregular intervals, to correspond to the times of autopsy of some of the mice.

To find parasites, thorough examination of smears is necessary and at this stage it cannot be said that parasites are probably absent from any particular organ, as the work has not yet been completed. Whether the distribution of parasites in immunosuppressed mice or chicks is the same as in normal ones, has not yet been established. However, I. felis occurs in (apart from the mesenteric lymph nodes) the liver and spleen, at least, of both

---

*Betsolan injection (Glaxo Laboratories, Greenford) was used. Each ml. contained 2 mg. of betamethasone, Most mice and chicks received .1 ml. daily, both before and after infection. For some mice, the dosage given was higher.

TABLE 11

Mice given oocysts of Isospora felis of the cat per os and examined for extraintestinal infection

Time elapsed since infection	Normal	Immunosuppressed with betamethasone	Control mice*
24 hours	2	2	2
48 hours	2	2	2
72 hours	2	2	2
96 hours	2	2	2
5 days	2	2	2
10 days	2	2	2
25 days	2	2	2
1½ months	2	2	2

*Precautions were taken in the caging of experimental and control mice - see page 29.

normal and immunosuppressed mice and chicks (Figures 33 - 37). I. felis has previously been seen in mice only in the mesenteric lymph node (Frenkel and Dubey, 1972a) and has not been observed in other organs (although there was indirect evidence for its occurrence there - Frenkel and Dubey, op. cit.) or in birds.

In earlier infections in the mesenteric lymph nodes of mice (Figure 38), the nuclei of intracellular zoites assumed a variety of shapes (Figures 39 and 40) and the parasites appeared to divide by binary fission (Figure 41). The organisms were broader than the sporozoites ingested (Figure 42) and also unlike the products of schizogony in the gut of cats (Figures 43 and 44). As from a few days post infection, the shapes of the nuclei tended to be more uniform (Figure 45). Cysts containing two* cystozoites were occasionally seen. "Sheathed" I. felis usually appeared to have "shrunk" inside the cyst (Figure 46).

It is not yet certain whether a greater number of parasites develops in immunosuppressed mice (which sometimes appeared to be the case) as the distribution of I. felis in the mesenteric lymph node smears of both normal and immunosuppressed individuals is irregular. This aspect is receiving further consideration, as is the question of possible division of parasites in chronic infections in immunosuppressed mice (Figure 47).

There is considerable variation in the size of parasites, depending on how they are lying in the smear and whether or not they have "shrunk" inside the cyst. The dimensions of 10 cysts in the mesenteric lymph nodes of normal mice 5-25 days post infection were 16.0-23.0 x 7.8-12.6 (average 20.0 x 8.6) µm. These measurements are of cysts that were lying in more or less the same position.

---

*Such cysts, which have not previously been observed, were seen in the mesenteric lymph nodes of both normal and immunosuppressed mice.

Figures 33 and 34. Isospora felis in impression smear of the spleen of a normal mouse, 25 days after oral infection with oocysts (x 1,600). Giemsa's stain.

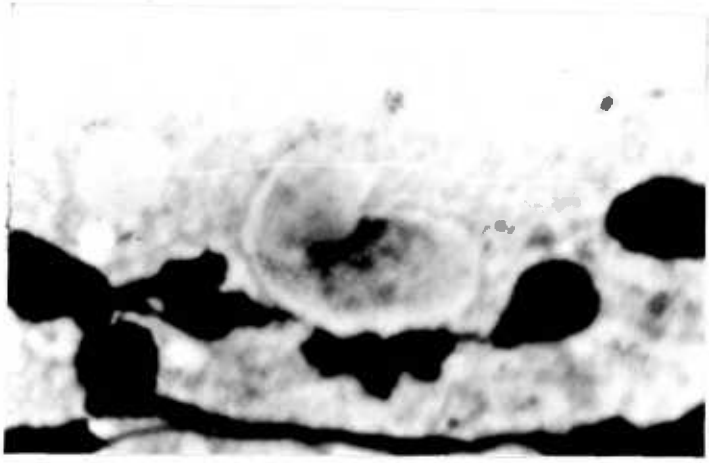

Figure 33

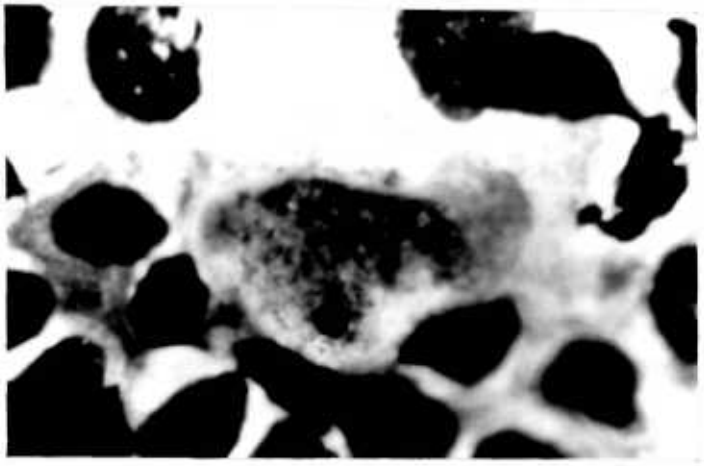

Figure 34

Figures 35 and 36. Isospora felis in impression smear of the liver of an immunosuppressed chick, four days after oral infection with oocysts (X 1,600). Giemsa's stain.

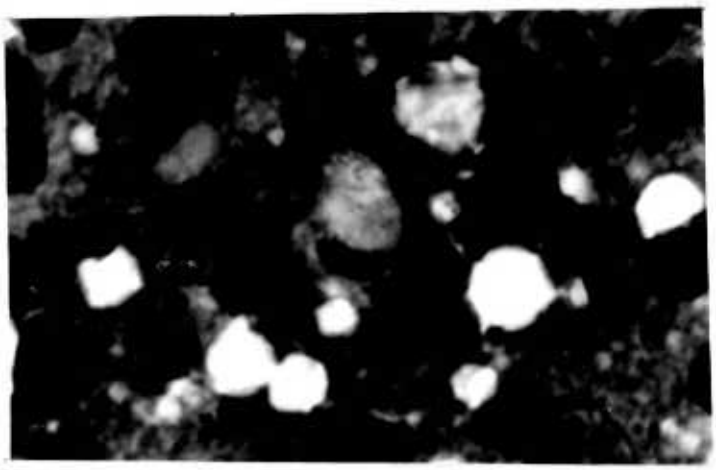

Figure 35

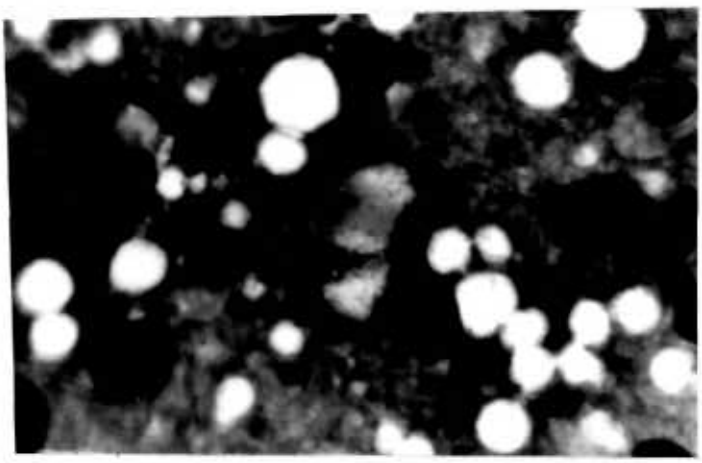

Figure 36

Figure 37. Isospora felis in impression smear of the spleen of a normal chick, 15 days after oral infection with oocysts (x 1,600). Giemsa's stain.

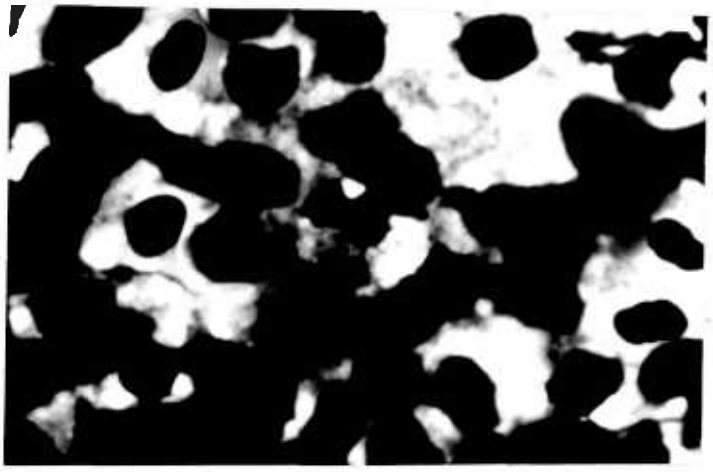

Figure 37

Figure 38. Isospora felis in impression smear of the mesenteric lymph node of an immunosuppressed mouse 48 hours after oral infection with oocysts (x 1,600). Giemsa's stain.

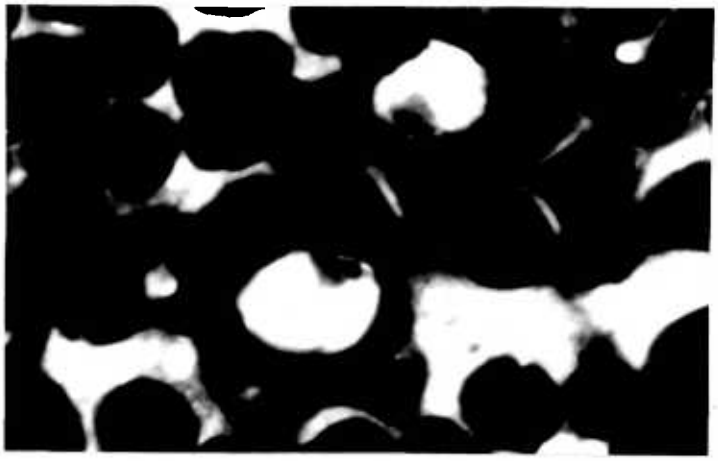

Figure 38

Figures 39 and 40. Isospora felis showing nuclear activity in mesenteric lymph node impression smears from two normal mice, 24 and 72 hours, respectively, after oral infection with oocysts (x 1,600). Giemsa's stain.

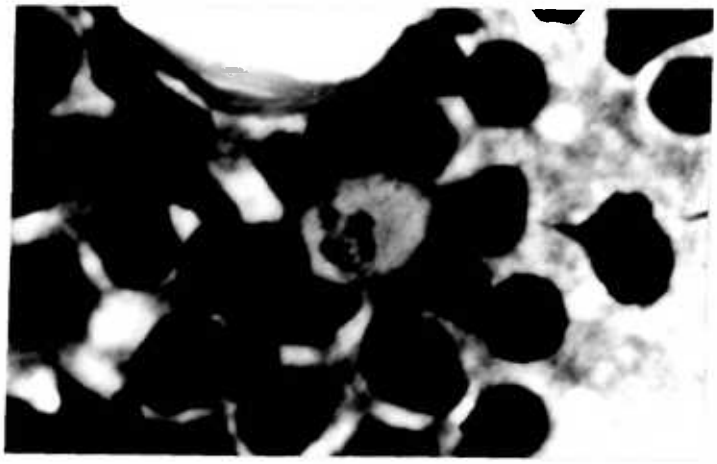

Figure 39

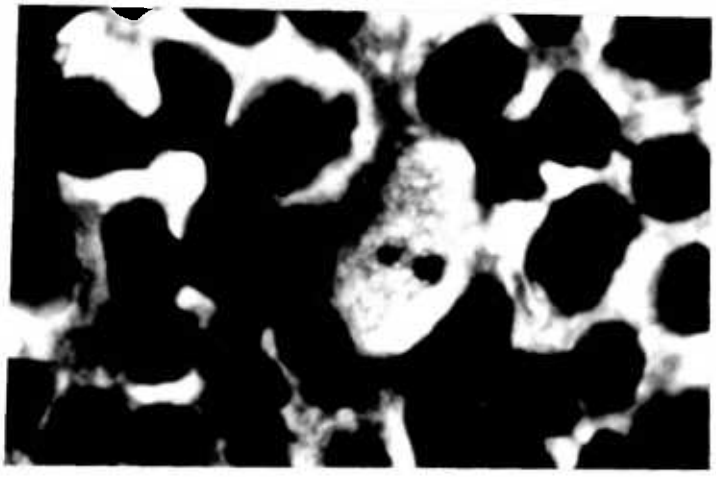

Figure 40

Figure 41. Paired zoites in the mesenteric lymph node of the mouse referred to in the caption for Figure 39 (x 1,600). Giemsa's stain.

Figure 42. Sporozoite of Isospora felis (x 1,600). Giemsa's stain.

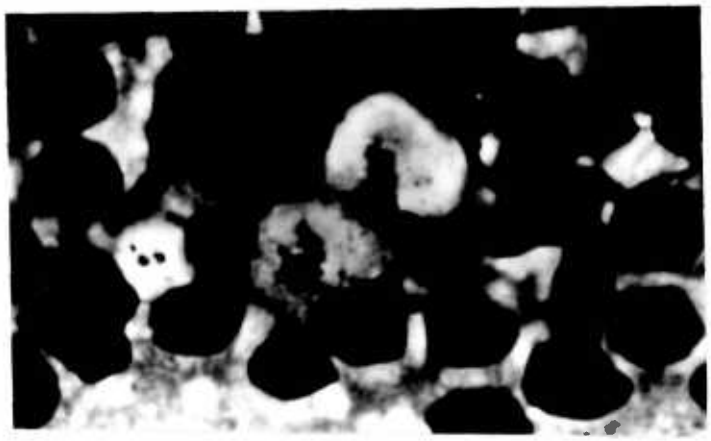

Figure 41

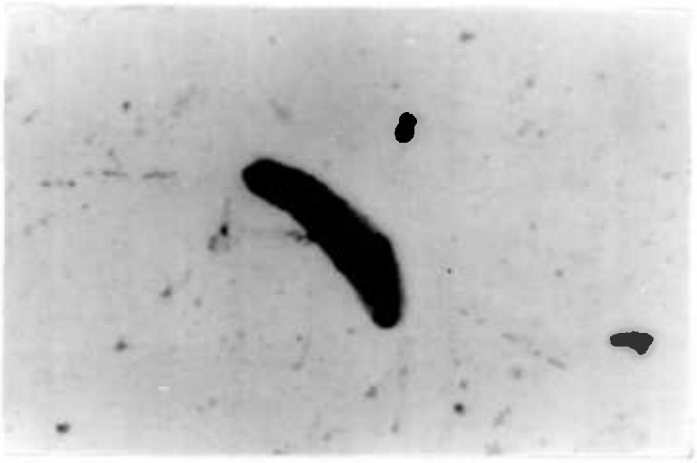

Figure 42

Figures 43 and 44. First generation Isospora felis merozoites in a smear from the intestine of a kitten, four days after oral infection with oocysts (x 1,600). Giemsa's stain. The one end of this stage did not stain with Giemsa.

Figure 45. Group of three Isospora felis in impression smear of the mesenteric lymph node of a normal mouse, 25 days after oral infection with oocysts (x 1,600). Giemsa's stain.

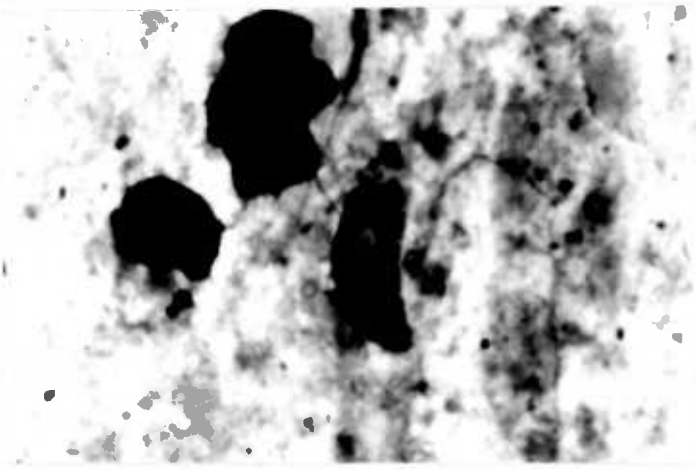

Figure 43

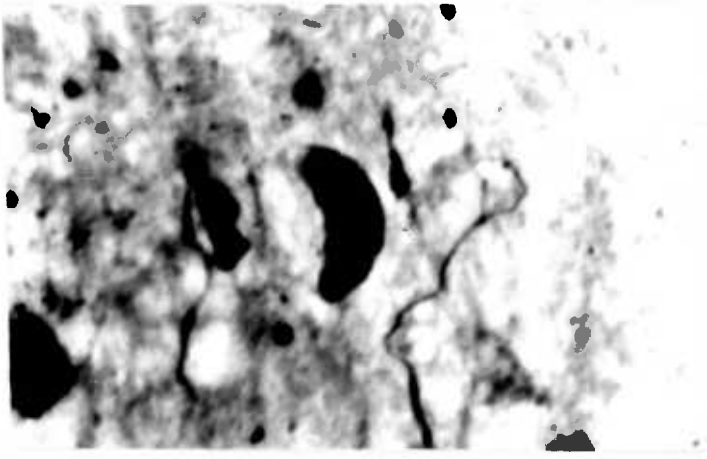

Figure 44

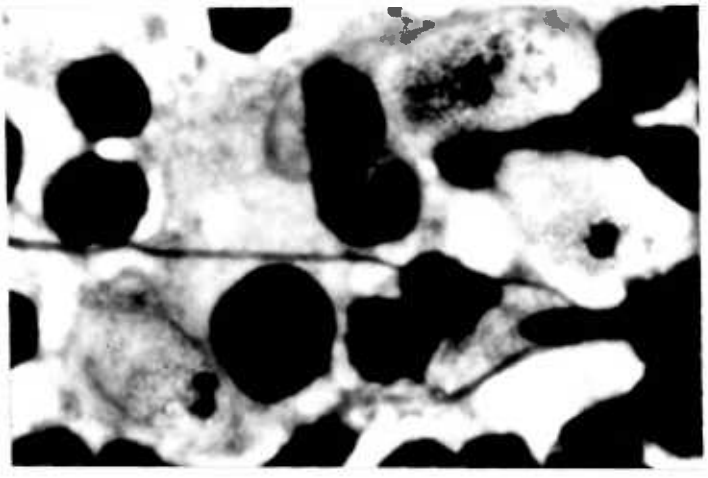

Figure 45

Figure 46. Isospora felis in impression smear of the mesenteric lymph node of an immunosuppressed mouse, four days after oral infection with oocysts (x 1,600). Giemsa's stain.

Figure 47. Paired zoites of Isospora felis in impression smear of the mesenteric lymph node of an immunosuppressed mouse*, 28 days after oral infection with oocysts (x 1,600). Giemsa's stain.

*This mouse was not one of those referred to in Table 11 but was infected in a separate experiment.

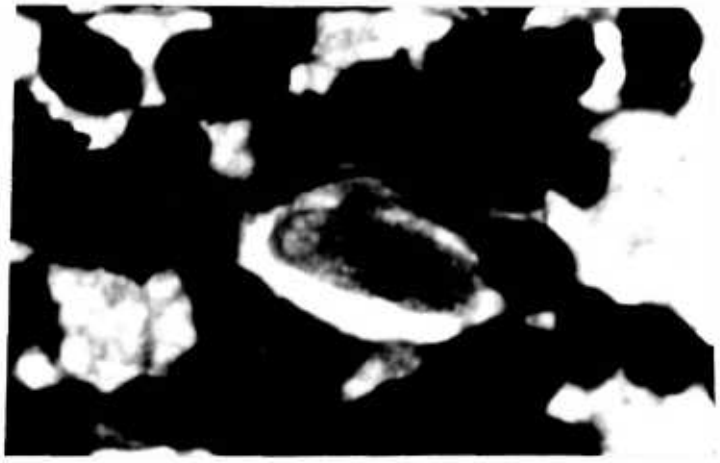

Figure 46

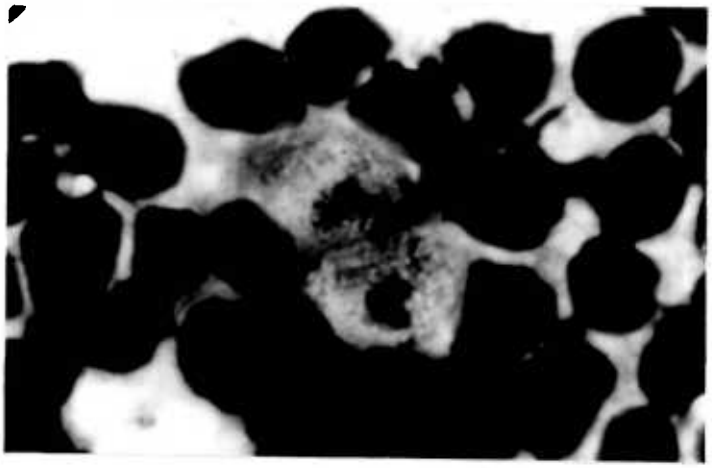

Figure 47

DISCUSSION

Susceptibility of different hosts to intestinal infection with cattle Sarcocystis

The absence of oocysts in the faeces of the experimental chimpanzees was puzzling. Sporocysts similar to those of I. hominis have been recorded from a young chimpanzee which was examined after 6 months in captivity (Rijpstra, 1967), but the source of infection was not determined. In nature, chimpanzees sometimes eat meat (Teleki, 1973). On present evidence it seems that the sarcocysts in the meat were not infective for chimpanzees because these animals were the "wrong" host (see pages 105-109).

A number of other reasons for the failure of the chimpanzees to become infected were considered, and most rejected, e.g.:-

1. Viability of cystozoites affected by milk. This appears, however, to have a protective effect (de Roever-Bonnet, 1972; Saari and Räisänen, 1974). A milk diet in mice, on the other hand, appears to confer some resistance to Toxoplasma infection (Lai et al., 1975). As mentioned on page 11, milk was included in the diet of the chimpanzees.

2. Resistance to infection (immunity): two chimpanzees had an apparent preinfection titre to Sarcocystis in the indirect fluorescent antibody test of 1:64. A third had a titre of 1:16. The serum of the fourth animal was negative.

3. Cystozoites not viable. Sarcocystis and Toxoplasma survive low temperatures and high temperatures initially (see "Historical Review"; Jacobs et al., 1960; Dubey, 1974) and the time that had elapsed between obtaining the meat and the feeding of sarcocysts to the chimpanzees would not have affected the viability of the organisms.

Life-cycle of *Sarcocystis*

The significance of carnivorism in the transmission of *Sarcocystis* is now becoming clear. The life-cycle involves two vertebrate hosts: the "prey" (e.g. ungulates, rodents, birds, etc.) and a "predator" (e.g. man, dog, cat, weasel, cheetah, snake, etc.) with asexual multiplication usually taking place in the prey and sexual reproduction of the parasite restricted to the predator (see Figure 48). There is a precedent in the Eimeriina for such a situation, i.e. an alternation of generations in different hosts. Thus, in the genus *Aggregata*, schizogony occurs in one host (crab) and the sexual cycle in another (cuttle fish) - Dobell (1925). Baboons and probably some monkeys, which are frequently omnivorous and in which sarcocysts occur (e.g. Mandour, 1969; Terrell and Stookey, 1972; McConnell *et al.*, 1973, 1974; Prathap, 1973) sometimes play the part of predator and at other times that of prey. The same situation must have occurred in early man.

A tentative life-cycle of *Sarcocystis* is depicted in Figure 48. In summary, sporocysts (D), passed in the faeces of the "predator" (man, dog, cat, weasel, cheetah, snake, etc.), are ingested by the "prey" (ungulates, rodents, birds, etc.) and their sporozoites initiate an asexual multiplication (E) in, primarily, reticulo-endothelial cells (usually endotheial cells of blood vessels) in almost all tissues. In muscle, merozoites eventually give rise to the well-known sarcocysts (A), containing many thousands of cystozoites (B). There are, however, several reports of sarcocysts in the brains of cattle and sheep (Bigalke and Tustin, 1960; Hilgenfeld and Punke, 1974; Luengo *et al.*, 1974; Munday *et al.*, 1975). Available evidence suggests that when the muscle is eaten by the predator, the cystozoites penetrate the intestine and develop (C) into macro and microgametocytes underneath the epithelium. Apparently there is no schizogony immediately preceding gametogony in the gut of the predator.

Oocysts sporulate *in situ*. After sporulation they contain two sporocysts, each with four sporozoites and are thus of the "isosporan" type. The oocysts progressively escape into the lumen of the intestine and are shed in the faeces, usually as free sporocysts.

Sporocysts in faeces of predator

The sporocysts of *Sarcocystis* differ from those of other cyst-forming coccidia of, for example, cats (*I. felis*, *I. rivolta*, *Toxoplasma*, *Hammondia* and *Besnoitia*), in that (1) they are usually shed singly (Figure 19) and not within the oocyst; (2) they are usually fully sporulated on being excreted; and (3) the patent period is markedly longer than that of other coccidia (with the exception of *Frenkelia*, a final host of which is the buzzard *Buteo buteo* - Rommel and Krampitz, 1975). Histological evidence indicates that *Sarcocystis* typically develops beneath* the intestinal epithelium (*vide antea*) and the retention of oocysts subepithelially in the gut wall would explain the persistence of sporocysts in the faeces.

A consequence of the subepithelial development of *Sarcocystis* is that it is frequently not possible to diagnose chronic intestinal infections by examining faeces (Markus, 1972). *I. canis* of the dog developes immediately underneath the intestinal epithelium (Lepp and Todd, 1974) and *I. rivolta* of the dog predominantly subepithelially (Mahrt, 1967). These large parasites do not often occur deep in the lamina propria and presumably they break out of the villi relatively easily, e.g. during renewal of the intestinal epithelium (Markus, 1972).

The importance of a two-host cycle in the life-cycles of some of the

---

* Frenkel (1974) incorrectly gave the site of development of *Sarcocystis* in his review as the intestinal epithelium.

Figure 48. Life-cycle of Sarcocystis. Tissue cysts (A) containing cystozoites (B) are ingested by the predator. The cystozoites grow directly to sexual stages (C) in the intestine of the predator - (the parasites in diagram C have been enlarged in relation to the epithelial cells). Oocysts sporulate in situ in the subepithelial tissue and are released into the lumen of the gut; forms in the faeces are mainly free sporocysts (D) which have broken out of the fragile oocysts. When ingested by the prey, the sporozoites from sporocysts initiate one or more cycles of asexual multiplication (E) in, mainly, reticulo-endothelial cells of most tissues. Merozoites of schizonts give rise to the tissue cysts in muscle. (Different stages not drawn to scale).

(Diagram from Markus et al., J. trop. Med. Hyg. 77: 248-259, 1974).

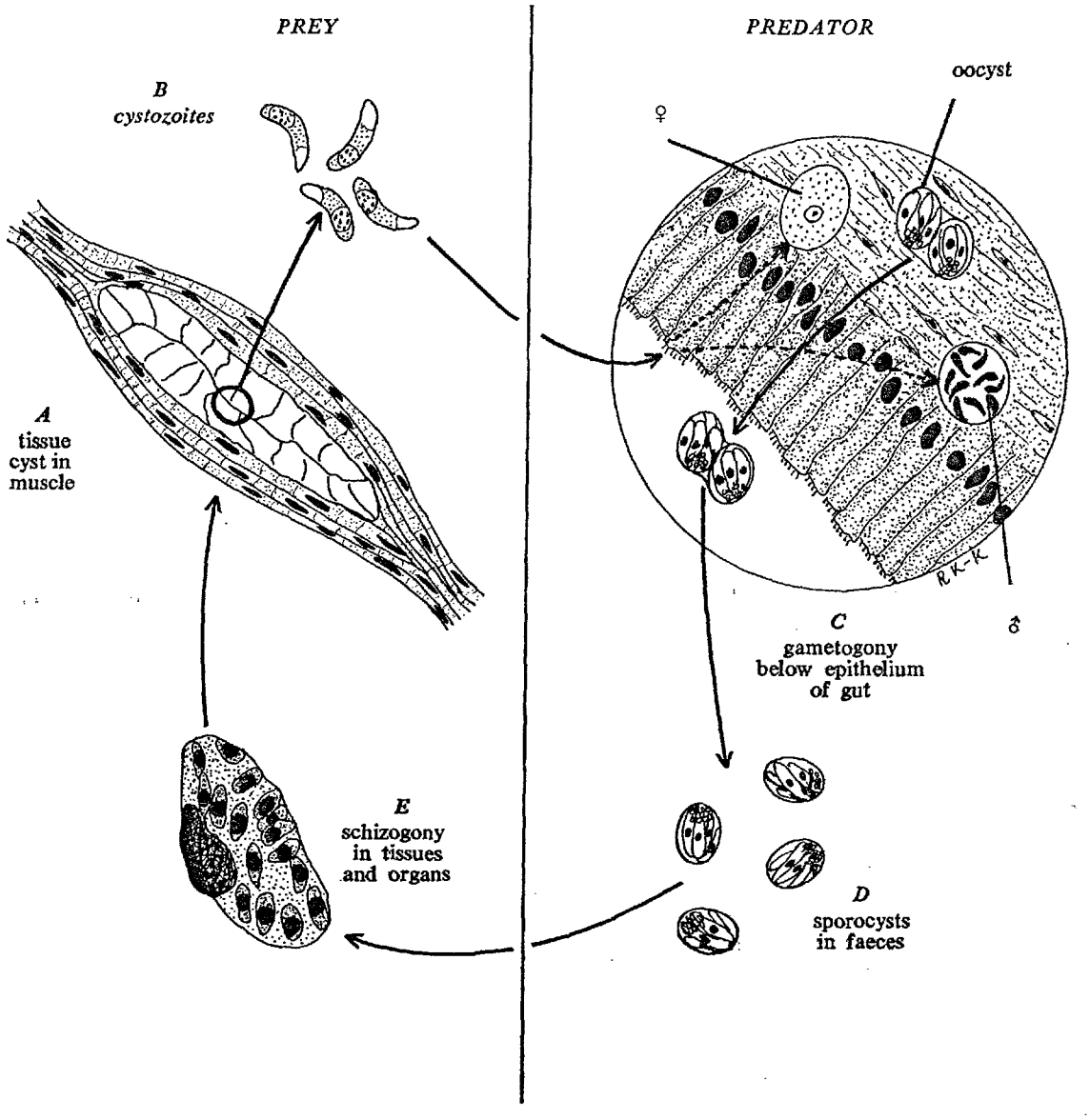
PREY
PREDATOR
B
cystozoites
oocyst
♀
A
tissue
cyst in
muscle
C
gametogony
below epithelium
of gut
♂
E
schizogony
in tissues
and organs
D
sporocysts
in faeces

Figure 48

smaller isosporan coccidia has become apparent. Whereas ingestion by the predator of the tissue cyst stage of Sarcocystis, Hammondia and Besnoitia is regularly followed by oocyst formation, the oocyst stage fails to produce the complete oocyst-to-oocyst cycle in the predator (Heydorn, 1973; Rommel and Heydorn, 1973; Fayer, 1974a; Rommel et al., 1974; Frenkel and Dubey, 1975a, b; Wallace, 1975). In this respect the oocyst of T. gondii is also much less "efficient" than the tissue cyst (Dubey et al., 1970a; Wallace, 1973b). Thus, the full life-cycle of these organisms in naturally infected predators appears to be dependent on the predator ingesting tissue cysts in raw flesh. In contrast to this situation, the ingestion of even a single infective oocyst of I. felis by a non-immune cat is sufficient to result in schizogony, gametogony and oocyst formation; and the same is true of other large isosporan coccidia of cats and dogs of which the life-cycle has been studied. There are also a number of published records of direct man-to-man transmission of I. belli, one of the most recent being that of McCracken (1970).

The faecal stage of Frenkelia glareoli* of the bank vole Clethrionomys

---

* Rommel and Krampitz (1975) do not refer in their paper to F. glareoli but describe a new species of Frenkelia from the bank vole Clethrionomys glareolus, viz. F. clethrionomyobuteonis. Whilst the authors' motives in describing the new species seem to be sound, Frenkelia glareoli (Erhardová, 1955) has priority - see Biocca (1968). At this time the validity of the name Frenkelia clethrionomyobuteonis Rommel and Krampitz, 1975 is in doubt and it must be relegated to synonymy with F. glareoli.

A name proposed (formal description not yet published) for a species of Sarcocystis having "macroscopically visible" sarcocysts in sheep and of which the cat is the final host is (unfortunately) given in this paper. (The parasite concerned is currently known as Sarcocystis tenella). In making reference to the new name (see Rommel and Krampitz, op. cit.), the authors have not met any of the three conditions of Article 13(a) of the International Code of Zoological Nomenclature (International Commission on Zoological Nomenclature, 1964) which would prevent the new name from becoming a nomen nudum. Preliminary study of the relevant literature reveals that if this life-cycle is indeed that of a single species of Sarcocystis, there may be at least one available name for the taxon which is not a nomen dubium, viz. Sarcocystis gigantea (Railliet, 1886), originally described as Balbiania gigantea.

glareolus in the buzzard Buteo buteo is indistinguishable from that of Sarcocystis and it has been inferred that Frenkelia and Sarcocystis may prove to be congeneric (Rommel and Krampitz, 1975). These authors concluded from their experimental observations that "the sporocysts of Isospora buteonis of Buteo buteo are developmental stages of Frenkelia sp. of Clethrionomys glareolus". It should not, however, be assumed that the free sporocysts of I. buteonis Henry, 1932 shed by B. buteo and other raptors are a part of the life-cycle of Frenkelia only. Predatory birds other than the buzzard pass I. buteonis in their faeces (e.g. Henry, 1932; Nieschulz, 1935; Scholtyseck, 1954). Some of these species of birds failed to develop a patent infection after being fed vole brains containing F. glareoli (Rommel and Krampitz, op. cit.).

Rodent-snake Sarcocystis cycles exist (Rzepczyk, 1974) and there may be rodent-bird cycles as well. One evolutionary implication of a long patent period of Sarcocystis in a migratory bird of prey (that of Frenkelia in the buzzard was 7-57 days) might be that species of Sarcocystis have become established in unrelated rodents forming the bird's prey in different areas or zoogeographical regions. For example, B. buteo from parts of Europe migrates annually in large numbers right down to the southern tip of Africa (Elliott and Jarvis, 1970, 1972/3). Places in Africa where the species is abundant (e.g. Benson et al., 1971) include parts where rodent Sarcocystis is known to occur (e.g. Mandour, 1972b).

Other parasite adaptations resulting from predator-prey relationships between hosts are indicated by taeniid cestodes, larvae of some of which occur in rodents, whilst the adults live in carnivores and birds of prey. To choose an example that fits in with the Clethrionomys/Buteo/Frenkelia association: the larva of Cladotaenia globifera occurs in the liver of C. glareolus and the adult in the small intestine of B. buteo (see Murai and

Tenora, 1973).

The weasel Mustela nivalis was found by Tadros and Laarman (1975a, b) to be the final host of Sarcocystis of the common European vole Microtus arvalis. Again, by analogy with other tapeworm adaptations (Murai and Tenora, op. cit.), one might predict that M. nivalis will prove not to be the only final host of Sarcocystis of M. arvalis. Likewise, M. nivalis is probably also the final host of Sarcocystis spp. of other rodents.

Asexual multiplication in tissues of prey

The fact that schizogony has been found to be still in progress more than a month post infection, suggests to the writer that at least two cycles of asexual multiplication take place after ingestion of sporocysts. More than one type of schizont has been seen in cattle (Markus et al., 1974) and sheep (Munday et al., 1975). Sporozoite-initiated intestinal infections of I. felis of the cat (Shah, 1971), I. rivolta of the dog (Mahrt, 1967), I. canis of the dog (Lepp and Todd, 1974) and probably I. belli of man (Brandborg et al., 1970; Asami and Shinkichi, 1974) also comprise more than one schizogonic cycle.

Absence of asexual intestinal stages

Schizonts were not observed in the intestines of cats or dogs fed tissue cysts of Sarcocystis, although most of the animals were not sacrificed very early in the infection (Heydorn and Rommel, 1972a, b; Vershinin, 1973; Fayer, 1974a; Mehlhorn and Scholtyseck, 1974b; Munday et al., 1975; present study). Cystozoites of an avian Sarcocystis species also underwent no schizogony in tissue culture (Fayer, 1972a). Furthermore, asexual reproduction has not been seen in the host's gut in the case of other coccidia which, judging from the nature of the oocysts and sporocysts,

will probably prove to be stages in the life-cycle of Sarcocystis spp., e.g. I. tropicalis of the jackal Canis aureus (Mukherjea and Krassner, 1965) and I. papionis of the chacma baboon Papio ursinus (McConnell et al., 1971). Possible reasons why asexual stages of Sarcocystis have not been located in the intestine of animals which have ingested tissue cysts, are that (1) asexual intestinal stages are absent, ephemeral or difficult to see; or (2) schizogony does take place, but in an extra-intestinal location, with subsequent reinvasion of the gut (cf. Box, 1975b). Support for the view that schizogony between cystozoite and gamete does not occur in the animal in the fact that it was not seen in tissue culture (Fayer, 1972a).

Various multiplicative stages of the related Toxoplasma are found in the intestine of cats which have been fed cysts in mouse tissues (Hutchison et al., 1971; Dubey and Frenkel, 1972b; Frenkel, 1973b). These asexual stages divide by schizogony, endodyogeny, endopolygeny and "splitting", either alone or in combination (Frenkel op. cit.). The details of the cycle in the gut of felines is still not fully understood. Galuzo et al. (1973) postulated that some cystozoites of Toxoplasma give rise directly to sexual stages in cats. This would be analogous to what appears to be the situation in the life-cycle of Sarcocystis.

Causative organisms of Dalmeny disease and other unidentified Sporozoa

The remarkable outbreak of the so-called Dalmeny disease in Canadian cattle (Corner et al., 1963) may have been caused by schizogony of Sarcocystis in the organs. Ten out of 17 pregnant cows aborted and out of 25 cattle affected, five died and 12 were killed when moribund. An unidentified protozoon was seen in the endothelial cells of the blood

vessels of many tissues in 11 out of 16 animals examined histologically. Toxoplasma, to which the parasites bore some resemblance, was excluded by serological tests. From the description of Corner et al. (1963), the parasites of the Canadian cattle appeared to be indistinguishable from experimentally produced schizonts of Sarcocystis in calves (see Markus et al., 1974). Notable similarities were in (1) size and general appearance, (2) the size and occasional palisade formation of the nuclei, (3) the wide range of tissues infected and (4) the type of cell invaded. As with experimental calves (see "Historical Review"), heavy infections - possibly acquired by the accidental ingestion of large numbers of sporocysts contaminating the stable - were sometimes fatal.

Lainson (1972) described a similarly unidentified parasite in the liver and lungs of a bovine in Leicestershire, England, and recognised a strong resemblance to the parasite of Dalmeny disease. This animal, a bull calf (mistakenly referred to by Lainson, op. cit. as a heifer calf) was thought to have died from a deficiency of copper and magnesium (F. G. Clegg, personal communication to the author) - not manganese as stated by Lainson (op. cit.). Unstained sections of this case were stained by Markus et al. (1974) and the parasites (Figures 49 and 50) were compared with those in sections of kidney of experimental calves provided by Drs. R. Fayer and A. J. Johnson. In the material from the Leicestershire calf, the schizonts are a little smaller than in the experimentally infected tissue, but in other respects, such as the prominent nuclei occasionally in palisade formation, they again resemble the schizonts of Sarcocystis. Mononuclear organisms similar to those described by Fayer and Johnson (1974) are present in the lung sections.

Lainson (1972) discussed another unidentified protozoon in the brain, liver and spleen of an armadillo in British Honduras (Belize), which again

Figures 49 and 50. Schizonts of unidentified protozoon (? Sarcocystis sp.) in the liver of a bull calf in England (x 1,500). Giemsa's stain.

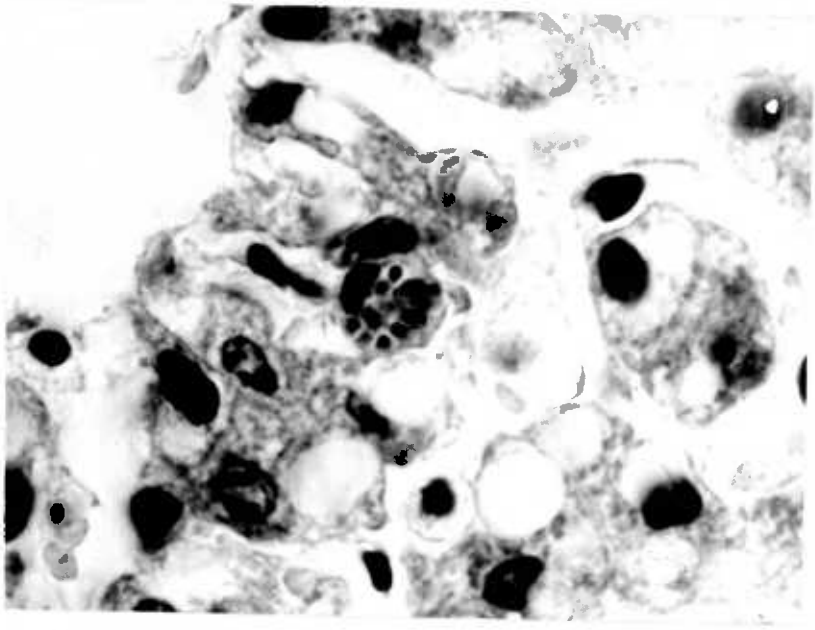

Figure 49

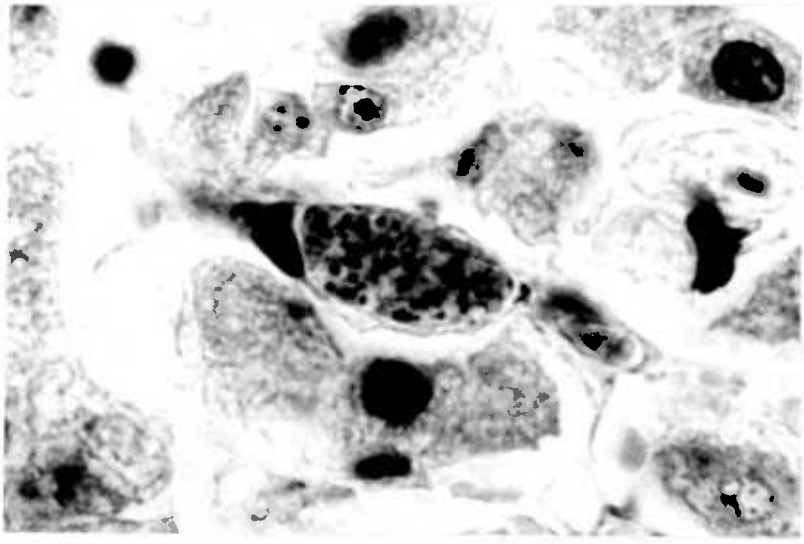

Figure 50

bore some resemblance to the then unknown proliferative stages of Sarcocystis. Lainson found no parasites in impression smears of lung of the armadillo. A few species of coccidia are known, though imperfectly, from armadillos (see Lainson, op. cit.). Although there appear to be no published records from this host in Belize or elsewhere, muscle cysts of Sarcocystis have been found in armadillos in Pará State (Lainson, personal communication to R. Killick-Kendrick - see Markus et al., 1974) and Bahia State (Howells, personal communication to the author) in Brazil. The unidentified protozoon in the armadillo may have been Sarcocystis.

Mandour and Keymer (1972) described a protozoon of uncertain identity in a swamp rat Otomys kempi, collected in Zambia. Asexual stages were observed which resembled schizonts of Sarcocystis. The heart was the most heavily infected organ. Whilst the diaphragm, spleen, lungs and connective tissue (situated between layers of skeletal muscle and between the spleen and pancreas) were also parasitized, no stages were seen in the blood, liver, pancreas, kidney or adrenal glands.

Unidentified Toxoplasma - like sporozoan parasites have been responsible for additional documented cases of encephalomyelitis and disease showing other symptoms in large and small domestic animals (Beech and Dodd, 1974; Dubey et al., 1974; Hartley and Blakemore, 1974; McErlean, 1974; Neufeld and Brandt, 1974). The diseases in sheep (Hartley and Blakemore, op. cit.; McErlean, op. cit.) had certain features in common with experimental Sarcocystis infections in lambs (Munday et al., 1975). Lesions and organisms in a cat (Neufeld and Brandt, op. cit.) resembled some that have been seen in feline Toxoplasma infections (Dubey and Frenkel, 1974). Some of the other unidentified parasites may have been little-known coccidia like Hammondia.

Unidentified schizonts and sexual stages in subcutaneous tissues of a dog were clearly those of a coccidium (Shelton et al., 1968). Records of Hepatozoon-like schizonts in other carnivores and in which no stages were observed in the peripheral blood (see Klopfer et al., 1973), need to be re-examined, to see whether some of the parasites could have been Sarcocystis. Mature sarcocysts have *apparently been recorded in the hearts of captive lions (Bhatavdekar and Purohit, 1963). However, as discussed in the following section, muscle cysts of Sarcocystis are not often found in carnivores.

Coccidiosis is conventionally thought of as an infection of the intestine. However, even some species of Eimeria, as in the case of Sarcocystis, undergo extra-intestinal schizogony (and gametogony) (see McCully et al., 1970; Lainson, 1972), and extra-intestinal forms of I. felis and I. rivolta of the cat and the "small race" of I. bigemina of the dog are known (Dubey and Frenkel, 1972a; Heydorn, 1973; present study). Extra-intestinal stages of these three isosporan species and of I. rivolta and I. canis of the dog (Heydorn, 1973; Dubey, 1975; Markus, 1975; present study) have been shown experimentally to develop in hosts other than the "final" host, and the fact that extra-intestinal stages of some isosporan coccidia have yet to be studied in detail makes it difficult to identify fortuitously encountered, sporozoon-like parasites in the organs of man or animals with natural infections (e.g. Archibald and Susu, 1924; Zlotnick, 1955; Dissanaike and Poopalachelvam, 1975). Some species of Isospora in

---

* The cystozoites measured about 12.3 x 2.4 μm. The identity of the parasite remains in doubt, however, as "typical sarcocysts" were reported to develop in mice four to seven weeks after they had been fed infected muscle or following the intramuscular injection of cystozoites.

birds are also thought not to be limited to the intestine (Box, 1973, 1975a, b).

Dissanaike and Poopalachelvam's (1975) parasite was described from the spleen of an insectivore. Attention is drawn to the fact that unidentified organisms were seen in man in two cases of splenomegaly (Archibald and Susu, 1924; Zlotnick, 1955). In 1974, the present author was shown a colour photomicrograph of a stained blood film (from a child), submitted to the London School of Hygiene and Tropical Medicine for an opinion by Dr. K. B. Rogers, Consultant Microbiologist at the Childrens' Hospital, Ladywood, Middleway, Ladywood, Birmingham. There was a group of eight zoites, resembling "Octoplasma garnhami" described by Dissanaike and Poopalachelvam (op. cit.) in that the nuclei were centrally placed. The organisms did not appear to be intracellular and one possibility is that they came from a schizont, ruptured during preparation of the smear.

Asexual multiplication in carnivores

Tissue cysts of Sarcocystis are very rarely found in carnivores such as the dog and cat, yet they are often present in the musculature of animals which are primarily herbivorous. A possible explanation is that asexual multiplication normally takes place in the prey. It may be noted that sporozoites in cattle sporocysts from dogs excysted in the presence of bovine bile but not canine bile (Fayer and Leek, 1973). If this behaviour is constant and applies also to other species of Sarcocystis and to the bile of other carnivores, it could be an adaptation to the two-host life-cycle; and may explain why muscle cysts are so rarely seen in predators. Occasionally, however, sarcocysts are encountered in a predator, e.g. "S. lindemanni" in man (Mandour, 1965b; Jeffrey, 1974), parasites which may well prove to be the same as one or more species of Sarcocystis occurring in domestic animals. It is possible that tissue cysts are formed in a

predator as a result of asexual multiplication after the accidental ingestion (or perhaps inhalation - see El-Kasaby and Sykes, 1972, 1973a, b) of oocysts or sporocysts. The sporocysts most readily available to modern man would probably be those derived from an intestinal infection in the same individual.

Markus (1975) raised the matter of the zoonotic potential of the five described genera of isosporan cyst-forming coccidia related to Toxoplasma. Reference will be made here to Hammondia as this genus was considered by Frenkel (1974) and Frenkel and Dubey (1975a, b) to belong to the family Sarcocystidae - although as discussed below, there are grounds for placing it in the Toxoplasmatidae. Like Sarcocystis, which is occasionally found extraintestinally in human tissues (Mandour, 1965b; Jeffrey, 1974), Hammondia has an obligatory two-host life-cycle and may show a similar ability to multiply asexually in man. Frenkel recently mentioned having seen cysts in man "morphologically compatible" with those of Hammondia (Frenkel and Dubey, 1975b). The cyst-forming protozoon Toxoplasma (Nakayama, 1974; Shimada et al., 1974), which can be subinoculated and can give rise to extraintestinal infections if ingested in raw meat, is being recognised with increasing frequency as a lethal pathogen in persons receiving immunosuppressive therapy and/or with severe underlying disease (see Markus, 1975). Hammondia and Sarcocystis cannot be subinoculated from one to another host animal and perhaps, therefore, chronic Hammondia and Sarcocystis infections do not have the same propensity as those of Toxoplasma for relapsing. Nevertheless, some infections with the former organisms might be harmful in the *acute phase in the immunologically

---

* Immunodeficiency in Toxoplasma infections can result in (1) a persisting primary infection; or (2) recrudescent toxoplasmosis, which is relapse of a chronic infection.

compromised patient. Frenkel and Dubey (1975a) found that in immunosuppressed mice fed Hammondia oocysts, there were a greater number of organisms in the initial infection, with a concomitant increase in the number of cysts subsequently formed. However, man would not normally ingest oocysts of Hammondia or sporocysts of Sarcocystis in the large numbers that cause morbidity and fatalities in experimental animals or in animals living under natural conditions (Corner et al., 1963; Frenkel, 1974; Frenkel and Dubey, 1975a, b; Gestrich et al., 1975; Johnson et al., 1975; Munday et al., 1975; Wallace, 1975).

Schizogony and gametogony in the same host

African baboons Papio spp. serve as examples of animals which are both prey and predator. Isospora papionis was originally described from the intestine of the chacma baboon Papio ursinus* in South Africa by McConnell et al. (1971). Its morphological features and location in the intestine suggest to the present author that it is almost certainly the oocyst of Sarcocystis, tissue cysts of which have been seen in the skeletal musculature and, occasionally, heart of no less than 47 out of 100 baboons (McConnell et al., 1973, 1974). Whether these tissue cysts are stages of the same species of Sarcocystis described as I. papionis, remains to be determined. Muscles of baboons in East Africa are also infected with Sarcocystis (Kim et al., 1968). It has recently been discovered that baboons frequently eat hares, small antelope and the neonatal young of larger antelope, even in areas where plant foods are readily available (Stoltz and Saayman, 1970;

---

* Considered a subspecies of P. cynocephalus by some authors (see McConnell et al., 1974).

Harding, 1973; Strum, 1975). Cannabalism amongst baboons has also been observed (Saayman, 1971). Intestinal infections of I. papionis were detected in three of the 100 baboons examined (McConnell et al., 1974) and "Isospora sp." was seen in a faecal sample from a baboon in Kenya (Kuntz and Moore, 1973). Direct oocyst-to-oocyst transmission of Sarcocystis has not yet been experimentally demonstrated. Thus it is uncertain whether such intestinal infection can occur in the baboon following the ingestion of sporocysts or whether gametogony and oocyst formation only take place in the intestine after the infected flesh of some animal has been eaten. The prevalence of Sarcocystis in the musculature of some of the prey animals eaten by baboons is known to be high (Mugera, 1968; Mandour and Keymer, 1970; Kaliner et al., 1971, 1974; Knottenbelt, 1974; Kaliner, 1975). Meat-eating by baboons is predominantly an adult male activity (Stoltz and Saayman, op. cit.; Harding, op. cit.; Strum, op. cit.) and it should be noted that all six baboons having oocysts in the intestine (or in skeletal muscle - see below) were adult males (McConnell et al., 1974). However, it would be unwise to attempt to draw conclusions on the basis of this small sample. In view of the prevalence of tissue cysts in the baboon, the role of this animal in the epidemiology of Sarcocystis infections would seem to be primarily that of a prey species.

Sporulating and fully sporulated oocysts of I. papionis were seen in the skeletal muscle of three of the 100 baboons examined (McConnell et al., 1972, 1974). Sporocysts may have been ingested both by the 47 baboons having tissue cysts of Sarcocystis and by the three with oocysts in striated muscle (gametes and oocysts were also detected in the intestine of one of them), giving rise to asexual multiplication in the tissues, with subsequent gametogony and oocyst formation (perhaps "accidental") in an extra-intestinal location.

Transplacental transmission

There are scattered references to *Sarcocystis* infections believed to have been acquired *in utero* (e.g. in a foal - Cunningham, 1973). However, in sheep congenital sarcosporidiosis is thought to be rare (Munday and Corbould, 1974).

Transplacental infection of man and animals with the related *T. gondii* is a well-known phenomenon and can be a cause of abortion (e.g. Beverley and Watson, 1961; Harding *et al.*, 1961; Jacobs and Hartley, 1964; Beverley and Watson, 1971; Watson and Beverley, 1971; Munday, 1972b; Sharman *et al.*, 1972; Uhlíková and Hübner, 1973; Desmonts and Couvreur, 1974; Hartley and Moyle, 1974; Hartley and Bridge, 1975). Although abortion caused by *Toxoplasma* has generally been thought to be the result of the mother suffering an acute infection during pregnancy, in animals and man there is also evidence of a correlation between recently acquired latent maternal toxoplasmosis and a poor obstetric history (e.g. Sharf *et al.*, 1973).

Bovine abortions occurred in Dalmeny disease (Corner *et al.*, 1973), the causative organism of which is thought to have been *Sarcocystis* (Markus *et al.*, 1974). In view of this, the close relationship of *Sarcocystis* to *Toxoplasma* and the high prevalence of sarcosporidiosis in cattle and sheep, the possible role of *Sarcocystis* as a cause of abortion in domestic animals needs to be investigated.

Systematic relationship of *Sarcocystis* to *Hammondia*, *Besnoitia*, *Frenkelia* and *Toxoplasma*

Frenkel (1974) and Frenkel and Dubey (1975a, b) placed *Hammondia hammondi* (which has a cat-mouse cycle) in the family Sarcocystidae on the grounds that this genus is closely related to *Sarcocystis* because of the obligatory* two-host life-cycle of *Hammondia* and the fact that cysts occurred predominantly in muscle, with relatively few cysts in the brains of mice. It might equally be argued, however, that *Hammondia* is closely related to *Toxoplasma* (Table 12). The tissue cysts of *H. hammondi* are *Toxoplasma*-like in several details and unlike those of *Sarcocystis*. They contain "slender" *Toxoplasma*-like cystozoites. *Hammondia* also has other features in common with *Toxoplasma* that are not shared with *Sarcocystis* (see Table 12): the oocysts of *Hammondia* (morphologically indistinguishable from those of *Toxoplasma*) are shed unsporulated; and schizogony occurs in the intestinal epithelium of the cat. It is concluded that *Hammondia* might be better placed in the family Toxoplasmatidae, together with *Besnoitia* and *Toxoplasma*.

Besnoitia has a *Toxoplasma*-like oocyst, and the parasite can be subinoculated from one to another intermediate host, as *Toxoplasma* can be. *Besnoitia* was considered by Wallace and Frenkel (1975) to belong to the Toxoplasmatidae. *Besnoitia besnoiti* was found to be distinct from *Toxoplasma* in the indirect fluorescent antibody test (Tadros and Laarman, 1975c) but occasional cross-reaction at a titre of 1:32 between *Toxoplasma* and

---

* Sporulated oocysts, when fed to cats, did not give rise to an oocyst-to-oocyst cycle; and the parasite could not be passaged from mouse to mouse by subinoculation.

TABLE 12

Sarcocystis compared with *Toxoplasma* and *Hammondia**

Feature	*Toxoplasma*	*Hammondia*	*Sarcocystis*
Brain cysts	+++	+	rare
Cystozoites (bradyzoites)	slender	slender	broad
Schizogony in gut of cat	present	present	absent
Developmental site in intestine	epithelium	epithelium	lamina propria
Condition in which oocysts shed	unsporulated	unsporulated	sporulated
Patent period	short	short	long
Antigenic relationship with *Toxoplasma*		yes	no

* For additional criteria see text, Frenkel (1974) and Frenkel and Dubey (1975a, b).

Besnoitia sp. was shown in the same test by Wallace and Frenkel (1975). In other tests, B. jellisoni and Toxoplasma appeared to have certain antigens in common, although immunologically they were different (Lunde and Jacobs, 1965). In the "Introduction", it was suggested that the Toxoplasma-like oocysts seen by Rommel (1975) may have been those of Besnoitia. Although Besnoitia is referred to in the paper by Rommel and Krampitz (1975), there is, however, no further comment by Rommel on the Toxoplasma-like oocysts seen by him (Rommel, op. cit.); and only the work of Peteshev et al. (1974) is quoted.

Frenkelia, as was pointed out by Rommel and Krampitz (1975), would appear to be closely related to Sarcocystis and should be classified in the family Sarcocystidae.

Frenkel (1974) referred to "Genus Hammondia gen. nov." and to "Hammondia hammondi nov. spec., to be further described (Frenkel and Dubey, 1974) ...". A number of details concerning the parasite were given by Frenkel (op. cit.) and the tissue cyst of H. hammondi was illustrated by a photomicrograph. The paper referred to by Frenkel (op. cit.) as "Frenkel and Dubey, 1974" was, in fact, published in 1975, the title being: "Hammondia hammondi gen. nov., sp. nov., from domestic cats, a new coccidian related to Toxoplasma and Sarcocystis". It was intended that this should be the formal description of the new genus and species. The generic and specific names will, however, have to be attributed to Frenkel: the correct name of H. hammondi* is Hammondia hammondi Frenkel, 1974 (not Hammondia hammondi Frenkel and Dubey, 1975).

---

* Frenkel (1974), in proposing a scheme for referring to sporocysts or oocysts like H. hammondi, pending investigation of their life-cycles, used the word "isosporid". As "isosporid" appears to be, but is not an English word derived from a scientific family name "Isosporidae", a better adjective to use would be "isosporan".

Identification of coccidia in the faeces of naturally infected cats and dogs

At least four easily distinguishable types of isosporan oocyst may be found in the faeces of cats (Figure 51) and at least four types in dogs (Figure 52). Some oocysts of cats are figured by Dubey (1973), Frenkel (1973b) and Rommel (1975) and some oocysts of dogs are illustrated by Rommel (1975). Measurements of oocysts in cats and dogs are given in Tables 13 and 14, respectively. For the dimensions of Hammondia and Besnoitia oocysts in cats, which are similar to those of Toxoplasma, see Peteshev et al. (1974), Frenkel (1974), Frenkel and Dubey (1975a, b) and Wallace and Frenkel (1975).

There has been some confusion surrounding the name "Isospora bigemina" which, even recently, has been used for more than one coccidium of cats and dogs (e.g. by Levine and Ivens, 1965b, Shah, 1970 and Zaman, 1970) and has included both T. gondii and Sarcocystis (inter alia). The "small race of I. bigemina" in the dog has been shown not to be the same (as some workers had thought) as T. gondii (Heydorn, 1973; Žuković, et al. 1973).

In cats, neither T. gondii (or T. gondii-like oocysts) nor Sarcocystis is as commonly seen as are the larger I. felis and I. rivolta, both of which are shed in the unsporulated state as intact oocysts. I. felis is the largest cat coccidium and that most frequently encountered.

The idea that coccidian oocysts have a high degree of dimensional constancy and that size alone can be used narrow limits in specific identification, is open to question. Oocysts of various coccidia increase markedly in size during patency (Duszynski, 1971).

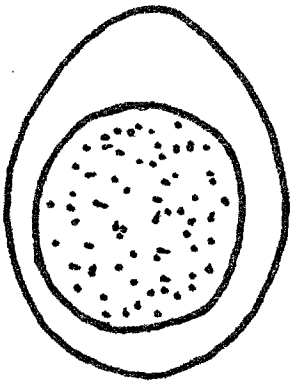

Isospora felis

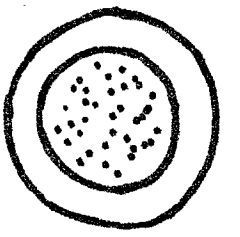

Isospora rivolta



*Sarcocystis



Toxoplasma; Hammondia; Besnoitia



Figure 51. Relative sizes of isosporan coccidia in cats.

---

*Sarcocystis is usually passed fully sporulated and as a free sporocyst.

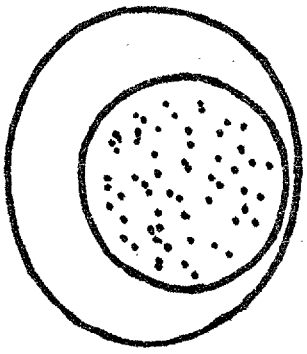

Isospora canis

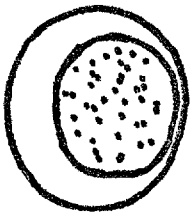

Isospora rivolta



*Sarcocystis



"small race of
I. bigemina"
(possibly a species
of Hammondia)



30 um

Figure 52. Relative sizes of isosporan coccidia in dogs.

---

*Sarcocystis is usually passed fully sporulated and as a free sporocyst.

TABLE 13

*Dimensions in μm of sporulated isosporan oocysts and *Sarcocystis* sporocysts in cats

Parasite	Size	Number measured	Author
Isospora felis	38-51 x 27-39 (41.6 x 30.5)	40	Shah, 1970
Isospora rivolta	21-28 x 18-23 (25.0 x 21.1)	30	Shah, 1970
Toxoplasma gondii	(12.7 x 10.4)	50	Hutchison *et al.*, 1971
Sarcocystis (bovine)	Sporocyst: 11.6-14.9 x 8.2 - 10.4 (12.9 x 8.7)	50	Markus *et al.*, 1974

*Average measurements are given in parentheses.

TABLE 14

*Dimensions in μm of sporulated isosporan oocysts and *Sarcocystis* sporocysts in dogs

Parasite	Size	Number measured	Author
Isospora canis	34-40 x 28-32 (36 x 30)	50	Lepp & Todd, 1974
Isospora rivolta	20-27 x 15-24 (23 x 19)	50	Levine & Ivens, 1965b
**"Small race of *Isospora bigemina*"	10.0-14.6 x 9.2-13.1 (11.9 x 11.1)	150	Heydorn, 1973
Sarcocystis (ovine)	*Sporocyst*: 13.1-16.1 x 8.5-10.8 (14.8 x 9.9)	100	Rommel *et al.*, 1974

*Average measurements are given in parentheses.

**Possibly a species of *Hammondia*.

Serology of human sarcosporidiosis

Whereas the ability to diagnose sarcosporidiosis serologically may prove to be desirable in human medicine, the use of such tests in the future will probably be more of academic interest in veterinary medicine (but see last paragraph of this subsection).

As discussed above, antibodies to Sarcocystis detectable by the indirect fluorescent antibody test did not appear in the serum of an experimental cat with an intestinal infection (analogous to I. hominis in man) which followed the ingestion of tissue cysts in raw cattle diaphragm. The reason may have been that extraintestinal infection is sometimes or always necessary for antibody production. Unlike Toxoplasma, Sarcocystis in carnivores does not normally develop extraintestinal stages, which in the case of Toxoplasma appear to play a role in stimulating the production of antibody (Dubey and Frenkel, 1972b). Even intestinal schizogony does not occur in Sarcocystis infections. Some indication of the extent to which Sarcocystis in the intestine is "recognised" by the carnivore host is perhaps provided by the following comments. Fayer (1974a), who studied gametogony and oocyst formation of bovine Sarcocystis in the dog, found no gross or microscopic lesions in the gut and stated that "little or no cellular reaction to the parasite" was seen in stained sections. In dogs infected with ovine Sarcocystis, "there appeared to be no cellular reaction to the presence of the parasites in the intestine" (Munday et al., 1975).

Many persons show apparent serum antibodies to Sarcocystis of cattle in the indirect fluorescent antibody test (Markus, 1973d; Laarman et al., 1974; Tadros et al., 1974), though this did not happen in the complement fixation test when S. tenella (macroscopic cysts) antigen was used (Bordjoški and Conić, 1973; Bordjoški et al., 1975). Whether or not S. tenella

infects man has yet to be established. The indications are that the macroscopic ovine cysts do not do so (Rommel et al., 1974). Tadros et al. (1974) considered that their results indicated the presence of antibody in man to Sarcocystis of cattle. Markus (1973d) had interpreted similar results with caution. Laarman et al. (1974) demonstrated apparent antibody in both known I. hominis carriers and non-carriers (including vegetarians), with use of bovine Sarcocystis antigen and I. hominis sporozoites in the indirect fluorescent antibody test. Only occasionally did they observe such reactions in young babies. Laarman et al. (1974) speculated (inter alia) that there might be cross-reaction between I. hominis and I. belli. The question of false positives should be considered. Whether the indirect fluorescent antibody test can give false positives as it occasionally does with Toxoplasma antigen (see Araujo et al., 1971; Remington and Desmonts, 1973; Hyde et al., 1975), is an aspect requiring investigation. Furthermore, it should be noted that there is a serum factor which in the indirect fluorescent antibody test causes polar fluorescence of Toxoplasma in approximately 30% of seronegative individuals. This factor is heat stable, can be titrated, and does not usually occur in the blood of infants of less than 6 months of age (Sulzer and Wilson, 1971; Kaufman et al., 1973). The possibility that a similar factor causes polar or whole body fluorescence of Sarcocystis needs to be eliminated.

In the most recent review of sarcosporidiosis in man (Jeffrey, 1974), it is suggested that the complement-fixation test would be of value (e.g. McGill and Goodbody, 1957) in distinguishing between toxoplasmosis and sarcosporidiosis in cases where morphological study of small cysts in muscle gives an equivocal diagnosis. Markus (1974c) pointed out that while much information concerning the serodiagnosis of toxoplasmosis is available, this is not true of sarcosporidiosis.

Subclinical coccidiosis in man caused by I. hominis is common (e.g. Tadros et al., 1974). If antibody is indeed formed, it follows that tests using Sarcocystis antigen on sera of persons having unidentified muscle cysts of Toxoplasma could be positive for Sarcocystis because of a past or concomitant intestinal I. hominis infection. On the basis of present knowledge, therefore, a positive result from a serological test for sarcosporidiosis in a person with unidentified muscle cysts might be difficult to interpret, particularly if tests for Toxoplasma are also positive. The chances that a test for toxoplasmosis will be positive are good, since it is now a well-established fact that antibodies to Toxoplasma are found in many healthy persons. Only a negative test for toxoplasmosis would help to exclude this protozoon in a patient having unidentified cysts in muscle. However, the absence of demonstrable Toxoplasma antibody cannot be taken as absolute proof that the parasite is not present in the tissues (Remington and Araujo, 1974).

While a negative serological test for toxoplasmosis in a patient having unidentified cysts in muscle would be useful information, more experimental work on antibody production in Sarcocystis infections in relation to the use of tests for sarcosporidiosis is necessary.

It is concluded that serological tests for human sarcosporidiosis/coccidiosis caused by I. hominis are, in the present state of knowledge, of limited (if any) value. It is not known whether apparent antibody in man indicates infection with muscle cysts or an intestinal infection or both; and the presence of apparent antibody in *vegetarians and non-I. hominis carriers (Laarman et al., 1974) has yet to be explained.

---

* Sera of 21 vegetarians in Holland were all positive at a serum dilution of 1:20, twelve having titres of 1:160 or more!

As far as animals are concerned, serological tests may prove to be useful, e.g. in experimental infection of *lambs or *calves. Tests have been used in prevalence studies and experimental infections in herbivore (prey) animals by some authors. It is not known whether intestinal infections with Sarcocystis in carnivores such as dogs and cats can be diagnosed serologically.

---

* Only the tissue phase of the sarcosporidial infection takes place in animals such as these, whereas in man both tissue and intestinal infections can occur. This makes interpretation of the results of serological tests in man difficult.

Specificity of serological tests for human toxoplasmosis

As shown by some of the papers quoted elsewhere in this thesis, toxoplasmosis is clearly an important disease in both animals (see also Campbell et al., 1955; Meier et al., 1957; Siim, 1963; Drake and Hime, 1967; Vainisi and Campbell, 1969; Watson, 1972; Cusick et al., 1974) and, as is well-known, man. Thus it is necessary to know something of the serological and immunological relationships of the Isospora-type coccidia of mammals.

Immediately following the discovery of isosporan oocysts in the life-cycle of Toxoplasma gondii, the important question of the specificity of current serological tests for antibodies to Toxoplasma was raised by a number of authors (Jadin and Willaert, 1970; Overdulve, 1970; Werner and Janitschke, 1970; Hutchison et al., 1971; Draper et al., 1971; Laarman and Mas Bakal, 1971; Piekarski and Witte, 1971; Stagno et al., 1971).

The evidence indicates an absence of any marked cross-reactivity between Toxoplasma and Isospora spp. of cats (e.g. de Andrade and Weiland, 1971; Draper et al., 1971; Piekarski and Witte, 1971) or dogs (e.g. Heydorn, 1973; Žuković et al., 1973). As far as I. belli of man is concerned, a suggestion by Stagno et al. (1971) that there may be common antigenicity between Toxoplasma and I. belli was not supported by Eaton et al. (1973), who found evidence to the contrary. Thus the opinion of de Oliveira et al. (1973) that there is "group" cross-reaction between Toxoplasma on the one hand and I. hominis and I. belli on the other is open to question and needs to be confirmed.

Sera of persons known to be passing I. hominis (= Sarcocystis) were tested by the dye test (Laarman and Mas Bakal, 1971) and indirect fluorescent antibody test (Doby and Beaucournu, 1972; Tadros et al., 1974; Dymowska et al., 1974; Płotkowiak, 1975) but cross-reaction with Toxoplasma

was not observed. Similarly, an absence of cross-reactivity between Toxoplasma and Sarcocystis from bovine diaphragm was suggested by the results of examination of Toxoplasma-positive chimpanzee sera in the indirect fluorescent antibody test (Markus, 1973d).

Cats that are shedding sporocysts of Sarcocystis can be superinfected with Toxoplasma, resulting in the production of oocysts of the latter parasite as well (Piekarski and Witte, 1971; Frenkel, 1973b). Although several workers have shown that a strong immunity usually develops in cats in which Toxoplasma has undergone gametogony, cats can be re-infected with Sarcocystis relatively easily (vide antea).

As far as the tissue stage of Sarcocystis is concerned, it was thought that both Toxoplasma and Sarcocystis antigens could be used in the dye-test for toxoplasmosis (Muhlpfordt, 1951; Awad, 1954). However, this was subsequently shown not to be the case (Cathie and Cecil, 1957). Something that is inexplicably poorly documented in the current literature is the fact that the specificity of various serological tests for Toxoplasma has been independently established by a number or persons, who used sera of man (Beverley, 1957; see Kulasiri, 1960; Fulton and Voller, 1964; Mandour, 1965b), monkeys (Jacobs, 1956) and baboons (McConnell et al., 1973) with infections of Sarcocystis spp. or sera of sheep having macroscopic sarcocysts (see e.g. Awad and Lainson, 1954; Cathie, 1957; Cathie and Cecil, 1957; Awad, 1958; Kulasiri, 1960; Piekarski and Saathoff, 1962; de Andrade and Weiland, 1971). See also the section on "Systematic relationship of Sarcocystis to Hammondia, Besnoitia, Frenkelia and Toxoplasma".

None of the five described genera of isosporan coccidia related to T. gondii other than Sarcocystis are known to infect man, although Frenkel has

seen Hammondia-like cysts in man (Frenkel and Dubey, 1975b). Hammondia and Toxoplasma share some antigens (Frenkel, 1974; Frenkel and Dubey, 1975a, b; Wallace, 1975). If Hammondia does infect man, some low titres of apparent antibody against Toxoplasma may, in fact, represent cross-reaction with Hammondia.

However, it is concluded that there are as yet no grounds for questioning the reliability of routine serological tests for acute human toxoplasmosis.

Extraintestinal infections of *Isospora felis*

There is not as yet any evidence that immunosuppression in mammals with infections of *Isospora sensu strictu* can cause extended schizogony and development of parasites in abnormal sites as happens in some *Eimeria* infections of birds and with some other coccidia (*vide antea*; McLoughlin, 1969; Fitzgerald, 1970; Long, 1970, 1971; Long and Rose, 1970; Rose, 1970). Sporozoite-initiated proliferation by schizogony (as defined by Scholtyseck, 1973) appears to be restricted to the intestine (e.g. Hitchcock, 1955; Lickfeld, 1959; Shah, 1971). Parasites can be transported in the extraintestinal tissues as happens in some other coccidial infections (cf. Fitzgerald, 1974; Sénaud *et al.*, 1974).

At least some species of *Isospora sensu strictu* show similarities to organisms such as *Sarcocystis* and *Toxoplasma* in that infection can take place as a result of carnivorism. In this respect *Isospora* is also similar to *Hepatozoon* (Landau, 1973a, b; Landau *et al.*, 1972).

REFERENCES

ABBAS, A.M.A. & BARRADA, A. 1971. Apparent isolation of Toxoplasma gondii from human faeces. Trans. R. Soc. trop. Med. Hyg. 65: 337-338.

AKAO, S. 1970. A new species of Sarcocystis parasitic in the whale Balaenoptera borealis. J. Protozool. 17: 290-294.

AOKI, T. 1973. A case of isolation of Toxoplasma gondii from the peripheral blood of a woman infected chronically. (In Japanese). Jap. J. Parasit. 22: 277-280.

ARAMBULO, P.V. III, ABASS, J.B. & WALKER, J.S. 1974. Silvered leaf-monkeys (Presbytis cristatus). II. Gastrointestinal parasites and their treatment. Lab. Anim. Sci. 24: 299-306.

ARAUJO, F.G., BARNETT, E.V., GENTRY, L.O. & REMINGTON, J.S. 1971. False-positive anti-Toxoplasma fluorescent-antibody tests in patients with antinuclear antibodies. Appl. Microbiol. 22: 270-275.

ARAUJO, F.G., WONG, M.M., THEIS, J. & REMINGTON, J.S. 1973. Experimental Toxoplasma gondii infection in a nonhuman primate. Am. J. trop. Med. Hyg. 22: 465-472.

ARCAY-DE-PERAZA, L. 1967. Coccidiosis en monos y su comparacion con la isosporosis humana, con descripcion de una nueva especie de Isospora en Cacajao rubicundus (Uakari Monkey o Mono Chucuto). Acta biol. Venezuela 5: 203-222.

ARCHIBALD, R.G. & SUSU, B. 1924. A sporozoon from the spleen of a case of splenomegaly in the Sudan. Trans. R. Soc. trop. Med. Hyg. 17: 482-484.

ASAMI, K. & SHINKICHI, A. 1974. Light and electronmicroscopical observations on developmental stages of Isospora belli in the human intestinal mucosa. Proc. 3rd int. Congr. Parasit. (Munich) 1: 104-105.

ASHFORD, R.W. 1975. Preliminary observations on the life cycle of Isospora buteonis. J. Protozool. 22: 48A.

AWAD, F.I. 1954. A new dye test for Toxoplasma and Sarcocystis infections by use of Sarcocystis tenella spores. Trans. R. Soc. trop. Med. Hyg. 48: 337-341.

AWAD, F.I. 1958. The complement-fixation test in the diagnosis of sarcosporidiosis. Am. J. vet. Res. 19: 1010-1012.

AWAD, F.I. 1973. The transmission of Sarcocystis tenella in sheep. Z. ParasitKde 42: 43-48.

AWAD, F.I. & LAINSON, R. 1954. A note on the serology of sarcosporidiosis and toxoplasmosis. J. clin. Path. 7: 152-156.

BAMFORD, C.R. 1975. Toxoplasmosis mimicking a brain abscess in an adult with treated scleroderma. Neurology 25: 343-345.

BEECH, J. & DODD, D.C. 1974. Toxoplasma - like encephalomyelitis in the horse. Vet. Path. 11: 87-96.

BEHYMER, R.D., HARLOW, D.R., BEHYMER, D.E. & FRANTI, C.E. 1973. Serologic diagnosis of toxoplasmosis and prevalence of Toxoplasma gondii antibodies in selected feline, canine and human populations. J. Am. vet. med. Ass. 162: 959-963.

BENSON, C.W., BROOKE, R.K., DOWSETT, R.J. & IRWIN, M.P.S. 1971. The birds of Zambia. Collins, London.

BERGER, J. & PIEKARSKI, G. 1973. Epidemiologisch-serologische Beobachtungen über die Infektion mit Toxoplasma gondii anhand einer prospektiven Untersuchungsreihe. Zentbl. Bakt. ParasitKde. Abt. I. Orig. 224: 391-411.

BEVERLEY, J.K.A. 1957. No title - "Discussion" following papers read in a "Symposium on toxoplasmosis". Trans. R. Soc. trop. Med. Hyg. 51: 118-120.

BEVERLEY, J.K.A., HUTCHISON, W.M., ALLSUP, T.N., SPENCE, J.B. & WATSON, W.A. 1975. Studies on the spread of Toxoplasma gondii to sheep. Br. vet. J. 131: 130-136.

BEVERLEY, J.K.A. & WATSON, W.A. 1961. Ovine abortion and toxoplasmosis in Yorkshire. Vet. Rec. 73: 6-11.

BEVERLEY, J.K.A. & WATSON, W.A. 1971. Prevention of experimental and of naturally occurring ovine abortion due to toxoplasmosis. Vet. Rec. 88: 39-41.

BHATAVDEKAR, M.Y. & PUROHIT, B.L. 1963. A record of sarcosporidiosis in lion. Indian vet. J. 40: 44-45.

BICKNELL, S.R. 1972. An unsuccessful attempt to transmit toxoplasmosis to mice from the faeces of artificially infected sheep. Br. vet. J. 128: xi-xiv.

BIGALKE, R.D. & TUSTIN, R.C. 1960. The occurrence of a cyst of Sarcocystis Lankester 1882 in the cerebellum of an ox. Jl S. Afr. vet. med. Ass. 31: 271-274.

BIOCCA, E. 1968. Class Toxoplasmatea: critical review and proposal of the new name Frenkelia gen. n. for M-organism. Parassitologia 10: 89-98.

BISHOPP, F.C. & LAAKE, E.W. 1921. Dispersion of flies by flight. J. agric. Res. 21: 729-766.

BOCH, J., KÜHN, D., ROMMEL, M. & WEILAND, G. 1974. Toxoplasma-Infektionen bei Haustieren und ihre Bedeutung für die Toxoplasmose des Menschen. Munch. med. Wschr. 116: 1477-1480.

BORDJOŠKI, A. & CONIĆ, V. 1974. Novija istraživanja sarkosporidioze u ljudi. Acta Parasit. Iugosl. 4: 99-106.

BORDOŠKI, A., CONIĆ, V., MILICA, B. & SAVIN, Ž. 1975. Serological investigations of sarcosporidiosis in human beings by the complement fixation test. 2nd European Multicolloquy of Parasitology, Trogir (summaries of papers read): 17. Društvo Parazitologa Jugoslavije, Beograd.

BORG, O.A. & WOODRUFF, A.W. 1973. Prevalence of infective ova of Toxocara species in public places. Br. med. J. 4: 470-472.

BOX, E.D. 1973. Comparative development of two Isospora species in the canary. J. Protozool. 20: 510.

BOX, E.D. 1975a. Exogenous stages of Isospora serini (Aragão) and Isospora canaria sp. n. in the canary (Serinus canarius Linnaeus). J. Protozool. 22: 165-169.

BOX, E.D. 1975b. An explanation for chronic coccidiosis in canaries (Serinus canarius). J. Protozool. 22: 28A.

BRANDBORG, L.L., GOLDBERG, S.B. & BREIDENBACH, W.C. 1970. Human coccidiosis - a possible cause of malabsorption. The life cycle in small-bowel mucosal biopsies as a diagnostic feature. New Engl. J. Med. 283: 1306-1313.

BRAVENY, I., DISKO, R. & JANSSEN, H. 1973. Untersuchungen zur Epidemiologie der Toxoplasmose. Dt. med. Wschr. 98: 535-539.

BRAY, R.S. & GARNHAM, P.C.C. 1962. The Giemsa-colophonium method for staining Protozoa in tissue sections. Indian J. Malar. 16: 153-155.

BREUER, H.J. 1966. Untersuchungsergebnisse über das Vorkommen von Sarkosporidien bei Rindern, Schafen und Schweinen und deren fleischhygienische Bedeutung. Schlacht- Vieh. Z. 66: 119-120.

BUXTON, P.A. 1920. The importance of the housefly as a carrier of E. histolytica. Br. med. J. 1: 143-144.

CAMPBELL, R.S.F., MARTIN, W.B. & GORDON, E.D. 1955. Toxoplasmosis as a complication of canine distemper. Vet. Rec. 67: 708-716.

ČATÁR, G. 1973. Domestic animals and animals in natural conditions as potential reservoirs of toxoplasmosis for man. 9th Int. Congr. trop. Med. and Malaria, Athens (abstracts of communications) 2: 148.

ČATÁR, G. 1974a. Toxoplazmóza v ekologických podmienkach na Slovensku. Treatises on biology 20 (1-2). Scientific committee for special biology and scientific committee for general biology of the Slovak Academy of Science. Bratislava.

ČATÁR, G. 1974b. Possibilities of distribution of toxoplasmosis in urban conditions. Proc. 3rd int. Congr. Parasit. (Munich) 1: 309-310.

CATHIE, I.A.B. 1957. An appraisal of the diagnostic value of the serological tests for toxoplasmosis. Trans. R. Soc. trop. Med. Hyg. 51: 104-110.

CATHIE, I.A.B. & CECIL, G.W. 1957. Sarcospores and toxoplasm serology. Lancet 1: 816-818.

COFFEY, M.D. 1966. Studies on the association of flies (Diptera) with dung in southeastern Washington. Ann. ent. Soc. Am. 59: 207-218.

COHEN, S.N. 1970. Toxoplasmosis in patients receiving immunosuppressive therapy. J. Am. med. Ass. 211: 657-660.

COMSTOCK, G.W. & GANLEY, J.P. 1973. Association of toxoplasmosis and cats. Am. J. Epidem. 97: 424.

COPEMAN, S.M., HOWLETT, F.M. & MERRIMAN, G. 1911. An experimental investigation on the range of flight of flies. Rep. loc. Govt Bd publ. Hlth new ser., no. 53: 1-10.

CORNER, A.H., MITCHELL, D., MEADS, E.B. & TAYLOR, P.A. 1963. Dalmeny disease. An infection of cattle presumed to be caused by an unidentified protozoon. Can. vet. J. 4: 252-264.

COUTINHO, J.O., TAUNAY, A. DE E. & LIMA, L.P. DE C. 1957. Importância da Musca domestica como vector de agentes patogênicos para o homem. Revta Inst. Adolfo Lutz 17: 5-23.

CRAGG, J.B. 1956. The olfactory behaviour of Lucilia species (Diptera) under natural conditions. Ann. appl. Biol. 44: 467-477.

CRAGG, J.B. & COLE, P. 1956. Laboratory studies on the chemosensory reactions of blowflies. Ann. appl. Biol. 44: 478-491.

CUMMINS, L.B., KEELING, M.E. & McCLURE, H.M. 1973. Preventive medicine in anthropoids: parasite control. Lab. Anim. Sci. 23: 819-822.

CUNNINGHAM, C.C. 1973. Sarcocysts in the heart muscle of a foal. Vet. Rec. 92: 684.

CUSICK, P.K., SELLS, D.M., HAMILTON, D.P. & HARDENBROOK, H.J. 1974. Toxoplasmosis in two horses. J. Am. vet. med. Ass. 164: 77-80.

DE ANDRADE, C.M. & WEILAND, G. 1971. Serologische Untersuchungen zur Feststellung gemeinsamer Antigene von Toxoplasmen, Sarkosporidien und Kokzidien. Berl. Münch. Tierärztl. Wschr. 84: 61-64.

DE OLIVEIRA, G.S.C., BARBOSA, W. & DA SILVA, A.L. 1973. Isosporose humana en goiás 1. Dados epidemiológicos, clínicos e imunológicos. Revta Patol. trop. 2: 387-395.

DE ROEVER-BONNET, H. 1972. Protective effect of various tissues and dilution fluids on Toxoplasma parasites in the stomach of the mouse. Trop. geogr. Med. 24: 14-17.

DE ROEVER-BONNET, H. 1974. Toxoplasma in faeces of experimentally and naturally infected animals. Proc. 3rd int. Congr. Parasit. (Munich) 1: 308.

DESMONTS, G. & COUVREUR, J. 1974. Congenital toxoplasmosis. A prospective study of 378 pregnancies. New Engl. J. Med. 290: 1110-1116.

DE VOS, A.J. 1970. Studies of the host range of Eimeria chinchillae de Vos & van der Westhuizen, 1968. Onderstepoort J. vet. Res. 37: 29-36.

DISSANAIKE, A.S. & POOPALACHELVAM, M. 1975. Sarcocystis booliati n. sp. and a parasite of undetermined taxonomic position, Octoplasma garnhami n. gen. n. sp., from the moonrat, Echinosorex gymnurus. S.E. Asian J. trop. Med. publ. Hlth 6: 175-185.

DOBELL, C. 1925. The life-history and chromosome cycle of Aggregata eberthi (Protozoa: Sporozoa: Coccidia). Parasitology 17: 1-136.

DOBOS-KOVÁCS, M., MÉSZÁROS, J., PELLÉRDY, L. & BALSAI, A. 1974a. Toxoplasmose bei Känguruhs (Thylogale eugenii) verursacht durch Toxoplasma-Oozysten enthaltendes Futter. Parasit. Hung. 7: 85-89.

DOBOS-KOVÁCS, M., MÉSZÁROS, J., PELLÉRDY, L. & BALSAI, A. 1974b. Studies on source of Toxoplasma infection in captive kangaroos. Acta vet. hung. 24: 293-301.

DOBY, J.M. & BEAUCOURNU, J.C. 1972. Absence de réactions croisées en immuno-fluorescence indirecte entre sérum de porteurs de Isospora hominis et antigènes Toxoplasma. Bull. Soc. Path. exot. 65: 404-409.

DOBY, J.M., DESMONTS, G., BEAUCOURNU, J.C. & AKINCHINA, G.T. 1974. Recherche immunologique systématique de toxoplasmose chez les petits mammifères sauvages en France. Folia parasit., Praha 21: 289-300.

*DORAN, D.J. 1953. Coccidiosis in the kangaroo rats of California. Univ. Calif. Publs Zool. 59: 31-60.

---

* Not seen by the author.

DRAKE, J.C. & HIME, J.M. 1967. Two syndromes in young dogs caused by Toxoplasma gondii. J. small Anim. Pract. 8: 621-626.

DRAPER, C.C., KILLICK-KENDRICK, R., HUTCHISON, W.M., SIIM, J. CHR. & GARNHAM, P.C.C. 1971. Experimental toxoplasmosis in chimpanzees. Br. med. J. 2: 375-378.

DROST, S. 1974. Die Sarkosporidien des Schalenwildes. I. Sarkosporidien bei Wildschweinen. Angew. Parasit. 15: 212-221.

DRURY, R.A.B. & WALLINGTON, E.A. 1967. Carleton's histological technique. Oxford University Press.

DUBEY, J.P. 1973. Feline toxoplasmosis and coccidiosis: a survey of domiciled and stray cats. J. Am. vet. med. Ass. 162: 873-877.

DUBEY, J.P. 1974. Effect of freezing on the infectivity of Toxoplasma cysts to cats. J. Am. vet. med. Ass. 165: 534-536.

DUBEY, J.P. 1975. Experimental Isospora canis and Isospora felis infection in mice, cats, and dogs. J. Protozool. 22: 416-417.

DUBEY, J.P., DAVIS, G.W., KOESTNER, A. & KIRYU, K. 1974. Equine encephalomyelitis due to a protozoan parasite resembling Toxoplasma gondii. J. Am. vet. med. Ass. 165: 249-255.

DUBEY, J.P. & FRENKEL, J.K. 1972a. Extra-intestinal stages of Isospora felis and I. rivolta (Protozoa: Eimeriidae) in cats. J. Protozool. 19: 89-92.

DUBEY, J.P. & FRENKEL, J.K. 1972b. Cyst-induced toxoplasmosis in cats. J. Protozool. 19: 155-177.

DUBEY, J.P. & FRENKEL, J.K. 1973. Experimental Toxoplasma infection in mice with strains producing oocysts. J. Parasit. 59: 505-512.

DUBEY, J.P. & FRENKEL, J.K. 1974. Immunity to feline toxoplasmosis: modification by administration of corticosteroids. Vet. Path. 11: 350-379.

DUBEY, J.P., MILLER, N.L. & FRENKEL, J.K. 1970a. The Toxoplasma gondii oocyst from cat faeces. J. exp. Med. 132: 636-662.

DUBEY, J.P., MILLER, N.L. & FRENKEL, J.K. 1970b. Characterization of the new fecal form of Toxoplasma gondii. J. Parasit. 56: 447-456.

DUBREMETZ, J.-F., PORCHET-HENNERÉ, E. & PARENTY, M.-D. 1975. Croissance de Sarcocystis tenella en culture cellulaire. C. r. hebd. Séanc. Acad. Sci., ser. D, 280: 1793-1795.

DURFEE, P.T., MA, C.H., WANG, C.F. & CROSS, J.H. 1974. Infectivity and pathogenicity of Toxoplasma oocysts for swine. J. Parasit. 60: 886-887.

DUSZYNSKI, D.W. 1971. Increase in size of Eimeria separata oocysts during patency. J. Parasit. 57: 948-952.

DUSZYNSKI, D.W. & FILE, S.K. 1974. Structure of the oocyst and excystation of sporozoites of Isospora endocallimici n. sp., from the marmoset Callimico goeldii. Trans. Am. microsc. Soc. 93: 403-408.

*DYMOWSKA, Z., KLASA, A., PŁOTKOWIAK, J. & ZIELIŃSKA, E. 1974. Immunofluorescence test with Toxoplasma antigen in persons with Isospora hominis infection (in Russian). Medycyna doświ. Mikrobiol. 26: 247-250.

EATON, R.D.P., SCOTT, F. & BOODRAM, C. 1973. Toxoplasmosis isosporosis. New Engl. J. Med. 288: 797.

---

* Not seen: reference from Tropical Diseases Bulletin 71(12): 1308, 1974.

EDDY, G.W., ROTH, A.R. & PLAPP, F.W., Jr. 1962. Studies on the flight habits of some marked insects. J. econ. Ent. 55: 603-607.

EL-AFIFI, A., ABDO, A.H. & EL-SAWAH, H.M. 1963. Transmission of Sarcocystis blanchardi into white mice. Vet. Med. J., Giza 8: 219-223.

EL-KASABY, A. & SYKES, A.H. 1972. Eimeria acervulina and macrophage response in chickens: behaviour of the parasite and the host cells. Trans. R. Soc. trop. Med. Hyg. 66: 539-540.

EL-KASABY, A. & SYKES, A.H. 1973a. Coccidiosis and macrophage response in chickens. Proc. 4th Europ. poult. Conf. (London): 137-140.

EL-KASABY, A. & SYKES, A.H. 1973b. The role of chicken macrophages in the parenteral excystation of Eimeria acervulina. Parasitology 66: 231-239.

ELLIOTT, C.C.H. & JARVIS, M.J.F. 1970. Fourteenth ringing report. Ostrich 41: 1-117.

ELLIOTT, C.C.H. & JARVIS, M.J.F. 1972/73. Fifteenth ringing report. Ostrich 43: 236-295 & 44: 34-78.

ELSDON-DEW, R. & FREEDMAN, L. 1953. Coccidiosis in man: experiences in Natal. Trans. R. Soc. trop. Med. Hyg. 47: 209-214.

EUZÉBY, J., LESTRA, TH. & GAUTHEY, M. 1972. Note de recherche: sur les affinités taxonomiques des sarcosporidies. Bull. Soc. Sci. vét. Méd. comp. Lyon 74: 207-211.

FAYER, R. 1970. Sarcocystis: development in cultured avian and mammalian cells. Science 168: 1104-1105.

FAYER, R. 1972a. Gametogony of Sarcocystis sp. in cell culture. Science 175: 65-67.

FAYER, R. 1972b. Cultivation of feline Isospora rivolta in mammalian cells. J. Parasit. 58: 1207-1208.

FAYER, R. 1974a. Development of Sarcocystis fusiformis in the small intestine of the dog. J. Parasit. 60: 660-665.

FAYER, R. 1974b. Canis latrans and C. familiaris: host of Sarcocystis fusiformis. Proc. 3rd int. Congr. Parasit. (Munich) 1: 114-115.

FAYER, R. 1975. Effects of refrigeration, cooking, and freezing on Sarcocystis in beef from retail stores. Proc. helminth. Soc. Wash. 42: 138-140.

FAYER, R. & JOHNSON, A.J. 1973. Development of Sarcocystis fusiformis in calves infected with sporocysts from dogs. J. Parasit. 59: 1135-1137.

FAYER, R. & JOHNSON, A.J. 1974. Sarcocystis fusiformis: development of cysts in calves infected with sporocysts from dogs. Proc. helminth. Soc. Wash. 41: 105-108.

FAYER, R. & JOHNSON, A.J. 1975. Sarcocystis fusiformis infection in the coyote (Canis latrans). J. infect. Dis. 131: 189-192.

FAYER, R. & KOCAN, R.M. 1971. Prevalence of Sarcocystis in grackles in Maryland. J. Protozool. 18: 547-548.

FAYER, R. & LEEK, R.G. 1973. Excystation of Sarcocystis fusiformis sporocysts from dogs. Proc. helminth. Soc. Wash. 40: 294-296.

FAYER, R. & MAHRT, J.L. 1972. Development of Isospora canis (Protozoa; Sporozoa) in cell culture. Z. ParasitKde 38: 313-318.

FAYER, R., MAHRT, J.L. & JOHNSON, A.J. 1973. The life cycle and pathogenic effects of Sarcocystis fusiformis in experimentally infected calves (Film). J. Protozool. 20: 509.

FAYER, R. & THOMPSON, D.E. 1974. Isospora felis: development in cultured cells with some cytological observations. J. Parasit. 60: 160-168.

FEDEROV, V.G. 1962. The role of the housefly (Musca domestica L.) in the dissemination of the eggs of helminths and cysts of intestinal Protozoa during the winter. Medskaya Parazit. 31: 618-620.

FELDMAN, H.A. 1974. Discussion of paper by J.K. Frenkel, M.D., Ph.D.: breaking the transmission chain of Toxoplasma: a program for the prevention of human toxoplasmosis. Bull. N.Y. Acad. Med. 50: 236-239.

FISHER, S. & REID, R.R. 1973. Antibodies to Toxoplasma gondii and contact with animals in the home. Med. J. Aust. 1: 1275-1277.

FITZGERALD, P.R. 1970. Development of Eimeria stiedae in avian embryos. J. Parasit. 56: 1252-1253.

FITZGERALD, P.R. 1974. Results of blood transfusions from donor rabbits infected with Eimeria stiedai to recipient coccidia-free rabbits. J. Protozool. 21: 336-338.

FLECK, D.G. 1974a. Toxoplasmosis and embryopathy. Br. med. J. 1: 244.

FLECK, D.G. 1974b. Epidemiology of toxoplasmosis. Proc. 3rd int. Congr. Parasit. (Munich) 1: 305.

FLECK, D.G., CHESSUM, B.S. & PERKINS, M. 1972. Coccidian-like nature of Toxoplasma gondii. Br. med. J. 3: 111-112.

FORD, A.C. & SPELTIE, T. 1973. Some aspects of the parasitology of the non-human primates at the Netherlands Primate Center. Exp. Anim. 6: 15-24.

FORD, G.E. 1974. Prey-predator transmission in the epizootiology of ovine sarcosporidiosis. Aust. vet. J. 50: 38-39.

FORD, G.E. 1975. Transmission of sarcosporidiosis from dogs to sheep maintained specific pathogen free. Aust. vet. J. 51: 407-408.

FRENKEL, J.K. 1971. Protozoal diseases of laboratory animals. In: Pathology of protozoal and helmintic diseases, (ed. Marcial-Rojas, R.A.), pp. 318-369. The Williams and Wilkins Co., Baltimore.

FRENKEL, J.K. 1973a. Toxoplasma in and around us. BioScience 23: 343-352.

FRENKEL, J.K. 1973b. Toxoplasmosis: parasite life cycle, pathology, and immunology. In: The coccidia (eds Hammond, D.M. and Long, P.L.), pp. 343-410. University Park Press, Baltimore and Butterworths, London.

FRENKEL, J.K. 1974. Advances in the biology of Sporozoa. Z. ParasitKde 45: 125-162.

FRENKEL, J.K. & DUBEY, J.P. 1972a. Rodents as vectors for feline coccidia, Isospora felis and Isospora rivolta. J. infect. Dis. 125: 69-72.

FRENKEL, J.K. & DUBEY, J.P. 1972b. Toxoplasmosis and its prevention in cats and man. J. infect. Dis. 126: 664-673.

FRENKEL, J.K. & DUBEY, J.P. 1973. Effects of freezing on the viability of Toxoplasma oocysts. J. Parasit. 59: 587-588.

FRENKEL, J.K. & DUBEY, J.P. 1975a. Hammondia hammondi gen. nov., sp. nov., from domestic cats, a new coccidian related to Toxoplasma and Sarcocystis. Z. ParasitKde 46: 3-12.

FRENKEL, J.K. & DUBEY, J.P. 1975b. Hammondia hammondi: a new coccidium of cats producing cysts in muscle of other mammals. Science 189: 222-224.

FRENKEL, J.K., DUBEY, J.P. & MILLER, N.L. 1970. Toxoplasma gondii: fecal stages identified as coccidian oocysts. Science 167: 893-896.

FRENKEL, J.K., DUBEY, J.P. & WALLACE, G.D. 1974. Developmental and biologic comparisons between Toxoplasma and Sarcocystis-like isolates. Proc. 3rd int. Congr. Parasit. (Munich) 1: 110-111.

FRENKEL, J.K., NELSON, B.M. & ARIAS-STELLA, J. 1975. Immunosuppression and toxoplasmic encephalitis. Clinical and experimental aspects. Hum. Path. 6: 97-111.

FRENKEL, J.K., RUIZ, A. & CHINCHILLA, M. 1975. Soil survival of Toxoplasma oocysts in Kansas and Costa Rica. Am. J. trop. Med. Hyg. 24: 439-443.

FRYE, W.W. & MELENEY, H.E. 1932. Investigations of Endamoeba histolytica and other intestinal protozoa in Tennessee: IV. A study of flies, rats, mice and some domestic animals as possible carriers of the intestinal protozoa of man in a rural community. Am. J. Hyg. 16: 729-749.

FULTON, J.D. & VOLLER, A. 1964. Evaluation of immunofluorescent and direct agglutination methods for detection of specific Toxoplasma antibodies. Brit. med. J. 2: 1173-1175.

GALUZO, I.G., BUGAEV, A.M. & KONOVALOVA, S.I. 1973. Some new considerations on the life cycle of Toxoplasma gondii. Prog. Protozool. 4: 147.

*GALUZO, I.G., KONOVALOVA, S.I., BUGAEV, A.M., BEZUKLADNIKOVA, N.A. & KRIVKOVA, A.M. 1972. The life cycle of Toxoplasma and its circulation in nature. (In Russian). Voprosy Prirodnoi Ochagovosti Boleznei, Alma-Ata, USSR 5: 64-99.

GESTRICH, R. 1974. Investigations on survival and resistance of Sarcocystis fusiformis cysts in beef. Proc. 3rd int. Congr. Parasit. (Munich) 1: 117.

---

* Original not seen (from Translation No. 41 of the College of Veterinary Medicine, University of Illinois, edited by Norman D. Levine).

GESTRICH, R. & HEYDORN, A.-O. 1974. Untersuchungen zur Überlebensdauer von Sarkosporidienzysten im Fleisch von Schlachttieren. Berl. Münch tierärztl. Wschr. 87: 475-476.

GESTRICH, R., HEYDORN, A.-O. & BAYŞU, N. 1975. Beiträge zum Lebenszyklus der Sarkosporidien VI. Untersuchungen zur Artendifferenzierung bei Sarcocystis fusiformis und Sarcocystis tenella. Berl. Münch. tierärztl. Wschr. 88: 191-197.

GESTRICH, R., MEHLHORN, H. & HEYDORN, A.-O. 1975. Licht- und elektronenmikroskopische Untersuchungen an Cysten von Sarcocystis fusiformis in der Muskulatur von Kälbern nach experimentellen Infektionen mit Oocysten und Sporocysten der grossen Form von Isospora bigemina der Katze. Zentbl. Bakt. ParasitKde (Abt I; Orig.) (in press).

GESTRICH, R., SCHMITT, M. & HEYDORN, A.-O. 1974. Pathogenität von Sarcocystis tenella-Sporozysten aus den Fäzes von Hunden für Lämmer. Berl. Münch tierärztl. Wschr. 87: 362-363.

GLEASON, T.H. & HAMLIN, W.B. 1974. Disseminated toxoplasmosis in the compromised host. A report of five cases. Archs int. Med. 134: 1059-1062.

GREEN, A.A. 1951. The control of blowflies infesting slaughter-houses. I. Field observations of the habits of blowflies. Ann. appl. biol. 38: 475-494.

GREENLEE, J.E., JOHNSON, W.D., CAMPA, J.F., ADELMAN, L.S. & SANDE, M.A. 1975. Adult toxoplasmosis presenting as polymyositis and cerebellar ataxia. Ann. intern. Med. 82: 367-371.

HABERKORN, A. 1970. Zur Empfänglichkeit nicht spezifischer Wirte für Schizogonie-Stadien verschiedener Eimeria-Arten. Z. ParasitKde 35: 156-161.

HABERKORN, A. 1971. Zur Wirtsspezifität von Eimeria contorta n. sp. (Sporozoa: Eimeriidae). Z. ParasitKde 37: 303-314.

HAFEZ, M. 1941a. Investigations into the problem of fly control in Egypt. Bull. Soc. Fouad. I. Ent. 25: 99-144.

HAFEZ, M. 1941b. A study of the biology of the Egyptian common house-fly: Musca vicina Macq. [Diptera : Muscidae]. Bull. Soc. Fouad. I. Ent. 25: 163-190.

HAMMER, O. 1941. Biological and ecological investigations on flies associated with pasturing cattle and their excrement. Vidensk. Meddr dansk naturh. Foren. 105: 141-394.

HARDING, J.D.J., BEVERLEY, J.K.A., SHAW, I.G., EDWARDS, B.L. & BENNETT, G.H. 1961. Toxoplasma in English pigs. Vet. Rec. 73: 3-6.

HARDING, R.S. 1973. Predation by a troop of olive baboons (Papio anubis). Am. J. phys. Anthrop. 38: 587-592.

HARRIS, A.H. & DOWN, H.A. 1946. Studies of the dissemination of cysts and ova of human intestinal parasites by flies in various localities on Guam. Am. J. trop. Med. 26: 789-800.

HARTLEY, W.J. & BLAKEMORE, W.F. 1974. An unidentified sporozoan encephalomyelitis in sheep. Vet. Path. 11: 1-12.

HARTLEY, W.J. & BRIDGE, P.S. 1975. A case of suspected congenital Toxoplasma encephalomyelitis in a lamb associated with a spinal cord anomaly. Br. vet. J. 131: 380-384.

HARTLEY, W.J. & MOYLE, G.G. 1974. Further observations on the epidemiology of ovine Toxoplasma infection. Aust. J. exp. Biol. med. Sci. 52: 647-653.

HARTLEY, W.J. & MUNDAY, B.L. 1974. Felidae in the dissemination of toxoplasmosis to man and other animals. Aust. vet. J. 50: 224-228.

HEINZ, H.J. & BRAUNS, W. 1955. The ability of flies to transmit ova of Echinococcus granulosus to human foods. S. Afr. J. med. Sci. 20: 131-132.

HENDRICKS, L.D. 1974. A redescription of Isospora arctopitheci Rodhain, 1933 (Protozoa: Eimeriidae) from Primates of Panama. Proc. helminth. Soc. Wash. 41: 229-233.

HENDRICKS, L.D. & WALTON, B.C. 1974. Vertebrate intermediate hosts in the life cycle of an isosporan from a non-human primate. Proc. 3rd int. Congr. Parasit. (Munich) 1: 96-97.

HENRY, D.P. 1932. Isospora buteonis sp. nov. from the hawk and owl, and notes on Isospora lacazii (Labbé) in birds. Univ. Calif. Publs Zool. 37: 291-300.

HEYDORN, A.-O. 1973. Zum Lebenszyklus der kleinen Form von Isospora bigemina des Hundes. 1. Rind und Hund als mögliche Zwischenwirte. Berl. Münch. tierärztl. Wschr. 86: 323-329.

HEYDORN, A.-O., IPCZYNSKI, V., MUHS, E.O. & GESTRICH, R. 1974. Zystenstadien aus der Muskulatur von Isospora hominis-infizierten Kälbern. Berl. Münch. tierärztl. Wschr. 87: 278.

HEYDORN, A.-O., MEHLHORN, H. & GESTRICH, R. 1975. Licht- und elektronenmikroskopische Untersuchungen an Cysten von Sarcocystis fusiformis in der Muskulatur von Kälbern nach experimenteller Infektion mit Oocysten und Sporocysten von Isospora hominis Railliet et Lucet, 1891. 2. Die Feinstruktur der Metrocyten und Merozoiten. Zentbl. Bakt. ParasitKde (Abt. I; Orig.) 232: 373-391.

HEYDORN, A.-O. & ROMMEL, M. 1972a. Beiträge zum Lebenszyklus der Sarkosporidien. II. Hund und Katze als Überträger der Sarkosporidien des Rindes. Berl. Münch. tierärztl. Wschr. 85: 121-123.

HEYDORN, A.-O. & ROMMEL, M. 1972b. Beiträge zum Lebenszyklus der Sarkosporidien. IV. Entwicklungsstadien von S. fusiformis in der Dunndarmschleimhaut der Katze. Berl. Münch. tierärztl. Wschr. 85: 333-336.

HILGENFELD, M. & PUNKE, G. 1974. Zur Sarkosporidieninfektion des Zentralnervensystems des Schafes, ein Beitrag zur Differentialdiagnose von Protozoeninfektionen. Arch. exp. VetMed. 28: 621-626.

HINDLE, E. & MERRIMAN, G. 1913. The range of flight of Musca domestica. Report upon experiments. Rep. loc. Govt Bd publ. Hlth, new ser., no. 85: 20-41.

HITCHCOCK, D.J. 1955. The life cycle of Isospora felis in the kitten. J. Parasit. 41: 383-397.

HOARE, C.A. 1972. The developmental stages of Toxoplasma. J. trop. Med. Hyg. 75: 56-58.

HOELSCHER, C.E., COMBS, R.L., Jr & BRAZZEL, J.R. 1968. Horn fly dispersal. J. econ. Ent. 61: 370-373.

HOGAN, M.J. 1975. Child with congenital ocular toxoplasmosis: no treatment of mother needed. J. Am. med. Ass. 232: 1168-1169.

HSU, C-K., & MELBY, E.C., Jr. 1974. Isospora callimico n sp, (Coccidia: Eimeriidae) from Goeldi's marmoset (Callimico goeldii). Lab. Anim. Sci. 24: 476-479.

HUSSEY, H.H. 1975. Toxoplasmosis of the central nervous system. J. Am. med. Ass. 232: 743.

HUTCHISON, W.M., DUNACHIE, J.F., SIIM, J. CHR. & WORK, K. 1969. Life cycle of Toxoplasma gondii. Br. med. J. 4: 806.

HUTCHISON, W.M., DUNACHIE, J.F., SIIM, J. CHR. & WORK, K. 1970. Coccidian-like nature of Toxoplasma gondii. Br. med. J. 1: 142-144.

HUTCHISON, W.M., DUNACHIE, J.F., WORK, K. & SIIM, J. CHR. 1971. The life cycle of the coccidian parasite, Toxoplasma gondii, in the domestic cat. Trans. R. Soc. trop. Med. Hyg. 65: 380-399.

HYDE, B., BARNETT, E.V. & REMINGTON, J. 1975. Method for differentiation of nonspecific from specific Toxoplasma IgM fluorescent antibodies in patients with rheumatoid factor. Proc. Soc. exp. Biol. Med. 148: 1184-1188.

INTERNATIONAL COMMISSION ON ZOOLOGICAL NOMENCLATURE. 1964. International code of zoological nomenclature adopted by the XV international congress of zoology. International Trust for Zoological Nomenclature, London.

*ITO, S., TSUNODA, K., NICHIKAWA, H. & MATSUI, T. 1974. Pathogenicity for piglets for Toxoplasma oocysts originated from naturally infected cat. Natn. Inst. Anim. Hlth Q., Tokyo 14: 182-187.

JACOBS, L. 1956. Propagation, morphology and biology of Toxoplasma. Ann. N.Y. Acad. Sci. 64: 154-179.

JACOBS, L. 1967. Toxoplasma and toxoplasmosis. Adv. Parasit. 5: 1-45.

JACOBS, L. & HARTLEY, W.J. 1964. Ovine toxoplasmosis: studies on parasitaemia, tissue infection, and congenital transmission in ewes infected by various routes. Br. vet. J. 120: 347-364.

JACOBS, L. & JONES, F.E. 1950. The parasitemia in experimental toxoplasmosis. J. infect. Dis. 87: 78-89.

---

* Not seen by author. Abstracted in Tropical Diseases Bulletin, July 1975.

JACOBS, L., REMINGTON, J.S. & MELTON, M.L. 1960. The resistance of the encysted form of Toxoplasma gondii. J. Parasit. 46: 11-21.

JADIN, J.B. & WILLAERT, E. 1970. L'analogie morphologique des sporozoaires pose le problème de leur parenté antigénique. Protistologica 4: 477-480.

JANITSCHKE, K. & KÜHN, D. 1972. Toxoplasma-Oozysten im Kot natürlich infizierter Katzen. Berl. Münch. tierärztl. Wschr. 85: 46-47.

JANITSCHKE, K. & WERNER, H. 1972. Untersuchungen über die Wirtsspezifität des geschlechtlichen Entwicklungszyklus von Toxoplasma gondii. Z. ParasitKde 39: 247-254.

JAUSION, H. & DEKESTER, M. 1923. Sur la transmission comparée des kystes d'Entamoeba dysenteriae et de Giardia intestinalis par les mouches. Archs Inst. Pasteur Alger. 1: 154-155.

JEFFERIES, D.J. 1974. Earthworms in the diet of the red fox (Vulpes vulpes). J. Zool., Lond. 173: 251-252.

JEFFREY, H.C. 1974. Sarcosporidiosis in man. Trans. R. Soc. trop. Med. Hyg. 68: 17-29.

JEWELL, M.L., FRENKEL, J.K., JOHNSON, K.M., REED, V. & RUIZ, A. 1972. Development of Toxoplasma oocysts in neotropical Felidae. Am. J. trop. Med. Hyg. 21: 512-517.

JOHNSON, A.J., HILDEBRANDT, P.K. & FAYER, R. 1975. Experimentally induced Sarcocystis infection in calves: pathology. Am. J. vet. Res. 36: 995-999.

JONES, T.C. 1974. Congenital toxoplasmosis. New Engl. J. Med. 291: 365.

JOYNER, L.P. 1975. Toxoplasma in dogs and cats. Vet. Rec. 97: 39.

KALINER, G. 1975. Observations on the histomorphology of sarcosporidian cysts of some East African game animals (Artiodactyla). Z. ParasitKde 46: 13-23.

KALINER, G., GROOTENHUIS, J.G. & PROTZ, D. 1974. A survey for sarcosporidial cysts in East African game animals. J. Wildl. Dis. 10: 237-238.

KALINER, G., SACHS, R., FAY, L.D. & SCHIEMANN, B. 1971. Untersuchungen über das Vorkommen von Sarcosporidien bei ostafrikanischen Wildtieren. Tropenmed. Parasit. 22: 156-164.

KARIM, K.A. & LUDLAM, G.B. 1975a. The relationship and significance of antibody titres as determined by various serological methods in glandular and ocular toxoplasmosis. J. clin. Path. 28: 42-49.

KARIM, K.A. & LUDLAM, G.B. 1975b. Serological diagnosis of congenital toxoplasmosis. J. clin. Path. 28: 383-387.

KAUFMAN, G.I., REMINGTON, J.S. & WATERS, H.C. 1973. Automation of the indirect fluorescent-antibody test for toxoplasmosis. Appl. Microbiol. 25: 724-730.

KEELING, M.E. & McCLURE, H.M. 1974. Pneumococcal meningitis and fatal enterobiasis in a chimpanzee. Lab. Anim. Sci. 24: 92-95.

KILLOUGH, R.A., HARTSOCK, J.G., WOLF, W.W. & SMITH, J.W. 1965. Face fly dispersal, nocturnal resting places, and activity during sunset as observed in 1963. J. econ. Ent. 58: 711-715.

KIM, C.S., EUGSTER, A.K. & KALTER, S.S. 1968. Pathologic study of the African Baboon (Papio sp.) in his native habitat. Primates 9: 93-104.

KLOPFER, U., NOBEL, T.A. & NEUMANN, F. 1973. Hepatozoon-like parasite (schizonts) in the myocardium of the domestic cat. Vet. Path. 10: 185-190.

KNOTTENBELT, D.C. 1974. An investigation into the incidence and pathology of natural trypanosomiasis of bushbuck (Tragelaphus scriptus) and kudu (T. strepsiceros). Trop. Anim. Hlth Prod. 6: 131-143.

KROGSTAD, D.J., JURANEK, D.D. & WALLS, K.W. 1972. Toxoplasmosis. With comments on risk of infection from cats. Ann. intern. Med. 77: 773-778.

KÜHN, D., OPPERMANN, W.H., RÖDEL, H. & CENTURIER, H. 1972. Experimentelle Infektion von Hunden mit Toxoplasma-Oozysten. Berl. Münch. tierärztl. Wschr. 85: 309-314.

KÜHN, D., WARNECKE, M. & CENTURIER, H. 1973. Untersuchungen über die Möglichkeit der Ausscheidung von Toxoplasmen in Sekreten und Exkreten nach oraler Infektion mit Toxoplasma-Zysten und -Oozysten bei der Katze. Berl. Münch. tierärztl. Wschr. 86: 69-72.

KULASIRI, C. 1960. The specificity of the Sabin-Feldman dye test with reference to protozoal infections. J. clin. Path. 13: 339-348.

KUNTZ, R.E. & MOORE, J.A. 1973. Commensals and parasites of African Baboons (Papio cynocephalus L. 1766) captured in Rift Valley province of central Kenya. J. med. Primat. 2: 236-241.

LAARMAN, J.J. & MAS BAKAL, P. 1971. Proc. 1er multicolloque européen de parasitologie (Rennes): 276-278.

LAARMAN, J.J., TADROS, W. & VAN DEN EIJK, A. 1974. Sero-epidemiological observations involving human coccidiosis. Unpublished paper read at the 3rd Int. Congr. Parasit. (Munich).

LAGE, H.A., LAGE, S.A. & LOBO, M.E. 1974. Cross-infection experiments with "Isospora" of cats and dogs. Mems. Inst. Oswaldo Cruz 72: 137-142.

LAI, C.H., TIZARD, I.R. & INGRAM, D.G. 1975. The protective effect of a milk diet on Toxoplasma gondii infection in mice. Can. J. comp. Med. 39: 191-193.

LAINSON, R. 1972. A note on sporozoa of undetermined taxonomic position in an armadillo and a heifer calf. J. Protozool. 19: 582-586.

LANDAU, I. 1973a. A comparison of the life cycles of Toxoplasma and Hepatozoon, with reference to the general phenomenon and the role of cyst formation in the Coccidia. Ann. trop. Med. Parasit. 67: 403-407.

LANDAU, I. 1973b. Diversité des mécanismes assurant la pérennité de l'infection chez les sporozoaires coccidiomorphes. Mém. Mus. natn. Hist. nat., Paris. ser. A, 77: 1-62.

LANDAU, I., MICHEL, J.C., CHABAUD, A.G. & BRYGOO, E.R. 1972. Cycle biologique d'Hepatozoon domerguei; discussion sur les caractères fondamentaux d'un cycle de Coccidie. Z. Parasit-Kde 38: 250-270.

LEMPKE, B.J. 1962. Insecten gevangen op het lichtschip „Noord Hinder". Ent. Ber., Amst. 22: 101-111.

LEPP, D.L. & TODD, K.S., Jr. 1974. Life cycle of Isospora canis Nemeséri, 1959 in the dog. J. Protozool. 21: 199-206.

LEVINE, N.D. & IVENS, V. 1965a. The coccidian parasites (Protozoa, Sporozoa) of rodents. Illinois biol. Monogr. no. 33.

LEVINE, N.D. & IVENS, V. 1965b. Isospora species in the dog. J. Parasit. 51: 859-864.

LEVINE, N.D. & IVENS, V. 1970. The coccidian parasites (Protozoa, Sporozoa) of ruminants. Illinois biol. Monogr. no. 44.

LICKFELD, K.G. 1959. Untersuchungen über das Katzencoccid Isospora felis (Wenyon 1923). Arch. Protistenk. 103: 427-456.

LINDQUIST, A.W., YATES, W.W. & HOFFMAN, R.A. 1951. Studies of the flight habits of three species of flies tagged with radioactive phosphorus. J. econ. Ent. 44: 397-400.

LONG, P.L. 1970. Development (schizogony) of Eimeria tenella in the liver of chickens treated with corticosteroid. Nature 225: 290-291.

LONG, P.L. 1971. Schizogony and gametogony of Eimeria tenella in the liver of chick embryos. J. Protozool. 18: 17-20.

LONG, P.L. & ROSE, M.E. 1970. Extended schizogony of Eimeria mivati in betamethasone-treated chickens. Parasitology 60: 147-155.

LOTZE, J.C. & LEEK, R.G. 1970. Failure of development of the sexual phase of Eimeria intricata in heavily inoculated sheep. J. Protozool. 17: 414-417.

LOTZE, J.C., SHALKOP. W.T., LEEK, R.G. & BEHIN, R. 1964. Coccidial schizonts in mesenteric lymph nodes of sheep and goats. J. Parasit. 50: 205-208.

LUDLAM, G.B. & KARIM, K.A. 1975. Diagnosis of toxoplasmosis. Br. med. J. 2: 445.

LUDVÍK, J. 1963. Electron microscopic study of some parasitic protozoa. Prog. Protozool. 1: 387-392.

LUENGO, M., ARATA, N. & LUENGO, J. 1974. Hallazgo de sarcosporidio en cerebelo de bovino. Boln chil. Parasit. 29: 39-41.

LUND, E.E. 1970. Means of acquisition of certain intestinal parasites of poults. J. Parasit. 56(4), sect. 2, part 1: 217-218.

LUNDE, M.N. & JACOBS, L. 1965. Antigenic relationship of Toxoplasma gondii and Besnoitia jellisoni. J. Parasit. 51: 273-276.

McCONNELL, E.E., BASSON, P.A., DE VOS, V., MYERS, B.J. & KUNTZ, R.E. 1974. A survey of diseases among 100 free-ranging baboons (Papio ursinus) from the Kruger National Park. Onderstepoort J. vet. Res. 41: 97-168.

McCONNELL, E.E., BASSON, P.A., THOMAS, S.E. & DE VOS, V. 1972. Oocysts of Isospora papionis in the skeletal muscles of Chacma Baboons. Onderstepoort J. vet. Res. 39: 113-116.

McCONNELL, E.E., BASSON, P.A., WOLSTENHOLME, B., DE VOS, V. & MALHERBE, H.H. 1973. Toxoplasmosis in free-ranging Chacma Baboons (Papio ursinus) from the Kruger National Park. Trans. R. Soc. trop. Med. Hyg. 67: 851-855.

McCONNELL, E.E., DE VOS, A.J., BASSON, P.A. & DE VOS, V. 1971. Isospora papionis n. sp. (Eimeriidae) of the Chacma Baboon Papio ursinus (Kerr, 1972). J. Protozool. 18: 28-32.

McCRACKEN, A.W. 1972. Natural and laboratory-acquired infection by Isospora belli. Sth. med. J., Nashville 65: 800 and 818.

McCULLY, R.M., BASSON, P.A., DE VOS, V. & DE VOS, A.J. 1970. Uterine coccidiosis of the impala caused by Eimeria neitzi spec. nov. Onderstepoort J. vet. Res. 37: 45-58.

McERLEAN, B.A. 1974. Ovine paralysis associated with spinal lesions of toxoplasmosis. Vet. Rec. 94: 264-266.

McGILL, R.J. & GOODBODY, R.A. 1957. Sarcosporidiosis in man with periarteritis nodosa. Br. med. J. 2: 333-334.

MacLEOD, J. & DONNELLY, J. 1958. Local distribution and dispersal paths of blowflies in hill country. J. Anim. Ecol. 27: 349-374.

MacLEOD, J. & DONNELLY, J. 1960. Natural features and blowfly movement. J. Anim. Ecol. 29: 85-93.

McLOUGHLIN, D.K. 1969. The influence of dexamethasone on attempts to transmit Eimeria meleagrimitis to chickens and E. tenella to turkeys. J. Protozool. 16: 145-148.

MAHRT, J.L. 1967. Endogenous stages of the life cycle of Isospora rivolta in the dog. J. Protozool. 14: 754-759.

MAHRT, J.L. 1973. Sarcocystis in dogs and its probable transmission from cattle. J. Parasit. 59: 588-589.

MANDOUR, A.M. 1965a. Studies on Sarcocystis with special reference to its life history in rodents. Unpublished Ph.D. thesis, University of London.

MANDOUR, A.M. 1965b. Pathology and symptomatology of Sarcocystis infection in man. Trans. R. Soc. trop. Med. Hyg. 59: 432-435.

MANDOUR, A.M. 1969. Sarcocystis nebitti n. sp. from the rhesus monkey. J. Protozool. 16: 353-354.

MANDOUR, A.M. 1971. Fine structure of Sarcocystis kortei Castellani and Chalmers, 1909 from a Rhesus monkey Macaca mulatta. J. Egypt. Soc. Parasit. 1: 29-37.

MANDOUR, A.M. 1972a. Electron microscopic studies on Sarcocystis sp. in the harsh-furred rat, Lophuromys flavopunctatus from Malawi (Kenya) (sic!). Proceedings of the first scientific symposium of rodents and their control in Egypt: 123-127. General Organisation for Government Printing Offices, Cairo.

MANDOUR, A.M. 1972b. Sarcocystis infection in some African rodents. Proceedings of the first scientific symposium of rodents and their control in Egypt: 119-121. General Organisation for Government Printing Offices. Cairo.

MANDOUR, A.M. & KEYMER, I.F. 1970. Sarcocystis infection in African antelopes. Ann. trop. Med. Parasit. 64: 513-523.

MANDOUR, A.M. & KEYMER, I.F. 1972. A protozoan parasite of uncertain nature in Kemp's vlei rat, (Otomys kempi, Dollman, 1915) from Zambia (Northern Rhodesia). Proceedings of the first scientific symposium of rodents and their control in Egypt: 129-133. General Organisation for Government Printing Offices, Cairo.

MARC, Y., FLEURY, H. & MARC, J. 1974. La sérologie de la toxoplasmose est-elle enfin réalisable a grande échelle? Bordeaux med. 7: 265-272.

MARINKELLE, C.J. 1969. "Isospora cebi" sp. n. aislada de un mico de Colombia ("Cebus albifrons"). Revta bras. Biol. 29: 35-40.

MARKUS, M.B. 1967. Secondary intergradation amongst bulbuls of the genus Pycnonotus in the Transvaal Province, South Africa. Bull. Br. Orn. Club 87: 17-23.

MARKUS, M.B. 1968. Plumage and reproductive condition in the masked weaver Ploceus velatus Vieillot. Revue Zool. Bot. afr. 78: 107-112.

MARKUS, M.B. 1972. Diagnosis of isoporosis and toxoplasmosis. Trans. R. Soc. trop. Med. Hyg. 66: 673-674.

MARKUS, M.B. 1973a. Symptoms, transmission, prevention and treatment of toxoplasmosis. S. Afr. med. J. 47: 1588-1590.

MARKUS, M.B. 1973b. Sarcosporidiosis in healthy cattle. Meat Hyg. 4: 24-25.

MARKUS, M.B. 1973c. Gametogony of Isospora-type coccidia. Trans. R. Soc. trop. Med. Hyg. 67: 7-8.

MARKUS, M.B. 1973d. Serology of toxoplasmosis, isosporosis and sarcosporidiosis. New Engl. J. Med. 289: 980-981.

MARKUS, M.B. 1974a. Earthworms and coccidian oocysts. Ann. trop. Med. Parasit. 68: 247-248.

MARKUS, M.B. 1974b. Birds, coprophagous arthropods and coccidian oocysts. Proc. 3rd int. Congr. Parasit. (Munich) 1: 98-99.

MARKUS, M.B. 1974c. Serology of human sarcosporidiosis. Trans. R. Soc. trop. Med. Hyg. 68: 415-416.

MARKUS, M.B. 1975. Coccidia related to Toxoplasma gondii: possible zoonoses. S. Afr. med. J. 49: 1905.

MARKUS, M.B., DRAPER, C.C., HUTCHISON, W.M., KILLICK-KENDRICK, R. & GARNHAM, P.C.C. 1974. Attempted infection of chimpanzees and cats with Sarcocystis of cattle. Trans. R. Soc. trop. Med. Hyg. 68: 3.

MARKUS, M.B., KILLICK-KENDRICK, R. & GARNHAM, P.C.C. 1974. The coccidial nature and life-cycle of Sarcocystis. J. trop. Med. Hyg. 77: 248-259.

MARQUARDT, W.C. 1966. Attempted transmission of the rat coccidium Eimeria nieschulzi to mice. J. Parasit. 52: 691-694.

MARTÍNEZ-FERNÁNDEZ, A., SELA, M. & PEREIRO, A. 1975. Some facts relating to the diagnosis and biology of Sarcocystis spp. 2nd European Multicolloquy of Parasitology, Trogir (summaries of papers read): 15-16. Društvo Parazitologa Jugoslavije, Beograd.

MASON, P.R., JACOBS, M.R. & FRIPP, P.J. 1974. Serological survey of toxoplasmosis in the Transvaal. S. Afr. med. J. 48: 1707-1709.

MAYBERRY, L.F. & MARQUARDT, W.C. 1973. Transmission of Eimeria separata from the normal host, Rattus, to the mouse, Mus musculus. J. Parasit. 59: 198-199.

MAYBERRY, L.F., PLAN, B., NASH, D.J. & MARQUARDT, W.C. 1975. Genetic dependence of coccidial transmission from rat to mouse. J. Protozool. 22: 28A.

MEHLHORN, H. 1975. Elektronenmikroskopischer Nachweis von alkalischer Phosphatase und ATP-ase in Cystenstadien von Sarcocystis tenella (Sporozoa, Coccidia) aus der Schlundmuskulatur von Schafen. Z. ParasitKde 46: 95-109.

MEHLHORN, H., HEYDORN, A.-O. & GESTRICH, R. 1975a. Licht- und elektronenmikroskopische Untersuchungen an Cysten von Sarcocystis fusiformis in der Muskulatur von Kälbern nach experimenteller Infektion mit Oocysten und Sporocysten von Isospora hominis Railliet et Lucet, 1891. 1. Zur Entstehung der Cyste und der Cystenwand. Zentbl. Bakt. ParasitKde (Abt. I; Orig) 231: 301-322.

MEHLHORN, H., HEYDORN, A.-O. & GESTRICH, R. 1975b. Licht- und elektronenmikroskopische Untersuchungen an Cysten von Sarcocystis fusiformis in der Muskulatur von Kälbern nach experimenteller Infektion mit Oocysten und Sporocysten der grossen Form von Isospora bigemina des Hundes 1. Zur Entstehung der Cyste und der „Cystenwand". Zentbl. Bakt. ParasitKde (Abt. I; Orig) 232: 392-409.

MEHLHORN, H. & SCHOLTYSECK, E. 1973. Elektronenmikroskopische Untersuchungen an Cystenstadien von Sarcocystis tenella aus der Oesophagus-Muskulatur des Schafes. Z. ParasitKde 41: 291-310.

MEHLHORN, H. & SCHOLTYSECK, E. 1974a. Die Parasit-Wirtsbeziehungen bei verschiedenen Gattungen der Sporozoen (Eimeria, Toxoplasma, Sarcocystis, Frenkelia, Hepatozoon, Plasmodium und Babesia) unter Anwendung spezieller Verfahren. Microsc. acta 75: 429-451.

MEHLHORN, H. & SCHOLTYSECK, E. 1974b. Licht- und elektronenmikroskopische Untersuchungen an Entwicklungsstadien von Sarcocystis tenella aus der Darmwand der Hauskatze. Z. ParasitKde 43: 251-270.

MEHLHORN, H., SCHOLTYSECK, E. & SÉNAUD, J. 1974. Transmission de Sarcocystis tenella, chez le chat, à partir des formes kystiques parasites intramusculaires du Mouton: les oocystes et les sporocystes et microscopie photonique et électronique. C. r. hebd. Séanc. Acad. Sci., Paris, (D) 273: 1111-1114.

MEHLHORN, H. & SÉNAUD, J. 1975. Action lytique des bactéries présentes dans les kystes de Sarcocystis tenella (Sporozoa, Protozoa). Arch. Microbiol. 104: 241-244.

MEHLHORN, H., SÉNAUD, J., CHOBOTAR, B. & SCHOLTYSECK, E. 1975. Electron microscope studies of cyst stages of Sarcocystis tenella: the origin of micronemes and rhoptries. Z. ParasitKde 45: 227-236.

MEHLHORN, H., SÉNAUD, J. & SCHOLTYSECK, E. 1974. Étude ultrastructurale des coccidies formant des kystes: Toxoplasma gondii, Sarcocystis tenella, Besnoitia jellisoni et Frenkelia sp.: distribution de la phosphatase acide et des polysaccharides au niveau des ultrastructures chez le parasite et chez l'hote. Protistologica 10: 21-42.

MEIER, H., HOLZWORTH, J. & GRIFFITHS, R.C. 1957. Toxoplasmosis in the cat - fourteen cases. J. Am. vet. med. Ass. 131: 395-414.

METELKIN, A. 1935. The rôle of flies in the spread of coccidiosis in animals and men. Medskaya Parazit. 4: 75-82.

MIHÁLYI, F. 1966. Flies visiting fruit and meat in an open-air market in Budapest. Acta zool., hung. 12: 331-337.

MILLER, M.J., ARONSON, W.J. & REMINGTON, J.S. 1969. Late parasitemia in asymptomatic acquired toxoplasmosis. Ann. intern. Med. 71: 139-145.

MILLER, N.L., FRENKEL, J.K. & DUBEY, J.P. 1972. Oral infections with Toxoplasma cysts and oocysts in felines, other mammals, and in birds. J. Parasit. 58: 928-937.

MOULINIER, C., COUPRIE, B. & MANDOUL, R. 1974. Plaidoyer pour prospection serologique prenuptiale de la toxoplasmose. Bordeaux med. 7: 249-256.

MUGERA, G.M. 1968. Sarcosporidiosis in gazelles in Kenya. E. Afr. Wildl. J. 6: 139-140.

MÜHLPFORDT, H. 1951. Das Verhalten Sarkosporidien-infizierter Tiere im Sero-Farbtest auf Toxoplasmose nach Sabin und Feldman. Z. Tropenmed. Parasit. 3: 205-215.

MUKHERJEA, A.K. & KRASSNER, S.M. 1965. A new species of Coccidia [Protozoa: Sporozoa] of the genus Isospora Schneider, 1881, from the jackal, Canis aureus Linnaeus. Proc. zool. Soc., Calcutta 18: 35-40.

MUNDAY, B.L. 1972a. Serological evidence of Toxoplasma infection in isolated groups of sheep. Res. vet. Sci. 13: 100-102.

MUNDAY, B.L. 1972b. Transmission of Toxoplasma infection from chronically infected ewes to their lambs. Br. vet. J. 128: lxxi-lxxii.

MUNDAY, B.L., BARKER, I.K. & RICKARD, M.D. 1975. The developmental cycle of a species of Sarcocystis occurring in dogs and sheep, with observations on pathogenicity in the intermediate host. Z. ParasitKde 46: 111-123.

MUNDAY, B.L. & CORBOULD, A. 1974. The possible role of the dog in the epidemiology of ovine sarcosporidiosis. Br. vet. J. 130: ix-xi.

MUNDAY, B.L. & RICKARD, M.D. 1974. Is Sarcocystis tenella two species? Aust. vet. J. 50: 558-559.

MURAI, É. & TENORA, FR. 1973. Some taeniid species (Cestoidea) parasitizing vertebrates (Rodentia, Carnivora, Strigiformes) in Hungary. Acta zool. hung. 19: 125-132.

MURVOSH, C.M. & THAGGARD, C.W. 1966. Ecological studies of the house fly. Ann. ent. Soc. Am. 59: 533-547.

NAKAYAMA, I. 1974. Two modes of morphological changes of cyst found in the brain of mice chronically infected with Beverley strain of Toxoplasma gondii. Jap. J. med. Sci. Biol. 27: 263-268.

NASH, J.T.C. 1913. Range of flight of Musca domestica. Lancet 2: 1585-1586.

NERY-GUIMARÃES, F. & LAGE, H.A. 1973. Produção irregular e inconstante de oocistos pela ministração de cistos de "Toxoplasma gondii" Nicolle & Manceaux, 1909, em gatos. Mems. Inst. Oswaldo Cruz 71: 157-167.

NEUFELD, J.L. & BRANDT, R.W. 1974. Cholangiohepatitis in a cat associated with a coccidia-like organism. Can. vet. J. 15: 156-159.

NICOLL, W. 1911. On the part played by flies in the dispersal of the eggs of parasitic worms. Rep. loc. Govt Bd publ. Hlth new ser., no. 53: 13-30.

NIESCHULZ, O. 1935. Über Coccidien der Schleiereule. Zentbl. Bakt. ParasktKde (Abt II) 92: 279-280.

NORRIS, K.R. 1959. The ecology of sheep blowflies in Australia. Monographiae biol. 8: 514-544.

OVERDULVE, J.P. 1970. The identity of Toxoplasma Nicolle & Manceaux, 1909 with Isospora Schneider, 1881. Proc. K. med. Akad. Wet. 73, ser. c, no. 1: 129-151.

OWEN, D. & CASILLO, S. 1973. A preliminary survey of the nematode parasites of some imported Old-World monkeys. Lab. Anim. 7: 265-269.

PAMPIGLIONE, S., POGLAYEN, G., ARNONE, B. & DE LALLA, F. 1973. Toxoplasma gondii oocysts in the faeces of naturally infected cat. Br. med. J. 2: 306.

*PANASYUK, D.I., MINTYUGOV, V.N., PYATOV, M.V., ZYABLOV, A.A. & GOLOVIN, V.G. 1971. Toward a species preference in Sarcosporidia. (In Russian). Veterinariya no. 4: 65-67.

PARLE, J.N. 1963. Micro-organisms in the intestines of earthworms. J. gen. Microbiol. 31: 1-11.

PENKERT, R.A. 1973. Possible spread of toxoplasmosis by feed contaminated by cats. J. Am. vet. med. Ass. 162: 924.

PEPPLER, H.J. 1944. Usefulness of microorganisms in studying dispersion of flies. Bull. U.S. Army med. Dep., no. 75: 121-122.

PETERSON, D.R., COONEY, M.K. & BEASLEY, R.P. 1974. Prevalence of antibody to Toxoplasma among Alaskan natives: relation to exposure to the Felidae. J. infect. Dis. 130: 557-563.

PETERSON, D.R., TRONCA, E. & BONIN, P. 1972. Human toxoplasmosis prevalence and exposure to cats. Am. J. Epidem. 96: 215-218.

PETESHEV, V.M., GALUZO, I.G. & POLOMOSHNOV, A.P. 1974. Koshki-definitivnye khozyaeva besnoitii (Besnoitia besnoiti). Izv. Akad. Nauk. kazakh. SSR (Seria Biologicheskaya) 1: 33-38.

PIEKARSKI, G. & SAATHOFF, M. 1962. Vergleichende serologische Untersuchungen mit Sarcosporidien- und Toxoplasma-antigenen. Z. ParasitKde 21: 363-380.

PIEKARSKI, G. & WITTE, H.M. 1971. Experimentelle und histologische Studien zur Toxoplasma-Infektion der Hauskatze. Z. ParasitKde 36: 95-121.

---

*Original not seen (from translation No. 43 of the College of Veterinary Medicine, University of Illinois, edited by Norman D. Levine).

PIPKIN, A.C. 1949. Experimental studies on the role of filth flies in the transmission of Endamoeba histolytica. Am. J. Hyg. 49: 255-275.

PLANT, J.W., RICHARDSON, N. & MOYLE, G.G. 1974. Toxoplasma infection and abortion in sheep associated with feeding of grain contaminated with cat faeces. Aust. vet. J. 50: 19-21.

PŁOTKOWIAK, J. 1975. Problems of Isospora hominis (Railliet et Lucet, 1891) infection in Poland. 2nd European Multicolloquy of Parasitology, Trogir (summaries of papers read): 5. Društvo Parazitologa Jugoslavije, Beograd.

POELMA, F.G. 1966. Eimeria lemuris n. sp., E. galago n. sp. and E. otolicni n. sp. from a galago Galago senegalensis. J. Protozool. 13: 547-549.

POELMA, F.G. & ZWART, P. 1972. Toxoplasmose bij kroonduiven en andere vogels in de koninklijke Rotterdamse diergaarde "blijdorp". Acta zool. path. antverp. no. 55: 29-40.

PORCHET-HENNERÉ, E. 1975. Quelques précisions l'ultrastructure de Sarcocystis tenella. I. L'endozoite (après coloration négative). J. Protozool. 22: 214-220.

PORCHET-HENNERÉ, E. & PONCHEL, M.G. 1974. Quelques précisions sur l'ultrastructure de Sarcocystis tenella: l'architecture du kyste et l'aspect des endozoïtes en microscopie électronique à balayage. C. r. Acad. Sci., Paris 279, ser. D: 1179-1181.

PORTER, J.A., Jr. 1972. Parasites of marmosets. Lab. Anim. Sci. 22: 503-506.

PRATHAP, K. 1973. Sarcocystis in the Malaysian long-tailed monkey, Macaca irus. Trans. R. Soc. trop. Med. Hyg. 67: 615.

PRICE, J.H. 1969. Toxoplasma infection in an urban community. Br. med. J. 4: 141-143.

PUROHIT, S.K. & D'SOUZA, B.A. 1973. An investigation into the mode of transmission of sarcosporidiosis. Br. vet. J. 129: 230-235.

QUATERMAN, K.D., MATHIS, W. & KILPATRICK, J.W. 1954. Urban fly dispersal in the area of Savannah, Georgia. J. econ. Ent. 47: 405-412.

REMINGTON, J.S. & ARAUJO, F.G. 1974. Immunological tolerance to Toxoplasma gondii. Proc. 3rd int. Congr. Parasit. (Munich) 1: 294.

REMINGTON, J.S. & DESMONTS, G. 1973. Congenital toxoplasmosis: variability in the IgM-fluorescent antibody response and some pitfalls in diagnosis. J. Pediat. 83: 27-30.

RIEMANN, H.P., BRANT, P.C., FRANTI, C.E., REIS, R., BUCHANAN, A.M., STORMONT, C. & BEHYMER, D.E. 1974. Antibodies to Toxoplasma gondii and Coxiella burneti among students and other personnel in veterinary colleges in California and Brazil. Am. J. Epidem. 100: 197-208.

RIFAAT, M.A., NASR, N.T., SADEK, M.S.M., ARAFA, M.S. & MAHDI, A.H. 1973. The role of the domestic rat, Rattus alexandrinus as a reservoir host of Toxoplasma gondii in Egypt. J. trop. Med. Hyg. 76: 257-258.

RIJPSTRA, A.C. 1967. Sporocysts of Isospora sp. in a chimpanzee (Pan troglodytes, L.). Proc. K. ned. Akad. Wet., (C) 70: 395-401.

ROBERTS, E.W. 1947. The part played by the faeces and vomit-drop in the transmission of Entamoeba histolytica by Musca domestica. Ann. trop. Med. Parasit. 41: 129-142.

RODHAIN, J. 1933. Sur une coccidie de l'intestin de l'ouistiti: Hapale jacchus penicillatus (Geoffroy). C. r. Soc. Biol. 114: 1357-1358.

ROMMEL, M. 1975. Neue Erkenntnisse zur Biologie der Kokzidien, Toxoplasmen, Sarkosporidien und Besnoitien. Berl. Münch. tierärztl. Wschr. 88: 112-117.

ROMMEL, M. & HEYDORN, A.-O. 1972. Beiträge zum Lebenszyklus der Sarkosporidien. III. Isospora hominis (Railliet und Lucet, 1891) Wenyon, 1923, eine Dauerform der Sarkosporidien des Rindes und des Schwins. Berl. Münch. tierärztl. Wschr. 85: 143-145.

ROMMEL, M. & HEYDORN, A.-O. 1973. Sarkosporidien von Rind, Schaf und Schwein in Hund, Katze und Mensch. Prog. Protozool. 4: 352.

ROMMEL, M. & HEYDORN, A.-O. 1974. Neue Erkenntnisse zur Epidemiologie der Sarkosporidiose bei Mensch und Tier. Fortschr. VetMed. 20: 104-106.

ROMMEL, M., HEYDORN, A.-O., FISCHULE, B. & GESTRICH, R. 1974. Beiträge zum Lebenszyklus der Sarkosporidien. V. Weitere Endwirte der Sarkosporidien von Rind, Schaf und Schwein und die Bedeutung des Zwischenwirtes für die Verbreitung dieser Parasitose. Berl. Münch. tierärztl. Wschr. 87: 392-396.

ROMMEL, M., HEYDORN, A.-O. & GRUBER, F. 1972. Beiträge zum Lebenszyklus der Sarkosporidien. I. Die Sporozyste von S. tenella in den Fäzes der Katze. Berl. Münch. tierärztl. Wschr. 85: 101-105.

ROMMEL, M. & KRAMPITZ, H.E. 1975. Beiträge zum Lebenszyklus der Frenkelien 1. Die Identität von Isospora buteonis aus dem Mäusebussard mit einer Frenkelienart (F. clethrionomyobuteonis spec. n.) aus der Rötelmaus. Berl. Münch. tierärztl. Wschr. 88: 338-340.

ROOT, F.M. 1921. Experiments on the carriage of intestinal protozoa of man by flies. Am. J. Hyg. 1: 131-153.

ROSE, M.E. 1970. Immunity to coccidiosis: effect of betamethasone treatment of fowls on Eimeria mivati infection. Parasitology 60: 137-146.

ROUND, M.C. 1961. Observations on the possible role of filth flies in the epizootiology of bovine cysticercosis in Kenya. J. Hyg., Camb. 59: 505-513.

ROWLAND, E. & VANDENBERGH, J.G. 1965. A survey of intestinal parasites in a new colony of rhesus monkeys. J. Parasit. 51: 294-295.

RUIZ, A., FRENKEL, J.K. & CERDAS, L. 1973. Isolation of Toxoplasma from soil. J. Parasit. 59: 204-206.

RZEPCZYK, C.M. 1974. Evidence of a rat-snake life cycle for Sarcocystis. Int. J. Parasit. 4: 447-449.

SAARI, M. & RAISÄNEN, S. 1974. Transmission of acute Toxoplasma infection. The survival of trophozoites in human tears, saliva, and urine and in cow's milk. Acta Ophthal. 52: 847-852.

SAAYMAN, G.S. 1971. Behaviour of adult males in a troop of free-ranging chacma baboons (Papio ursinus). Folia Primatol. 15: 36-57.

SASAKI, Y., IIDA, T., OOMURA, K., TSUTSUMI, Y., TSUNODA, K., ITO, S. & NISHIKAWA, H. 1974. Experimental Toxoplasma infection of pigs with oocysts of Isospora bigemina of feline origin. Jap. J. vet. Sci. 36: 459-465.

SCHOLTYSECK, E. 1954. Untersuchungen über die bei einheimischen Vogellarten vorkommenden Coccidien der Gattung Isospora. Arch. Protistenk. 100: 91-112.

SCHOLTYSECK, E. 1973. Die Deutung von Endodyogenie und Schizogonie bei Coccidien und anderen Sporozoen. Z. ParasitKde 42: 87-104.

SCHOLTYSECK, E., MEHLHORN, H. & MÜLLER, B.E.G. 1973. Identifikation von Merozoiten der vier cystenbildenden Coccidien (Sarcocystis, Toxoplasma, Besnoitia, Frenkelia) auf Grund feinstruktureller Kriterien. Z. ParasitKde 42: 185-206.

SCHOLTYSECK, E., MEHLHORN, H. & MÜLLER, B.E.G. 1974. Feinstruktur der Cyste und Cystenwand von Sarcocystis tenella, Besnoitia jellisoni, Frenkelia sp. und Toxoplasma gondii. J. Protozool. 21: 284-294.

SCHOOF, H.F., SIVERLY, R.E. & JENSEN, J.A. 1952. House fly dispersion studies in metropolitan areas. J. econ. Ent. 45: 675-683.

SCOTT, J.M. & SWINBURNE, L.M. 1973. Toxoplasmosis and embryopathy. Br. med. J. 4: 422.

SCOTT, J.W. 1943. Life history of sarcosporidia, with particular reference to Sarcocystis tenella. Bull Wyo. agric. Exp. Stn, no. 259.

ŠEBEK, Z. 1960. Sarcocystis bei den Insektenfressern und Nagtieren. Zool. Listy 9: 1-6.

ŠEBEK, Z. 1962. Sarcocystis und M-Organismen bei Insektenfressern und Nagtieren. Zool. Listy 11: 355-366.

SÉNAUD, J. 1967. Contribution a l'etude des sarcosporidies et des toxoplasmes (Toxoplasmea). Protistologica 3: 167-232.

SÉNAUD, J., MEHLHORN, H. & SCHOLTYSECK, E. 1974. Besnoitia jellisoni in macrophages and cysts from experimentally infected laboratory mice. J. Protozool. 21: 715-720.

SHAH, H.L. 1970. Isospora species of the cat and attempted transmission of I. felis Wenyon, 1923 from the cat to the dog. J. Protozool. 17: 603-609.

SHAH, H.L. 1971. The life cycle of Isospora felis Wenyon, 1923, a coccidium of the cat. J. Protozool. 18: 3-17.

SHARF, M., EIBSCHITZ, I. & EYLAN, E. 1973. Latent toxoplasmosis and pregnancy. Obstet. Gynec. 42: 349-354.

SHARMAN, G.A.M., WILLIAMS, K.A.B., THORBURN, H. & WILLIAMS, H. 1972. Studies of serological reactions in ovine toxoplasmosis encountered in intensively-bred sheep. Vet. Rec. 91: 670-675.

SHEFFIELD, H.G. & MELTON, M.L. 1970. Toxoplasma gondii: the oocyst, sporozoite, and infection of cultured cells. Science 167: 892-893.

SHEFFIELD, H.G. & MELTON, M.L. 1974. Immunity to Toxoplasma gondii in cats. Proc. 3rd int. Congr. Parasit. (Munich) 1: 106-107.

SHELTON, G.C., KINTNER, L.D. & MacKINTOSH, D.O. 1968. A coccidia-like organism associated with subcutaneous granulomata in a dog. J. Am. vet. med. Ass. 152: 263-267.

SHIBALOVA, T.A. & PETRENKO, V.I. 1972. Isospora bigemina: sporozoite-induced development of the life cycle in tissue culture. Parazitologiya 6: 201-205.

SHIMADA, K., O'CONNOR, G.R. & YONEDA, C. 1974. Cyst formation by Toxoplasma gondii (RH strain) in vitro. Archs. Ophthalmol. 92: 496-500.

SHURA-BURA, B.L. 1952. Experimental study of houseflies using radioactive indicators. (In Russian). Zoo. Zh. 31: 410-412.

SHURA-BURA, B.L., SHAIKOV, A.D., IVANOVA, E.V., GLASUNOVA, A.Ia., MITRIUKOVA, M.S. & FEDOROVA, K.G. 1958. The character of dispersion from the point of release in certain species of flies of medical importance. Ent. Rev., Wash. 37: 282-290.

ŠIBALIĆ, D. 1975a. Apparent isolation of Sarcocystis sp. from human blood (a preliminary note). Trans. R. Soc. trop. Med. Hyg. 69: 148-152.

ŠIBALIĆ, D. 1975b. Ispitivanje parazitemije pacijenata u toku akutne i kronične toksoplazmoze. Acta Parasit. Iugosl. 6: 7-11.

ŠIBALIĆ, D. 1975c. Mogućnost izolacije Toxoplasma gondii iz krvi ljudi obolelih od toksoplazmoze i prilog poznavanju njene vitalnosti u krvi in vitro. Acta Parasit. Iugosl. 6: 13-18.

SIEYRO, L. 1942. Die Hausfliege (Musca domestica) als Überträger von Entamoeba histolytica und anderen Darmprotozoen. Dt. tropenmed. Z. 46: 361-372.

SIIM, J. CHR. 1974. Toxoplasma gondii. In: Actualités protozoologiques (resume des discussions des tables rondes du 4e congres international de protozoologie, 2-9 Septembre 1973, Clermont-Ferrand, France), 1: 203-212. Universite de Clermont, Clermont-Ferrand.

SIIM, J. CHR., BIERING-SØRENSEN, U. & MØLLER, T. 1963. Toxoplasmosis in domestic animals. Adv. vet. Sci. 8: 335-429.

SILVERMAN, P.H. & GRIFFITHS, R.B. 1955. A review of methods of sewage disposal in Great Britain, with special reference to the epizootiology of Cysticercus bovis. Ann. trop. Med. Parasit. 49: 436-450.

SIMPSON, C.F. 1966. Electron microscopy of Sarcocystis fusiformis. J. Parasit. 52: 607-613.

SIMPSON, C.F. & FORRESTER, D.J. 1973. Electron microscopy of Sarcocystis sp.: cyst wall, micropore, rhoptries, and an unidentified body. Int. J. Parasit. 3: 467-470.

*SOMINSKII, Z.F., PANASYUK, F.I. & VILKOVA, R.P. 1971. Pathological changes in experimental sarcocystosis of chickens. Veterinariya no. 6: 68-69.

---

*Original not seen (from Translation No. 44 of the College of Veterinary Medicine, University of Illinois, edited by Norman D. Levine).

SPINDLER, L.A., ZIMMERMAN, H.E., Jr & JAQUETTE, D.S. 1946. Transmission of Sarcocystis to swine. Proc. helminth. Soc. Wash. 13: 1-11.

STAGNO, S. & THIERMANN, E. 1973. Acquisition of Toxoplasma infection by children in a developing country. Bull. Wld Hlth Org. 49: 627-631.

STAGNO, S., THIERMANN, E. & PÉREZ, C. 1971. Toxoplasmosis isosporosis. New Engl. J. Med. 284: 853.

STINSON, E.B., BEIBER, C.P., GRIEPP, R.B., CLARK, D.A., SHUMWAY, N.E. & REMINGTON, J.S. 1971. Infectious complications after cardiac transplantation. Ann. intern. Med. 74: 22-36.

STOLTZ, L.P. & SAAYMAN, G.S. 1970. Ecology and behaviour of baboons in the northern Transvaal. Ann. Transv. Mus. 26: 99-143.

STRUM, S.C. 1975. Primate predation: interim report on the development of a tradition in a troop of olive baboons. Science 187: 755-757.

SUKHOVA, M.N. 1951. On the problem of the epidemiological significance of coprobiontic xerophilous species of synanthropic flies.(In Russian). Zool. Zh. 30: 188-190.

SULZER, A.J. & WILSON, M. 1971. Toxoplasma gondii: polar staining in fluorescent antibody test. Expl Parasit. 29: 197-200.

SWANEPOEL, R., BLACKBURN, N.K. & EFSTRATIOU, S. 1974. An investigation of the relationship between infection with Toxoplasma gondii and contact with animals. Cent. Afr. J. Med. 20: 206-210.

TADROS, W.A. 1970. Studies on the M-organism and related protozoan parasites of rodents. Unpublished Ph.D. thesis, University of London.

TADROS, W. & LAARMAN, J.J. 1975a. The weasel, Mustela nivalis as the final host of a Sarcocystis of the common European vole, Microtus arvalis. Proc. K. ned. Akad. Wet., (B) 78: 325-326.

TADROS, W. & LAARMAN, J.J. 1975b. The life cycle of Sarcocystis of the vole Microtus arvalis. 2nd European Multicolloquy of Parasitology, Trogir (summaries of papers read): 14-15. Društvo Parazitologa Jugoslavije, Beograd.

TADROS, W. & LAARMAN, J.J. 1975c. A study of serological cross-reaction amongst the four members of the "Toxoplasmea" by the indirect immunofluorescence (I.F.A.) technique. 2nd European Multicolloquy of Parasitology, Trogir (summaries of papers read): 9-10. Društvo Parazitologa Jugoslavije, Beograd.

TADROS, W., LAARMAN, J.J. & VAN DEN EIJK, A.A. 1974. The demonstration of antibodies to Sarcocystis fusiformis antigen in sera of Isospora hominis carriers, using the indirect fluorescence technique. Z. ParasitKde 43: 221-224.

TELEKI, G. 1973. The omnivorous chimpanzee. Scient. Am. 230: 33-42.

TERRELL, T.G. & STOOKEY, J.L. 1972. Chronic eosinophilic myositis in a Rhesus Monkey infected with sarcosporidiosis. Vet. Path. 9: 266-271.

TESKEY, H.J. 1960. A review of the life-history and habits of Musca autumnalis De Geer (Diptera: Muscidae). Can. Ent. 92: 360-367.

THAVER, S. 1974. Developments in the indirect fluorescent antibody test for tropical parasitic infections, especially malaria. Unpublished thesis presented for the Fellowship of the Institute of Medical Laboratory Technology, London.

THOMSEN, M. & HAMMER, O. 1936. The breeding media of some common flies. Bull. ent. Res. 27: 559-587.

THORNTON, H. 1972. Sarcosporidiosis - a review. Trop. Anim. Hlth Prod. 4: 54-57.

TODD, K.S., Jr & HAMMOND, D.M. 1968. Life cycle and host specificity of Eimeria callospermophili Henry, 1932 from the Unita Ground Squirrel Spermophilus armatus. J. Protozool. 15: 1-8.

TODD, K.S., Jr, HAMMOND, D.M. & ANDERSON, L.C. 1968. Observations on the life cycle of Eimeria bilamellata Henry, 1932 in the Unita Ground Squirrel Spermophilus armatus. J. Protozool. 15: 732-740.

TODD, K.S., Jr & LEPP, D.L. 1972. Completion of the life cycle of Eimeria vermiformis Ernst, Chobotar, and Hammond, 1971, from the mouse, Mus musculus, in dexamethasone-treated rats, Rattus norvegicus. J. Parasit. 58: 400-401.

TODD, K.S., Jr, LEPP, D.L. & TRAYSER, C.V. 1971. Development of the asexual cycle of Eimeria vermiformis Ernst, Chobotar, and Hammond, 1971, from the mouse, Mus musculus, in dexamethasone-treated rats, Rattus norvegicus. J. Parasit. 57: 1137-1138.

TOWNSEND, J.J., WOLINSKY, J.S., BARINGER, J.R. & JOHNSON, P.C. 1975. Acquired toxoplasmosis. Archs Neurol. 32: 335-343.

TUGWELL, P., BURNS, E.C. & WITHERSPOON, B. 1966. Notes on the flight behaviour of the horn fly, Haematobia irritans (L.) (Diptera: Muscidae). J. Kansas ent. Soc. 39: 561-565.

UHLÍKOVÁ, M. & HÜBNER, J. 1973. Congenital transmission of toxoplasmosis in domestic rabbits. Folia parasit., Praha 20: 285-291.

UIMANEN, I. & LEINIKKI, P. 1974. Are pet cats an important source of human toxoplasmosis? Proc. 3rd int. Congr. Parasit. 1: 306.

VAINISI, S.J. & CAMPBELL, L.H. 1969. Ocular toxoplasmosis in cats. J. Am. vet. med. Ass. 154: 141-152.

VAUGHAN, V.C. 1900. Conclusions reached after a study of typhoid fever among the American soldiers in 1898. J. Am. med. Ass. 34: 1451-1459.

VERSHININ, I.I. 1973. Developmental cycle of Sarcocystis tenella. (In Russian). Veterinariya no. 10: 75-78.

VETTERLING, J.M., PACHECO, N.D. & FAYER, R. 1973. Fine structure of gametogony and oocyst formation of Sarcocystis sp. in cell culture. J. Protozool. 20: 613-621.

VIENS, P. & MORISSET, R. 1975. Toxoplasmosis and the compromised host. Int. J. clin. Pharmacol. Biopharm. 11: 361-365.

WALLACE, G.D. 1969. Serologic and epidemiologic observations on toxoplasmosis on three Pacific atolls. Am. J. Epidem. 90: 103-111.

WALLACE, G.D. 1971a. Experimental transmission of Toxoplasma gondii by filth-flies. Am. J. trop. Med. Hyg. 20: 411-413.

WALLACE, G.D. 1971b. Isolation of Toxoplasma gondii from the feces of naturally infected cats. J. infect. Dis. 124: 227-228.

WALLACE, G.D. 1972. Experimental transmission of Toxoplasma gondii by cockroaches. J. infect. Dis. 126: 545-547.

WALLACE, G.D. 1973a. Sarcocystis in mice inoculated with Toxoplasma-like oocysts from cat faeces. Science 180: 1375-1377.

WALLACE, G.D. 1973b. The role of the cat in the natural history of Toxoplasma gondii. Am. J. trop. Med. Hyg. 22: 313-322.

WALLACE, G.D. 1973c. Intermediate and transport hosts in the natural history of Toxoplasma gondii. Am. J. trop. Med. Hyg. 22: 456-464.

WALLACE, G.D. 1974. Serologic and immunologic relationships of oocyst-producing parasites with similarities to Toxoplasma and Sarcocystis. Proc. 3rd int. Congr. Parasit. (Munich) 1: 112-113.

WALLACE, G.D. 1975. Observations on a feline coccidium with some characteristics of Toxoplasma and Sarcocystis. Z. ParasitKde 46: 167-178.

WALLACE, G.D. & FRENKEL, J.K. 1975. Besnoitia species (Protozoa, Sporozoa, Toxoplasmatidae): recognition of cyclic transmission by cats. Science 188: 369-371.

WALLACE, G.D., MARSHALL, L. & MARSHALL, M. 1972. Cats, rats, and toxoplasmosis on a small Pacific island. Am. J. Epidem. 95: 475-482.

WALLACE, G.D., ZIGAS, V. & GAJDUSEK, D.C. 1974. Toxoplasmosis and cats in New Guinea. Am. J. Epidem. 23: 1-14.

WATSON, W.A. 1972. Toxoplasmosis in human and veterinary medicine. Vet. Rec. 91: 254-258.

WATSON, W.A. & BEVERLEY, J.K.A. 1971. Epizootics of toxoplasmosis causing ovine abortion. Vet. Rec. 88: 120-124.

WENYON, C.M. & O'CONNOR, F.W. 1917. An inquiry into some problems affecting the spread and incidence of intestinal protozoal infections of British troops and natives in Egypt, with special reference to the carrier question, diagnosis and treatment of amoebic dysentery, and an account of three new human intestinal protozoa. Jl R. Army med. Cps 28: 686-698.

WERNER, H. & JANITSCHKE, K. 1970. Entwicklungsphasen, Entwicklungszyklen und systematische Stellung von Toxoplasma gondii. Zentbl. Bakt. ParasitKde (Abt. I) 214: 540-550.

WERNER, J.K. & WALTON, B.C. 1972. Prevalence of naturally occurring Toxoplasma gondii infections in cats from U.S. military installations in Japan. J. Parasit. 58: 1148-1150.

WHITESIDE, J.D. & BEGENT, P.H.J. 1975. Toxoplasma encephalitis complicating Hodgkin's disease. J. clin. Path. 28: 443-445.

WONG, M.M., THEIS, J. & KARR, S., Jr. 1974. Experimental toxoplasmosis in the stumptailed macaque (M. arctoides). J. med. Primat. 3: 195-212.

YAO, H.Y., YUAN, I.C. & HUIE, D. 1929. The relation of flies, beverages and well water to gastro-intestinal diseases in Peping. Natn. med. J. China 15: 410-418.

YILMAZ, S.M. & HOPKINS, S.H. 1972. Effects of different conditions on duration of infectivity of Toxoplasma gondii oocysts. J. Parasit. 58: 938-939.

YOUNG, E. & VAN DEN HEEVER, L.W. 1969. The African buffalo as a source of food and by-products. Jl S. Afr. vet. med. Ass. 40: 83-88.

ZAIDENOV, A.M. 1960. Study of house fly (Diptera, Muscidae) migrations in Chita by means of luminescent tagging. Ent. Rev., Wash. 39: 406-414.

ZAJÍČEK, D. & PÁV, J. 1972. Coccidiosis of the wild boar (Sus scrofa L.) in Czechoslovakia. Folia Parasit., Praha 19: 369-373.

ZAMAN, V. 1970. Morphology of Toxoplasma oocysts and its comparison with other cat coccidia. S.E. Asian J. trop. Med. publ. Hlth 1: 329-335.

ZAMAN, V. 1972. Inability to infect Felis bengalensis by Toxoplasma gondii. S.E. Asian J. trop. Med. publ. Hlth 3: 623.

ZAMAN, V. & COLLEY, F.C. 1972. Fine structure of Sarcocystis fusiformis from the Indian water buffalo (Bubalus bubalis) in Singapore. S.E. Asian J. trop. Med. publ. Hlth 3: 489-495.

ZEVE, V.H., PRICE, D.L. & HERMAN, C.M. 1966. Electron microscope study of Sarcocystis sp. Expl. Parasit. 18: 338-346.

ZLOTNICK, A. 1955. Observations on a parasite found in leucocytes of the peripheral blood in a case of hepato-splenomegaly. Trans. R. Soc. trop. Med. Hyg. 49: 472-475.

ŽUKOVIĆ, M., WIKERHAUSER, T., DŽAKULA, N. & MAGUD, I. 1973. Pokušaj peroralne i intraperitonealne invazije miševa malom formom Isospora bigemina iz psa. Acta Parasit. Iugosl. 4: 43-45.

SUBSIDIARY MATTER

The following publications, written subsequent to the candidate's registration for the Ph.D. degree, are submitted as subsidiary matter:-

1. Markus, M. B. 1972. Notes on the natal plumage of South African Passeriform birds. Ostrich 43: 17-22. This paper is based on data in Markus, M. B. 1969. A preliminary survey of the occurrence of neossoptiles in South African passeriform birds, with special reference to natal pteryloses. University Microfilms, Ann Arbor, Michigan, U.S.A. Order No. M-2297. 210 pp. Thesis accepted in partial fulfilment of the requirements for the degree of M.Sc. in Zoology, Faculty of Science, University of Pretoria.

*2. Markus, M. B. & Oosthuizen, J. H. 1972. Pathogenicity of Haemoproteus columbae. Trans. R. Soc. trop. Med. Hyg. 66: 186-187. This paper is based on data in Markus, M. B. 1970. Studies on blood parasites of birds, with special reference to seasonal variations in parasitaemia. 85 pp. Unpublished dissertation accepted in partial fulfilment of the requirements for the degree of M.Sc. (Medical Parasitology), Faculty of Medicine, University of London (London School of Hygiene and Tropical Medicine).

3. Markus, M. B. 1972. Mortality of vultures caused by electrocution. Nature 238: 228.

4. Markus, M. B. 1972. Diagnosis of isosporosis and toxoplasmosis. Trans. R. Soc. trop. Med. Hyg. 66: 673-674.

*5. Markus, M. B. & Oosthuizen, J. H. 1972. The haematozoa of South African birds. VI. Avian malaria. Vet. Rec. 91: 198-199.

6. Markus, M. B. 1973. Gametogony of Isopora - type coccidia. Trans. R. Soc. trop. Med. Hyg. 67: 7-8.

7. Markus, M. B. 1973. Dogs and transmission of toxoplasmosis. Brit. med. J. 2 (5687): 666.

8. Markus, M. B. 1973. Symptoms, transmission, prevention and treatment of toxoplasmosis. S. Afr. med. J. 47: 1588-1590.

9. Markus, M. B. 1973. Serology of toxoplasmosis, isosporosis and sarcosporidiosis. N. Engl. J. Med. 289: 980-981.

10. Markus, M. B. 1973. African trypanosomiasis and toxoplasmosis. Trans. R. Soc. trop. Med. Hyg. 67: 723.

11. Markus, M. B. 1974. Differentiation of coccidia in cats and transmission of toxoplasmosis. Med. J. Aust. 1: 80.

*12. Markus, M. B., Draper, C. C., Hutchison, W. M., Killick-Kendrick, R. and Garnham, P. C. C. 1974. Attempted infection of chimpanzees and cats with Sarcocystis of cattle. Trans. R. Soc. trop. Med. Hyg. 68: 3.

13. Markus, M. B. 1974. Earthworms and coccidian oocysts. Ann. trop. Med. Parasit. 68: 247-248.

14. Markus, M. B. 1974. Birds, coprophagous arthropods and coccidian oocysts. Proc. 3rd int. Congr. Parasit. (Munich) 1: 98-99.

15. Markus, M. B. 1974. Arthropod-borne disease as a possible limiting factor in avian distribution. Proc. 3rd int. Congr. Parasit. (Munich) 3: 1675-1676.

16. Markus, M. B. 1974. Arthropod-borne disease as a possible factor limiting the distribution of birds. Int. J. Parasit. 4: 609-612.

17. Markus, M. B. 1974. Serology of human sarcosporidiosis. Trans. R. Soc. trop. Med. Hyg. 68: 415-416.

*18. Markus, M. B., Killick-Kendrick, R. and Garnham, P. C. C. 1974. The coccidial nature and life-cycle of Sarcocystis. J. trop. Med. Hyg. 77: 248-259.

19. Markus, M. B. 1974. Cats and toxoplasmosis. S. Afr. med. J. 48: 2386.

20. Markus, M. B. 1975. Risk of human infection by Toxoplasma oocysts. Vet. Rec. 96: 413.

21. Markus, M. B. 1975. Coccidia related to Toxoplasma gondii: possible zoonoses. S. Afr. med. J. 49: 1095.

*Statement of the candidate's share in conjoint publications in terms of Regulation 44.6 for postgraduate students proceeding to the degree of Ph.D.

The candidate played a major role in these four conjoint publications. No. 2: The candidate proposed the survey, prepared and examined the blood smears and wrote and published the paper. The pigeons were trapped jointly

by the candidate and the second author, who stained the blood films. No. 5: The candidate scanned the slides and wrote and published the note. The second author collected the two francolins, prepared the blood smears and stained them. No. 12: With the exception of the performing of the indirect fluorescent antibody tests (where the candidate's contribution was about 50%), the bleeding of chimpanzees and the first two (unsuccessful) attempts to infect a cat, the candidate carried out the experimental work, including the collection of antigen. The first two chimpanzee experiments were planned jointly by all authors. The candidate wrote the abstract. No. 18: The candidate carried out the experimental work (except as indicated above for publication No. 12), undertook the literature survey and wrote the paper (which was modified in the light of comments by the other authors), with the exception of the initial drafts of (i) the last two paragraphs in the first column of page 6 of the reprint and (ii) the section on page 8 starting "The remarkable outbreak ..." to "... Brazil" at the end of the first paragraph on page 9. The candidate participated fully in the setting out of the figure on page 4 and in its detailed planning as regards parasite morphology but was not responsible for drawing the final diagram. The sections showing asexual stages of Sarcocystis in bovine tissues were examined jointly with the other authors.

Ostrich 43 (1): 17-22, 1972.

NOTES ON THE NATAL PLUMAGE OF SOUTH AFRICAN PASSERIFORM BIRDS

MILES B. MARKUS

Received June 1971

INTRODUCTION

Passeriform birds, unlike many non-passerines, are only sparsely covered with neossoptiles on emerging from the egg; or may be naked on hatching. Total loss of the natal plumage has occurred independently in members of several South African passerine families. Differences with regard to the number and, to a lesser extent, the distribution of neossoptiles on individual birds may be either natural or caused by abrasion. There can, for example, be variations in downy pterylosis between birds from the same locality or nest. The nature of the observed variation (Markus 1969), however, indicates that basic phenotypic differences are expressions of genotypic diversity.

This paper is based on data to be found in a catalogue of references to the downy plumage, which was supplemented by the results of detailed examination of nestlings representing more than half the genera of passerines that breed in the South African zoogeographical sub-region (Markus 1969). The classification used here is that of the South African Ornithological Society List Committee (1969). However, it should be noted that the family Campephagidae is placed immediately preceding the Pycnonotidae as in the latest version of Wetmore's classification of the birds of the world (Wetmore 1960).

The notes which follow serve, *inter alia*, to show some of the more important gaps in our knowledge.

EURYLAIMIDAE

No specimens were examined. Although Lowe (1924) had two embryos of *Smithornis* available for study, he does not state whether neossoptiles are present or absent. However, the indications are that *Smithornis* does not possess neossoptiles (Serle 1955); the comments of this author with regard to the presence or absence of the natal plumage of other species were found to be accurate.

PITTIDAE

According to Van Tyne & Berger (1959), neonates are naked.

ALAUDIDAE

Characteristic of the larks is their light-coloured, straw-like natal plumage. Abdominal neossoptiles were recorded for *Alaemon*, *Certhilauda* and *Calandrella* (if *starki* is relegated to the genus *Alauda* as proposed by MacLean (1969)) but were not seen in *Mirafra* or *Eremopterix* Upper rectrix covert neossoptiles were encountered in *Alaemon grayi* only. *Calandrella* had the greatest number of neossoptiles on the antebrachium. However, additional material will have to be studied before these differences can be evaluated.

HIRUNDINIDAE

Femoral neossoptiles, previously only known to occur in *Delichon urbica* (Witherby *et al.* 1938), *Hirundo rustica* (Leigh 1909 and Wetherbee 1957) and *Petrochelidon pyrrhonota* (Wetherbee *op. cit.*) were discovered on specimens of *H. albigularis* (not always present), *H. semirufa*, *H. cucullata*, *H. abyssinica*, *H. spilodera* (not always present) and *Riparia paludicola*. Of the last six species mentioned, the femoral tract had been recorded in southern Africa for *H. abyssinica* (Serle 1955) and *R. paludicola* (Serle 1943). Three other references may or may not indicate the presence of femoral neossoptiles: Skead (MS) refers to down on ". . . crurals . . ." in the case of *H. spilodera* and Serle (1950) mentions that *H. rupestris* has "crural" neossoptiles. Moreau (1940) saw neossoptiles ". . . on the hind flanks . . ." of *Psalidoprocne pristoptera*. The findings with regard to the femoral tract support relationships as interpreted by Mayr & Bond (1943) who group *Hirundo* and *Petrochelidon* together. *H. semirufa*, *H. cucullata* and *H. abyssinica*, all of which construct retort-

shaped nests, are placed by some authors in the genus *Cecropis* and *H. spilodera* in *Petrochelidon*. The natal pterylosis of *Hirundo*, *Cecropis* and *Petrochelidon* is found to be similar.

Abdominal neossoptiles occurred on one of four specimens of *H. cucullata*, that with the highest total number of neossoptiles. Abdominal neossoptiles were previously unknown in the family Hirundinidae.

Individual variation amongst birds from the same nest was noted with regard to the presence/absence of certain alar neossoptiles in the case of *H. semirufa*. Crural neossoptiles were doubtfully present on one *H. semirufa*. The only other crural neossoptile seen was on the right leg of the *H. cucullata* nestling having the greatest number of neossoptiles (Markus 1969).

DICRURIDAE

Only fragmentary data are available. It is possible that *Dicrurus* does possess a small number of neossoptiles, in spite of statements to the contrary; but additional specimens need to be examined.

ORIOLIDAE

Although no nestlings were available for study, literature references for two South African representatives, *Oriolus auratus* and *O. larvatus*, indicate that neossoptiles do occur on Ethiopian birds. The latter species possesses coronal, scapular and spinal neossoptiles, at least.

CORVIDAE

All three South African corvids are hatched with neossoptiles.

Nestlings of *Corvus capensis* seen by Skead (1952) lacked capital neossoptiles. This is a most interesting observation as it would appear that there is only one other species known to possess neossoptiles on the dorsal surface of the body but not on the head, this being *Corvus frugilegus*. Ingram (1920) considered that there is less necessity for concealment as the latter species nests in colonies. *C. capensis*, however, is not a colonial nester. *C. albus* has neossoptiles on the head; but no data are available for *C. albicollis* with regard to the presence or absence of orbital and coronal neossoptiles.

PARIDAE

Parus niger has neossoptiles. *Anthoscopus*, given separate family rank by some authors, does not.

CERTHIIDAE

Van Tyne & Berger (*op. cit.*) state that nestlings are downy, although no data are available for the single South African representative of this family.

TIMALIIDAE

Chicks can be either naked or with down (Van Tyne & Berger *op. cit.*). There is no information for South African representatives.

CAMPEPHAGIDAE

The neossoptile pterylosis of *Campephaga phoenicia*, as representative of the Campephagidae, is unique. A large number of conspicuous neossoptiles are present; these are pure white and contrast sharply with the dark skin. The distribution of those of the capital tract is complex, the structures being found on most loci. The spinal tract is unusually broad, being composed of four to six rows of neossoptiles. According to the literature *Coracina* also possesses neossoptiles. Sibley (1970) found the egg-white protein electrophoretic pattern of *Campephaga* to be unlike that of other passerines.

PYCNONOTIDAE

These birds are naked on hatching.

TURDIDAE

Neossoptiles were found in the lower pelvic region in *Turdus* only.

The thrush genera *Turdus* and *Monticola* can be distinguished from each other on the basis of their downy pteryloses. A greater variety of alar neossoptile loci are represented in *Turdus*. The marked reduction in the number of neossoptiles in the wing of *Monticola* may indicate a relationship with the chats e.g. *Oenanthe*, *Cercomela*, *Thamnolaea* and *Saxicola*. Unlike *Cercomela* and *Thamnolaea*, the *Monticola* that was examined, a specimen of *M. angolensis*, did not have femoral neossoptiles; neither is the tract referred to in the literature pertaining to South African thrushes of the genus. This absence of the femoral tract is worthy of further investigation in order to determine the constancy of the feature. The tract is attributed to *Oenanthe* (Witherby *et al.* 1938: 148, 157 & 166); also apparently, to a South African representative of the genus (Roberts 1936). In their descriptions of the distribution of the natal down of *Saxicola torquata*, Serle (1950) and Witherby *et al.* (*op. cit.*) do not mention the femoral tract. *S. rubetra* also lacks femoral down (Witherby *et al.*, *op. cit.*)

The robins *Cossypha* and *Pogonocichla* possess neossoptiles, as does the rock-jumper *Chaetops*. Remarkable is the fact that typical neossoptiles are absent in *Erythropygia leucophrys* but present in *E. coryphaeus*. The reason for this infrageneric difference is not readily apparent. The genus as a whole needs to be studied in detail.

SYLVIIDAE

In each of eight genera there is more than one breeding species in the South African zoogeographical sub-region. The nestlings of seven of these, *Acrocephalus*, *Apalis*, *Sylvietta*, *Eremomela*, *Camaroptera*, *Cisticola* and *Prinia* are hatched without neossoptiles, in spite of statements to the contrary (for details see Markus 1969) which require confirmation. There are no descriptions of newly-hatched young of the eighth, *Bradypterus*. Pulli of *Heliolais*, doubtfully separable from *Prinia*, are probably also naked on hatching. Unfortunately there are no satisfactory data for the monotypic genera *Sphenoeacus*, *Achaetops* and *Melocichla* (White (1960) places all three species, *S. afer*, *A. pycnopygius* and *M. mentalis* in *Sphenoeacus*), nor for the single South African species of *Chloropeta*.

Regarding the remaining (monotypic) genus, *Seicercus* (Sylviidae, *inc. sed.!*): Moreau & Moreau (1937), referring to three *S. ruficapillus* chicks in the same nest, write: ". . . naked . . . with tufts of down over the eyes." It would be instructive to know if neossoptiles are, in fact, restricted to the capital region as in *Zosterops*, in association with which, incidentally, *S. ruficapillus* commonly feeds.

MUSCICAPIDAE

Neossoptiles are present in the genera *Muscicapa*, *Melaenornis*, *Trochocercus* and *Terpsiphone* but do not occur on *Parisoma* (*subcaeruleum*), *Batis* or *Stenostira*.

The single specimen of *Terpsiphone* that was examined had a large total neossoptile count (490) and the following unusual loci were represented: interramal, cervical (ventral), under rectrix covert, patagial covert and middle carpal remex covert.

MOTACILLIDAE

All three genera, *Motacilla*, *Anthus* and *Macronyx* have neossoptiles. The neossoptile pteryloses of two *Macronyx capensis* specimens differed considerably, the greatest number of neossoptiles recorded for a South African passerine (502) being found on one of these.

The African longclaws *Macronyx* and the American meadowlarks *Sturnella* fill similar niches and represent a classic example of convergent evolution. The birds are comparable with regard to habitat, voice, nest, habits and colouration, the similarity being carried even to the white outer tailfeathers in the two genera (Friedmann 1946). Two spirit specimens of *Sturnella magna* were borrowed from the Chicago Natural History Museum (courtesy of Maj. Melvin A. Taylor) and it was found that the natal pteryloses of *Macronyx* and *Sturnella* are not alike. The former has a greater number of neossoptiles and more loci are represented. Furthermore, the latter has neossoptiles on the spinal tract in the region of the neck that are lacking in *Macronyx*.

LANIIDAE

A number of contradictory statements exist in the literature. Nevertheless, it appears that shrikes of the following genera are probably without neossoptiles on hatching: *Eurocephalus, Nilaus, Dryoscopus, Tchagra, Laniarius, Malaconotus* and *Corvinella.* Caudal and/or alar structures occur on some birds, e.g. *Tchagra senegala, T. tchagra* and *Malaconotus zeylonus.* Microscopic examination of specimens is required in order to confirm the nakedness of birds of the above genera. The possibility of geographic variation being responsible for the presence/absence of neossoptiles on *T. senegala* should be considered, even though it seems unlikely that this will prove to be the case.

The distribution of neossoptiles in *Lanius collaris* is rather peculiar, only the abdominal, caudal and alar tracts being represented. This pattern was also found in Nearctic *Lanius* (Wetherbee. *op cit.*)

PRIONOPIDAE

There is a single reference – for *Prionops retzii:* ". . . without down" (White 1943). Van Tyne & Berger (*op. cit.*), however, state that newly-hatched young are "Downy".

STURNIDAE

Creatophora, Cinnyricinclus, Lamprotornis and *Onychognathus* have neossoptiles. There is no satisfactory information for the other two South African genera, viz. *Spreo* and *Buphagus.* Specimens of *Lamprotornis australis* and *Onychognathus morio* were examined. For "hole-nesters" these birds are endowed with a large number of neossoptiles.

PROMEROPIDAE

Promerops is liberally covered with natal down. Unfortunately an attempt to obtain newly-hatched meliphagids from Australia for comparison was unsuccessful. Van Tyne & Berger (*op. cit.*) comment as follows on meliphagid nestlings: "With sparse down."

NECTARINIIDAE

The bodies of probably all newly-hatched South African sunbirds are devoid of natal down. The statement in Van Tyne & Berger (*op. cit.*) is, therefore, inaccurate; and may be incorrect.

ZOSTEROPIDAE

The distribution of neossoptiles in *Zosterops* is most unusual; these feathers are apparently restricted to the head (Lovell-Keays 1915; Serle 1940; Skead & Ranger 1958; Van Tyne & Berger *op. cit.;* Markus 1969).

PLOCEIDAE

The sparrows (subfamily Passerinae: *Passer, Petronia*), which exhibit a tendency to nest in "holes", do not have neossoptiles. *Bubalornis* and *Plocepasser*, like the Passerinae, construct large, unwoven nests. The indications are that neither of the latter genera possesses neossoptiles but more data are required, especially for *Bubalornis.* It is the opinion of Sushkin (1927) that the subfamily Passerinae represents a distinct branch of evolution, not standing in ". . . direct ascendant or descendant relation . . ." to the Ploceinae and Estrildinae; and that the Plocepasserinae (he includes *Plocepasser* and *Philetairus* but not *Sporopipes*) form an intermediate group leading from the presumably archaic Bubalornithinae, with its main features pointing in the direction of the Passerinae. A specimen of *Philetairus* had neossoptiles on several loci not shared by any of the other Ploceidae that were studied (e.g. auricular, postauricular, malar and cervical (ventral)), whilst a second *Philetairus* did not. Like the Ploceinae and most of the Estrildinae and unlike *Passer* and *Petronia, Sporopipes* possesses neossoptiles. Crural neossoptiles were present, as in many of the Ploceinae that were examined. On the basis of these findings and other studies (Markus 1964, 1965 and unpublished) it was concluded (Markus 1969) that it would be preferable to follow Sclater (1930) in retaining a separate subfamily, the Sporopipinae, rather than place *Sporopipes* in the Passerinae. Clench (1970) (née Heimerdinger), who studied the teleoptile body pterylosis, also

concluded that *Sporopipes* should not be included in the Passerinae. I support the recent findings of Pocock (1966) and Sibley (1970) that *Passer* is not a ploceid.

The greater secondary coverts of *Ploceus* and/or a secondary(ies) are longer than most other neossoptiles of the wing. In the case of *P. intermedius*, however, the alar neossoptiles in general are conspicuous and there is a concomitant "increase" in the total number present on the bird. Wetherbee (*op. cit.*) found that certain North American passerines from arid environments seemed to have longer neossoptiles and a greater number of loci were apparently represented on such species. The African *P. intermedius* is also a bird of more arid regions. Attention may be drawn to the fact that in its lack of a special ceiling lining inside the roof, the nest of *P. intermedius* differs from all but one of other nests of weavers of the genus *Ploceus* studied by Collias & Collias (1964) including, *inter alia*, the nests of *P. capensis*, *P. xanthops*, *P. velatus* and *P. cucullatus*, species examined during the course of the present investigation. The inner side of the roof of the nest of *P. intermedius* was found to be ". . . merely a continuation of the weaving of the grasses of the roof" (Collias & Collias *op. cit.*). The ceiling occurs in the nests of weavers whose distribution centres in areas of frequent and abundant rainfall and is perhaps an adaptation for rain-shedding. Thus the question arises as to whether the greater coverage of the body of *P. intermedius* with neossoptiles may have/have had survival value.

In having relatively few or no neossoptiles on the wing, the Estrildinae differ from other members of the Ploceidae on which neossoptiles occur (but see *Uraeginthus angolensis* in Markus 1969). Morlion (1964) found that certain teleoptiles of the alar tract which are present in *Ploceus* are absent in *Estrilda*. The nest-building ability in the Estrildinae is not well-developed and certain species sometimes or regularly take over the nests of other species. It is interesting to note that *Estrilda astrild* apparently does not possess neossoptiles.

FRINGILLIDAE

Neossoptiles occur on all South African representatives of this "advanced" family. Compared with other passerines, there is no noticeable reduction in the downy covering.

The natal pteryloses of *Serinus* and *Emberiza* are similar.

SUMMARY

It would appear that natal pterylosis may sometimes be used in systematic studies, bearing in mind that taxonomic value cannot be assessed independently of adaptive significance. Whether passerine neossoptiles are degenerating structures and whether they have an embryonic and/or postnatal function(s) remain important questions (Markus 1969).

Striking features are the infrageneric variation with regard to the presence/absence of neossoptiles in *Erythropygia* and *Estrilda*, a possible absence of capital neossoptiles in *Corvus capensis* and the unusual natal pteryloses of *Campephaga*, *Lanius* and *Zosterops*.

ACKNOWLEDGEMENTS

Sincere thanks are extended to Mr. C. J. Skead for allowing me to use his valuable unpublished field notes and to Drs. Rolf and Mary Jensen, Mr Carl Vernon and other persons mentioned in Markus (1969) who so kindly donated specimens. I am also indebted to the Frank M. Chapman Memorial Fund Committee of the American Museum of Natural History, New York and the South African Council for Scientific & Industrial Research for the award of grants which supported this investigation in part.

REFERENCES

CLENCH, M. H. 1970. Variability in body pterylosis, with special reference to the genus *Passer*. *Auk* 87:650–691.

COLLIAS, N. E. & COLLIAS, E. C. 1964. Evolution of nest-building in the weaverbirds (Ploceidae). *Univ. Calif. Publs Zool.* 73:1–239.

FRIEDMANN, H. 1946. Ecological counterparts in birds. *Sci. Mon.* 63:395–398.

INGRAM, C. 1920. A contribution to the study of nestling birds. *Ibis* pp. 856-880.

LEIGH, A. G. 1909. On the down-plumage and mouth-coloration of nestling birds. *Br. Birds* 3:153-154.
LOVELL-KEAYS, L. 1915. The breeding of the African White-eye. *Zosterops viridis (sic.) Avicult. Mag.* pp. 272-278.
LOWE, P. R. 1924. On the presence of broadbills (Eurylaemidae) in Africa. *Proc. Zool. Soc. Lond.* pp. 279-291.
MACLEAN, G. L. 1969. South African lark genera. *Cimbebasia* ser. A 1(4):80-94.
MARKUS, M. B. 1964. Premaxillae of the fossil *Passer predomesticus* Tchernov and the extant South African Passerinae. *Ostrich* 35:245-246.
MARKUS, M. B. 1965. Mandible of the Cape Sparrow. *S. Afr. J. Sci.* 61:207.
MARKUS, M. B. 1969. *A preliminary survey of the occurrence of neossoptiles in South African passeriform birds, with special reference to natal pteryloses.* University Microfilms, Ann Arbor, Michigan. Order no. M-2297.
MAYR, E. & BOND, J. 1943. Notes on the generic classification of the swallows, Hirundinidae. *Ibis* 85:334-341.
MOREAU, R. E. 1940. Numerical data on African birds' behaviour at the nest. – II. *Psalidoprocne holomelaena massaica* Neum., the Rough-wing Bank-Martin. *Ibis* pp. 234-248.
MOREAU, R. E. & MOREAU, M. W. 1937. Biological and other notes on some East African birds. *Ibis* pp. 321-343.
MORLION, M. 1964. Pterylography of the wing of the Ploceidae. *Gerfaut* 54:111-158.
POCOCK, T. N. 1966. Contributions to the osteology of African birds. *Ostrich* suppl. 6:83-94.
ROBERTS, A. 1936. Some unpublished field notes made by Dr (Sir) Andrew Smith (between the years 1826 and 1831 in the Cape Colony (Cape Province of South Africa). Compiled from his manuscript notes.) *Ann. Transv. Mus.* 18:271-323.
SCLATER, W. L. 1930. *Systema avium aethiopicarum.* part 2. London: Taylor & Francis.
SERLE, W. 1940. Field observations on some northern Nigerian birds. – Part II. *Ibis* pp. 1-47.
SERLE, W. 1943. Further field observations on northern Nigerian birds. *Ibis* 85:264-300 & 413-437.
SERLE, W. 1950. A contribution to the ornithology of the British Cameroons. *Ibis* 92:343-376 & 602-638.
SERLE, W. 1955. Miscellaneous notes on the birds of the eastern highlands of southern Rhodesia. *Ostrich* 26:115-127.
SIBLEY, C. G. 1970. A comparative study of the egg-white proteins of passerine birds. *Bull. Peabody Mus. nat. Hist.* no. 32.
SKEAD, C. J. 1952. A study of the Black Crow *Corvus capensis. Ibis* 94:434-451.
SKEAD, C. J. & RANGER, G. A. 1958. A contribution to the biology of the Cape Province white-eyes (*Zosterops*). *Ibis* 100:319-333.
SOUTH AFRICAN ORNITHOLOGICAL SOCIETY LIST COMMITTEE. 1969. *Check list of the birds of South Africa.* Cape Town: S.A.O.S.
SUSHKIN, P. L. 1927. On the anatomy and classification of the weaver-birds. *Bull. Am. Mus. nat. Hist.* 57:1-32.
VAN TYNE, J. & BERGER, A. J. 1959. *Fundamentals of ornithology.* New York: John Wily & Sons.
WETHERBEE, D. K. 1957. Natal plumages and downy pteryloses of passerine birds of North America. *Bull. Am. Mus. nat. Hist.* 113:343-436.
WETMORE, A. 1960. A classification for the birds of the world. *Smithsonian misc. Coll.* 139(11):1-37.
WHITE, C. M. N. 1943. Field notes on some birds of Mwinilunga, Northern Rhodesia. *Ibis* 85: 127-131.
WHITE, C. M. N. 1960. A check list of the Ethiopian Muscicapidae (Sylviinae). Part I. *Occ. Pap. natn. Mus. Sth. Rhod.* 3(24B):399-430.
WITHERBY, H. F., JOURDAIN, F. C. R., TICEHURST, N. F. & TUCKER, B. W. 1938. *The handbook of British birds.* vol 2. London: Witherby.

Miles B. Markus, Dept. of Zoology and Applied Entomology, Imperial College, University of London, London S.W. 7, England.

Reprinted from
TRANSACTIONS OF THE ROYAL SOCIETY OF TROPICAL MEDICINE AND HYGIENE.
Vol. 66. No. 1. pp. 186-187, 1972.

PATHOGENICITY OF *HAEMOPROTEUS COLUMBAE*

SIR,—Some workers are of the opinion that *Haemoproteus columbae* produces no clinical signs of disease in domestic pigeons *Columba livia;* or the protozoon is dismissed as being of little importance as a pathogen (e.g. CHANDLER and READ, 1961). This is not always the case.

In view of the paucity of information on this common haematozoon in feral *C. livia* populations (KNISLEY and HERMAN, 1967), thin smears of peripheral blood were prepared between June 1968 and June 1969 at regular bimonthly intervals from adult and (occasionally) subadult feral pigeons trapped on Church Square, Pretoria. Usually the blood of 20 birds was filmed and for the sake of uniformity, pigeons having the general phenotype of the blue chequer variety were selected. Before being released the birds were marked with numbered leg bands. A total of 127 individuals was examined, 9 of these more than once. 100% of the pigeons proved to be infected with *H. columbae* and no seasonal variation in parasitaemia was noted. This is not unexpected since *Pseudolynchia canariensis* (Hippoboscidae), the known vector, was collected throughout the year and pigeons are probably continually exposed to reinfection—to which a bird that has recovered is susceptible (COATNEY, 1933).

On 20 April 1969 a pigeon, still somewhat immature, was noticed feeding by itself. At times it would lie down whilst pecking at food and was less wary than the others and reluctant to fly. This lethargic individual was easily caught by hand, the only one to be captured in this manner. Its blood was "watery" and microscopic examination of the smear revealed the presence of many basophilic erythrocytes. In *Leucocytozoon simondi* infections, this situation is indicative of an anaemic condition (FALLIS et al., 1951; KOCAN and CLARK, 1966; DESSER, 1967). Of all pigeons examined this bird had the highest number of red blood cells parasitized by *H. columbae,* viz. 50·6% (20,000 erythrocytes were examined). Both mature as well as immature gametocytes were present and many cells contained more than 3 young forms, both reticulocytes as well as mature erythrocytes being involved. A positive correlation was found between multiple invasion of erythrocytes by *H. columbae* and the intensity of parasitaemia (MARKUS, 1970)—as in, for example, human *Plasmodium* infections (WANG, 1970).

The fact that pigeons may be visibly affected was recorded by COATNEY (1933) and earlier workers, who noted similar symptoms. It appears that anaemia and anorexia are correlated with heavy infections, as indicated by the number of gametocytes in the blood, and the protozoon has a marked deleterious effect only if there is an accumulation of parasites. Internally the liver and spleen become enlarged and dark in colour (ACTON and KNOWLES, 1914; BECKER et al., 1956; LEVINE, 1962). GARNHAM (1966) is of the opinion that *H. columbae* must be pathogenic to some extent because at the peak of parasitaemia ". . . nearly half the erythrocytes contain gametocytes." Our results support this statement. However, it is unusual for anaemia in *C. livia* to result from the destruction of erythrocytes and as a rule infected birds show no signs of disease (LEVINE, 1962). It would be instructive if the statements in various standard texts to the effect that infections can be fatal could be supported by future studies yielding quantitative data.

This work received financial support from the Frank M. Chapman Memorial Fund of the American Museum of Natural History, New York, and the South African Council for Scientific and Industrial Research.

We are, etc.,

MILES B. MARKUS,
Department of Medical Protozoology,
London School of Hygiene and Tropical Medicine.
Present address:
Department of Zoology and Applied Entomology,
Imperial College, University of London, S.W.7.
J. H. OOSTHUIZEN,
Department of Zoology,
University of Pretoria, South Africa.

23 *November*, 1971

REFERENCES

ACTON, H. W. & KNOWLES, R. (1914). *Indian J. med. Res.*, **1**, 663.
BECKER, E. R., HOLLANDER, W. F. & PATTILLO, W. H. (1956). *J. Parasit.*, **42**, 474.
CHANDLER, A. C. & READ, C. P. (1961). *Introduction to Parasitology*, 10th ed. (Wily International Ed.), p. 165. New York: John Wily.
COATNEY, G. R. (1933). *Am. J. Hyg.*, **18**, 133.
DESSER, S. S. (1967). *J. Protozool.*, **14**, 244.
FALLIS, A. M., DAVIES, D. M. & VICKERS, M. A. (1951). *Can. J. Zool.*, **29**, 305.
GARNHAM, P. C. C. (1966). *Malaria Parasites and other Haemosporidia*, p. 946. Oxford: Blackwell Scientific Publications.
KNISLEY, J. O. & HERMAN, C. M. (1967). *Chesapeake Sci.*, **8**, 200.
KOCAN, R. M. & CLARK, D. T. (1966). *J. Protozool.*, **13**, 465.
LEVINE, N. D. (1962). *Trans. Ill. St. Acad. Sci.*, **55**, 92.
MARKUS, M. B. (1970). M.Sc. (Medical Parasitology) dissertation, University of London (unpublished).
WANG, C. C. (1970). *Trans. R. Soc. trop. Med. Hyg.*, **64**, 268.

Printed by F. J. PARSONS LTD., *London, Folkestone and Hastings.*

(*Reprinted from Nature, Vol. 238, No. 5361, p. 228, July 28, 1972*)

Mortality of Vultures caused by Electrocution

IN the south-western Transvaal in South Africa, Cape vultures, *Gyps coprotheres*, have been accidentally electrocuted by contact with 88 kV high tension power lines; it is possible that, occasionally, individuals of other vulture species may be involved as well. It is not known whether these large birds are killed trying to perch or when flying off, or both.

Table 1 Minimum Numbers of Vultures Electrocuted 1970–71 *

Month	1970	1971	Total
January	1	4	5
February	4	3	7
March	10	16	26
April	5	33	38
May	3	11	14
June	3	2	5
July	0	2	2
August	0	0	0
September	0	0	0
October	0	2	2
November	2	8	10
December	7	13	20
Totals	35	94	129

* Figures for early 1972 are: January, 5; February, 4; March, 10.

From January 1, 1970, to March 31, 1972, at least 148 vultures were killed. Table 1 shows that there is a quiet period at the time of year when *G. coprotheres* has eggs and young in the nest in the Transvaal. Presumably the concentration of vultures in an area at any one time would depend on the amount of food available. The figure 148 relates to the number of bodies found during inspections, frequently carried out to determine the cause of line faults: vultures have proved to be troublesome in this regard. As the power lines pass through both densely populated areas of human habitation and rural scrub country, additional corpses could easily have been removed by man or scavengers, disappeared as a result of decomposition, or have been overlooked. Thus the actual number of deaths was no doubt greater.

It would be of value to know if vultures are also electrocuted in other areas, particularly those where there are relatively few large trees for them to perch in, as is the case in the SW Transvaal. Birds with a low reproductive rate, like vultures, usually have a correspondingly low death rate, and accidental electrocution on a large scale might have a significant impact on vulture populations.

This report was written while I was visiting the Mammal Research Unit of the South African Council for Scientific and Industrial Research, supported by a CSIR travel grant.

MILES B. MARKUS

Department of Zoology and Applied Entomology,
Imperial College,
University of London SW7

Printed in Great Britain by Flarepath Printers Ltd., St. Albans, Herts.

Reprinted from
TRANSACTIONS OF THE ROYAL SOCIETY OF TROPICAL MEDICINE AND HYGIENE.
Vol. 66. No. 4. pp. 673-674, 1972.

DIAGNOSIS OF ISOSPOROSIS AND TOXOPLASMOSIS

SIR,—During July 1969 an adult female yellow mongoose *Cynictis penicillata* was run over by a motor car in the western Transvaal, South Africa. Nematode eggs were recovered from a faecal sample by centrifugal flotation, using a saturated sodium chloride solution, but no coccidian oöcysts were detected. However, a few coccidian gametocytes and oöcysts were subsequently discovered in the small intestine (20 sections stained with haematoxylin and eosin were checked). During the course of field work in the same area in 1971, *Isospora* was found to be a common parasite of *C. penicillata* and thus the endogenous stages seen earlier were probably those of this protozoon.

DUBEY and FRENKEL (1972a) demonstrated the persistence of extra-intestinal stages of *I. felis* in an experimentally infected cat some time after the disappearance of oöcysts from its faeces. They (DUBEY and FRENKEL, 1972b) also saw *Toxoplasma* schizonts and gametocytes in the gut of a kitten that had stopped passing oöcysts 2 weeks previously and suggested that re-excretion of oöcysts might have taken place had the animal not been killed for autopsy. Various authors (e.g. FRENKEL, 1970; DRAPER et al., 1971; HUTCHISON et al., 1971) have referred to cases of experimental toxoplasmosis where oöcysts were apparently not shed at all. WENYON (1923) located numerous oöcysts of *I. bigemina* in the intestine of a cat without finding them in the faeces and was of the opinion that in the case of chronic *I. bigemina* infections, oöcysts probably escape from damaged villi when the latter break down but otherwise tend not to leave the villi regularly. He thought that infections might be overlooked if diagnoses were to be based on faecal examinations alone. The experience of MCCONNELL et al. (1971), who question the reliability of scrutiny of faeces for the detection of *I. papionis* (and possibly *I. hominis*), was similar. On histological study of the intestine, these authors found macrogametes and sporulated oöcysts of *I. papionis* in 15% of the chacma baboons, *Papio ursinus*, which they captured but in spite of careful examination of intestinal contents, observed no oöcysts or sporocysts. The number of parasites seen in sections (oöcysts predominated) was fairly large in the case of one of the baboons.

The same problems of diagnosis may apply more widely to *Isospora*-type infections (including *Sarcocystis*—FAYER, 1972; ROMMEL and HEYDORN, 1972) and failure to detect chronic infections in, *inter alia*, man and other primates on the basis of faecal examinations may not always mean that gametogony is not taking place or that the concentration techniques used for the recovery of oöcysts are necessarily inefficient. "Retention" of oöcysts would seem to be less likely in the case of species in which the sexual cycle takes place in the intestinal epithelium, as opposed to the lamina propria. Examples are *I. felis* (SHAH, 1971) and *Toxoplasma* (HUTCHISON et al., 1971; DUBEY and FRENKEL, 1972b) in cats, which have a rapid turnover of epithelial cells of the small intestine under both normal and pathological conditions (MCMINN, 1954).

Because of possible cross-reactions (e.g. STAGNO et al., 1971), the specificity of current serological tests for the presence of antibodies to *Toxoplasma* is in doubt. This question also needs to be resolved.

Field work was made possible by a travel grant from the South African Council for Scientific and Industrial Research and a research grant from the C.S.I.R. Mammal Research Unit.

I am, etc.,

MILES B. MARKUS,
Department of Zoology and Applied Entomology,
Imperial College, University of London, S.W.7.

19 *June*, 1972

REFERENCES

DRAPER, C. C., KILLICK-KENDRICK, R., HUTCHISON, W. M., SIIM, J. CHR. & GARNHAM, P. C. C. (1971). *Br. med. J.*, **2**, 375.
DUBEY, J. P. & FRENKEL, J. K. (1972a). *J. Protozool.*, **19**, 89.
——— & ——— (1972b). *Ibid.*, **19**, 155.
FAYER, R. (1972). *Science*, **175**, 65.
FRENKEL, J. K. (1970). *J. infect. Dis.*, **122**, 553.
HUTCHISON, W. M., DUNACHIE, J. F., WORK, K. & SIIM, J. CHR. (1971). *Trans. R. Soc. trop. Med. Hyg.*, **65**, 380.

McConnell, E. E., De Vos, A. J., Basson, P. A. & De Vos, V. (1971). *J. Protozool.*, **18**, 28.
McMinn, R. M. H. (1954). *J. Anat.*, **88**, 527.
Rommel, M. & Heydorn, A.-O. (1972). *Berl. Münch. tierärztl. Wschr.*, **85**, 143.
Shah, H. L. (1971). *J. Protozool.*, **18**, 3.
Stagno, S., Thiermann, E. & Perez, C. (1971). *New Engl. J. Med.*, **284**, 853.
Wenyon, C. M. (1923). *Ann. trop. Med. Parasit.*, **17**, 231.

Printed by F. J. PARSONS LTD., *London, Folkestone and Hastings.*

Reprinted from THE VETERINARY RECORD, August 19th, 1972, Pp. 198-199, Vol. 91, No. 8.

The Haematozoa of South African Birds. VI: Avian Malaria

Sir,—The climatic barriers which limit the distribution of human malaria do not exist in the case of bird malaria, which is found in most parts of the world. To date the only published records of its occurrence in Africa, south of the Limpopo river appear to be from the Jackass Penguin, *Spheniscus demersus* (Fantham & Porter, 1944) and a Helmeted Guinea-fowl, *Numida meleagris* (Garnham, 1966).

An adult female Swainson's Francolin, *Francolinus swainsonii*, and an adult male Coqui Francolin, *F. coqui*, both shot on July 8th, 1967 on the farm Olifantspoort, Nylstroom District, N. Transvaal, were infected with *Plasmodium*. Specific identification of the protozoa must await morphological and biological study of additional material following subinoculation.

It should be noted that the Yellow-necked Francolin, *F. leucoscepus*, is a natural host of *Plasmodium durae* (Dr. B. A. Southgate, personal communication to M.B.M., 1970), which has caused fatal epizootics in domestic turkeys in Kenya (de Jong, 1971). The indications are that Swainson's Francolin and the Yellow-necked Francolin had a common ancestor (Hall, 1963). Mohan and Manwell (1969) reported *P. juxtanucleare* from *Francolinus* sp. in Tanzania. *P. fallax*, at least, has been found in the Helmeted Guinea-fowl in various parts of Africa and the most recent record concerning this bird, that of Peirce and Backhurst (1970) in Kenya, may have been of *P. fallax*.

A survey of the blood parasites of galliform birds in Africa is needed in view of the potential economic and veterinary importance of certain avian plasmodia.

Acknowledgments.—Work on the haematozoa of birds is assisted by grants from the Frank M. Chapman Memorial Fund of the American Museum of Natural History, New York and the S.A. Council for Scientific & Industrial Research.

March 14th, 1972.

Yours faithfully,

M. B. MARKUS.

Department of Zoology & Applied Entomology, Imperial College, University of London, S.W.7.

J. H. OOSTHUIZEN.

Department of Zoology, University of Pretoria, S. Africa.

References

DE JONG, A. C. (1971). "Some Haemosporidian Parasites of Parakeets and Francolins". Unpublished Ph.D. thesis, University of London.

FANTHAM, H. B. & PORTER, A. (1944). *Proc. zool. Soc. Lond.* **114**. 279.

GARNHAM, P. C. C. (1966). "Malaria Parasites and other Haemosporidia". p. 644. Blackwell Scientific Publications, Oxford.

HALL, B. P. (1963). *Bull. Br. Mus. nat. Hist.* **10**. 105.

MOHAN, R. N. & MANWELL, R. D. (1969). *J. Parasit.* 55. 543.

PEIRCE, M. A. & BACKHURST, G. C. (1970). *E. Afr. wildl. J.* 8. 208.

Printed by H. R. GRUBB LTD., 15 Imperial Way, Purley Way, Croydon, CR9 4PY.

Reprinted from
TRANSACTIONS OF THE ROYAL SOCIETY OF TROPICAL MEDICINE AND HYGIENE,
Vol. 67. No. 1. pp. 7-8, 1973.

Gametogony of *Isospora*-type coccidia

MILES B. MARKUS

Department of Zoology and Applied Entomology, Imperial College, University of London, S.W.7

A sexual cycle resulting in the production of disporocystic, tetrazoic oöcysts takes place in the intestinal wall of at least some of the hosts of *Toxoplasma* (HUTCHISON et al., 1971; JEWELL et al., 1972), *Sarcocystis* (HEYDORN and ROMMEL, 1972) and *Isospora*. Sporocysts may be excreted for considerable lengths of time and the longer patent periods seem to occur in the cases of forms like *Isospora hominis* and *Sarcocystis*, where there is evidence of gametogony within the lamina propria of the intestine (LAARMAN and VAN DER SLIK-VAN DER VEEN, 1961; MARKUS, 1972). Reactivation of *Toxoplasma* oöcyst production in the cat (where development takes place in the epithelium and the patent period is comparatively short), following infection with *I. felis*, has been reported (CHESSUM, 1972). Oöcysts are now known to be important in the transmission of *Toxoplasma* from naturally infected domestic cats (WALLACE, 1971) to other animals (MUNDAY, 1972) and man (FLECK et al., 1972). Isosporan oöcysts can appear in the faeces of man, *inter alia*, following the consumption of meat infected with *Sarcocystis* (ROMMEL and HEYDORN, 1972); and are shed in kittens that have been given various tissues of mice previously fed *I. felis* and *I. rivolta* oöcysts (FRENKEL and DUBEY, 1972). In view of the morphological appearance of extra-intestinal stages of *Isospora* (DUBEY and FRENKEL, 1972), host records of haemogregarines need to be re-examined. The significance of the rôle of carnivorism in the transmission of coccidia also requires investigation. Even *Toxoplasma* (like *Besnoitia*) may not be restricted to warm-blooded animals as is generally believed (STONE and MANWELL, 1969).

Small numbers of isosporan oöcysts have been found in faeces of many adult mongooses in the western Transvaal, South Africa. In the case of a young yellow mongoose *Cynictis penicillata* with a moderately heavy infection of *Isospora* sp., the main developmental stages in epithelial cells of the small intestine could be seen together in a few adjoining sections. Pieces of intestine were fixed in Bouin's (aqueous), Carnoy's and Helly's fluids and in formol-saline. Sections were stained with (i) Heidenhain's iron haematoxylin and (ii) Ehrlich's haematoxylin and eosin. There were not many schizonts. Oöcysts and mature macrogametes predominated, although younger forms were also in evidence. Oöcysts from this individual fall within the size range given by BRAY (1954) for *I. garnhami* but the sporocysts are larger. Microgametogony is similar to that of *I. felis* (SHAH, 1971). Early microgametocytes were present. More advanced ones with fragmented nuclei and irregular fissures in the cytoplasm were located, as well as older microgametocytes with partially invaginated surfaces. At a still later stage of development, the microgametocytes contained spherical nuclei, mainly peripherally orientated. Extra-intestinal stages were not seen in imprints of the brain, heart, liver, spleen, lung or kidney of this animal (lymph nodes were not examined). Further details will be published elsewhere.

A travel grant and a research grant in support of field work were received from the South African Council for Scientific and Industrial Research and the C.S.I.R. Mammal Research Unit (University of Pretoria), respectively.

REFERENCES

BRAY, R. S. (1954). *Ann. trop. Med. Parasit.*, **48**, 405.
CHESSUM, B. S. (1972). *Br. vet. J.*, **128**, xxxiii.
DUBEY, J. P. & FRENKEL, J. K. (1972). *J. Protozool.*, **19**, 89.
FLECK, D. G., CHESSUM, B. S. & PERKINS, M. (1972). *Br. med. J.*, **3**, 111.
FRENKEL, J. K. & DUBEY, J. P. (1972). *J. infect. Dis.*, **125**, 69.
HEYDORN, A.-O. & ROMMEL, M. (1972). *Berl. Münch. tierärztl. Wschr.*, **85**, 333.
HUTCHISON, W. M., DUNACHIE, J. F., WORK, K. & SIIM, J. CHR. (1971). *Trans. R. Soc. trop. Med. Hyg.*, **65**, 380.

JEWELL, M. L., FRENKEL, J. K., JOHNSON, K. M., REED, V. & RUIZ, A. (1972). *Am. J. trop. Med. Hyg.*, **21**, 512.
LAARMAN, J. J. & VAN DER SLIK-VAN DER VEEN, J. V. (1961). *Ned. Tijdschr. Geneesk.*, **105**, 1731.
MARKUS, M. B. (1972). *Trans. R. Soc. trop. Med. Hyg.*, **66**, 673.
MUNDAY, B. L. (1972). *Res. vet. Sci.*, **13**, 100.
ROMMEL, M. & HEYDORN, A.-O. (1972). *Berl. Münch. tierärztl. Wschr.*, **85**, 143.
SHAH, H. L. (1971). *J. Protozool.*, **18**, 3.
STONE, W. B. & MANWELL, R. D. (1969). *Ibid.*, **16**, 99.
WALLACE, G. D. (1971). *J. infect. Dis.*, **124**, 227.

Printed by F. J PARSONS LTD., *London, Folkestone and Hastings.*

Dogs and Transmission of Toxoplasmosis

SIR,—*Toxoplasma gondii* oocysts from naturally infected domestic cats (Prof. S. Pampiglione and others, 5 May, p. 306) would seem to be of importance epidemiologically[1-3] and can remain viable in soil for long periods.[1 4] In several standard texts and papers the dog (in which *T. gondii* infection is also common) is implicated as a possible source of human toxoplasmosis. This, in the light of present knowledge, is misleading, and it should be stressed that formation of oocysts of *T. gondii* is known only in domestic cats and some wild felids.[5 6] They are not shed by dogs (not even when immunosuppressive drugs are used[7]) or various other vertebrates that have been given toxoplasmosis experimentally.[5 8 9] Nor has *T. gondii* been isolated in excretions or secretions of dogs successfully infected orally with oocysts.[7] Thus there is as yet no evidence for droplet infection, and the family dog would not appear to be important in the transmission of toxoplasmosis to man.

The primary source of infection in the case of dogs is probably raw meat containing tissue cysts. Filth flies have been shown to carry *T. gondii* oocysts and can contaminate food for up to 48 hours after contact with infected faeces[10] (contrary to popular belief, in nature faeces are often only partially covered with soil by the cat after being excreted). Many dogs are in the habit of snapping at flies and frequently succeed in catching and eating them. The significance of this in the transmission of canine toxoplasmosis remains to be determined.

As discussed elsewhere in a review of the symptoms, transmission, prevention, and treatment of toxoplasmosis,[11] human infections are usually acquired (1) transplacentally, (2) by the ingestion in raw meat of microscopic tissue cysts, or (3) by the inadvertent ingestion of oocysts, either directly or via transport hosts such as flies and cockroaches. In addition, accidental infection of laboratory workers with *T. gondii* (some cases being illustrative of transmission by wound contamination) and transmission of toxoplasmosis by leucocyte transfusion have been reported. There is a risk of transmitting *T. gondii* by normal blood transfusion.[11]—I am, etc.,

MILES B. MARKUS

Department of Zoology,
Imperial College,
London S.W.7

1 Fleck, D. G., Chessum, B. S., and Perkins, M., *British Medical Journal*, 1972, 3, 111.
2 Peterson, D. R., Tronca, E., and Bonin, P., *American Journal of Epidemiology*, 1972, 96, 215.
3 Wallace, G. D., Marshall, L., and Marshall, M., *American Journal of Epidemiology*, 1972, 95, 475.
4 Ruiz, A., Frénkel, J. K., and Cerdas, L., *Journal of Parasitology*, 1973, 59, 204.
5 Janitschke, K., and Werner, H., *Zeitschrift für Parasitenkunde*, 1972, 39, 247.
6 Jewell, M. L., Frenkel, J. K., Johnson, K. M., Reed, V., and Ruiz, A., *American Journal of Tropical Medicine and Hygiene*, 1972, 21, 512.
7 Kühn, D., Oppermann, W. H., Rödel, H., and Centurier, H., *Berliner und Münchener tierärztliche Wochenschrift*, 1972, 85, 309.
8 Draper, C. C., Killick-Kendrick, R., Hutchison, W. M., Siim, J. C., and Garnham, P. C. C., *British Medical Journal*, 1971, 2, 375.
9 Miller, N. L., Frenkel, J. K., and Dubey, J. P., *Journal of Parasitology*, 1972, 58, 928.
10 Wallace, G. D., *American Journal of Tropical Medicine and Hygiene*, 1971, 20, 411.
11 Markus, M. B., *South African Medical Journal*. In press.

Reprinted from the "S.A. Medical Journal", Vol. 47, 8th September 1973, pages 1588 - 1590

Symptoms, Transmission, Prevention and Treatment of Toxoplasmosis*

MILES B. MARKUS,† M.SC. (MED. PAR.) UNIV. LOND., B.SC., M.SC. UNIV. PRET., *Department of Medical Protozoology, London School of Hygiene and Tropical Medicine, London, UK*

SUMMARY

A concise, up-to-date review is presented, with special reference to developments during the past 3 years concerning oöcyst transmission in cat faeces.

Lymphadenopathy is the most frequently observed manifestation of symptomatic acquired toxoplasmosis. This may or may not be accompanied by one or more of the following: malaise, fatigue, fever, muscular pain, splenomegaly, hepatomegaly, abdominal pain, sore throat, headache, or rash. In more severe cases (e.g. in immunodeficient patients or those receiving immunosuppressive therapy) there may be encephalitis, hepatitis, pneumonitis, myocarditis, or pericarditis.

Damage resulting from congenital infection is to the central nervous system *inter alia*.

Pregnant women should exercise care when handling raw meat. They should wash their hands after handling domestic cats and before eating.

S. Afr. Med. J., 47, 1588 (1973).

The *South African Medical Journal* recently published an international recommendation[1] that 'the public as well as the medical profession be informed of the frequency, origins and effects of toxoplasmosis in their areas', that pregnant women and neonates be serologically tested, and that study of 'all environmental factors which contribute to the development, dissemination and treatment of toxoplasmosis' be undertaken. In a paper on clinical toxoplasmosis last year,[2] it was pointed out that the notion that approximately one-half billion humans currently harbour live parasites is 'poorly appreciated by the medical profession which has yet to include the disease in its day-to-day considerations'. An account of a case of fatal myocarditis in a 10-year-old girl,[3] probably caused by the ubiquitous protozoon *Toxoplasma gondii*, lists references to earlier papers on human toxoplasmosis in South Africa, some of which contain information that is now misleading or out of date.

The consequences of reactivation of quiescent *Toxoplasma* infection in immunologically compromised patients where the defence mechanisms have been rendered ineffective by underlying disease and/or treatment, can be lethal, and the protozoon is emerging as an important opportunistic pathogen in cases of malignancy[2,4-7] and organ (renal and cardiac) transplantation.[4,8] Early therapy with pyrimethamine and sulphadiazine may prove life-saving in such patients and thus toxoplasmosis should always be promptly considered where there are symptoms referable to brain (in particular), lungs, liver or heart.[5-7]

As in most other parts of the world, toxoplasmosis in both man and animals is common in Africa south of the Sahara,[3,9-16] where there almost certainly have been more overt clinical cases than have been reported.

SYMPTOMS

Acquired human toxoplasmosis, though usually subclinical, can mimic several conditions.[2,17,18] As was first stressed by Siim and others,[19] lymphadenopathy is the most usual symptom of clinical disease,[2,17] the involvement varying from enlargement of a single lymph node to generalized lymphadenopathy. Lymphadenopathy may or may not be accompanied by one or more of the following: malaise, fatigue, fever, muscular pain, splenomegaly, hepatomegaly, abdominal pain, sore throat, headache or rash. In more severe cases there may be encephalitis, hepatitis, pneumonitis, myocarditis or pericarditis. Toxoplasmosis is today recognized as being a common cause of lymphadenopathy in cases where the Paul-Bunnell test for glandular fever is negative.[2,18,20-23]

More dramatic are some of the manifestations of congenital toxoplasmosis, resulting from primary infection of the mother during pregnancy. Estimates of congenital toxoplasmosis per 1 000 live births range between 0,25 and 6 - 7 in different countries.[22] In addition to abortion of the foetus (probably rare), the effects of transplacental infection include microcephaly, hydrocephaly, cerebral calcification and seizure disorders in the infant. Some workers consider *Toxoplasma* to be an important cause of repeated human abortion but this requires further investigation.[17,24,25] Apart from damage to the central nervous system, there may be pneumonitis, fever, rash, generalized oedema, hepatosplenomegaly, jaundice, anaemia, lymphadenopathy, or myocarditis. Retinochoroiditis occurs in a large number of cases,[2,6,11,21,25] most frequently in the young adult and often in the absence of other symptoms. Whether retinochoroiditis can also result from acquired infection is not clear.

OÖCYST TRANSMISSION

Knowledge of the life cycle of *Toxoplasma* has been incomplete for many years but the discovery of coccidian-type asexual (schizogonic) and sexual (gametogonic) stages

* Date received: 21 March 1973.
† Present address: Dept of Zoology, Imperial College, University of London, SW7, UK.

in the intestinal epithelium of experimental domestic cats, resulting in the formation of oöcysts which are shed in the faeces,[26,27] has made it easy to understand how many human infections are acquired. The resistant oöcysts from naturally infected cats[28-31] can remain viable in water and soil for long periods[32,33] and as discussed elsewhere,[31-36] have been shown to infect man and animals in nature.

Production of oöcysts of *Toxoplasma* is known only in domestic cats and wild members of the family Felidae.[37-39] They are not shed by dogs (not even when immunosuppressive drugs are used[40]) or various other vertebrates that have been given toxoplasmosis experimentally.[38,39] The oöcysts, after becoming infective as a result of sporulation within 1 - 4 days after excretion, contain 2 sporocysts, each with 4 sporozoites. Thus the *Toxoplasma* oöcyst is morphologically similar to that of the coccidian genus *Isopora*[41] which, as far as mammals are concerned, occurs mainly in carnivores. Feline *Isospora* species and isosporan oöcysts in man are larger than the *Toxoplasma* oöcysts in cats. Human isosporosis, apparently the result of ingestion of tissue cysts (containing the cystozoites[42]) of *Sarcocystis* in uncooked meat of domestic animals,[43] is known in South Africa.[44] Coccidiosis in man is thought to be of little medical importance but it may be that, as in some animals,[45-47] stages can occur in tissues other than the intestine, with hitherto unknown effects. Unlike *Toxoplasma*, oöcyst transmission can take place directly from man to man in the case of *Isospora belli*, several reports being on record. Probably because of differing developmental sites in the intestinal wall,[36,48,49] oöcysts of *I. hominis* in man are shed for long periods, whereas the period in the case of *Toxoplasma* in the cat is comparatively short (1 - 3 weeks).

PREVENTION

Human toxoplasmosis is usually acquired transplacentally; by the ingestion of microscopic tissue cysts occurring in meat; or by the inadvertent ingestion of oöcysts, either directly or via transport hosts such as flies and cockroaches.[50] In addition, accidental infection of laboratory workers with *Toxoplasma*[6,32,39] (some cases being illustrative of transmission by wound contamination) and transmission of toxoplasmosis by leucocyte transfusion[51] have been reported. There would appear to be a risk of transmitting *Toxoplasma* by blood transfusion.[2,5,6,40,51-53]

Since the disease is primarily a danger to the foetus, pregnant women, particularly if seronegative, should exercise care when handling raw meat. After so doing they should not, for instance, prepare any food that is not going to be cooked, e.g. cold salad, without first washing the hands. They should also avoid unnecessarily close contact with the household cat and its litter tray, particularly if the animal is fed on raw meat or is in the habit of catching rats, mice or birds. Hands should be washed after handling the cat and before eating. Likewise, vegetables or fruit that may have become contaminated by soil containing cat faeces should be well rinsed.

Frenkel and Dubey[54] discuss, in some detail, the prevention of *Toxoplasma* infection in cats and methods by which the zoönotic danger can be reduced.

DIAGNOSIS AND TREATMENT

Subclinical congenital toxoplasmosis in neonates may not be uncommon and could be an important cause of central nervous system problems that only become apparent in later infancy or childhood.[5] Quantitation of immunoglobulin (IgM) in cord sera in conjunction with an IgM indirect flourescent antibody test would seem to be useful for early screening of the newborn.[5]

Provided that reasonable precautions are taken (see 'Prevention'), it is debatable whether expectant mothers should be serologically tested as a routine for antibodies to *Toxoplasma*, unless the person concerned is particularly at risk or develops fever, rash or lymphadenopathy during her pregnancy.[18,51]

Current serological and parasitological diagnostic techniques and treatment for toxoplasmosis (including possible contra-indications[51,55]) are discussed in some of the papers listed.[2,5-7,17,18,21,33,55-57] Where treatment is indicated, oral administration of the following drugs in divided doses for 1 month has been suggested:[57] '(*i*) sulphadiazine (4 g daily in adults; 100 mg/kg body weight per day in children); and (*ii*) pyrimethamine (25 mg/day in adults and 1 mg/kg/day in children) with a double dose used for the first 3 days. In addition, extra folinic acid will correct toxic effects and does not impair the efficiency of therapy. Leucovorin calcium (6 mg/day for adults and 1 mg/day for children) and given in conjunction with fresh baker's yeast (100 mg daily) should be effective for this purpose'. White blood cell and platelet counts should be carried out weekly and if either or both decrease significantly, pyrimethamine therapy should be discontinued.

I acknowledge receipt of a travel grant from the South African Council for Scientific and Industrial Research and financial assistance from the Mammal Research Unit, Department of Zoology, University of Pretoria, in support of recent field work.

REFERENCES

1. Klenerman, P. (1973): S. Afr. Med. J., 47, 4.
2. Kean, B. H. (1972): Trans. Roy. Soc. Trop. Med. Hyg., 66, 549.
3. Van der Horst, R., Klenerman, P., Schonland, M. and Gotsman, M. S. (1972): S. Afr. Med. J., 46, 949.
4. Cohen, S. N. (1970): J. Amer. Med. Assoc., 211, 657.
5. Remington, J. S. (1970): Ann. Rev. Med., 21, 201.
6. Remington, J. S. and Gentry, L. O. (1970): Ann. N. Y. Acad. Sci., 174, 1006.
7. Carey, R. M., Kimball, A. C., Armstrong, D. and Lieberman, P. H. (1973): Amer. J. Med., 54, 30.
8. Stinson, E. B., Beiber, C. P., Griepp, R. B., Clark, D. A., Shumway, N. E. and Remington, J. S. (1971): Ann. Intern. Med., 74, 22.
9. Wiseman, R. A., Fleck, D. G. and Woodruff, A. W. (1970): Brit. Med. J., 4, 152.
10. Dodge, J. S. (1972): J. Hyg. (Lond.), 70, 763.
11. Olurin, O., Fleck, D. G. and Osuntokun, B. (1972): Trop. Geogr. Med., 24, 240.
12. Quarcoopome, C. O. (1972): Ghana Med. J., 11, 256.
13. Roever-Bennet, H. de (1972): Trop. Geogr. Med., 24, 7.
14. Bigalke, R. D., Tustin, R. C., du Plessis, J. L., Basson, P. A. and McCully, R. M. (1967): J. S. Afr. Vet. Med. Assoc., 37, 243.
15. Du Plessis, J. L., Bigalke, R. D. and Gurnell, T. O. (1967): *Ibid.*, 38, 79.
16. Discussion (1972): Trans. Roy. Soc. Trop. Med. Hyg., 66, 570.
17. Hentsch, D. ed. (1971): *Toxoplasmosis*. Berne: Hans Huber.
18. Krogstad, D. J., Juranek, D. D. and Walls, K. W. (1972): Ann. Intern. Med., 77, 773.
19. Work, K. (1971): Acta path. microbiol. scand., sect. B, suppl. 221.
20. Beverley, J. K. A. (1973): Brit. Med. J., 2, 475.
21. Boughton, C. R. (1970): Med. J. Aust., 2, 418.
22. Jacobs, L. (1970): J. Wildl. Dis., 6, 305.
23. Field, P. R., Moyle, G. G. and Parnell, P. M. (1972): Med. J. Aust., 2, 196.
24. Southern, P. M. (1972): Obstet. and Gynec., 39, 45.
25. Perkins E. S. (1973): Brit. J. Ophthal., 57, 1.

26. Dubey, J. P., Miller, N. L. and Frenkel, J. K. (1970): J. Exp. Med., **132**, 636.
27. Hutchison, W. M., Dunachie, J. F., Work, K. and Siim, J. Chr. (1971): Trans. Roy Soc. Trop. Med. Hyg., **65**, 380.
28. Wallace, G. D. (1973): Amer. J. Trop. Med. Hyg., **22**, 313.
29. Janitschke, K. and Kühn, D. (1972): Berl. Münch. tierärztl. Wschr., **85**, 46.
30. Werner, J. K. and Walton, B. C. (1972): J. Parasit., **58**, 1148.
31. Pampiglione, S., Poglayen, G., Arnone, B. and de Lalla, F. (1973): Brit. Med. J., **2**, 306.
32. Hutchison, W. M., Dunachie, J. F. and Siim, J. Chr. (1972): Proc. Roy. Soc. Med., **65**, 1001.
33. Ruiz, A., Frenkel, J. K. and Cerdas, L. (1973): J. Parasit., **59**, 204.
34. Wallace, G. D., Marshall, L. and Marshall, M. (1972): Amer. J. Epidem., **95**, 475.
35. Peterson, D. R., Tronca, E. and Bonin, P. (1972): *Ibid.*, **96**, 215.
36. Markus, M. B. (1973): Trans. Roy. Soc. Trop. Med. Hyg., **67**, 7.
37. Jewell, M. L., Frenkel, J. K., Johnson, K. M., Reed, V. and Ruiz, A. (1972): Amer. J. Trop. Med. Hyg., **21**, 512.
38. Janitschke, K. and Werner, H. (1972): Z. Parasitenk., **39**, 247.
39. Miller, N. L., Frenkel, J. K. and Dubey, J. P. (1972): J. Parasit., **58**, 928.
40. Kühn, D., Oppermann, W. H., Rödel, H. and Centurier, H. (1972): Berl. Münch. tierärztl. Wschr., **85**, 309.
41. Garnham, P. C. C. (1972): Int. J. Syst. Bact., **22**, 403.
42. Hoare, C. A. (1972): J. Trop. Med. Hyg., **75**, 56.
43. Rommel, M. and Heydorn, A.-O. (1972): Berl. Münch. tierärztl. Wschr., **85**, 143.
44. Elsdon-Dew, R. and Freedman, L. (1953): Trans. Roy. Soc. Trop. Med. Hyg., **47**, 209.
45. McCully, R. M., Basson, P. A., de Vos, V. and de Vos, A. J. (1970): Onderstepoort J. Vet. Res., **37**, 45.
46. Frenkel, J. K. and Dubey, J. P. (1972): J. Infect. Dis., **125**, 69.
47. Lainson, R. (1972): J. Protozool., **19**, 582.
48. Laarman, J. J. and Van der Slik-Van der Veen, J. V. (1961): Ned. T. Geneesk., **105**, 1731.
49. Markus, M. B. (1972): Trans. Roy. Soc. Trop. Med. Hyg., **66**, 673.
50. Wallace, G. D. (1972): J. Infect. Dis., **126**, 545.
51. Siegel, S. E., Lunde, M. N., Gelderman, A. H., Halterman, R. H., Brown, J. A., Levine, A. S. and Craw, R. G. jnr (1971): Blood, **37**, 388.
52. Draper, C. C., Killick-Kendrick, R., Hutchison, W. M., Siim, J. Chr. and Garnham, P. C. C. (1971): Brit. Med. J., **2**, 375.
53. Frenkel, J. K. (1971): Curr. Top. Path., **54**, 28.
54. Frenkel, J. K. and Dubey, J. P. (1972): J. Infect. Dis., **126**, 664.
55. Jacobs, L. (1967): Advanc. Parasitol., **5**, 1.
56. World Health Organization (1969): Wld Hlth Org. Tech. Rep. Ser. No. 431.
57. Gelderman, A. H. (1972): J. Amer. Med. Assoc., **222**, 713.

PIONEER 32990

New England Journal of Medicine,
Vol. 289, No. 18, pp. 980-981,
November 1, 1973.

SEROLOGY OF TOXOPLASMOSIS, ISOSPOROSIS AND SARCOSPORIDIOSIS

To the Editor: After the discovery of isosporan oocysts in the life cycle of *Toxoplasma gondii,* the important question of the specificity of current serologic tests for antibodies to *T. gondii* was raised by several authors. The suggestion of Stagno et al. (N Engl J Med 284:853, 1971) that there may be common antigenicity between *T. gondii* and *Isospora belli* has been disputed by Eaton et al. (N Engl J Med 288:797, 1973). Additional information indicative of an absence of any marked cross-reactivity between *T. gondii* and isospora is provided by Doby and Beaucournu,[1] who summarize earlier records (including those relating to isospora species of animals), with two exceptions.[2,3] Furthermore, it is apparent from a number of recent papers that prior infections of isospora in cats do not influence susceptibility to *T. gondii* or vice versa.

Isosporan oocysts indistinguishable from those of *I. hominis* are shed in man after ingestion in uncooked meat of tissue cysts of *Sarcocystis fusiformis* from cattle and *S. miescheriana* from swine.[4] As incidental to collaborative experimental work (Draper, Garnham, Hutchison, Killick-Kendrick, Markus and Siim) on sarcocystis in animals, to be published elsewhere, human serum specimens were tested in Draper's laboratory, with use of *S. fusiformis* antigen prepared by liberating cystozoites from macroscopic cysts extracted from infected bovine diaphragm. Our preliminary findings in the indirect fluorescent-antibody test suggest an absence of cross-reaction between *S. fusiformis* (in the light of present knowledge, a stage in the life cycle of *I. hominis*[4]) and *T. gondii;* persons reacting with what is apparently a positive titer (found up to a dilution of 1:1024) may prove to be (or to have been) *I. hominis* carriers. Further experimentation — e.g., inactivation of serum of adults[5,6] — is indicated to assess the value of these results. Doby and Beaucournu,[1] using *T. gondii* antigen and serum of known carriers of *I. hominis* in the indirect fluorescent-antibody test, also demonstrated that the two protozoa are immunologically distinct.

As far as the tissue stage of sarcocystis is concerned, the specificity of various serologic tests for *T. gondii* has been confirmed by earlier workers who used serums from man and monkeys with infections of sarcocystis species and serum of sheep with *S. tenella* infections.[5-13] Wallace,[14] in studying the life cycle of an animal parasite that was either an unusual strain of *T. gondii* or a species of sarcocystis, found that this organism and *T. gondii* share a few antigens but that there is little or no cross-immunity.

It must be concluded that there are as yet no grounds for questioning the reliability of routine serologic tests for human toxoplasmosis.

Miles B. Markus, M.Sc. (Med. Par.), M.Sc.
London, England University of London

1. Doby JM, Beaucournu JC: Absence de réactions croisées en immunofluorescence indirecte entre sérum de porteurs de *Isospora hominis* et antigènes *Toxoplasma.* Bull Soc Pathol Exot 65:404-409, 1972
2. de Andrade CM, Weiland G: Serologische Untersuchungen zur Feststellung gemeinsamer Antigene von Toxoplasmen, Sarkosporidien und Kokzidien. Berl Munch Tierarztl Wochenschr 84:61-64, 1971
3. Draper CC, Killick-Kendrick R, Hutchison WM, et al: Experimental toxoplasmosis in chimpanzees. Br Med J 2:375-378, 1971
4. Rommel M, Heydorn A-O: Beiträge zum Lebenszyklus der Sarkosporidien III. *Isospora hominis* (Railliet und Lucet, 1891) Wenyon, 1923, eine Dauerform der Sarkosporidien des Rindes und des Schweins. Berl Munch Tierarztl Wochenschr 85:143-145, 1972
5. Cathie IAB: An appraisal of the diagnostic value of the serological tests for toxoplasmosis. Trans R Soc Trop Med Hyg 51:104-110, 1957
6. Cathie IAB, Cecil GW: Sarcospores and toxoplasm serology: an investigation of their alleged cross-reaction. Lancet 1:816-818, 1957
7. Awad FI: The complement-fixation test in the diagnosis of sarcosporidiosis. Am J Vet Res 19:1010-1012, 1958
8. Awad FI, Lainson R: A note on the serology of sarcosporidiosis and toxoplasmosis. J Clin Pathol 7:152-156, 1954
9. Bordjochki A, Conitch V, Petrovitch Z, et al: La technique de l'immunofluorescence pour le diagnostic de la-sarcosporidiose. Comptes Rendus 1er multicolloque européen de parasitologie, Rennes, 1971, pp 285-287
10. Fulton JD, Voller A: Evaluation of immunofluorescent and direct agglutination methods for detection of specific *Toxoplasma* antibodies. Br Med J 2:1173-1175, 1964
11. Kulasiri C: The specificity of the Sabin-Feldman dye test with reference to protozoal infections. J Clin Pathol 13:339-348, 1960
12. Piekarski G, Saathoff M: Vergleichende serologische Untersuchungen mit Sarcosporidien- und *Toxoplasma*-Antigenen. Z Parasitenkd 21:363-380, 1962
13. Rommel M, Heydorn A-O, Gruber F: Beiträge zum Lebenzyklus der Sarkosporidien I. Die Sporozyste von *S. tenella* in den Fäzes der Katze. Berl Munch Tierarztl Wochenschr 85:101-105, 1972
14. Wallace GD: *Sarcocystis* in mice inoculated with *Toxoplasma*-like oocysts from cat feces. Science 180:1375-1377, 1973

Reprinted from
TRANSACTIONS OF THE ROYAL SOCIETY OF TROPICAL MEDICINE AND HYGIENE.
Vol. 67. No. 5. p. 723, 1973.

AFRICAN TRYPANOSOMIASIS AND TOXOPLASMOSIS

SIR,—The question of whether human African trypanosomiasis sera can give false positives in the indirect fluorescent antibody test for toxoplasmosis has been raised by SEAH and GABRIELIAN (1972). There is some evidence that this is not the case as cross reaction has not been shown in the complement fixation, direct agglutination, indirect fluorescent antibody or dye tests (BEVERLEY, 1957; CATHIE, 1957; FULTON and VOLLER, 1964).

I am, etc.,

MILES B. MARKUS,
Department of Zoology and Applied Entomology,
Imperial College,
University of London, S.W.7.

16 *July*, 1973

REFERENCES

BEVERLEY, J. K. A. (1957). *Trans. R. Soc. trop. Med. Hyg.*, **51**, 118.
CATHIE, I. A. B. (1957). *Ibid.*, **51**, 104.
FULTON, J. D. & VOLLER, A. (1964). *Br. med. J.*, **2**, 1173.
SEAH, S. K. K. & GABRIELIAN, S. (1972). *Trans. R. Soc. trop. Med. Hyg.*, **66**, 807.

From The Medical Journal of Australia, 19 January 1974 (Vol. 1, No. 3), p. 80 only.

DIFFERENTIATION OF COCCIDIA IN CATS AND TRANSMISSION OF TOXOPLASMOSIS

SIR: Some points touched on in the articles on toxoplasmosis in the Journal, June 30, invite comment.

A puppy was suggested as one of the possible sources of infection in a case of congenital toxoplasmosis. Subclinical canine toxoplasmosis is very common. However, there is as yet no evidence that close contact with household pets other than cats can result in human infection. *Toxoplasma gondii* has not been isolated from excretions or secretions of dogs[1] and aerosol transmission of *T. gondii* is unknown, in spite of statements in the literature to the effect that it takes place. The significance of the frequency with which the upper cervical lymph nodes in man are affected in lymphadenopathic toxoplasmosis[2] remains to be determined. It is conceivable that the point of entry could be the upper respiratory tract, following inhalation of oocysts,[3] or the upper digestive tract, following penetration of the mucosa by cystozoites.

In the editorial (Journal, June 30) it was stated that infective *T. gondii* oocysts, after being ingested by a cat, will give rise to the typical coccidian cycle in the gut. This is an over-simplification (although it is true in the case of *Isospora felis* and *I. rivolta*). Whilst the oocyst stage of *T. gondii* is apparently highly infectious (for example, only small numbers are required to infect wild rats), it is not efficient in producing the complete oocyst-to-oocyst cycle in the cat.[4,5] Carnivorism is important and the full life-cycle in cats is dependent on their ingesting tissue cysts of *T. gondii* in raw flesh.

Mr B. L. Munday (Journal, September 15) provides a concise summary of precautions that might be taken by pregnant women. It would be as well to bear in mind that as coprophagous arthropods like flies, cockroaches, earthworms and dung beetles may play a role in the epidemiology of toxoplasmosis by transporting oocysts,[6,7,8,9,10] flies should be kept away from food.

Reference was made in the editorial (Journal, June 30) to the similarity between *T. gondii* oocysts and those of *I. bigemina*. Even recently, the latter name appears to have been used for more than one coccidium found in cats[11]—oocysts measuring approximately 12 × 10μ are likely to be (but are not necessarily[12]) those of *T. gondii*; and some slightly larger coccidia occurring in cat fæces mainly as free, sporulated sporocysts are now known to be stages in the life cycle of *Sarcocystis*.[13,14,15] As elsewhere, species of *Sarcocystis* are likely to be common parasites of herbivores in Australia.[16] Neither *T. gondii* nor *Sarcocystis* is as commonly seen in cats as are the larger *I. felis* and *I. rivolta*. Thus at least four different types of isosporan oocyst, all of which are figured in a recent paper,[17] may be shed in the fæces of cats. Sporocysts of *Sarcocystis*, because of their subepithelial location in the intestine, are shed for much longer periods than are *I. felis*, *I. rivolta* or *T. gondii*.[18] The "small race of *I. bigemina*" in the dog is not the same as *T. gondii*[19,20] (as some workers have thought) and as was pointed out in your editorial, only feline species are known to excrete *T. gondii* oocysts. In spite of its close relationship to other Isospora-type coccidia, *T. gondii* would appear to be immunologically distinct and there are as yet no grounds for questioning the reliability of routine serological tests for human toxoplasmosis.[21]

Department of Zoology,
Imperial College,
University of London,
London, S.W. 7.

M. B. MARKUS.

[1] Kühn, D., Oppermann, W. H., Rödel, H., and Centurier, H., *Berl. Münch. tierärztl. Wschr.*, 1972, 85: 309.

[2] Dorfman, R. F., and Remington, J. S., *New Engl. J. Med.*, 1973, 289: 878.

[3] Beverley, J. K. A., *Brit. med. J.*, 1973, 2: 175.

[4] Dubey, J. P., Miller, N. L., and Frenkel, J. K., *J. exp. Med.*, 1970, 132: 636.

[5] Wallace, G. D., *Amer. J. trop. Med. Hyg.*, 1973, 22: 313.

[6] Dubey, J. P., Miller, N. L., and Frenkel, J. K., *J. Parasit.*, 1970, 56: 447.

[7] Zajíček, D., and Páv, J., *Folia Parasit.*, 1972, 19: 369.

[8] Markus, M. B., *Brit. med. J.*, 1973, 2: 666.

[9] Wallace, G. D., *Amer. J. trop. Med. Hyg.*, 1973, 22: 456.

[10] Markus, M. B., *Ann. trop. Med. Parasit.*, in the press.

[11] Shah, H. L., *J. Protozool.*, 1970, 17: 603.

[12] Wallace, G. D., *Science*, 1973, 180: 1375.

[13] Heydorn, A.-O., and Rommel, M., *Berl. Münch. tierärztl. Wschr.*, 1972, 85: 333.

[14] Markus, M. B., *Meat Hyg.*, in press.

[15] Markus, M. B., Draper, C. C., Hutchison, W. M., Killick-Kendrick, R., and Garnham, P. C. C., *Trans. Roy. Soc. trop. Med. Hyg.*, in press.

[16] Whiting, R. H., *Aust. vet. J.*, 1972, 48: 449.

[17] Dubey, J. P., *J. Amer. vet. med. Ass.*, 1973, 162: 873.

[18] Markus, M. B., *S. Afr. Med. J.*, 1973, 47: 1588.

[19] Heydorn, A.-O., *Berl. Münch. tierärztl. Wschr.*, 1973, 86: 323.

[20] Zukovic, M., Wikerhauser, T., Dzakula, N., and Magud, I., *Acta Parasit. Jugoslav.*, 1973, 4: 43.

[21] Markus, M. B., *New Engl. J. Med.*, 1973, 289: 980.

Reprinted from
TRANSACTIONS OF THE ROYAL SOCIETY OF TROPICAL MEDICINE AND HYGIENE, Vol. 68. No. 1. p. 3, 1974.

Attempted infection of chimpanzees and cats with *Sarcocystis* of cattle

M. B. MARKUS*, C. C. DRAPER†, W. M. HUTCHISON‡, R. KILLICK-KENDRICK* AND P. C. C. GARNHAM*

**Department of Zoology and Applied Entomology, Imperial College, University of London, S.W.7.*
†*Ross Institute, London School of Hygiene and Tropical Medicine, Keppel Street, W.C.*1
‡*Department of Biology, University of Strathclyde, Glasgow C.*1

After eating raw beef containing tissue cysts of *Sarcocystis* of cattle (currently known as *Sarcocystis fusiformis*), 2 human volunteers excreted oöcysts and free sporocysts morphologically indistinguishable from *Isospora hominis* (ROMMEL and HEYDORN, 1972). Cats are likewise susceptible (HEYDORN and ROMMEL, 1972a, b). In the hope of obtaining information concerning the human infection (e.g. intestinal and possible extra-intestinal stages) by using a higher ape, attempts were made to infect 4 splenectomized chimpanzees and, as controls, 4 specific pathogen-free cats. The animals were at different times fed minced cattle diaphragm or heart containing *S. fusiformis* or a suspension, in saline, of *S. fusiformis* cysts from bovine cardiac muscle.

Only one cat, which had eaten infected diaphragm, shed *S. fusiformis* sporocysts (or, more rarely, intact oöcysts). The prepatent period was approximately 7 days. Sporocysts similar in appearance to those examined by HEYDORN and ROMMEL (1972a) were passed for at least 11 weeks (they were still being shed at the time of the laboratory meeting). This confirms the coccidial nature of *Sarcocystis*. The mean size of 50 sporocysts was 12·9 × 8·7 (11·6 – 14·9 × 8·2 – 10·4; S.D. both length and width = 0·6) μm.

Cystozoites (HOARE, 1972) liberated from macroscopic cysts of *S. fusiformis* in bovine diaphragm were used as antigen in the indirect fluorescent antibody test. No rising titres were observed in any of the experimental animals, not even in the cat in which gametogony occurred. To date (10½ weeks post infection) this cat has remained sero-negative. It may be noted that dye test antibody titres in cats following infection with tissue cysts of *Toxoplasma gondii* tend (regardless of strain) to be lower than in other animals (e.g. WALLACE, 1973). The formation of antibodies to *Toxoplasma* in cats fed tissue cysts can be delayed and it may even be that extra-intestinal infection is necessary for antibody production (DUBEY and FRENKEL, 1972).

In spite of the fact that sporocysts morphologically similar to those of *I. hominis* have been recorded from a chimpanzee (RIJPSTRA, 1967), it is possible that man and dogs are more susceptible to infection with *S. fusiformis* than are chimpanzees and cats (MARKUS et al., in press).

REFERENCES

DUBEY, J. P. & FRENKEL, J. K. (1972). *J. Protozool.*, **19**, 155.
HEYDORN, A.-O. & ROMMEL, M. (1972a). *Berl. Münch. tierärztl. Wschr.*, **85**, 121.
——— (1972b). *Ibid.*, **85**, 333.
HOARE, C. A. (1972). *J. trop. Med. Hyg.*, **75**, 56.
RIJPSTRA, A. C. (1967). *Proc. K. ned. Akad. Wet.*, ser. C, **70**, 395.
ROMMEL, M. & HEYDORN, A.-O. (1972). *Berl. Münch. tierärztl. Wschr.*, **85**, 143.
WALLACE, G. D. (1973). *Am. J. trop. Med. Hyg.*, **22**, 313.

We thank Dr. Elizabeth U. Canning and Dr. A. O. Heydorn for their interest and Mr. Sherali Thaver for technical assistance. At the time of one of the chimpanzee experiments, Dr. Heydorn kindly arranged to have additional control animals infected in his laboratory (*vide* MARKUS et al., in press). M.B.M. acknowledges support from the South African Medical Research Council and a S.A. Council for Scientific and Industrial Research travel grant. Work at Strathclyde University is supported in part by The World Health Organization, Geneva.

Annals of Tropical Medicine and Parasitology, 1974. Vol. 68, No. 2

Earthworms and coccidian oocysts

During the course of a survey of the food eaten by stray and domiciled cats in north London (Markus, unpublished), it became apparent that cats in this urban area regularly catch and consume wild birds. Certain species of birds were observed feeding on earthworms in gardens following rainy periods when the soil was moist and worms came to the surface.

It has been shown that *Toxoplasma gondii* oocysts from buried cat faeces are viable after being brought to the surface by earthworms and fed to mice (Dubey *et al.*, 1970). As antibody detectable by the dye test does not necessarily develop in birds infected with *Toxoplasma* oocysts (Miller *et al.*, 1972; Wallace, 1973), it was decided to investigate the infectivity of coccidian oocysts in earthworms and worm casts in regard to birds by using *Eimeria tenella*. 455 000 freshly sporulated oocysts of the Weybridge strain (supplied by Dr. L. P. Joyner of the Central Veterinary Laboratory, Weybridge) were mixed with a 1 cm layer of soil moistened with tap water, in the bottom of each of a number of sealed plastic containers 9 cm in diameter. One specimen of *Lumbricus terrestris*, weighing approximately 1·5 g, was introduced into each container. The containers were kept in darkness at room temperature for 1 week, after which the worms were carefully rinsed with water and placed in new dishes containing a 3 cm layer of humid soil, into which they burrowed. Worms were washed again at intervals, dissected and the gut contents of each administered *per os* in water to a 3-day-old Apollo cockerel. Earthworm casts were also fed to chicks.

There is no indication that the passage of coccidian oocysts through earthworms affects their viability. The later infections (see Table) tended to be light. This can be ascribed to the fact that material in burrowing *L. terrestris* takes about 12 hours to pass through the alimentary canal, as opposed to about 20 hours when the worms are feeding (Parle, 1963). Microscopically the oocysts in earthworm casts did not differ from fresh oocysts.

As reviewed elsewhere (Markus, 1973*a*), the ubiquitous (Beverley, 1973) protozoon *T. gondii* can cause serious disease in man and is proving to be an opportunistic and lethal pathogen in cancer and organ transplant patients. Following the discovery in cats of typical coccidian sexual reproduction of *Toxoplasma* (Hutchison *et al.*, 1971), resulting in formation of oocysts which are shed in the faeces and which can persist in soil (Fleck *et al.*, 1972;

TABLE

Isolation of viable *Eimeria tenella* in earthworms and worm casts

Hours after contact with soil containing oocysts	Worm	Positive soil control	Negative soil control
0	6/6*	6/6	0/6
4	6/6	6/6	0/6
8	5/6	6/6	0/6
12	5/6	6/6	0/6
Earthworm casts	6/6	6/6	0/6

*Number of chicks in which infection detected/number fed material.

Ruiz *et al.*, 1973), it has been shown that the oocyst stage is not efficient in producing the complete oocyst-to-oocyst cycle in domestic or wild felines; and in the case of stray domestic cats the natural life cycle is dependent on small avian and mammalian intermediate hosts that form their prey. Furthermore, only the extra-intestinal or tissue phase of the developmental cycle takes place in non-feline hosts when tissue cysts in uncooked meat or infective oocysts are ingested (Dubey, 1973; Frenkel, 1973; Wallace, 1973). Most small mammals and birds become infected easily with the oocyst stage of *Toxoplasma* (which Heydorn (1973) and Žuković *et al.* (1973) have shown is not the same as the small race of *Isopora bigemina* of the dog as some workers have thought) and survivors function as long-term carriers of the parasite (Miller *et al.*, 1972; Dubey and Frenkel, 1973; Wallace, 1973). Natural *Toxoplasma* infections in wild birds in Europe appear to be common (Čatár, 1973).

In areas of human habitation with a large cat population and small vegetable and flower gardens, a cat-earthworm-bird-cat cycle would facilitate contamination of the soil with resistant (Frenkel and Dubey, 1973) *Toxoplasma* oocysts. These are transmissible to man (Fleck *et al.*, 1972; Miller *et al.*, 1972) and animals (Miller *et al.*, 1972; Dubey and Frenkel, 1973; Wallace, 1973) via the mouth and possibly even by inhalation (Beverley, 1973). Transport hosts such as flies and cockroaches also play a role (Markus, 1973*b*; Wallace, 1973). Some small mammals, by accidentally ingesting oocysts (e.g. in grooming) that have been moved to the surface by earthworms, or perhaps in some cases by actually consuming surface-feeding earthworms at night, could establish a similar cycle. The omnivorous *Rattus rattus*, for example, is a well-known *Toxoplasma* reservoir and will become infected after ingesting small numbers of oocysts (Wallace, 1973).

The author acknowledges support from the South African Medical Research Council and a S.A. Council for Scientific and Industrial Research travel grant.

Miles B. Markus
Department of Zoology and Applied Entomology,
Imperial College,
University of London,
London SW7 2AZ.

5 November 1973

REFERENCES

Beverley, J. K. A. (1973). *British Medical Journal*, **2**, 475–478.
Čatár, G. (1973). *Ninth International Congress on Tropical Medicine and Malaria (Abstracts of Communications)*, **2**, 148.
Dubey, J. P. (1973). *Journal of the American Veterinary Medical Association*, **162**, 873–877.
Dubey, J. P. & Frenkel, J. K. (1973). *Journal of Parasitology*, **59**, 505–512.
Dubey, J. P., Miller, N. L. & Frenkel, J. K. (1970). *Journal of Parasitology*, **56**, 447–456.
Fleck, D. G., Chessum, B. S. & Perkins, M. (1972). *British Medical Journal*, **3**, 111–112.
Frenkel, J. K. (1973). *BioScience*, **23**, 343–352.
Frenkel, J. K. & Dubey, J. P. (1973). *Journal of Parasitology*, **59**, 587–588.
Heydorn, A. O. (1973). *Berliner und Münchener Tierärztliche Wochenschrift*, **86**, 323–329.
Hutchinson, W. M., Dunachie, J. F., Work, K. & Siim, J. Chr. (1971). *Transactions of the Royal Society of Tropical Medicine and Hygiene*, **65**, 380–399.
Markus, M. B. (1973*a*). *South African Medical Journal*, **47**, 1588–1590.
Markus, M. B. (1973*b*). *British Medical Journal*, **2**, 666.
Miller, N. L., Frenkel, J. K. & Dubey, J. P. (1972). *Journal of Parasitology*, **58**, 928–937.
Parle, J. N. (1963). *Journal of General Microbiology*, **31**, 1–11.
Ruiz, A., Frenkel, J. K. & Cerdas, L. (1973). *Journal of Parasitology*, **59**, 204–206.
Wallace, G. D. (1973). *American Journal of Tropical Medicine and Hygiene*, **22**, 456–464.
Žuković, M., Wikerhauser, T., Džakula, N. & Magud, I. (1973). *Acta Parasitologica Iugoslavica*, **4**, 43–45.

Proc. 3rd Intern. Congr. Parasit. (Munich) 1: 98-99, 1974.

BIRDS, COPROPHAGOUS ARTHROPODS AND COCCIDIAN OOCYSTS

M. B. MARKUS

Department of Zoology and Applied Entomology, Imperial College, University of London, London, U. K.

Preliminary investigations have been conducted on possible mechanisms by which oocysts of *Toxoplasma* and *Sarcocystis* passed by carnivores may be dispersed in the environment of non-carnivorous hosts.

Marked house flies *Musca domestica* flew from cat faeces in a garden (emptied indoor litter tray) to a nearby kitchen and blowflies *Calliphora erythrocephala* moved from dog faeces on a public footpath to cows in an adjoining field. In the laboratory, intact *Sarcocystis fusiformis* sporocysts were recovered inside 2 out of 50 *C. erythrocephala* which had fed on faeces from an experimental cat. Even if *Toxoplasma* oocysts are shed by felines in epidemiologically significant numbers, it is more difficult to see how large outbreaks of oocyst-induced ovine toxoplasmosis can occur in open pastures than it is to understand the high prevalence of *Sarcocystis* in old cattle and sheep, which have closer contact with dogs than with cats.

There are published records of the transportation of at least 12 kinds of helminth eggs by wild flies. Coccidian oocysts pass undamaged through the digestive tract of invertebrates: *Isospora felis*/cockroaches; *Toxoplasma*/earthworms, flies and cockroaches; *Eimeria*/flies, earthworms and dung beetles —eaten by wild boars, which often have toxoplasmosis. Flies might facilitate transmission where predators and prey congregate, e.g. waterholes. A moist habitat would be a suitable environment where e.g. ducks, buffalo, antelope, baboons and the Brazilian tortoise could acquire infections.

Birds like gulls are thought to carry *Taenia saginata* eggs from sewage to pastures. Perhaps *Isopora hominis* (i. e. *Sarcocystis)* sporocysts are disseminated in the same way. In some parts of the world, waders (particularly *Charadriidae* and *Scolopacidae)* might play a significant role.

Filth flies and other coprophagous arthropods could transport oocysts and sporocysts for short distances, whilst birds might be important in disseminating them over a wider area.

Proc. 3rd Intern. Congr. Parasit. (Munich) 3: 1675-1676, 1974.

ARTHROPOD-BORNE DISEASE AS A POSSIBLE LIMITING FACTOR IN AVIAN DISTRIBUTION

M. B. MARKUS

Department of Zoology and Applied Entomology, Imperial College, University of London, London, U. K.

Of the ca 2000 kinds of birds inhabiting the Ethiopian zoogeographical region, approximately 120 species occur in tropical montane evergreen forests at elevations of more than 1525 metres. Despite their potential mobility, only about 39 typically montane forest species are also found in low-lying country, even though the intervening areas separating montane forests vary from only a few to many hundreds of kilometres. This phenomenon (also apparent in e. g. tropical South East Asia and equatorial South America) is difficult to explain, particularly as such species do cross tracts of "unsuitable" country and since some birds that are restricted to montane forest in tropical Africa occur at all altitudes down to sea level in the South.

WARNER found that arthropod-borne disease in the Hawaiian islands (bird malaria and avian pox in particular) limits the distribution of the Drepaniidae to elevations above approximately 600 metres. ROWAN raised the question of whether the distribution of certain African birds could be determined in the same way. This might well be the case if the virus/haematozoon in wild birds that are not immunogenetically resistant is as virulent as in some exotic caged species. Avian malaria and bird pox are not uncommon in both migratory and resident African and European birds. Palaearctic migrants visit Africa annually (mainly tropical parts) in such vast numbers that the potential for transport of arthropod-transmitted diseases is very great. Likewise, a number of local migrants from the tropics move southwards (CLANCEY, MARKUS, PROZESKY and WINTERBOTTOM, 1969, Check list of the birds of South Africa).

Field experiments could be conducted in tropical regions, including e. g. Ethiopia (inexplicably few species in montane forest), the Kenya-Tanzania border area (unusually high degree of subspeciation in montane populations separated by comparatively short distances) and Madagascar (avifauna inexplicably poor).

International Journal for Parasitology. 1974. *Vol.* 4. *pp.* 609–612. *Pergamon Press. Printed in Great Britain.*

ARTHROPOD-BORNE DISEASE AS A POSSIBLE FACTOR LIMITING THE DISTRIBUTION OF BIRDS

MILES B. MARKUS

Department of Zoology and Applied Entomology, Imperial College, London SW7 2BB, England

(*Received* 25 *February* 1974)

Abstract—MARKUS M. B. 1974, Arthropod-borne disease as a possible factor limiting the distribution of birds. *International Journal for Parasitology* 4: 609–612. Warner found that arthropod-borne disease in the Hawaiian islands (bird malaria and avian pox in particular) is a factor limiting the distribution of the Drepaniidae. Rowan considers it conceivable that the present distribution of certain African birds (and perhaps some other vertebrates showing similar patterns of occurrence) may have been determined in the same way. This suggestion is supported by the observations of the author in southern Africa in regard to bird malaria and avian pox.

INDEX KEY WORDS: Arthropod-borne disease; avian malaria; avian pox; bird; distribution; ecology; Ethiopian region; *Haemoproteus; Leucocytozoon;* limiting factor; malaria; *Plasmodium;* pox; virus.

ORNITHOLOGICAL ASPECTS

THE MONTANE evergreen forests of the Ethiopian zoogeographical region are inhabited by approximately 120 species of birds, few of which are found south of the Zambesi River, and which are distinct from those of lowland forest. In the tropics the montane forest species, which represent a variety of families (Table 1), occur mainly at elevations of more than about 1525 m above sea level. Refuges at such levels "... support many of the rarest bird species in Africa, with extremely limited ranges and with in some cases populations that are likely to total less than 2000" (Moreau, 1966). Most of the birds living in montane forests have a discontinuous distribution, in some cases very wide (e.g. Benson & Irwin, 1965). Despite their potential mobility, only about 39 typically montane forest species are also to be met with in low-lying country (Moreau, 1966), even though the intervening areas separating their respective populations vary from only a few to many hundreds of kilometres. The reason for the restricted vertical distribution of many species in montane forests is not readily apparent, particularly since some of these birds are only montane species in tropical areas, occurring at all levels down to the coast in the southern parts of their respective ranges.

Rowan (1971), in a journal not readily available to parasitologists, has suggested that such avian distribution patterns in Africa, repeated by different and often wholly unrelated species, may be the result of arthropod-borne disease. In a paper dealing mainly with the detailed distribution of the Cape Robin *Cossypha caffra*, she discusses this

TABLE 1—COMPOSITION OF THE MONTANE FOREST AVIFAUNA OF THE ETHIOPIAN REGION*

Family	Number of species
Accipitridae	1
Phasianidae	6
Columbidae	4
Musophagidae	5
Tytonidae & Strigidae	2
Trogonidae	1
Bucerotidae	1
Capitonidae	2
Picidae	2
Eurylaemidae	1
Oriolidae	2
Paridae	1
Timaliidae	6
Campephagidae	2
Pycnonotidae	7
Turdidae	21
Sylviidae	21
Muscicapidae	6
Laniidae	7
Sturnidae	4
Nectariniidae	8
Ploceidae	
Estrildinae	4
Others	4
Fringillidae	2
Total	120

*Compiled from data in Moreau (1966); but for reasons discussed elsewhere (Markus, 1969), Wetmore's sequence of families is used in accordance with Clancey, Markus, Prozesky and Winterbottom (S.A. Ornithological Society, 1969) and other standard works on African birds.

possibility briefly in the light of Warner's (1968) finding that arthropod-borne disease (bird pox and avian malaria in particular) was responsible for the extinction of some Drepaniidae in the Hawaiian islands within historic times and for the restriction of others to elevations above approximately 600 m. Warner found that epidemiologically significant numbers of the introduced mosquito *Culex pipiens fatigans* do not occur above this level and that drepaniids from the mountains exhibited no appreciable immunogenetic capacity against either avian malaria or bird pox, but died of these diseases when experimentally exposed to the lowland environment. In view of the fact that the montane mosquito fauna in, for example, East Africa is largely distinct from that of lower altitudes in the same region, in addition to there being fewer species, Rowan considers that experimental work along the same lines as that carried out by Warner in Hawaii, may prove enlightening.

PARASITOLOGICAL CONSIDERATIONS

There are a few published reports of avian pox in wild African birds (Middlemiss, 1961; Steyn, 1971) but infections must be fairly common as it is not unusual to come across a bird with lesions resembling those of avian pox. A Diederik Cuckoo *Chrysococcyx caprius*, a Masked Weaver *Ploceus velatus* and several Cape Sparrows *Passer melanurus* have been examined histopathologically by the author (Markus, in preparation) and bird pox diagnosed. In nature the majority of avian pox infections are probably mild and self-limiting but in susceptible birds the disease is highly virulent (Kirmse, 1969; Giddens, Swango, Henderson, Lewis, Farner, Carlos & Dolowy, 1971).

Dr. B. M. McIntosh (*in litt.* to Rowan, 1971) has commented that any elimination by a pathogen of certain African bird species from lower altitudes must have been relatively 'recent' as hosts tend to become evolutionarily adapted to their parasites through selection. While this is so, introduction or reintroduction of potential pathogens or vectors into an area where they did not previously occur, could take place from time to time (e.g. Garnham, 1966; Manwell, 1968; Warner, 1968; Kirmse & Loftin, 1969; Garnham, 1973*a*). Intra-African migrants (e.g. S.A. Ornithological Society, 1969) and Palaearctic migrants in Africa probably regularly transport *Plasmodium* (Smith & Cox, 1972), *inter alia*. The fact that some ornithophilic mosquitoes, simuliids and ceratopogonids have a wide range of hosts would increase the potential for transmission of disease by susceptible vectors. Mosquitoes can develop susceptibility to avian plasmodia through selection within a few generations (Kilama & Craig, 1969; Corradetti, 1973; Maier, 1973).

Malaria in wild birds in Africa is not uncommon (Berson, 1964; Bray, 1964; Garnham, 1966; Oosthuizen & Markus, 1967; Manwell, 1968; Peirce & Backhurst, 1970; Cheke, 1971; Crewe, 1972; Markus & Oosthuizen, 1972*a*; Smith & Cox, 1972; Ashford, personal communication; Markus & Oosthuizen, unpublished data). However, the available evidence seems to indicate that the distribution of avian *Plasmodium* is localized and R. Killick-Kendrick has suggested to me that, in theory, one might expect a parasite to be more pathogenic in some birds on the periphery of an enzootic focus than in the case of species resident in the centre. Not all malarial infections in birds are innocuous. *Plasmodium relictum*, for example, which has a wider range of natural hosts than any other malaria parasite, is known to occur in at least 150 species of birds (Corradetti, Garnham, Neri, Scanga & Cavallini, 1970) and ". . . causes an unknown amount of damage to the bird life of the world" (Garnham, 1966). Whether or not a bird is susceptible to infection with sporozoites of *Plasmodium* introduced by a mosquito appears to depend largely on genetically determined properties of the host erythrocytes which do not follow a phylogenetic pattern and are subject to some individual variation (McGhee, 1971; McGhee & Sullivan, 1971; Butcher, Mitchell & Cohen, 1973).

As Harwin (in Rowan, 1971) has pointed out, temperature plays an important role in the multiplication of viruses and the development of human malaria parasites in the mosquito. Rowan states that "apparently no-one has worked out comparable figures for bird malaria". Information on the sporogonic cycle of avian parasites at both high and low temperatures is, in fact, available, e.g. for *P. lophurae*, *P. relictum* and *P. subpraecox* (Garnham, 1966). The climatic barriers which restrict the distribution of malignant tertian malaria largely to the tropics and subtropics do not exist in the case of bird malaria, which is found in most parts of the globe. An example in Africa is the strain of *P. relictum* which is transmitted in the Jackass Penguin *Spheniscus demersus* population off the temperate, southern tip of the continent (Markus & Oosthuizen, 1972*a*). Sporogony and transmission of some other non-human plasmodia also take place under relatively cool conditions. *P. berghei* (as now understood—Killick-Kendrick, 1974) of rodents, for example, is dependent on *Anopheles dureni millecampsi* which occurs only in the high Katangan forests, a relatively cool habitat. It is not only in the tropics, therefore, that malaria may be/have been a limiting factor in the distribution of birds (or certain other vertebrates—Rowan, 1971).

Comparatively little is known about the pathogenicity of protozoa of birds transmitted by haematophagous insects other than mosquitoes. *Haemoproteus sensu lato* may cause severe anaemia (Markus & Oosthuizen, 1972*b*) but there is little evidence that species of *Haemoproteus* are serious pathogens (Desser, 1973).

Leucocytozoon smithi is of importance to the turkey industry in the Nearctic region (Solis, 1973), while *L. simondi* is responsible for considerable mortality amongst both wild and domestic ducklings. The same may be true to some extent of *Leucocytozoon* spp. in which megaloschizogony occurs (Desser, 1973) and nestling birds in Africa (Garnham, 1950; Oosthuizen & Markus, 1968). At Kisumu in Kenya, for example, very heavy *Leucocytozoon* infections were found (Garnham, 1950) in dead and dying weaver nestlings, with lighter parasitaemias in the surviving older birds. A 'highly lethal' infection, apparently a form of leucocytozoonosis and perhaps transmitted by *Culicoides*, has been described in 'abnormal' hosts (Borst, 1973; Garnham, 1973*b*), mainly nestlings.

Apart from the fact that one would expect that the early life of a bird would be the time when it would be most susceptible to various environmental adversities, it would seem that nestlings are more frequently used by potential vectors for feeding than are adults (Blackmore & Dow, 1958). The majority of bird species are either naked or only sparsely covered with feathers during the first few weeks of life and at that stage are particularly vulnerable to attack by biting insects (Markus, 1969).

It should be possible to investigate Rowan's (1971) suggestion that the present distribution patterns of certain birds may be the result of arthropod-borne disease, by conducting experiments in the field (see Warner, 1968).

Acknowledgements—Work on the haematozoa of African birds was supported by the Frank M. Chapman Memorial Fund of the American Museum of Natural History, New York, and the South African Council for Scientific and Industrial Research.

REFERENCES

Benson C. W. & Irwin M. P. S. 1965. Some West–East distributional gaps in birds of evergreen forest in South-central Africa. In: *Science and Medicine in Central Africa* (Edited by Snowball G. J.) pp. 309–320. Pergamon Press, Oxford.

Berson J. P. 1964. Les protozoaires parasites des hématies et du système histiocytaire des oiseaux. *Revue d'Elevage et de Médecine Vétérinaire des Pays Tropicaux* **17**: 43–96.

Blackmore J. S. & Dow R. P. 1958. Differential feeding of *Culex tarsalis* on nestling and adult birds. *Mosquito News* **18**: 15–17.

Borst G. H. A. 1973. *Leucocytozoon* infection in parakeets in Holland. *Progress in Protozoology* **4**: 55.

Bray R. S. 1964. A check-list of the parasitic protozoa of West Africa with some notes on their classification. *Bulletin de l'Institut Française d'Afrique Noire* **26**: 238–315.

Butcher G. A., Mitchell G. H. & Cohen S. 1973. Mechanism of host specificity in malarial infection. *Nature* **244**: 40–42.

Cheke R. A. 1971. A note on some blood parasites from Ghanaian birds. *Revue de Zoologie et de Botanique Africaines* **84**: 97–98.

Corradetti A. 1973. Selection of avian plasmodia able to develop in the unusual mosquito *Anopheles* (*Myzomyia*) *stephensi*. *Progress in Protozoology* **4**: 463.

Corradetti A., Garnham P. C. C., Neri I., Scanga M. & Cavallini C. 1970. A redescription of *Plasmodium* (*Haemamoeba*) *relictum* (Grassi and Feletti, 1891). *Parassitologia* **12**: 1–10.

Crewe S. M. 1972. A new strain of avian malaria parasite. *Transactions of the Royal Society of Tropical Medicine and Hygiene* **66**: 6–7.

Desser S. S. 1973. Comparisons of life cycles and pathogenesis in the Haemosporidia. *9th International Congress on Tropical Medicine and Malaria*, Athens (Abstracts of Papers) **1**: 243–244.

Garnham P. C. C. 1950. Blood parasites of East African vertebrates, with a brief description of exo-erythrocytic schizogony in *Plasmodium pitmani*. *Parasitology* **40**: 328–337.

Garnham P. C. C. 1966. *Malaria Parasites and Other Haemosporidia*. Blackwell Scientific Publications, Oxford.

Garnham P. C. C. 1973*a*. Distribution of malaria parasites, in primates, insectivores and bats. *Symposia of the Zoological Society of London* **33**: 377–404.

Garnham P. C. C. 1973*b*. Epizootics of *Leucocytozoon* infections in parakeets in England. *Progress in Protozoology* **4**: 149.

Giddens W. E., Swango L. J., Henderson J. D., Lewis R. A., Farner D. S., Carlos A. & Dolowy W. C. 1971. Canary pox in sparrows and canaries (Fringillidae) and in weavers (Ploceidae). *Veterinary Pathology* **8**: 260–280.

Kilama W. L. & Craig G. B. 1969. Monofactorial inheritance of susceptibility to *Plasmodium gallinaceum* in *Aedes aegypti*. *Annals of Tropical Medicine and Parasitology* **63**: 419–432.

Killick-Kendrick R. 1974. Parasitic protozoa of the blood of rodents—II. Haemogregarines, malaria parasites and piroplasms of rodents: an annotated checklist and host index. *Acta Tropica* **31**: 28–69.

Kirmse P. 1969. Host specificity and pathogenicity of pox viruses from wild birds. *Bulletin of the Wildlife Disease Association* **5**: 376–386.

Kirmse P. & Loftin H. 1969. Avian pox in migrant and native birds in Panama. *Bulletin of the Wildlife Disease Association* **5**: 103–107.

McGhee R. B. 1971. *Plasmodium gallinaceum:* hereditary transmission of erythrocyte susceptibility. *Experimental Parasitology* **30**: 267–269.

McGhee R. B. & Sullivan, J. S. 1971. *Plasmodium gallinaceum:* variation in susceptibility of dove erythrocytes. *Experimental Parasitology* **30**: 356–362.

Maier W. A. 1973. Uber die Mortalität von *Culex pipiens fatigans* nach Infektion mit *Plasmodium cathemerium*. *Zeitschrift für Parasitenkunde* **41**: 11–28.

Manwell R. D. 1968. *Plasmodium octamerium* n. sp., an avian malaria parasite from the pintail whydah bird *Vidua macroura*. *Journal of Protozoology* **15**: 680–685.

Markus M. B. 1969. *A preliminary survey of the occurrence of neossoptiles in South African passeriform birds, with special reference to natal pteryloses*. University Microfilms, Ann Arbor, Michigan. Order No. M-2297.

Markus M. B. & Oosthuizen J. H. 1972*a*. The haematozoa of South African birds—VI. Avian malaria. *Veterinary Record* **91**: 198–199.

MARKUS M. B. & OOSTHUIZEN J. H. 1972*b*. Pathogenicity of *Haemoproteus columbae*. *Transactions of the Royal Society of Tropical Medicine and Hygiene* **66**: 186–187.

MIDDLEMISS E. 1961. Avian pox in South Africa. *Ostrich* **32**: 20–22.

MOREAU R. E. 1966. *The Bird Faunas of Africa and its Islands*. Academic Press, London.

OOSTHUIZEN J. H. & MARKUS M. B. 1967. The haematozoa of South African birds—II. Blood parasites of some Rhodesian birds. *Journal of the South African Veterinary Medical Association* **38**: 438–440

OOSTHUIZEN J. H. & MARKUS M. B. 1968. The hematozoa of South African birds—IV. Leucocytozoonosis in in nestlings. *Journal of Parasitology* **54**: 1244–1246.

PEIRCE M. A. & BACKHURST G. C. 1970. Observations on the haematozoa found in birds from the northern frontier district of Kenya. *East African Wildlife Journal* **8**: 208–212.

ROWAN M. K. 1971. On temperature and disease as limiting factors in distribution. *Ostrich* Suppl. No. 9: 147–151.

SMITH V. W. & COX F. E. G. 1972. Blood parasites and the weights of palaearctic migrants in central Nigeria. *Ibis* **114**: 105–106.

SOLIS J. 1973. Nonsusceptibility of some avian species to turkey *Leucocytozoon* infection. *Poultry Science* **52**: 498–500.

SOUTH AFRICAN ORNITHOLOGICAL SOCIETY LIST COMMITTEE 1969. *Check list of the birds of South Africa*. S.A.O.S., Cape Town.

STEYN P. 1971. Rattling cisticola with fowl-pox lesions. *Ostrich* 42: 74.

WARNER R. E. 1968. The role of introduced diseases in the extinction of the endemic Hawaiian avifauna. *Condor* **70**: 101–120.

Note added in proof: Cheke (*East African Wildlife Journal* **10**: 245–249, 1972) did not find *Plasmodium* in birds of two montane forests in Kenya at 2300 m and 3300 m respectively, and writes: "The lack of *Plasmodium* sp. infections is presumably due to the absence of the mosquito vectors at these high altitudes".

Reprinted from
TRANSACTIONS OF THE ROYAL SOCIETY OF TROPICAL MEDICINE AND HYGIENE, Vol. 68. No. 5. pp. 415-416, 1974.

SEROLOGY OF HUMAN SARCOSPORIDIOSIS

SIR,—In his review of sarcosporidiosis in man, JEFFREY (1974) suggested that the complement-fixation test would be of value in distinguishing between toxoplasmosis and sarcosporidiosis in cases where morphological study of small cysts in muscle gives an equivocal diagnosis. While much information concerning the serodiagnosis of toxoplasmosis is available, this is not true of sarcosporidiosis.

ROMMEL and HEYDORN (1972) found that after eating raw beef or pork containing *Sarcocystis*, human volunteers shed *Isospora hominis* in their faeces. Thus, *Sarcocystis* and *I. hominis* are different stages of the same parasite. Antibodies to *Sarcocystis* detectable by the indirect fluorescent antibody test were not shown in the serum of a cat with an intestinal infection (analogous to *I. hominis* in man) which followed the ingestion of tissue cysts of *Sarcocystis* in raw cattle diaphragm (MARKUS et al., 1974; MARKUS et al., in press). The reason may have been that extra-intestinal infection is sometimes or always necessary for antibody production. Unlike *Toxoplasma*, *Sarcocystis* in carnivores does not normally develop extra-intestinal stages (see MARKUS et al., in press), which play a rôle in stimulating the production of antibody. However, circulating antibody has apparently been demonstrated in both known *I. hominis* carriers and non-carriers (including vegetarians), with use of bovine *Sarcocystis* antigen and *I. hominis* sporozoites in the indirect fluorescent antibody test, but was only occasionally observed in young babies (LAARMAN et al., 1974; TADROS et al., 1974). Whether this test can give false positives as it occasionally does with *Toxoplasma* antigen, is an aspect requiring investigation (see ARAUJO et al., 1971; MARKUS, 1973; REMINGTON and DESMONTS, 1973). Furthermore, it should be noted that there is a serum factor which causes polar fluorescence of *Toxoplasma* in approximately 30% of seronegative individuals. This factor is heat stable, can be titrated, and does not usually occur in the blood of infants of less than 6 months of age (SULZER and WILSON, 1971; KAUFMAN et al., 1973). Subclinical coccidiosis caused by *I. hominis* is common (see TADROS et al., 1974). If antibody is indeed formed, it follows that tests using *Sarcocystis* antigen on sera of persons having unidentified muscle cysts of *Toxoplasma* could be positive for *Sarcocystis* because of a past or concomitant intestinal *I. hominis* infection. On the basis of present knowledge, therefore, a positive result from a serological test for sarcosporidiosis in a person with unidentified muscle cysts might be difficult to interpret, particularly if tests for *Toxoplasma* are also positive. The chances that a test for toxoplasmosis will be positive are good, since it is now a well-established fact that antibodies to *Toxoplasma* are found in a large number of healthy persons. Only a negative test for toxoplasmosis would help to exclude this protozoon in a patient having unidentified cysts in muscle. However, the absence of demonstrable *Toxoplasma* antibody cannot be taken as absolute proof that the parasite is not present in the tissues (REMINGTON and ARAUJO, 1974).

An obvious question which springs to mind is whether there is cross-reaction between *Sarcocystis* and *Toxoplasma*. It would appear that they are immunologically distinct. Cats which are shedding *I. cati* (one of the coccidia that has in the past been called *I. bigemina*), now known to be a resistant stage of *Sarcocystis* (HEYDORN and ROMMEL, 1972), can be superinfected with *Toxoplasma*, resulting in production of oöcysts of the latter parasite as well (see FRENKEL, 1973). However, although several workers have shown that immunity usually develops in cats in which *Toxoplasma* has undergone gametogony, the degree to which this happens following sexual reproduction of *Sarcocystis* has yet to be determined. The indications are that cats can be re-infected with *Sarcocystis* relatively easily (e.g. MARKUS et al., in press). Additional evidence suggesting an absence of any marked common antigenicity between *Sarcocystis* and *Toxoplasma* is provided by serological studies by MANDOUR (1965), MCCONNELL et al. (1973) and TADROS et al. (1974). In a summary of other work on this subject, the conclusion was reached (MARKUS, 1973) that there are as yet no grounds for questioning the reliability of routine serological tests for human toxoplasmosis. The opinion of DE OLIVEIRA et al. (1973) that there is "group" cross-reaction between *Toxoplasma* on the one hand and *I. hominis* and *I. belli* on the other is open to question and needs to be confirmed.

While a negative serological test for toxoplasmosis in a patient having unidentified cysts in muscle would be useful information, more experimental work on antibody production in *Sarcocystis* infections in relation to the use of tests for sarcosporidiosis is indicated.

I am, etc.,

MILES B. MARKUS,
Department of Zoology and Applied Entomology
Imperial College,
University of London,
London S.W.7.

8 *July*, 1974

REFERENCES

ARAUJO, F. G., BARNETT, E. V., GENTRY, L. O. & REMINGTON, J. S. (1971). *Appl. Microbiol.*, **22**, 270.
DE OLIVEIRA, G. S. C., BARBOSA, W. & DA SILVA, A. L. (1973). *Revta Patol. trop.*, **2**, 387.
FRENKEL, J. K. (1973). In: HAMMOND, D. M. & LONG, P. L. (eds), *The coccidia*, p. 343. Baltimore: University Park Press and London: Butterworths.
HEYDORN, A.-O. & ROMMEL, M. (1972). *Berl. Munch, tierärztl. Wschr.*, **85**, 121.
JEFFREY, H. C. (1974). *Trans. R. Soc. trop. Med. Hyg.*, **68**, 17.
KAUFMAN, G. I. REMINGTON, J. S. & WATERS, H. C. (1973). *Appl. Microbiol.*, **25**, 724.
LAARMAN, J. J., TADROS, W. & VAN DEN EIJK, A. A. (1974). Unpublished paper read at 3rd Int. Congr. Parasit. (Munich).

McConnell, E. E., Basson, P. A., Wolstenholme, B., De Vos, V. & Malherbe, H. H. (1973). *Trans. R. Soc. trop. Med. Hyg.*, **67**, 851.
Mandour, A. M. (1965). Ph.D. thesis, University of London.
Markus, M. B. (1973). *New Engl. J. Med.*, **289**, 980.
———, Draper, C. C., Hutchison, W. M., Killick- Kendrick, R. & Garnham, P. C. C. (1974). *Trans. R. Soc. trop. Med. Hyg.*, **68**, 3.
———, Killick-Kendrick, R. & Garnham, P. C. C. *J. trop. Med. Hyg.* (In press).
Remington, J. S. & Araujo, F. G. (1974). *Proc. 3rd Int. Congr. Parasit.* (Munich), **1**, 294.
——— & Desmonts, G. (1973). *J. Pediat.*, **83**, 27.
Rommel, M. & Heydorn, A.-O. (1972). *Berl. Münch. tierärztl. Wschr.*, **85**, 143.
Sulzer, A. J. & Wilson, M. (1971). *Expl. Parasit.*, **29**, 197.
Tadros, W., Laarman, J. J. & Van den Eijk, A. A. (1974). *Z. Parasit Kde*, **43**, 221.

Printed by F. J. PARSONS LTD., *London, Folkestone and Hastings.*

THE COCCIDIAL NATURE AND LIFE-CYCLE OF *SARCOCYSTIS*

M. B. MARKUS, R. KILLICK-KENDRICK and P. C. C. GARNHAM

Department of Zoology and Applied Entomology, Imperial College, University of London, London SW7 2AZ

Introduction

Rommel and Heydorn (1972) described experiments in which human volunteers ate raw beef infected with *Sarcocystis fusiformis** and uncooked pork containing cysts of *S. miescheriana*. Approximately nine days after the infected meat had been eaten, sporocysts morphologically indistinguishable from *Isospora hominis* appeared in the faeces. Similarly, *S. fusiformis* of cattle and *S. tenella* of sheep were found to cause intestinal infection in dogs and cats (Euzéby *et al.*, 1972; Heydorn and Rommel, 1972a, b; Rommel *et al.*, 1972; Fayer and Leek, 1973; Rommel and Heydorn, 1973; Ford, 1974; Markus *et al.*, 1974; Mehlhorn *et al.*, 1974; Munday and Corbould, 1974). Heydorn and Rommel's results, subsequently confirmed by other workers, revealed that *Sarcocystis* and certain species of *Isospora* are, in fact, different stages of the same parasite. The life-cycle of *Sarcocystis* is reviewed here in the light of recent discoveries.

Most of the earlier experimental work on *Sarcocystis* consisted of attempts to transmit the organism between mammals that commonly develop cysts in their muscles. A number of authors claim to have infected such animals by feeding them tissue cysts (see Rommel *et al.*, 1972; Awad, 1973). The results of much of the early work on the life-cycle of *Sarcocystis* are equivocal. Some of these experiments were not accompanied by adequate controls. In several, contamination of cages with oocysts or sporocysts could perhaps have taken place.

Relative susceptibility of hosts to intestinal infection with *S. fusiformis*

In the hope of obtaining more information about the human infection by using a higher ape, we, in collaboration with Dr. C. C. Draper and Prof. W. M. Hutchison, tried to infect four splenectomized chimpanzees and, as controls, four specific pathogen-free cats (Markus *et al.*, 1974). The animals were at different times fed minced cattle diaphragm or heart containing *S. fusiformis* or they were given a suspension, in saline, of *S. fusiformis* cysts packed with cystozoites (Figs. 1, 2), from bovine cardiac muscle. On most occasions, the material used was fresh and had not been refrigerated. Faecal samples were usually screened daily between days 5 and 15 and then thrice weekly for one month by centrifugal flotation, using a saturated sodium chloride solution. If no sporocysts were seen during this period, we stopped examining the faeces. Cystozoites liberated from *S. fusiformis* tissue cysts were used as antigen in the indirect fluorescent antibody test to examine the sera of the experimental chimpanzees and cats up to six months after cysts had been ingested.

No oocysts or sporocysts were detected in the faeces of the chimpanzees. A rising antibody titre was observed in one chimpanzee, which was seronegative for the first 21 weeks after ingesting tissue cysts. In the 23rd week the titre was 1 : 16 and a week later had risen to 1 : 64, where it remained for a few weeks before falling to 1 : 16. The time of seroconversion coincided with the fortuitous finding by Mr. Sherali Thaver of a single "zoite" (about 10μm in length) in a Giemsa-stained thick blood film. Unfortunately the zoite, also seen by P.C.C.G., Prof. L. J. Bruce-Chwatt, Dr. C. C. Draper and Miss V. C. L. C. Wilson, was accidentally destroyed. As the time when the seroconversion occurred was not only when the zoite was seen but also when an experimental *Plasmodium vivax* infection became patent, the cause of the rising titre is not clear. The malaria parasite and *Sarcocystis* are both Sporozoa and the possibility that there was some cross reaction must be considered.

Two muscle biopsies (triceps and latissimus dorsi) were performed eight months after the feeding of *Sarcocystis*, *i.e.* two months after the organism was seen in the blood film. No parasites were found in the biopsy material. The zoite may have escaped from a muscle cyst that was punctured when the blood film was prepared from the ear of the chimpanzee.

*The nomenclature of *Sarcocystis* in bovines is confused. Two of the names which have been used in recent years by authors referring to *Sarcocystis* in the ox are *S. hirsuta* Moulé, 1887 and *S. fusiformis* Railliet, 1897.

Reprinted from the JOURNAL OF TROPICAL MEDICINE AND HYGIENE, *November 1974, Vol. 77, pp. 248 - 259.*



Fig. 1. Sarcocyst from bovine heart muscle (× 200). Fresh preparation.

Another possibility is that it came from a ruptured schizont in the wall of a blood vessel. However, there is no proof that the presence of the zoite was the result of the chimpanzee having been fed tissue cysts of *Sarcocystis*. An autopsy is to be performed on this animal in due course.

S. fusiformis sporocysts (Fig. 3) and, more rarely, thin-walled oocysts (Fig. 4), were seen in the faeces of only one control cat, which seven days earlier had eaten diaphragm containing tissue cysts. The meat had been kept at 4°C. for 1 - 2 days. The tissue cysts of *S. fusiformis* can, therefore, still be infective after storage at this temperature. The cat that shed sporocysts remained seronegative up to six months after-infection. Seven months after it was first fed muscle, this cat and one of the others were again given infected bovine diaphragm on each of three consecutive days. Both cats started to shed small numbers of sporocysts after about seven days.

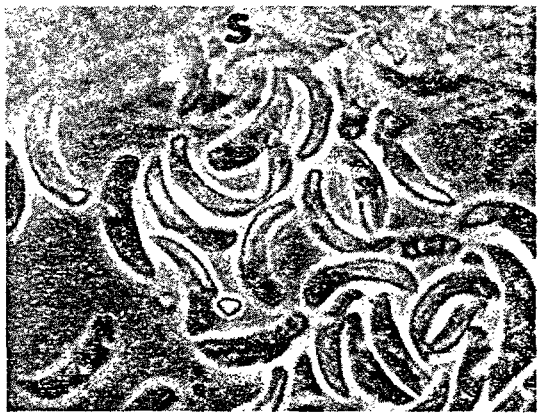

Fig. 2. Cystozoites of *Sarcocystis fusiformis*, liberated from a sarcocyst (S) (× 1,500). Fresh preparation.

Further controls for one of the chimpanzee experiments were kindly provided by Dr. A.-O. Heydorn, in whose laboratory five dogs and four cats were fed infected beef. All nine animals in Berlin (which had some time previously been infected with *S. fusiformis* in other experiments) subsequently shed sporocysts, which were more numerous in the dog faeces than in the cat faeces (Heydorn, personal communication). It may be noted that Fayer (personal communication) was unable to produce infection in 25 cats that had been fed bovine heart containing *S. fusiformis*, but found dogs to be susceptible (Fayer and Leek, 1973). Better controls for our experiments on chimpanzees would therefore have been dogs, rather than cats.

The absence of oocysts in the faeces of the experimental chimpanzees is puzzling. Sporocysts similar to those of *I. hominis* have been recorded from a young chimpanzee which was examined after six months in captivity (Rijpstra, 1967), but the source of infection was not determined. On present evidence it seems that while man and dogs are susceptible to intestinal infection with *Sarcocystis* of cattle, chimpanzees and cats are completely or partially refractory. However, there may yet be shown to be more than one species of *Sarcocystis* in cattle.

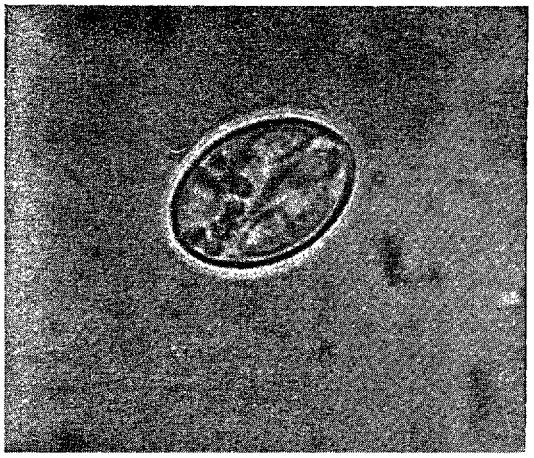

Fig. 3.

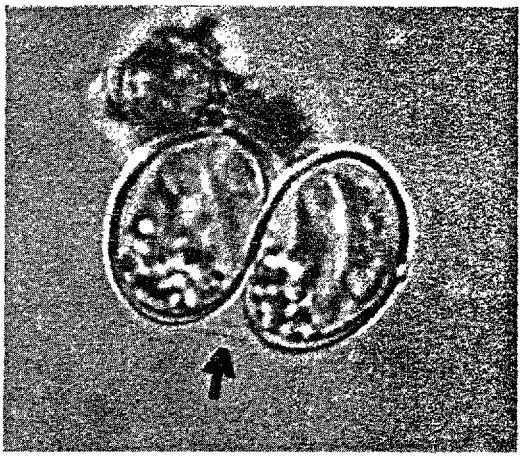

Fig. 4.

Figs. 3 and 4. *Sarcocystis fusiformis* from cat faeces (× 2,000). Fresh preparations. 3. Free sporocyst containing sporozoites. 4. Intact oocyst (thin oocyst wall arrowed).

Life-cycle

The significance of carnivorism in the transmission of *Sarcocystis* is now becoming clear. The life-cycle involves two vertebrate hosts: the " prey " (*e.g.* ungulates, rodents, birds, etc.) and a " predator " (*e.g.* man, dog, cat, cheetah, etc.), with asexual multiplication usually taking place in the prey and sexual reproduction of the parasite restricted to the predator (see Fig. 5). There is a precedent in the Eimeriina for such a situation, *i.e.* an alternation of generations in different hosts. Thus, in the genus *Aggregata,* schizogony occurs in one host (crab) and the sexual cycle in another (cuttle fish)—Dobell (1925). Monkeys and baboons, which tend to be omnivorous and in which sarcocysts occur (see Terrell and Stookey, 1972; McConnell *et al.*, 1973), sometimes play the part of predator and at other times that of prey. The same situation must have occurred in early man.

A tentative life-cycle of *S. fusiformis* is depicted in Fig. 5. In summary, sporocysts (D), passed in the faeces of the " predator " (man, dog, cat), are ingested by the " prey " (bovine) and their sporozoites initiate an asexual multiplication (E) in reticulo-endothelial cells (usually endothelial cells of blood vessels) in almost all tissues. In muscle, merozoites eventually give rise to the well-known sarcocysts (A), containing many thousands of cystozoites (B). However, there is an unique report of *S. fusiformis* in the brain of an ox (Bigalke and Tustin, 1960). Available evidence suggests that when the muscle is eaten by the predator, the cystozoites penetrate the intestine and develop (C) into macro and microgametocytes underneath the epithelium. Apparently there is no schizogony immediately preceding gametogony in the gut of the predator. By about the fifth day, oocysts begin sporulating *in situ.* The isosporan oocysts (containing two sporocysts, each with four sporozoites) progressively escape into the lumen of the intestine and are shed in the faeces, usually as free sporocysts.

The stages of *Sarcocystis* that have recently been identified and which are described below are (1) the oocyst (Rommel *et al.*, 1972), which is formed in the gut of the predator, and (2) schizonts in, mainly, endothelial cells of blood vessels of a wide range of tissues in the prey (Fayer and Johnson, 1973).

Sporocysts in faeces of predator

Sporocysts and intact oocysts (Figs. 3, 4) of the same appearance as those described by Heydorn and Rommel (1972a, b) were passed by our first infected cat for at least three months (two subsequent infections in cats are still patent at the time of writing). The mean size of 50 sporocysts was 12·9 × 8·7μm (11·6-14·9 × 8·2-10·4; standard deviation of both length and width=0·6). The sporocysts of *S. fusiformis* differ from those of better-known coccidia of cats (*I. felis, I. rivolta* and *T. gondii*) and from most coccidia of other animals, including *I. belli* of man, in that (1) they are usually shed singly and not within the oocyst; (2) they are usually fully sporulated on being excreted; and (3) the patent period is markedly

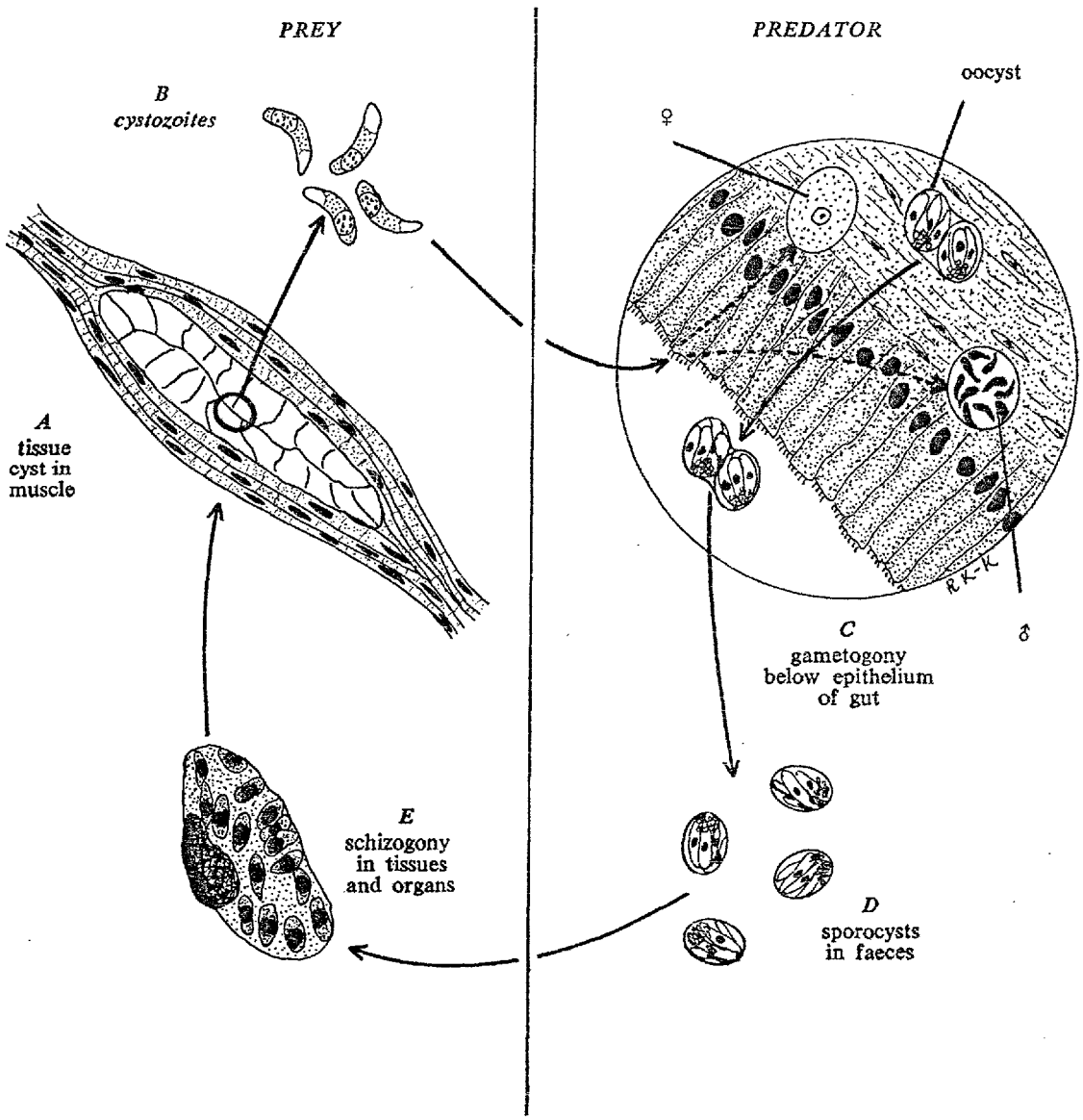

Fig. 5. Life-cycle of *Sarcocystis fusiformis*

Tissue cysts (A) containing cystozoites (B) are ingested by the predator. The cystozoites grow directly to sexual stages (C) in the intestine of the predator—(the parasites in diagram C have been enlarged in relation to the epithelial cells). Oocysts sporulate *in situ* in the subepithelial tissue and are released into the lumen of the gut; forms in the faeces are mainly free sporocysts (D) which have broken out of the fragile oocysts. When ingested by the prey, the sporozoites from sporocysts initiate one or more cycles of asexual multiplication (E) in reticulo-endothelial cells in most tissues. Merozoites of schizonts give rise to the tissue cysts in muscle. (Different stages not drawn to scale.)

longer than that of other coccidia. Histological evidence indicates that *S. fusiformis* and *S. tenella* typically develop beneath the intestinal epithelium and the retention of oocysts subepithelially in the gut wall (Heydorn and Rommel, 1972a, b) would explain the persistence of sporocysts in the faeces. Some isosporan sporocysts that have been found in the faeces of wild carnivores show similarities to known sporocysts of *Sarcocystis, e.g.* sporocysts in gut scrapings from a cheetah *Acinonyx jubatus* in South Africa (as seen in material given to M.B.M. in 1971 by Dr. Shan Thomas). The mean size of four sporocysts was 11·8 × 8·2μm.

It is not yet clear whether the sporocysts of all *Sarcocystis* species are shed singly and in a sporulated state, and the whole question of the identity and relationships of the smaller species of *Isospora* throughout the animal kingdom, requires investigation. The importance of a two-host cycle in the life-cycle of some of these coccidia has become apparent. Whereas ingestion by the predator of the muscle cyst stage of *Sarcocystis*, the " small race of *I. bigemina*" of the dog and the WC 1170 parasite (Wallace, 1973a) is regularly followed by gametogony, the oocyst stage fails to produce the complete oocyst-to-oocyst cycle in the predator (Heydorn, 1973; Rommel and Heydorn, 1973; Wallace, 1973a). In this respect the oocyst of *T. gondii* is also much less " efficient " than the tissue cyst (Dubey *et al.*, 1970; Wallace, 1973b). Thus the full life-cycle of these organ-



Fig. 6.

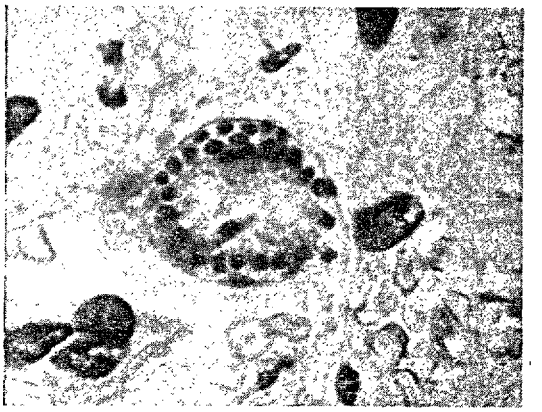

Fig. 7.

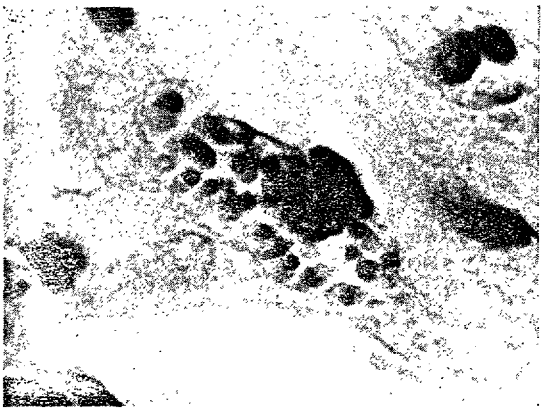

Fig. 8.

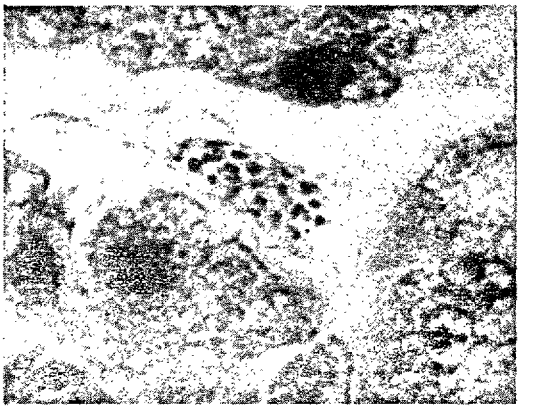

Fig. 9.

Figs. 6 - 9. Schizonts of *Sarcocystis fusiformis* in kidney of calf (× 1,500) (material by courtesy of R. Fayer and A. J. Johnson). Giemsa's stain. 6. Schizont approaching maturity, with deeply-staining nuclei. 7. Mature schizont with merozoites in transverse section and in palisade formation. 8. Mature schizont showing merozoites in longitudinal section. 9. A second type of schizont with small nuclei; almost mature.

isms in naturally infected predators appears to be dependent on the predator ingesting tissue cysts in raw flesh. In contrast to this situation, the ingestion of even a single infective oocyst of *I. felis* by a non-immune cat is sufficient to result in gametogony; and the same is true of other large isosporan coccidia of which the life-cycle has been studied.

Asexual multiplication in tissues of prey

Fayer and Johnson (1973) provided the first convincing description of schizonts of *Sarcocystis* in experimental animals. These were seen in all tissues taken from four of five calves during autopsy 26-33 days after having been fed $2{\cdot}5 \times 10^5 - 1{\cdot}0 \times 10^6$ sporocysts of *S. fusiformis* from dogs. In subsequent experiments, schizonts were first found 20 days after sporocysts had been fed to calves and were not seen in animals 40, 46 and 54 days after ingestion (Fayer and Johnson, 1974). These authors postulated that the products of the primary stages in calves gave rise to sarcocysts (Fig. 1) in muscle. The sarcocysts contain the "spores" (Fig. 2), or cystozoites, as named by Hoare (1972).

Sections of kidney from an experimental calf were very kindly sent to us by Drs. Fayer and Johnson. We stained them in Giemsa's stain and the description given below is based on this material. Two types of schizont were seen. One (Fig. 6) had densely stained discrete nuclei, occasionally arranged in a palisade at the periphery (Fig. 7). The schizonts were usually oval and the largest measured $34 \times 15\mu$m. Merozoites in mature forms lay in one plane and were nearly always seen in cross section or cut tangentially (Fig. 7). In one schizont, however, the merozoites were cut in the plane in which they lay. They were then seen to be elongate, measuring $4 \times 2\ \mu$m, with a single dense nucleus about $2\ \mu$m in diameter (Fig. 8). Fayer and Johnson found up to 50 merozoites in mature schizonts. The schizonts with these very distinctive nuclei were in the tubules as well as in the glomeruli.

The second and less common form was seen only in the tubules. Schizonts of this kind, which we presume represent an earlier generation, were smaller; the largest one seen measured only $15 \times 6\ \mu$m. The merozoites of these forms were tiny bodies, measuring about $2 \times 1\ \mu$m with nuclei about $1\ \mu$m in diameter (Fig. 9).

Gametogony

The prepatent period in our cats was approximately seven days, which corresponds to the findings of Heydorn and Rommel (1972a).

At the time of writing, sexual stages of *Sarcocystis* have been demonstrated experimentally only in the gut of dogs and cats (Heydorn and Rommel, 1972a, b) and in tissue culture (Fayer, 1970; 1972). In cats sacrificed up to five days after being fed meat infected with *S. fusiformis*, macrogametes and immature and mature oocysts were found in a subepithelial location (Heydorn and Rommel, 1972b). Mehlhorn and Scholtyseck (1974) described oocysts of *S. tenella* underneath the intestinal epithelium of a cat that was killed on the ninth day after infection. In addition to macrogametes and "cystlike bodies", microgametogony was observed in tissue culture by Fayer (1972) but so far microgametocytes have not been identified with certainty *in vivo*.

Curiously, no asexual development between cystozoite and gametocyte has been seen either in experimental animals or in tissue cultures.

Discussion

Coccidial nature of Sarcocystis

The discovery by Hutchison *et al.* (1969) that an isosporan phase existed in the life-cycle of *Toxoplasma* immediately indicated the probability that similar stages would occur in other members of the Toxoplasmea, including *Sarcocystis*. Ultrastructural studies on the tissue cysts and cystozoites clearly demonstrated that *Sarcocystis* is a sporozoon (*e.g.* Ludvik, 1963; Scholtyseck *et al.*, 1973) and this was confirmed by the work of Fayer (1970; 1972), who found gametogony of *Sarcocystis* in tissue culture. At about the same time, Rommel *et al.* (1972) showed the presence of disporocystid, tetrazoic oocysts in the life-cycle, thereby revealing its *Isospora*-like nature. The fine structure of the sexual stages of *Sarcocystis* greatly resembles that of *Toxoplasma* and *Eimeria* (Vetterling *et al.*, 1973). Mehlhorn and Scholtyseck (1974) and Mehlhorn *et al.* (1974) described the ultrastructure of the oocyst of *S. tenella*.

It is now apparent that some, if not all, of the free sporocysts known for many years from cats, dogs and man (Heydorn and Rommel, 1972a; Rommel and Heydorn, 1972; Rommel *et al.*, 1972) are those of *Sarcocystis* spp. Species of *Isospora* have also been described from wild carnivores and omnivores on the basis of sporulated sporocysts found in the faeces.

Carnivorism and oocyst transmission would seem to be important in the life-cycle of *Sarcocystis*. It is likely that in nature very few sporocysts need to be ingested to initiate asexual reproduction in the tissues of the prey, giving rise to large numbers of parasites. Sporocysts are shed by an infected carnivore over a long period; and environmental contamination with sporocysts (Markus, 1974) would provide a source of infection for the prey.

Coccidia in faeces of domestic cats

At least four different types of isosporan coccidia (*I. felis, I. rivolta, T. gondii* and *Sarcocystis*) may be found in the faeces of cats (see figures in Dubey, 1973 and Frenkel, 1973) and can be distinguished from each other without difficulty. Neither *T. gondii* nor *Sarcocystis* is as commonly seen in cats as are the larger *I. felis* and *I. rivolta*, both of which are shed in the unsporulated state as intact oocysts. *I. felis* is the largest cat coccidium.

There has been some confusion surrounding the name "*Isospora bigemina*" which, even recently, has been used for more than one coccidium of cats and has included both *T. gondii* and *Sarcocystis*. Unsporulated oocysts in naturally infected cats measuring approximately 12 × 10μm are usually those of *T. gondii*. However, they are not always so: Wallace (1973a) fed *Toxoplasma*-like oocysts from cat faeces to mice. Serologically and biologically the organism he was studying did not behave like *Toxoplasma*, in addition to which it apparently formed tissue cysts in mice, resembling those of *S. muris*. Similarly, serological and biological evidence showed that the "small race of *I. bigemina*" of the dog is not the same (as some workers had thought) as *T. gondii* (Heydorn, 1973; Zukovic, *et al.*, 1973).

Some coccidia slightly larger than *T. gondii* and occurring in the faeces of cats mainly as free, sporulated sporocysts (Fig. 3) are, as far as is known, stages in the life-cycle of *Sarcocystis*. Euzéby *et al.* (1972) appeared to obtain sporocysts of *S. tenella* but they erroneously considered the free sporocysts to be those of *I. felis*. Although the diagram in their paper may represent the sporocyst of *S. tenella*, the photomicrographs are not of *Sarcocystis* and resemble *I. felis*.

The idea that coccidian oocysts have a high degree of dimensional constancy and that size alone can be used within narrow limits in specific identification, is open to question. Oocysts of various coccidia increase markedly in size during patency (Duszynski, 1971). Furthermore, sporocysts of *S. fusiformis* in the dog appear to be larger (on average, 3·5μm) than those in the cat (Heydorn and Rommel, 1972a). Future studies should show whether this difference is due to the different hosts or to the presence of more than one species of *Sarcocystis* in cattle.

Absence of asexual intestinal stages

Schizonts were not observed in the intestines of eight cats or a dog fed meat containing *S. fusiformis* tissue cysts (Heydorn and Rommel, 1972a, b); or in a cat infected with cysts of *S. tenella* (Mehlhorn and Scholtyseck, 1974). Cystozoites of an avian *Sarcocystis* species also underwent no schizogony in tissue culture (Fayer, 1972). Furthermore, asexual reproduction has not been seen in the host's gut in the case of other coccidia which, judging from the nature of the oocysts and sporocysts, will probably prove to be stages in the life-cycle of *Sarcocystis* spp., *e.g. I. papionis* of the baboon (McConnell *et al.*, 1971). Possible reasons why asexual stages of *Sarcocystis* have not been located in the intestine of animals which have ingested tissue cysts, are that (1) asexual intestinal stages are absent, ephemeral or difficult to see; or (2) schizogony does take place, but in an extra-intestinal location with subsequent reinvasion of the gut. Support for the view that schizogony between cystozoite and gamete does not occur in the animal is the fact that it was not seen in tissue culture (Fayer, 1972).

Various multiplicative stages of the related *Toxoplasma* are found in the intestine of cats (Hutchison *et al.*, 1971; Frenkel, 1973) but the details of the cycle in the gut of felines is still not fully understood. Galuzo *et al.* (1973) postulated that some cystozoites of *Toxoplasma* give rise directly to sexual stages in cats. This would be analogous to what appears to be the situation in the life-cycle of *Sarcocystis*.

Wallace (1973a), in a series of carefully conducted experiments, studied a parasite which apparently showed similarities to both *T. gondii* and *Sarcocystis*. The oocyst was morphologically similar to that of *T. gondii* and was shed by cats in the unsporulated state. This, together with the fact that the **patent** period was relatively short, suggests that the developmental site was the intestinal epithelium (as opposed to the lamina propria), as in *T. gondii*. It would be interesting to know whether cystozoite-

induced schizogony of the organism isolated by Wallace occurs in the intestine of the predator, as it does in *T. gondii*. This would help to clarify the relationships of the former parasite, which may be important from the point of view of understanding the evolution of *Toxoplasma* and *Sarcocystis*.

Number of extra-intestinal schizogonic cycles

No parasites were seen in tissues of calves prior to 20 days after the oral administration of sporocysts (Fayer and Johnson, 1974). Yet the fact that young schizonts were found in the tissues of experimental calves as long as 33 days after infection (Fayer and Johnson, 1973) suggests to us that at least two cycles of asexual multiplication take place after ingestion of sporocysts. As discussed above, at least two types of schizont occur, one having large and the other small merozoites. Sporozoite-initiated intestinal infections of *I. felis* of the cat, *I. rivolta* and *I. canis* of the dog and probably *I. belli* of man also comprise more than one schizogonic cycle (Brandborg *et al.*, 1970; Hammond, 1973).

Causative organism of Dalmeny disease, and other unidentified sporozoa

The remarkable outbreak of the so-called Dalmeny disease in Canadian cattle (Corner *et al.*, 1963) may have been caused by schizogony of *Sarcocystis* in the organs. Ten out of 17 pregnant cows aborted and out of 25 cattle affected, five died and 12 were killed when moribund. An unidentified protozoon was seen in the endothelial cells of the blood vessels of many tissues in 11 out of 16 animals examined histologically. *Toxoplasma*, to which the parasites bore some resemblance, was excluded by serological tests. From the description of Corner *et al.* (1963), the parasites of the Canadian cattle appear to be indistinguishable from experimentally produced schizonts of *Sarcocystis*. Notable similarities are in (1) size and general appearance, (2) the size and occasional palisade formation of the nuclei, (3) the wide range of tissues infected and (4) the type of cell invaded. As with the experimental calves, heavy infections—possibly acquired by the accidental ingestion of large numbers of sporocysts contaminating the stable — were usually fatal.

Lainson (1972) described a similarly unidentified parasite in the liver and lungs of a bovine in Leicestershire, England, and recognised a strong resemblance to the parasite of Dalmeny disease. This animal, a bull calf, was thought to have died from a deficiency of copper and magnesium (F. G. Clegg, personal communication). One of us (P.C.C.G.) had unstained sections from the case, and we have recently stained them in Giemsa's stain and compared the parasites with those in the sections of kidney provided by Drs. Fayer and Johnson. In our material (Figs. 10, 11), the schizonts are a little smaller than in the experimentally infected tissue, but in other respects, such as the prominent nuclei occasionally in palisade formation, they again resemble the schizonts of *Sarcocystis*. Mononuclear organisms similar to those described by Fayer and Johnson (1974) are present in the lung sections.

Lainson (1972) discusses another unidentified protozoon in the brain, liver and spleen of an armadillo in British Honduras (Belize), which again bore some resemblance to the then unknown proliferative stages of *Sarcocystis*. Lainson found no parasites in impression

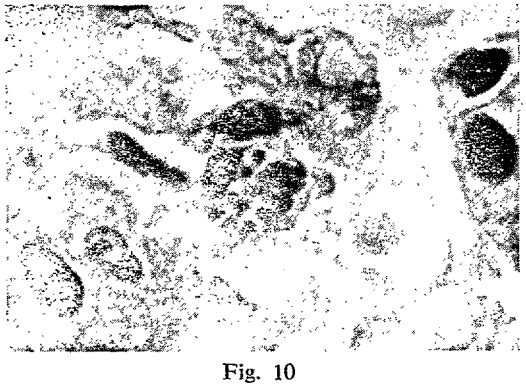

Fig. 10

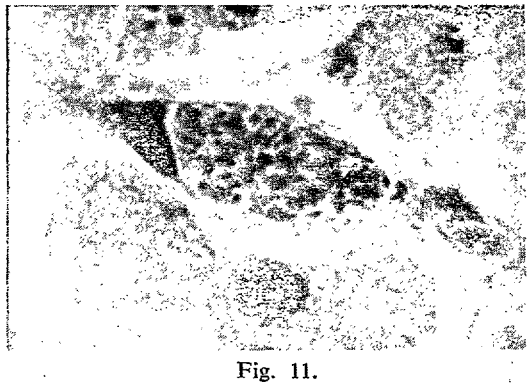

Fig. 11.

Figs. 10 and 11. Schizonts of unidentified protozoon (? *Sarcocystis* sp.) in the liver of a bull calf in England (× 1,500). Giemsa's stain.

smears of lung of the armadillo. A few species of coccidia are known, though imperfectly, from armadillos (see Lainson, 1972). Although there appear to be no published records from this host in Belize or elsewhere, muscle cysts of *Sarcocystis* have been found in armadillos in Pará State (Lainson, personal communication) and Bahia State (Howells, personal communication) in Brazil.

Mandour and Keymer (1972) described a protozoon of uncertain identity in a swamp rat *Otomys kempi*, collected in Zambia. Asexual stages were observed which closely resemble the schizonts of *S. fusiformis* described by Fayer and Johnson (1973) and we think that the parasite was probably *Sarcocystis*. The heart was the most heavily infected organ. Whilst the diaphragm, spleen, lungs and connective tissue (situated between layers of skeletal muscle and between the spleen and pancreas) were also parasitized, no stages were seen in the blood, liver, pancreas, kidney or adrenal glands.

Unidentified schizonts and sexual stages in subcutaneous tissues of a dog were clearly those of a coccidium (Shelton *et al.*, 1968). Records of *Hepatozoon*-like schizonts in other carnivores and in which no stages were seen in the peripheral blood (see Klopfer *et al.*, 1973), need to be re-examined, as some of the parasites may have been *Sarcocystis*. However, as discussed in the following section, muscle cysts of *Sarcocystis* are not often found in carnivores.

Coccidiosis is conventionally thought of as an infection of the intestine. However, even some species of *Eimeria*, as in the case of *Sarcocystis*, undergo extra-intestinal schizogony (and gametogony) (see McCully *et al.*, 1970; Lainson, 1972), and extra-intestinal forms of *I. felis* and *I. rivolta* of the cat and the "small race" of *I. bigemina* of the dog are known (Frenkel, 1973; Heydorn, 1973). Extra-intestinal stages of these three isosporan species and of *I. rivolta* of the dog (Heydorn, 1973) have been shown experimentally to develop in hosts other than the "final" host, and the fact that such stages can occur makes it difficult to identify fortuitously encountered sporozoon-like parasites in the organs of animals with natural infections (*e.g.* Zlotnick, 1955; Dissanaike *et al.*, 1974). Some species of *Isospora* in birds are also thought not to be limited to the intestine (Box, 1973).

Asexual multiplication in carnivores

Tissue cysts of *Sarcocystis* are very rarely found in carnivores such as the dog and cat, yet they are often present in the musculature of animals which are primarily herbivorous. A possible explanation is that asexual multiplication normally takes place in the prey. It may be noted that sporozoites in *S. fusiformis* sporocysts from dogs excysted in the presence of bovine bile but not canine bile (Fayer and Leek, 1973). If this behaviour is constant and applies also to other species of *Sarcocystis* and to the bile of other carnivores, it could be an adaptation to the two-host life-cycle; and may explain why muscle cysts are so rarely seen in predators. Occasionally, however, sarcocysts are encountered in a predator, *e.g. S. lindemanni* in man (Mandour, 1965; Jeffrey, 1974), a species of *Sarcocystis* which may well prove to be the same as one or more species occurring in domestic animals. It is possible that tissue cysts are formed in a predator as a result of asexual multiplication after the accidental ingestion (or perhaps inhalation — see El-Kasaby and Sykes, 1973) of oocysts or sporocysts. The sporocysts most readily available to modern man would probably be those derived from an intestinal infection in the same individual.

Schizogony and gametogony in the same host

The chacma baboon *Papio ursinus* serves as an example of an animal which is both prey and predator. *Isospora papionis* was originally described from the intestine of the chacma baboon by McConnell *et al.* (1971). Its morphological features suggest that it is almost certainly the oocyst of *Sarcocystis*, tissue cysts of which have been seen in muscles of no less than 47 out of 100 baboons (McConnell *et al.*, 1973). Whether these tissue cysts are stages of the same species of *Sarcocystis* described as *I. papionis*, remains to be determined. The chacma baboon occasionally eats meat, even in areas where plant foods are readily available (Stoltz and Saayman, 1970) and intestinal infections of *I. papionis* were detected in two of the 100 baboons examined (McConnell *et al.*, 1973). Direct oocyst-to-oocyst transmission of *Sarcocystis* has not yet been experimentally demonstrated. Thus it is uncertain whether such intestinal infection can occur in the baboon following the ingestion of sporocysts or whether gametogony only takes place in the intestine after the infected flesh of some animal

has been eaten. In view of the prevalence of tissue cysts in the baboon, the role of this animal in the epidemiology of *Sarcocystis* infections would seem to be primarily that of a prey species.

Sporulating and fully sporulated **oocysts** of *l. papionis* were seen in the **skeletal muscle** of two of the 100 baboons examined (McConnell *et al.*, 1972). Sporocysts may have been ingested both by the 47 baboons having tissue cysts of *Sarcocystis* and by the two with oocysts in striated muscle (gametes and oocysts were also detected in the intestine of one of them), giving rise to asexual multiplication in the tissues, with subsequent gametogony (perhaps " accidental ") in an extra-intestinal location.

Transplacental transmission

There are scattered references to *Sarcocystis* infections believed to have been acquired *in utero* (*e.g.* in a foal—Cunningham, 1973). In sheep, congenital sarcosporidiosis is thought to be rare (Munday and Corbould, 1974). However, lambs kept under laboratory conditions from 10 weeks after birth acquired *Sarcocystis* infections from an unknown source (Garnham and Lainson, 1960).

Summary and Conclusions

(1) Species of *Sarcocystis* can infect a variety of animals, and the coccidium has become evolutionarily adapted to the predator-prey relationship existing between its hosts. In view of this, and because of the pantropism of the schizonts in the body, *Sarcocystis* has assumed a new medical and veterinary importance. The pathogenicity of *Sarcocystis* in acute cases may sometimes be greater than hitherto suspected (cf. Dalmeny disease) and the long-term effects of chronic infections are unknown.

(2) Attempts to demonstrate sporocysts in the faeces of four chimpanzees fed tissue cysts of *Sarcocystis fusiformis* from cattle were unsuccessful.

(3) The mean size of 50 sporocysts of *S. fusiformis* in a cat was $12{\cdot}9 \times 8{\cdot}7\mu$m, with a prepatent period of approximately seven days and a minimum patent period of three months. Antibodies detectable by the indirect fluorescent antibody test were not shown in this animal. Prepatent periods of two other feline *S. fusiformis* infections were also about seven days.

(4) *S. fusiformis* tissue cysts in meat are infective to cats for at least two days after storage at 4°C.

(5) The unidentified parasites in Dalmeny disease in Canadian cattle, a calf in Britain and a wild African rodent are considered to have been *Sarcocystis*. Whether an unidentified protozoon in an armadillo in Central America was *Sarcocystis* is less certain.

(6) A tentative life-cycle of *Sarcocystis* is suggested: the sexual cycle normally takes place in a predator and the asexual cycle in an animal which forms its prey. Sporocysts or oocysts shed in the faeces of the predator are ingested by the prey and sporozoites initiate asexual multiplication in reticulo-endothelial cells, particularly endothelial cells of blood vessels. The products of schizogony in turn give rise to muscle cysts which, when eaten by the predator, grow directly into sexual stages in the intestine, with no schizogony preceding gametogony in the gut. Gametogony leads to production of oocysts, which sporulate in the gut wall before being passed in the faeces.

Acknowlegements

We wish to thank the following for assistance: Drs Elizabeth U. Canning, C. C. Draper, R. Gestrich, A.-O. Heydorn, A. N. Markus, Prof. W. M. Hutchison and Mr. S. Thaver. Drs R. Fayer and A. J. Johnson kindly provided us with sections of bovine kidney infected with *Sarcocystis*. We are grateful to Messrs. F. G. Clegg (Veterinary Investigation Centre, Sutton Bonington) and L. M. Markson (Central Veterinary Laboratory, Weybridge) for providing information concerning the Leicestershire calf and for permission to discuss this case.

M.B.M. was supported by the South African Medical Research Council and held a S.A. Council for Scientific and Industrial Research travel grant.

References

Awad, F. I. (1973).
The transmission of *Sarcocystis tenella* in sheep. *Z. ParasitKde, v42,* 43 - 48.

Bigalke, R. D. and **Tustin, R. C.** (1960).
The occurrence of a cyst of *Sarcocystis* Lankester 1882 in the cerebellum of an ox. *Jl S. Afr. vet. med. Ass., v31,* 271 - 274.

Box, E. M. (1973).
Comparative development of two *Isospora* species in the canary. *J. Protozool., v20,* 510.

Brandborg, L. L., Goldberg, S. B. and **Breidenbach, W. C.** (1970).
Human coccidiosis—a possible cause of malabsorption. The life cycle in small-bowel mucosal biopsies as a diagnostic feature. *New Engl. J. Med., v283,* 1306 - 1313.

Corner, A. H., Mitchell, D., Meads, E. B. and **Taylor, P. A.** (1963).
Dalmeny disease. An infection of cattle presumed to be caused by an unidentified protozoon. *Can. vet. J., v4,* 252 - 264.

Cunningham, C. C. (1973).
Sarcocysts in the heart muscle of a foal. *Vet. Rec., v92,* 684.

Dissanaike, A. S., Lim, B. L. and **Poopalachelvam, M.** (1974).
An unusual intracellular "sporozoan" parasite from the moon rat, *Echinosorex gymnurus,* from the Selangor Gombak forest reserve. *S.E. Asian J. trop. Med. publ. Hlth, v5,* 141 - 142.

Dobell, C. (1925).
The life-history and chromosome cycle of *Aggregata eberthi* (Protozoa: Sporozoa: Coccidia). *Parasitology, v17,* 1 - 136.

Dubey, J. P. (1973).
Feline toxoplasmosis and coccidiosis: a survey of domiciled and stray cats. *J. Am. vet. med. Ass., v162,* 873 - 877.

Dubey, J. P., Miller, N. L. and **Frenkel, J. K.** (1970).
The *Toxoplasma gondii* oocyst from cat faeces. *J. exp. Med., v132,* 636 - 662.

Duszynski, D. W. (1971).
Increase in size of *Eimeria separata* oocysts during patency. *J. Parasit., v57,* 948 - 952.

El-Kasaby, A. and **Sykes, A. H.** (1973).
The role of chicken macrophages in the parenteral excystation of *Eimeria acervulina. Parasitology, v66,* 231 - 239.

Euzéby, J., Lestra, Th. and **Gauthey, M.** (1972).
Note de recherche: sur les affinités taxonomiques des sarcosporidies. *Bull. Soc. Sci. vét. Méd. comp. Lyon, v74,* 207 - 211.

Fayer, R. (1970).
Sarcocystis: development in cultured avian and mammalian cells. *Science, v168,* 1104 - 1105.

Fayer, R. (1972).
Gametogony of *Sarcocystis sp.* in cell culture. *Ibid., v175,* 65 - 67.

Fayer, R. and **Johnson, A. J.** (1973).
Development of *Sarcocystis fusiformis* in calves infected with sporocysts from dogs. *J. Parasit., v59,* 1135 - 1137.

Fayer, R. and **Johnson, A. J.** (1974).
Sarcocystis fusiformis: development of cysts in calves infected with sporocysts from dogs. *Proc. helminth. Soc. Wash., v41,* 105 - 108.

Fayer, R. and **Leek, R. G.** (1973).
Excystation of *Sarcocystis fusiformis* sporocysts from dogs. *Ibid., v40,* 294 - 296.

Ford, G. E. (1974).
Prey-predator transmission in the epizootiology of ovine sarcosporidiosis. *Aust. vet. J., v50,* 38 - 39.

Frenkel, J. K. (1973).
Toxoplasmosis: parasite life cycle, pathology, and immunology. In: *The coccidia* (eds Hammond, D. M. and Long, P. L.), pp. 343 - 410. University Park Press, Baltimore and Butterworths, London.

Galuzo, I. G., Bugaev, A. M. and **Konovalova, S. I.** (1973).
Some new considerations on the life cycle of *Toxoplasma gondii. Prog. Protozool., v4,* 147.

Garnham, P. C. C. and **Lainson, R.** (1960).
Sheep as a potential reservoir of *Toxoplasma* for man. *Lancet, v2,* 71 - 74.

Hammond, D. M. (1973).
Life cycles and development of coccidia. In: *The coccidia* (eds Hammond, D. M. and Long, P. L.), pp. 45 - 79. University Park Press, Baltimore and Butterworths, London.

Heydorn, A.-O. (1973).
Zum Lebenszyklus der kleinen Form von *Isospora bigemina* des Hundes. 1. Rind und Hund als mögliche Zwichenwirte. *Berl. Münch. tierärztl. Wschr., v86,* 323 - 329.

Heydorn, A.-O. and **Rommel, M.** (1972a).
Beiträge zum Lebenszyklus der Sarkosporidien. II. Hund und Katze als Überträger der Sarkosporidien des Rindes. *Ibid., v85,* 121 - 123.

Heydorn, A.-O. and **Rommel, M.** (1972b).
Beiträge zum Lebenszyklus der Sarkosporidien. IV. Entwicklungsstadien von *S. fusiformis* in der Dünndarmschleimhaut der Katze. *Ibid., v85,* 333-336.

Hoare, C. A. (1972).
The developmental stages of *Toxoplasma. J. trop. Med. Hyg., v75,* 56 - 58.

Hutchison, W. M., Dunachie, J. F., Siim, J. Chr. and **Work, K.** (1969).
Life cycle of *Toxoplasma gondii. Br. med. J., v4,* 806.

Hutchison, W. M., Dunachie, J. F., Work, K. and **Siim, J. Chr.** (1971).
The life cycle of the coccidian parasite, *Toxoplasma gondii,* in the domestic cat. *Trans. R. Soc. trop. Med. Hyg., v65,* 380 - 399.

Jeffrey, H. C. (1974).
Sarcosporidiosis in man. *Trans. R. Soc. trop. Med. Hyg., v68,* 17 - 29.

Klopfer, U., Nobel, T. A. and **Neumann, F.** (1973).
Hepatozoon-like parasite (schizonts) in the myocardium of the domestic cat. *Vet. Path., v10,* 185 - 190.

Lainson, R. (1972).
A note on sporozoa of undetermined taxonomic position in an armadillo and a heifer calf. *J. Protozool., v19,* 582 - 586.

Ludvik, J. (1963).
Electron microscopic study of some parasitic protozoa. *Prog. Protozool., v1,* 387 - 392.

McConnell, E. E., Basson, P. A., Thomas, S. E. and **de Vos, V.** (1972).
Oocysts of *Isospora papionis* in the skeletal muscles of Chacma Baboons. *Onderstepoort J. vet. Res., v39,* 113 - 116.

McConnell, E. E., Basson, P. A. and **Wolstenholme, B., *et al.*** (1973).
Toxoplasmosis in free-ranging Chacma Baboons (*Papio ursinus*) from the Kruger National Park. *Trans. R. Soc. trop. Med. Hyg., v67,* 851 - 855.

McConnell, E. E., de Vos, A. J., Basson, P. A. and **de Vos, V.** (1971).
Isospora papionis n.sp. (Eimeriidae) of the Chacma Baboon *Papio ursinus* (Kerr, 1792). *J. Protozool., v18,* 28 - 32.

McCully, R. M., Basson, P. A., de Vos, V. and **de Vos, A. J.** (1970).
Uterine coccidiosis of the impala caused by *Eimeria neitzi spec. nov. Onderstepoort J. vet. Res., v37,* 45 - 58.

Mandour, A. M. (1965).
Pathology and symptomatology of *Sarcocystis* infection in man. *Trans. R. Soc. trop. Med. Hyg., v59,* 432 - 435.

Mandour, A. M. and **Keymer, I. F.** (1972).
A protozoan parasite of uncertain nature in Kemp's vlei rat (*Otomys kempi,* Dollman, 1915) from Zambia (Northern Rhodesia). *Proceedings of the first scientific symposium of rodents and their control in Egypt,* pp. 129 - 133. General Organisation for Government Printing Offices, Cairo.

Markus, M. B. (1974).
Birds, coprophagous arthropods and coccidian oocysts. *3rd Int. Congr. Parasit. (abstracts of proceedings), v1,* 98 - 99.

Markus, M. B., Draper, C. C. and **Hutchison, W. M.** *et al.* (1974).
Attempted infection of chimpanzees and cats with *Sarcocystis of cattle. Trans. R. Soc. trop. Med. Hyg., v68,* 3.

Mehlhorn, H. and **Scholtyseck, E.** (1974).
Licht- und elektronmikroskopische Untersuchungen an Entwicklungsstadien von *Sarcocystis tenella* aus der Darmwand der Hauskatze. *Z. ParasitKde, v43,* 251 - 270.

Mehlhorn, H., Scholtyseck, E. and **Senaud, J.** (1974).
Transmission de *Sarcocystis tenella,* chez le Chat, à partir des formes kystiques parasites intramusculaires du Mouton: les oocystes et les sporocystes et microscopie photonique et électronique. *C.r.hebd. Séanc. Acad. Sci., Paris, (D), v278,* 1111 - 1114.

Munday, B. L. and **Corbould, A.** (1974).
The possible role of the dog in the epidemiology of ovine sarcosporidiosis. *Br. vet. J., v130,* ix - xi.

Rijpstra, A. C. (1967).
Sporocysts of *Isospora* sp. in a chimpanzee *(Pan troglodytes, L.). Proc. K. ned. Akad. Wet. (C), v70,* 395 - 401.

Rommel, M. and **Heydorn, A.-O.** (1972).
Beiträge zum Lebenszyklus der Sarkosporidien. III. *Isospora hominis* (Railliet und Lucet, 1891) Wenyon, 1923, eine Dauerform der Sarkosporidien des Rindes und des Schweins. *Berl. Münch. tierärztl. Wschr., v85,* 143 - 145.

Rommel, M. and **Heydorn, A.-O.** (1973).
Sarkosporidien von Rind, Schaf und Schwein in Hund, Katze und Mensch. *Prog. Protozool., v4,* 352.

Rommel, M., Heydorn, A.-O. and **Gruber, F.** (1972).
Beiträge zum Lebenszyklus der Sarkosporidien. 1. Die Sporozyste von *S. tenella* in den Fäzes der Katze. *Berl. Münch. tierärztl. Wschr., v85,* 101-105.

Scholtyseck, E., Mehlhorn, H. and **Müller, B. E. G.** (1973).
Identifikation von Merozoiten der vier cystenbildenden Coccidien (*Sarcocystis, Toxoplasma, Besnoitia, Frenkelia)* auf Grund feinstruktureller Kriterien. *Z. ParasitKde, v42,* 185 - 206.

Shelton, G. C., Kintner, L. D. and **MacKintosh, D. O.** (1968).
A coccidia-like organism associated with subcutaneous granulomata in a dog. *J. Am. vet. med. Ass., v152,* 263 - 267.

Stoltz, L. P. and **Saayman, G. S.** (1970).
Ecology and behaviour of baboons in the northern Transvaal. *Ann. Transv. Mus., v26,* 99 - 143.

Terrell, T. G. and **Stookey, J. L.** (1972).
Chronic eosinophilic myositis in a Rhesus Monkey infected with sarcosporidiosis. *Vet. Path., v9,* 266-271.

Vetterling, J. M., Pacheco, N. D. and **Fayer, R.** (1973).
Fine structure of gametogony and oocyst formation in *Sarcocystis* sp. in cell culture. *J. Protozool., v20,* 613 - 621.

Wallace, G. D. (1973a).
Sarcocystis in mice inoculated with *Toxoplasma*-like oocysts from cat faeces. *Science, v180,* 1375-1377.

Wallace, G. D. (1973b).
The role of the cat in the natural history of *Toxoplasma gondii. Am. J. trop. Med. Hyg., v22,* 313-322.

Zlotnick, A. (1955).
Observations on a parasite found in leucocytes of the peripheral blood in a case of hepato-splenomegaly. *Trans. R. Soc. trop. Med. Hyg., v49,* 472-475.

Zukovic, M., Wikerhauser, T., Dzakula, N. and **Magud, I.** (1973).
Pokusaj peroralne i intraperitonealne invazije miseva malom formom *Isospora bigemina* iz psa. *Acta Parasit. Iugosl., v4,* 43 - 45.

1974. S. Afr. med. J. 48: 2386 (November 30).

CATS AND TOXOPLASMOSIS

To the Editor: A recent report on the prevalence of *Toxoplasma gondii* antibodies shows a greater number of positive sera among cat-show exhibitors than in other persons tested.[1] In this respect the South African results are comparable to data available for owners of pedigree cats in Finland.[2] It is not yet clear why there should be this difference. The extent to which owners of pedigree cats come into contact with their animals needs to be compared with the degree of contact in the case of owners of non-pedigree cats. For example, are pedigree cats used to a greater extent for breeding purposes (i.e. are young cats frequently kept) and how often are they provided with litter trays which owners have to clean? The handling of raw meat by the two groups of owners should also be studied. While the presence of domestic cats or wild felids in an area does appear to be necessary for *Toxoplasma* to exist there,[3] several investigators have failed to find a correlation between the prevalence of antibodies to *Toxoplasma* and having a pet cat in the family.[2,4-7] This is hardly surprising, since the time when oöcysts are most likely to adhere to the fur of a cat is when it defaecates; and unlike oöcysts of species of *Sarcocystis*,[8] those of *Toxoplasma* are not infective on being excreted. However, they will sporulate in moist soil within 1 - 5 days (sporulation can take longer if it is cold) and can survive under such conditions for several months, at least, even during winter.[9] Thus it is likely that there will be a greater chance of a person picking up infective *Toxoplasma* oöcysts on the hands by weeding the garden than by stroking the cat.

Lest cats should come to be regarded as undesirable pets, it is also important to note that apart from the fact that most human toxoplasmosis is subclinical, present knowledge suggests that cats might normally only shed oöcysts once,[10] probably during their first year. This will happen for a period of 1 - 3 weeks. After that a cat is almost always immune to oöcyst-producing reinfection—if not for life, certainly for a long time.

There are oöcysts morphologically indistinguishable from those of *Toxoplasma* and likewise found in cat faeces, but which have proved to be stages of hitherto undescribed organisms with similarities to both *Toxoplasma* and *Sarcocystis*.[11] If such coccidia can infect man, as they may well do, some low titres of apparent antibodies against *Toxoplasma*[1] may represent cross-reaction. However, there is as yet no reason to doubt the specificity of routine serological tests for active human toxoplasmosis.[12,13]

Miles B. Markus

Department of Zoology
Imperial College
University of London
London SW7 2AZ, England

1. Mason, P. R., Jacobs, M. R. and Fripp, P. J. (1974): S. Afr. Med. J., **48**, 1707.
2. Uimanen, I. and Leinikki, P. (1974): Proc. 3rd int. Congr. Parasit., Munich, **1**, 306.
3. Wallace, G. D., Zigas, V. and Gajdusek, D. C. (1974): Amer. J. Trop. Med. Hyg., **23**, 8.
4. Berger, J. and Piekarski, G. (1973): Zbl. Bakt., I. Abt. Orig., **224**, 391.
5. Braveny, I., Disko, R. and Janssen, H. (1973): Dtsch. med. Wschr., **98**, 535.
6. Comstock, G. W. and Ganley, J. P. (1973): Amer. J. Epidem., **97**, 424.
7. Fisher, S. and Reid, R. R. (1973): Med. J. Aust., **1**, 1275.
8. Markus, M. B., Killick-Kendrick, R. and Garnham, P. C. C. (1974): J. Trop. Med. Hyg. (in press).
9. Frenkel, J. K. and Dubey, J. P. (1973): J. Parasit., **59**, 587.
10. Sheffield, H. G. and Melton, M. L. (1974): Proc. 3rd int. Congr. Parasit., Munich, **1**, 106.
11. Frenkel, J. K., Dubey, J. P. and Wallace, G. D. (1974): *Ibid.*, **1**, 110.
12. Markus, M. B. (1973): New Engl. J. Med., **289**, 980.
13. *Idem*: Trans. Roy. Soc. Trop. Med. Hyg. (in press).

From The Veterinary Record, Vol. 96, No. 18, Page 413 (May 3, 1975).

Risk of human infection by *Toxoplasma* oocysts

SIR,—The short review of a paper on toxoplasmosis in your issue of March 8, p 220, suggests that cats may constitute a health hazard. This could be qualified, particularly as the ingestion by man of oocysts through having direct contact with a cat that has just shed them, will not result in his becoming infected.

A cat that passes *Toxoplasma* oocysts in its faeces will do so for only one to three weeks and to have an animal brought into the surgery during that period would not be a common event. Even when it happens, the oocysts in fresh faeces are in any case not immediately infective. They only become so after sporulation within about one to four days under suitable conditions; but sporulated oocysts can remain viable in moist soil for over a year (Frenkel 1974). A veterinary surgeon who frequently has direct contact with cats is perhaps just as likely to pick up infective oocysts on his hands by working in the garden as through, say, taking the temperature of a cat that is excreting *Toxoplasma* oocysts. For a cat to have infective oocysts adhering to its fur, the faeces from which they came would have to be a day or more old. This situation could arise if for example an oocyst-shedding animal were kept at the surgery and became soiled with old faeces in its cage.

There is evidence from research on islands and ~~elsewhere that~~ elsewhere that domestic cats or wild felids have to be present in a region for *Toxoplasma* to exist there (Peterson and others 1974, Wallace and others 1974). However, at least six recent studies in different parts of the world have failed to show a correlation between the prevalence of circulating antibodies to *Toxoplasma* in humans, or the occurrence of seroconversion, and ownership of a pet cat (see Stagno and Thiermann 1973, Markus 1974). Similarly, no significant differences were detected in this respect between veterinarians, their assistants and veterinary students on the one hand and persons not closely associated with the veterinary profession on the other (Riemann and others 1974, Swanepoel and others 1974).

If man ingests infective oocysts of *Toxoplasma* in small numbers, any resulting infection is likely to be subclinical (Durfee and others 1974, Sasaki and others 1974) and of little apparent consequence. It is mainly the foetus that might be at risk (Watson 1972). In addition to not consuming raw or lightly cooked meat, pregnant women should always wash vegetables, fruit and their hands before eating, particularly if it is known that they do not have serum antibodies to *Toxoplasma*.

M. B. MARKUS
Department of Zoology, Imperial College, University of London, London

REFERENCES

DURFEE, P. T., MA, C. H., WANG, C. F., & CROSS, J. H. (1974). *J. Parasit.* 60. 886.
FRENKEL, J. K. (1974). *Z. Parasitenk.* 45. 125.
MARKUS, M. B. (1974). *S. Afr. med. J.* 48. 2386.
PETERSON, D. R., COONEY, M. K., & BEASLEY, R. P. (1974). *J. infect. Dis.* 130. 557.
RIEMANN, H. P., BRANT, P. C., FRANTI, C. E., REIS, R., BUCHANAN, A. M., STORMONT, C., & BEHYMER, D. E. (1974). *Am. J. Epidem.* 100. 197.
SASAKI, Y., IIDA, T., OOMURA, K., TSUTSUMI, Y., TSUNODA, F., ITO, S., & NISHIKAWA, H. (1974). *Jap. J. vet. Sci.* 36. 459.
STAGNO, S., & THIERMANN, F. (1973). *Bull. WHO Hlth Org.* 49. 627.
SWANEPOEL, R., BLACKBURN, N. K., & EFSTRATIOU, S. (1974). *Cent. Afr. J. Med.* 20. 206.
WALLACE, G. D., ZIGAS, V., & GAJDUSEK, D. C. (1974). *Am. J. trop. Med. Hyg.* 23. 8.
WATSON, W. A. (1972). *Vet. Rec.* 91. 254.

From South African Medical Journal, Vol. 49, No. 46, 1 November 1975, Page 1905.

COCCIDIA RELATED TO TOXOPLASMA GONDII: POSSIBLE ZOONOSES

To the Editor: Toxoplasmosis, often with predominating neurological manifestations, is being recognised with increasing frequency in persons who receive immunosuppressive therapy and in patients with severe underlying disease.[1-7] Consequent immunodeficiency can result in persisting primary or recrudescent toxoplasmosis, which is potentially lethal but can be successfully treated.[3] These infections are, however, infrequently diagnosed antemortem and can even be overlooked at autopsy.[3] In the light of newly acquired biological knowledge concerning the 5 described genera of coccidia related to *Toxoplasma gondii*, the question of whether such protozoa could occur in man needs to be considered.

The discovery of an organism closely related to *Toxoplasma* and *Sarcocystis*, and shed in the faeces of cats and dogs, was reported at the 3rd International Congress of Parasitology in Munich in August 1974. This parasite has since been named *Hammondia*.[8-10] Like *Sarcocystis*, which is occasionally found extra-intestinally in human tissues,[11,12] *Hammondia* has an obligatory two-host life cycle and may well show a similar ability to multiply asexually in man. *Hammondia*-like cysts have been seen in man.[9] Although chronic *Hammondia* and *Sarcocystis* infections may not have the propensity of those of *Toxoplasma* for relapsing, some infections with the former organisms might be harmful in the acute phase in the immunologically compromised patient. However, man would not normally ingest oöcysts in the large numbers that cause fatalities in experimental animals or in animals living under natural conditions.[8-10,12-15] Some of the unidentified *Toxoplasma*-like sporozoa responsible for certain documented cases of encephalomyelitis and disease showing other symptoms in large domestic animals[16-18] are thought to have been *Sarcocystis*.[12] Others may have been parasites like *Hammondia*. Some low titres of apparent antibody against *Toxoplasma* in man could, in fact, represent cross-reaction with *Hammondia*.[8-10]

The zoonotic potential of *Besnoitia* and *Frenkelia* will also have to be assessed. *Besnoitia* is now known to have a *Toxoplasma*-like oöcyst stage in its life cycle[19,20] and *Frenkelia* a *Sarcocystis*-like oöcyst.[21]

Large isosporan coccidia which occur commonly in the faeces of domestic and wild carnivores have been thought to be host-specific, but probably exist in the human intestine. Work in which tissues of experimental cats were fed to dogs, and vice versa, showed indirectly that *Isospora felis* of the cat causes extra-intestinal infection in dogs and that *I. canis* of the dog infects cats in the same way.[22] *I. felis* formed cysts containing a single organism in extra-intestinal tissues of normal and immunosuppressed mice and birds. *Toxoplasma*-like proliferation of *I. felis* did not take place in these vertebrates and while such a parasite might infect man, it seems unlikely that it would be pathogenic.

The author was supported by the South African Medical Research Council and the South African Council for Scientific and Industrial Research. Attendance at the 3rd International Congress of Parasitology was made possible by an MRC grant.

M. B. Markus

1. Gleason, T. H. and Hamlin, W. B. (1974): Arch. intern. Med., 134, 1059.
2. Bamford, C. R. (1975): Neurology, 25, 343.
3. Frenkel, J. K., Nelson, B. M. and Arias-Stella, J. (1975): Hum. Pathol., 6, 97.
4. Greenlee, J. E., Johnson, W. D., Campa, J. F., Adelman, L. S. and Sande, M. A. (1975): Ann. intern. Med., 82, 367.
5. Hussey, H. H. (1975): J. Amer. med. Ass., 232, 743.
6. Townsend, J. J., Wolinsky, J. S., Baringer, J. R. and Johnson, P. C. (1975): Arch. Neurol., 32, 335.
7. Whiteside, J. D. and Begent, P. H. J. (1975): J. clin. Path., 28, 443.
8. Frenkel, J. K. and Dubey, J. P. (1975): Z. Parasitenk., 46, 3.
9. *Idem* (1975): Science, 189, 222.
10. Wallace, G. D. (1975): Z. Parasitenk., 46, 167.
11. Markus, M. B. (1974): Trans. roy. Soc. trop. Med. Hyg., 68, 415.
12. Markus, M. B., Killick-Kendrick, R. and Garnham, P. C. C. (1974): J. trop. Med. Hyg., 77, 248.
13. Gestrich, R., Heydorn, A.-O. and Baysu, N. (1975): Berl. Münch. tierärztl. Wschr., 88, 191.
14. Johnson, A. J., Hildebrandt, P. K. and Fayer, R. (1975): Amer. J. vet. Res., 36, 995.
15. Munday, B. L., Barker, I. K. and Rickard, M. D. (1975): Z. Parasitenk., 46, 111.
16. Beech, J. and Dodd, D. C. (1974): Vet. Pathol., 11, 87.
17. Dubey, J. P., Davis, G. W., Koestner, A. and Kiryu, K. (1974): J. Amer. vet. med. Assoc., 165, 249.
18. Hartley, W. J. and Blakemore, W. F. (1974): Vet. Pathol., 11, 1.
19. Rommel, M. (1975): Berl. Münch. tierärztl. Wschr., 88, 112.
20. Wallace, G. D. and Frenkel, J. K. (1975): Science, 188, 369.
21. Rommel, M. and Krampitz, H. E. (1975): Berl. Münch. tierärztl. Wschr., 88, 338.
22. Dubey, J. P. (1975): J. Protozool., 22, 416.