The role of the anterolateral structures and the ACL in controlling laxity of the intact and ACL-deficient knee.

C Kittl[1,2], H El Daou[1], KK Athwal[1], CM Gupte[3], A Weiler[4], A Williams[5], AA Amis[1,3]

Investigation performed at Imperial College London, London, United Kingdom

[1] The Biomechanics Group, Department of Mechanical Engineering, Imperial College London, UK.

[2]Department of Trauma Surgery, Landeskrankenhaus Steyr, 4400 Steyr, Austria

[3]The Musculoskeletal Surgery Group, Department of Surgery and Cancer, Imperial College London, UK.

[4]Sporthopaedicum Berlin, 10627 Berlin, Germany

[5]Fortius Clinic, 17 Fitzhardinge Street, London W1H 6EQ, UK.

Correspondence:

Prof Andrew Amis

The Biomechanics Group

Department of Mechanical Engineering

Imperial College London

London SW7 2AZ

United Kingdom

Tel +44 (0)20 7594 7062

a.amis@imperial.ac.uk

Acknowledgements: This study was supported by a Research Fellowship grant from Smith & Nephew (Endoscopy) Co which supported CK. The EPSRC and Wellcome Trust funded Centre of excellence for the application of technology to the treatment of osteoarthritis at Imperial College London provided the robot and supported HED. The Fortius Clinic London supported JS. Newcastle Healthcare Charity supported KKA. All support was paid to a research account of Imperial College London.

Title:

The role of the anterolateral structures and the ACL in controlling laxity of the intact and ACL-deficient knee.

Abstract

Background:

Anterolateral rotatory instability may result from combined ACL plus lateral extraarticular lesions, but the roles of the anterolateral structures remain controversial.

Purpose:

To determine the contribution of each anterolateral structure and the ACL in restraining simulated clinical laxity tests, in both the intact and ACL-deficient knee.

Study design:

Controlled laboratory study

Methods:

16 knees were tested using a six degree-of-freedom robot with a universal force sensor. The system automatically defined the path of unloaded flexion/extension. At different flexion angles, anterior-posterior, internal-external, and internal rotational laxity in response to the simulated pivot shift were tested. Eight knees were tested with the ACL-intact and eight as ACL-deficient. The kinematics of the intact/deficient knee was replayed after transecting/resecting each structure of interest. Therefore the drop in force/torque reflected the contribution of the transected/resected structure in restraining the laxity test. Data were analyzed using repeated-measures analyses of variance and paired t-tests.

Results:

Anterior translation: While intact, the ACL was clearly the primary restraint. The iliotibial tract (ITT) resisted 31% of the drawer force with the ACL cut, at 30° flexion; the ALL plus anterolateral capsule resisted 4%. Internal rotation: The superficial layer of the ITT significantly restrained internal rotation at higher flexion angles: 56±20% at 90° for the ACL-intact and ACL-deficient groups. The deep ITT layer restrained internal rotation at lower flexion angles, contributing 26±9% and 33±12% for the intact and deficient groups at 30°. The other anterolateral structures had no significant contribution. Pivot-shift-test: The ITT provided 79% of the restraint at 45° for the ACL deficient group. The ACL and the other anterolateral structures had only a small contribution in restraining the pivot-shift.

Conclusion:

The ALL and the anterolateral capsule had a minor role in restraining internal rotation; the ITT was the primary restraint at 30°- 90° flexion.

Clinical relevance:

The ITT showed large contributions to restraining anterior subluxation of the lateral tibial plateau and tibial internal rotation, which constitute the pathological laxity in anterolateral rotatory instability. In cases presenting anterolateral rotatory instability an ITT injury should be suspected and kept in mind if an extra-articular procedure is performed.

What is known about this subject: Despite several recent papers describing the anterolateral soft-tissue anatomy, there has been no objective biomechanical knowledge to support the use of anterolateral ligament reconstructions. A recent paper in the AJSM showed misleading data, given that they resected the ITT before measuring internal rotation restraint.

What this study adds to existing knowledge:

This study shows that it is the ITT that is the primary restraint to tibial internal rotation and the

rotational component of a simulated pivot-shift test. It did not find a significant role for the anterolateral ligament in restraining tibiofemoral laxity, contrary to recent speculation based on anatomical observations.

Introduction:

Anterior cruciate ligament (ACL) reconstruction generally has good to excellent results. However, a substantial group of 5-25% [3, 14, 18] of patients present unsatisfying results regarding International Knee Documentation Committee (IKDC) and return to sport scores. Reasons for this may include surgical error, concomitant peripheral injuries, failure of graft incorporation, and trauma. [18, 22] Unrecognized peripheral injuries may lead to persistent rotatory instabilities [1, 39] and therefore induce higher ACL graft forces [26], and may lead to early onset osteoarthritis. [43] Anterolateral rotatory instability (ALRI) is one of these complex rotatory instabilities, which has been suggested to be caused by an ACL tear either in combination with damaged anterolateral structures of the knee, [21, 29, 33, 46, 48] or by progressive elongation ('stretching-out') of other ligamentous support in a chronic ACL deficiency.[9]

The biomechanical principle behind ALRI is based on the medial shift of the rotational axis of the tibia from the center of the tibial plateau following an ACL rupture. [27, 30, 32] Thus, the lateral tibial plateau is more susceptible to subluxing anteriorly, especially when accentuated by concomitant injuries to the anterolateral structures. [21, 29, 34, 46, 48] This subluxation can be manually elicited in the pivot-shift test by internally and valgus rotating the tibia in low flexion angles. As the knee is then brought from extension to flexion, the tension in the iliotibial tract (ITT) has an increasing posterior component acting on the lateral aspect of the tibia. This suddenly reduces the lateral tibial plateau at higher flexion angles, [5, 32, 49] which is felt as a 'clunk' by the examiner. It is widely accepted that loss of integrity of the ACL is a prerequisite to elicit the pivot-shift phenomenon. [12, 16] However, it is not clear if and how additional injuries to the anterolateral structures influence the subluxation-reduction event. [46]

Injuries of various structures of the anterolateral side of the knee have been suggested to cause increased internal tibial rotational laxity. Damage of the capsulo-osseus layer of the ITT has been proposed to correlate most with the different grades of the pivot-shift. [46] Hematomas [36] and avulsion

[13] of the proximal attachment of the ITT (Kaplan's fibers) have also been noted in patients suffering from an increased rotational instability of the knee. Similarly, the mid-third lateral capsular ligament and the biceps femoris muscle complex have been linked to the Segond fracture, which indicates severe rotational instability [17]. Due to the limited arthroscopic view when performing an ACL reconstruction, injuries to these anterolateral structures may have been unnoticed. However, recent descriptions of the anterolateral ligament (ALL) have led to renewed interest in these structures, which may play a role in controlling rotational laxity of the knee. [6, 8, 20, 47]

The aim of the study was to determine the contribution of the anterolateral structures and the ACL in restraining 1. Anterior-posterior (AP) laxity. 2. Internal-external (IE) tibial rotation laxity. 3. Internal rotation laxity in response to a simulated pivot-shift (sPS) test in the ACL-intact and ACL-deficient knee. Based on the published articles, it was hypothesized that both the ITT and ALL would contribute to resisting anterolateral knee laxity. Knowledge of these contributions would aid the design of improved surgical procedures for stabilizing the knee.

Methods:

Specimen preparation:

18 fresh-frozen cadaver knee specimens were procured from a tissue bank after approval from the local research ethics committee. Two specimens were used to develop the sectioning and robotic testing protocol and the remaining 16 knees were included for final data analysis (mean age: 69; range: 52-93; 8 male, 8 female; 6 left, 10 right). Eight knees were tested with the ACL intact, and the remaining eight knees were used to test the ACL deficient state. In the latter knees the ACL was transected mid-substance through a 15mm mid patellar tendon incision before testing. A MacDonald's dissector was slid into the gap between the cruciate ligaments with the knee flexed, then a scalpel cut laterally/distally away from the dissector until there was a sudden increase in

anterior laxity of the knee that indicated complete ACL deficiency; lack of damage to other structures could be verified after the study was completed.

The knees were stored in polyethylene bags at -20°C, then thawed at room temperature 24h prior to testing. The skin and subcutaneous soft tissue were resected, leaving the muscles, tendons and ligaments intact. The tibia and the femur including all soft tissues were then cut approximately 120mm and 200mm from the joint line respectively. A tricortical screw was used to maintain the anatomic position of the proximal tibio-fibular joint. The tibia was securely potted into a cylindrical stainless-steel tube using polymethylmethacrylate (PMMA) bone cement. The center of the pot was aligned to the tibial axis of rotation at the interspinous space using a custom made alignment jig through a 15 mm longitudinal incision in the patellar tendon. The femur was then potted at 0° knee flexion, while the posterior condylar axis was aligned parallel to the base fixture orientation of the robot. The specimens were left mounted to the robot and kept moist throughout the whole experiment.

Tissue resection and cutting order:

Sequential resection of the anterolateral structures and transection of the ACL was performed whilst the knee remained mounted in the robot at 30° knee flexion. The sequence of cutting was from superficial to deep:

1. Superficial layer of the ITT (the sITT). A curved longitudinal cut from the anterior border of Gerdy's tubercle along the lateral patellar border (lateral retinaculum) was performed to resect the sITT away from its anterior attachment. The biceps femoris muscle complex was then completely resected, including the capsulo-osseus biceps femoris confluence and several tendinous and aponeurotic arms of both the long and short heads of the biceps femoris. The remaining strip of the sITT was then carefully resected from the deep and capsulo-osseus layers. (Figure 1)

2. The deep and capsulo-osseus layer of the ITT (the dcITT) including the Kaplan fibers were resected from their proximal femoral attachment and distal tibial attachment at the lateral tibial rim immediately posterior to Gerdy's tubercle. (Figure 2)

3. After removing the dcITT, the remaining fibers running superficial to the lateral collateral ligament (LCL) and inserting posterior and proximal to the lateral femoral epicondyle on the femur and posterior to Gerdy's tubercle on the tibia were resected (Figure 3). Fibers in this zone have previously been defined as the anterolateral ligament (ALL) by Dodds et al [8]. After this structure had been resected only the capsule remained on the anterolateral aspect of the knee.

4. The whole meniscofemoral and meniscotibial anterolateral capsule was resected. This included the midthird lateral capsular ligament and other fibers described as an ALL [47]. (Figure 4)

5. The ACL was cut midsubstance in the ACL-intact group at 90° knee flexion.

After completion of the initial testing stages listed above in knees 1 to 4, the protocol for knees 5 to 8 was extended in order to test additional structures on the medial side. This followed data processing on the first four knees, which showed a large residual resistance to tibial internal rotation after resecting/cutting the anterolateral structures and ACL. Unfortunately, because work on the medial structures had not been planned, the test protocol had not allowed for remounting the knees into the robot with sufficient precision to allow their testing to be extended, and so knees 1 to 4 could not be included in the extension to the protocol.

The following cuts were performed on four knees of the ACL-intact group after remounting the knees to the robot:

6. The medial collateral ligament complex, including the deep medial collateral ligament (dMCL) and the superficial collateral ligament (sMCL), was transected.

7. The posterior medial corner (PMC) including the posterior oblique ligament (POL), the semimembranosus tendon (SM) and the posterior medial capsule was transected.

Testing protocol:

Prior to testing, the knee was manually flexed and extended 10 times to minimize tissue hysteresis. The tibia and the femur were then mounted to the end-effector and to the fixed base unit of the robot at 0° knee flexion, respectively. In order to find the starting position at 0° all forces and moments acting across the tibio-femoral joint were neutralized. The robot automatically defined the path of passive motion of the knee across the range of flexion and extension by minimizing constraining forces and moments acting across the knee. The knee could then be moved to each desired angle of flexion and the simulated clinical tests were assessed, while all remaining forces/torques were minimized.

Simulated knee laxity tests were performed at 0°, 30°, 60° and 90° flexion, where anterior-posterior translation and internal-external rotation laxity were tested in response to a 90N anterior-posterior force and 5Nm internal-external torque respectively. The robot constrained the knee to remain at the chosen angle of flexion while the force or torque was applied, but was programmed to seek zero load in the secondary degrees of freedom of motion when the tibia was moved away from its initial position of equilibrium. Thus, for example, the tibia was allowed to rotate about its long axis and in valgus/varus, and also to move in medial/lateral and proximal/distal translations when an anterior translation was imposed. A simulated pivot shift test (4Nm internal tibial rotation and 8Nm valgus rotation) was performed at 15°, 30° and 45° flexion. The internal tibial torque was applied first and held constant while the valgus torque was applied and released, and tibial motion in the remaining degrees of freedom was measured, such as coupled anterior translation [23, 51]. After each resection/cut was performed, the same motion of the simulated laxity tests of the intact state was replayed and the force/torque versus displacement data were recorded. Thus the decrease in force/torque represented the contribution of the resected/cut structure in restraining the laxity test.

Each simulated laxity test was repeated 3 times. The loads were selected to be at the lower range of those applied during clinical examination of knee laxity, in order to prevent 'stretching-out' of the remaining structures after some had been resected/cut.

Internal and external rotation (5Nm) was tested at only 30° for the four remounted knees of the ACL intact group in order to test the structures on the medial side. In order to prevent error from remounting the specimen, the intact kinematics were replayed by moving the robot in position control to reproduce the path of motion recorded earlier when the knee was intact and the resulting forces and torques were used as a reference prior to any additional cuts.

Robotic biomechanical testing system:

The biomechanics testing platform (Figure 5) was a six degree-of-freedom industrial robot (Stäubli TX90, Stäubli Co., Pfaffikon, Switzerland) and a six axis universal force-moment sensor (UFS) (Omega85, ATI Industrial Automation). Similar configurations have been used previously [15]. The robot had a maximum load capacity of 200N and a repeatability of ±0.03 mm. The UFS was mounted between the specimen's tibia and the robot end-effector using a custom made mechanical fixture and had a resolution of 0.3N in the x and y-axes and 0.4N for the Z axis. The UFS could measure torques up to 80Nm in all three axes with a resolution of 0.013Nm about the x and y axes and of 0.009Nm about the z axis.

For the initial state of each knee (ACL intact group and ACL deficient group), the robotic platform was controlled to find the passive path of flexion-extension by minimizing the forces and torques, and then to simulate clinical laxity tests, while recording the position and the corresponding forces and torques at every 0.04 s.

Data Analysis:

A power calculation based on prior work on rotatory knee laxity [24] determined that a sample size of 8 would allow identification of changes of translation and rotation of 2.1 mm and 1.2° respectively with 80% power and 95% confidence.

Force or torque versus displacement graphs were plotted for each simulated laxity test, each flexion angle, and each knee. The force/torque endpoints of the three cycles were averaged. In order to obtain the internal rotation torque endpoint in case of the simulated pivot-shift the torque value was measured when the valgus torque was at its peak. The decrease in force/torque after each cut was then converted into percentage of the intact state/deficient state, which acted as a reference.

A repeated-measures ANOVA was used to assess the main effects of each independent variable (deficiency status and flexion angle) and the interaction between them for the ACL-intact and ACL-deficient groups. The dependent variables were the percentage contributions in restraining 1. Anterior translation; 2. Posterior translation; 3. Internal rotation; 4. External rotation; and 5. Internal rotation in response to a simulated pivot-shift test. Pairwise comparisons with Bonferroni correction to maintain 95% confidence were used to compare each contribution at different flexion angles.

Independent sample t-test or the Mann-Whitney U test for non-normally distributed data were used to address statistical significances between the ACL-intact and ACL-deficient group for each simulated test mentioned above.

Statistical analysis was performed in SPSS version 21, with significance level set at $P<0.05$.

Results:

Anterior and posterior tibial translation:

Overall, the anterolateral cutting sequence caused a significant increase ($p<.001$) in anterior laxity for both the ACL-intact and ACL-deficient groups. For the posterior translation only the ACL-intact group showed a significant effect ($p<0.05$). The interaction with the flexion angle was significant

(p<.001) when applying an anterior translation force, meaning that the contributions of each of the resisting structures varied across the arc of flexion.

ACL-Intact group:

Only the ACL had a significant role in restraining a 90N tibial anterior translation force (p<.001 at 0°, 30°, 60° and 90° knee flexion) (Figure 6). All other sectioned structures (Table 1) had only a small contribution. Furthermore, there was no significant contribution in restraining a 90N posterior tibial force for the ACL and all tested anterolateral structures.

ACL-Deficient group:

The sITT significantly restrained a 90N tibial anterior translation at 60° (p<.01) and 90° (p<.001), whereas the dcITT presented a significant contribution at 0° (p=.05), 30° (p=<.01), 60° (p=.05), and 90° (p=.04) (Figure 6). Compared to the ACL-intact group, all structures tended to make a higher contribution to restraining a 90N anterior tibial translation, but that change was only statistically significant for the sITT at 60° (p=.04) and the dcITT at 30° (p<.01).

Similar to the intact group none of the structures demonstrated a significant contribution to restraining a 90N posterior translation force.

Internal and external tibial rotation:

The state of the ACL (intact versus deficient) had a significant effect (p<.001) on the contributions of the structures of interest in restraining both internal and external rotation across the whole range of motion. Furthermore the percentage contributions changed significantly (p<.001) with knee flexion angle, when applying an internal rotation torque. For the external rotation only the ACL intact group showed small, but significant (p=0.042) changes of percentage contributions with flexion angle.

ACL-Intact group:

At full extension only the ACL had a statistically significant (p<.01) contribution to restraining a 5Nm internal rotation torque. (Figure 7, Table 2) The tested anterolateral structures collectively contributed a slightly higher resistance (23±18%), but none of them made a significant individual contribution. At 30°, 60° and 90° knee flexion both the sITT (p=.012; p<.01; p<.01), and dcITT (p<.01; p=.033; p=.023) provided a significant resistance to tibial internal rotation torque. The sITT had a greater impact at high flexion angles, reaching 56±20% contribution at 90°, whereas the dcITT showed a greater contribution at low flexion angles, reaching 26±9% at 30°. The whole ITT presented therefore a total contribution of 44%±10% at 30°, 76±11% at 60°, and 71±15% at 90°. The extracapsular ALL described by Dodds et al [8] displayed its highest contribution at 30° knee flexion (11±10%), which was not significant. Similarly, a significant role for the anterolateral capsule was not found at any tested knee flexion angle.

None of the tested structures made a significant contribution to restraining a 5Nm external tibial rotation torque, except the sITT at 30° (7±3%; p=.012) and 60° (4±3%; p=.039) knee flexion, which was small, but statistically significant.

The MCL and the PMC contributed 15±4% and 15±13% respectively to restraining tibial internal rotation at 30° flexion, which were not found to be significant with the small number tested (N=4) (Figure 7, Table 2). However the MCL had a significant (p=.037) role in restraining external tibial rotation, resulting in a 62±11% contribution at 30° knee flexion (N=4).

ACL-Deficient group:

The dcITT contributed the only significant (p=.027) restraint to a 5Nm internal rotation torque at full extension, which was also significantly larger (p<.01) than in the intact group. (Figure 7, Table 2) Both the sITT and the dcITT made significant contributions to restraining a 5Nm internal rotation torque at 30°, 60°, and 90°: p<.01, p<.001, and p<.001, respectively for the siTT and p<.01, p=.021, p=.02, respectively for the dcITT. Thus, the whole ITT (sITT+ dcITT) contributed a total internal

rotation restraint of 58±10% at 30°, 80±13% at 60°, and 76±14% at 90° knee flexion for the ACL deficient knee. Conversely, all the other anterolateral structures (ALL and the anterolateral capsule) made only a small contribution to restraining a 5Nm internal rotation torque, which was not found to be significant and did not differ significantly from their contribution with the ACL intact.

None of the tested structures in the ACL-deficient knee had a significant role in restraining tibial external rotation.

Simulated pivot-shift test:

Cutting structures caused a significant increase in sPS laxity in both the ACL intact ($p<.001$) and ACL deficient groups ($p<.001$) across the range of motion tested. There was also a significant interaction with flexion angle for both groups ($p<.001$), that is: the percent contributions varied as the knee flexed.

ACL-Intact group:

The dcITT significantly restrained a 4Nm internal rotation torque under a combined valgus torque at all tested flexion angles: ($p<.01$ at 15°, 30° and 45° knee flexion (Figure 8, Table 3). The sITT had a significant role ($p<.01$) in restraining the rotational component of the simulated pivot shift only at 45° (37±14%) of knee flexion. The ALL, ACL and the anterolateral capsule made only small contributions to restraining internal tibial rotation under the simulated pivot shift at all tested flexion angles (n.s.).

ACL-Deficient group:

Similarly to the ACL-intact group, the sITT at 45° ($p=.015$), and the dcITT at 15° ($p<.01$), 30° ($p<.01$), and 45° ($p=.048$) made a significant contribution to restraining a 4Nm internal rotational torque under a combined 8Nm valgus torque in an ACL-deficient knee. (Figure 8, Table 3) Although the

contribution of the ALL at 15° (7±4%) was lower than in the ACL-intact group, it made a significant contribution (p=.049) to restraining the simulated pivot-shift test.

Discussion:

The main finding of this study was that, contrary to the hypothesis and recent speculation based on anatomic observations alone, neither the extracapsular ALL or anterolateral capsular structures offered significant resistance to tibial internal rotation from 0 to 90° knee flexion. At full knee extension, the ACL was a significant restraint in the intact knee; with ACL-deficiency, that role fell onto the deep capsulo-osseous layer of the ITT. The combined actions of the superficial and deep layers of the ITT were the primary restraint (that is: their combined contribution was greater than 50% of the total) to tibial internal rotation above 30° knee flexion, and this contribution increased with increasing knee flexion, reaching 74% of the total resistance at 60° knee flexion. These findings fit with the observation of Terry et al [46], that the deep capsulo-osseous layer of the ITT had been damaged in 93% of functionally unstable knees that were reconstructed, and that this damage correlated significantly with the grade of the pivot-shift, whereas ACL damage did not.

It is widely accepted that the ACL is the primary restraint to anterior tibial translation. This is supported by our results, as the ACL was the only significant restraint in response to a 90N anterior tibial translation force. However, Butler et al [4] reported that the ACL made a larger contribution than was found in this study: 87% and 85% at 30° and 90° flexion, respectively. This difference may be because the test method used in the earlier study did not allow free tibial rotation, and so the ITT could not come into play as coupled tibial internal rotation was blocked.

There are inconsistencies across studies regarding the role of the ACL in controlling tibial internal rotation. Some authors found no statistically significant increase of internal tibial rotation after cutting the ACL. [7, 25] Similarly to the present study, other authors showed that ACL-deficiency

allowed a small but statistically significant increase in internal rotation [27, 31, 48] and internal rotation in response to a simulated pivot-shift test [23, 51] at low flexion angles. In accordance with Oh et al [37], who found a 13% decrease in dynamic internal rotational resistance in a simulated pivot landing at 15° knee flexion after cutting the ACL, we found a 17% decrease in response to a simulated pivot-shift test at 15° knee flexion and an almost 20% decrease of an isolated internal rotation moment at full extension. This also corresponds with Zantop et al [50], who found that the posterolateral bundle of the ACL played an important role in controlling internal rotation at low flexion angles. Loss of this constraint, which induces the 'screw-home', may allow anterior translation of the lateral tibial plateau in early knee flexion. [2, 5]

This study found that the anterolateral structures, particularly the superficial and deep layers of the ITT, were the primary restraint to tibial internal rotation between 30°-90° knee flexion and 30°- 45° for the simulated pivot-shift. Contrary to recent speculation, the ALL and related capsular structures together (so as to encompass the variety of recent anatomical interpretations of 'the ALL') were found to be a minor restraint. Sequential cutting studies investigating changes of joint laxity in internal tibial rotation and the simulated pivot shift have been carried out by several authors. Wroble et al [48] found a significant increase in internal rotation after sectioning the entire anterolateral structures at 30° and above. Yamamoto et al [49], and Hassler and Jakob [19] found such a large increase in internal rotation after cutting the ITT that the reduction of the lateral tibial plateau in a pivot shift test disappeared. Suero et al [42] measured a significant increase in lateral compartment translation after cutting the ITT, but concluded that it did not have more effect than other lateral structures. Looking at the current study's results, and the larger lever arms about the axis of tibial internal rotation of the peripheral structures, it appears logical that the anterolateral structures control internal rotational laxity better than the central ACL. However, although the studies described above presented data about changes of laxity – which are used for clinical diagnosis – that is not the same as knowing how much each structure contributes to restraining the laxity; that is: which are the primary and secondary restraints? There has been one study published

which addressed this question [38], but unfortunately they removed the superficial ITT prior to the experiment, which the present work has shown to be a primary restraint. In this state, the remaining structures will appear to be more important than they actually are in the intact knee. Also, the kinematics of the knee will have been abnormal, with further consequences for the validity of the data. Furthermore, tissues deep to the superficial ITT were preserved, and so data presented for "the ALL" may have been a combination of the deep layer of the ITT, plus the extracapsular ALL, plus the capsular structures, all of which have been shown in the present study to have distinct contributions. Thus, their conclusion that the ALL is a primary restraint to tibial internal rotation at high flexion angles may be questioned, and that was not found to be the case in the present study.

In the absence of the ACL, its restraining action fell onto the remaining intact structures, so the contributions of the superficial and deep layers of the ITT to restraining internal rotation and the simulated pivot-shift test were enhanced for the ACL deficient knees at almost every flexion angle. However this increase was only significant (4% to 18%) for the capsulo-osseus layer at 0°, which was where the ACL had made its largest contribution to controlling tibial rotation. These results suggest that the load on the ITT, and especially on the deep capsulo-osseus layer, will increase after ACL rupture. This is in accordance with previous data showing that simultaneous intra-articular ACL and extra-articular lateral reconstructions share the load imposed on the knee [10].

The contributions of the MCL and PMC to resisting tibial internal rotation at 30° knee flexion were measured in four knees as an ad-hoc addition to the original test protocol. That was because, after finishing the test series on the anterolateral structures and the ACL, the internal tibial rotation results at early flexion angles left speculations on the remaining 33% contribution at 30° knee flexion. Unfortunately, further investigation of the peripheral structures restraining internal tibial rotation of the knee could only be performed in four knees, because at this time it was not possible to remount the other knees to the robot in the exact same position without altering the kinematics due to residual forces/moments. The MCL and the PMC each contributed 15% of the restraint to

internal tibial rotation, implying a greater role than the ALL, the anterolateral capsule, and the ACL at 30° knee flexion. Moreover, the MCL showed a 60% contribution to restraining external rotation at 30°, which implies a substantial role in restraining external tibial rotation, as suggested by previous work. [40] These data were collected from only four knees, so are just an indication and cannot be taken as solid results. However, they suggest that it should be worthwhile to revisit the roles of the medial and posteromedial structures in restraining rotational laxity.

The differences in anatomical descriptions of the anterolateral aspect of the knee are not surprising, considering the complexity and variability of the structures found there. The femoral attachment of the ALL has been described at three different positions and it is not even agreed whether the ALL is a capsular or extracapsular structure [6, 8, 20, 47]. Different characterizations of the ALL may also have been confused with previously described structures like the deep capsulo-osseus layer of the ITT [44], the midthird lateral capsular ligament [21], the bilaminar structure of the capsule [41], and the aponeurotic extensions of the biceps femoris muscle [45]. Contrary to recent speculation, the extracapsular ALL (described by Dodds et al [8]) and the entire anterolateral capsule (which included the ALL described by Claes et al [6], Helito et al [20], and Vincent et al [47]) showed only a small contribution in restraining internal tibial rotation or internal tibial rotation in response to a simulated pivot shift test at all flexion angles examined. The capsulo-osseus layer of the ITT, on the contrary, is a more substantial structure which showed high potential in restraining anterior subluxation of the lateral tibial plateau, so it is surprising that damage of the anterolateral capsule and not the ITT has been considered as the cause of ALRI in recent publications. The functional importance of the ITT (especially the deep and capsulo-osseus fibers) is also implied by the high number of proprioceptors which have been found in the distal part of the ITT system. [11, 28] Thus, the deep and capsulo-osseus fibers of the ITT might have been underestimated in their role as potent restraints to ALRI, as evidenced by the biomechanical data on the ITT load-sharing with the ACL from Noyes et al [35] and the correlation with pivot-shift instability. [45, 46]

Although the present study presented an appropriate way of determining the contribution of peripheral structures in restraining knee laxity, it had several important limitations to note. The testing concentrated on the contribution of soft tissues in restraining knee laxity in a quasi-static setup that did not include the axial compression loading present during gait, and thus simulated clinical manual examination loading. This setup did not determine the contribution to functional stability of muscle loading; the short knee specimens had no proximal continuity to the tensor fascia lata, for example, and so the role of the ITT found in this work was likely to have been underestimated. The contribution of each structure to resisting tibiofemoral displacements was precisely derived from the intact/deficient kinematics of the knee using a repeated displacement-controlled method. A force-controlled method, which allows measurement of the increased joint laxity at a given load that follows the cutting of each structure, may appear to be more relevant for clinical diagnosis, but the results are sequence-dependent and so care must be taken in interpreting the resulting data. For example, if a minor restraint (such as the ALL) is the last structure left intact, then cutting it will allow a large increase in laxity, but that does not mean that it carried a significant load in use. Finally, it may be possible that resection of superficial structures – required here for visualization of deeper capsular structures – led to results different to those which would have resulted from isolated transection or real-world injuries.

Conclusion:

This study has measured the contributions of the ACL and anterolateral structures of the knee to resisting tibial internal rotation motion, for both the intact knee and after ACL injury. The data may offer guidance for the treatment of rotational instability of the injured knee. The ITT was found to be the primary restraint to internal tibial rotation for both the intact and ACL-deficient knee, from 30° to 90° knee flexion. The ITT was also found to be the primary restraint tointernal tibial rotation induced by application of a simulated pivot shift test, at 15° to 45° knee flexion. The contributions of the deep and capsulo-osseous fibers of the ITT imply a potent role in restraining anterior subluxation

of the lateral tibial plateau. This work did not find a significant restraining role for the ALL. These data suggest that it may be appropriate to identify and possibly to reconstruct additional ITT injuries in case of a suspected ALRI. Clinical research should focus on identifying additional peripheral injuries in MRI and clinical examination studies.

Tables:

Table 1. Sequential cuts/resections and corresponding anatomical structures

Cuts	Corresponding anatomical structure
Cut 1 (sITT)	Superficial layer of the iliotibial tract (ITT)*, biceps femoris muscle complex (including tendinous and aponeurotic arms of the long and short head.), biceps-capsuloosseous iliotibial tract confluens, lateral retinaculum, lateral patellofemoral ligament, lateral patellomeniscal ligament.
Cut 2 (dcITT)	Deep and capsulo-osseus layer of the ITT (supracondylar insertion, insertion near the septum, and retrograde insertion)
Cut 3 (ALL)	All structures running superficial to the LCL (anterolateral ligament; ALL described by Dodds et al., superficial capsule described by Seebacher et al.)
Cut 4 (Cap)	Whole anterolateral capsule (ALL described by Claes et al., Vincent et al., and Helito et al.)
Cut 5 (ACL)	Anterior cruciate ligament
Cut 6 (MCL)	Medial collateral ligament (superficial and deep portion)
Cut 7 (PMC)	Posteromedial corner (posterior oblique ligament, semimembranosus tendon, posteromedial capsule)

Table 2. Contribution [%] of each structure restraining a 5Nm internal rotation torque (for abbreviations see Table 1; shown as mean +/- SD; n=8 per group)

Cuts	**0°**		**30°**		**60°**		**90°**	
	Intact	**Def.**	**Intact**	**Def.**	**Intact**	**Def.**	**Intact**	**Def.**
sITT	8.3±7.7	3.7±3.6	18.1±9.1	24.3±12.5	52.2±18.1	53.7±15.3	55.8±20.4	55.6±16.1
dcITT	4.3±3.9	18.3±11.4	25.6±9	33.2±12.3	23.4±14.1	26±15.5	15.5±8.7	20.8±12.3
ALL	5.8±6.5	4.4±4.3	11±9.7	4.9±4.1	4.9±3.9	2.3±2.1	10±11.5	3.3±2.9
Cap	4.1±2.8	1.8±1.9	3.1±2.7	2±2.7	1.3±1.8	0.7±1.8	3.3±2.4	3.9±8.2
ACL	19.7±7.9	-	8.9±7.7	-	1±1.5	-	0.9±0.8	-
MCL	-	-	14.5±4.4	-	-	-	-	
PMC	-	-	14.7±12.6	-	-	-	-	

Table 3. Contribution [%] of each structure restraining a 4Nm internal rotation torque in response to a simulated pivot shift test (8Nm valgus torque) (for abbreviations see Table 1; shown as mean +/- SD; n=8 per group)

Cuts	**15°**		**30°**		**45°**	
	Intact	**Def.**	**Intact**	**Def.**	**Intact**	**Def.**
sITT	6.7±7.6	6.4±7.7	12.7±10.3	19±13.3	36.8±13.8	43.8±21
dcITT	17.3±7.8	27.2±13.3	29.3±12.5	35.4±13.8	35.5±13.4	28.4±17.2
ALL	11.1±11.4	6.9±4	13.8±14.4	5.8±5.1	8.4±7.8	2.9±2.2
Cap	4.1±3.4	2.3±2.5	2.6±2.5	2.2±2.6	2.1±1.7	0.7±1.3
ACL	16.8±10.9	-	10.4±9.9	-	5.1±5.6	-

Captions for illustrations

Figure 1. Lateral aspect of a left knee: the femur extends proximally to the right, and the tibia extends distally towards the bottom,left, with the patella at the top, left. Superficial layer of the iliotibial tract (ITT) flapped down (1), proximal femoral insertion of the ITT (2), supracondylar insertion of the ITT (3), retrograde insertion or capsulo-osseus layer (4), superior genicular artery (5), lateral collateral ligament (6), fibular head (7), Gerdy's tubercle (8), intermuscular septum (9).

Figure 2. Lateral aspect of a left knee: the femur extends proximally to the right, and the tibia extends distally towards the left, with the patella at the top. A, superficial layer of the iliotibial tract (ITT) and biceps femoris muscle complex removed. Gerdy's tubercle (1), capsulo-osseus layer of the ITT (2) inserting posterior to Gerdy's tubercle, lateral collateral ligament (LCL) (3). B, insertion site of the resected capsulo-osseus layer of the ITT (1), LCL (2).

Fig 3: lateral aspect of left knee: the femur extends proximally to the right, and the tibia extends distally towards the left, with the patella at the top. Shown after removal of deep capsule-osseous layer of ITT, leaving the extracapsular ALL exposed (arrows), passing over the proximal LCL. The femoral attachment is proximal and posterior to the epicondyle; the tibial attachment is midway between Gerdy's tubercle and the head of the fibula.

Figure 4. lateral aspect of a left knee: the femur extends proximally to the right, and the tibia extends distally towards the left, with the patella at the top. A, All structures running superficial to the lateral collateral ligament (LCL) were removed. Gerdy's tubercle (1), anterolateral capsule (2), LCL (3), femoral attachment of the lateral head of the gastrocnemius muscle (4). B, After removal of the anterolateral capsule, Gerdy's tubercle (1), lateral meniscus (2), popliteus tendon (3), LCL (4), femoral attachment of the lateral head of the gastrocnemius muscle (5).

Figure 5. Setup of the six degrees-of-freedom robotic system. The end of the moving arm of the robot has the tibial pot attached to it via a force/torque sensor. The femur is secured in a fixed mounting on the base.

Figure 6. Contribution [%] of tested structures in restraining a 90N anterior tibial translation at 0°, 30°, 60°, and 90°. Cross-hatched areas indicate results from the ACL-deficient group. sITT=superficial layer of the iliotibial tract; dcITT= deep and capsulo-osseus layer of the iliotibial tract; ALL= anterolateral ligament; Cap= anterolateral capsule; ACL= anterior cruciate ligament. Statistical significance: *p<.05; **p<.01; *** p<.001. (Shown as mean + SD, n=8)

Figure 7. Contribution [%] of tested structures in restraining a 5Nm internal rotation torque at 0°, 30°, 60°, and 90°. There is only one result for each of the medial collateral ligament (MCL) and the posterior medial corner (PMC) because they were only tested at 30° knee flexion, on four knees. Cross-hatched areas indicate results from the ACL-deficient group. ITT=superficial layer of the iliotibial tract; dcITT= deep and capsulo-osseus layer of the iliotibial tract; ALL= anterolateral ligament; Cap= anterolateral capsule; ACL= anterior cruciate ligament. Statistical significance: *p<.05; **p<.01; *** p<.001. (Shown as mean + SD, n=8, apart from MCL and PMC when n=4)

Figure 8. Contribution [%] of tested structures in restraining a 4Nm internal rotation torque in response to a simulated pivot shift test (4Nm internal rotation and 8Nm valgus rotation) at 15°, 30°, and 45°. Cross-hatched areas indicate results from ACL-deficient group. sITT=superficial layer of the iliotibial tract; dcITT= deep and capsulo-osseus layer of the iliotibial tract; ALL= anterolateral ligament; Cap= anterolateral capsule; ACL= anterior cruciate ligament. Statistical significance: *p<.05; **p<.01; *** p<.001. (Shown as mean + SD, n=8)

References:

1. Amis AA, Bull AM, Lie DT. Biomechanics of rotational instability and anatomic anterior cruciate ligament reconstruction. *Oper Tech Orthop.* 2005;15(1):29-35.

2. Andriacchi TP, Dyrby CO. Interactions between kinematics and loading during walking for the normal and ACL deficient knee. *J Biomech.* 2005;38(2):293-298.

3. Ardern CL, Webster KE, Taylor NF, Feller JA. Return to sport following anterior cruciate ligament reconstruction surgery: a systematic review and meta-analysis of the state of play. *Br J Sports Med.* 2011;45(7):596-606.

4. Butler DL, Noyes FR, Grood ES. Ligamentous restraints to anterior-posterior drawer in the human knee. A biomechanical study. *J Bone Joint Surg Am.* 1980;62(2):259-270.

5. Carson WG, Jr. Extra-articular reconstruction of the anterior cruciate ligament: lateral procedures. *Orthop Clin North Am.* 1985;16:191-211.

6. Claes S, Vereecke E, Maes M, Victor J, Verdonk P, Bellemans J. Anatomy of the anterolateral ligament of the knee. *J Anat.* 2013;223:321–328.

7. Diermann N, Schumacher T, Schanz S, Raschke MJ, Petersen W, Zantop T. Rotational instability of the knee: internal tibial rotation under a simulated pivot shift test. *Arch Orthop Trauma Surg.* 2009;129:353-358.

8. Dodds A, Halewood C, Gupte C, Williams A, Amis A. The anterolateral ligament Anatomy, length changes and association with the Segond fracture. *Bone Joint J.* 2014;96(3):325-331.

9. Ellison AE. The pathogenesis and treatment of anterolateral rotatory instability. *Clin Orthop Relat Res.* 1980(147):51-55.

10. Engebretsen L, Lew WD, Lewis JL, Hunter RE. The effect of an iliotibial tenodesis on antraarticular graft forces and knee joint motion. Am J Sports Med 18: 169-176.

11. Fairclough J, Hayashi K, Toumi H, et al. The functional anatomy of the iliotibial band during flexion and extension of the knee: implications for understanding iliotibial band syndrome. *J Anat.* 2006;208(3):309-316.

12. Fetto JF, Marshall JL. Injury to the anterior cruciate ligament producing the pivot-shift sign. *J Bone Joint Surg Am.* 1979;61(5):710-714.

13. Fleming RE, Jr., Blatz DJ, McCarroll JR. Lateral reconstruction for anterolateral rotatory instability of the knee. *Am J Sports Med.* 1983;11(5):303-307.

14. Freedman KB, D'Amato MJ, Nedeff DD, Kaz A, Bach BR, Jr. Arthroscopic anterior cruciate ligament reconstruction: a metaanalysis comparing patellar tendon and hamstring tendon autografts. *Am J Sports Med.* 2003;31(1):2-11.

15. Fujie H, Mabuchi K, Woo S L-Y, Livesay G, Arai S, Tsukamoto Y. The use of robotics technology to study human joint kinematics: a new methodology. J Biomech Eng 1993; 115: 211-217.

16. Galway HR, MacIntosh DL. The lateral pivot shift: a symptom and sign of anterior cruciate ligament insufficiency. *Clin Orthop Relat Res.* 1980:45-50.**15.**

17. Goldman AB, Pavlov H, Rubenstein D. The Ségond fracture of the proximal tibia: a small avulsion that reflects major ligamentous damage. *Am J Roentgenol* 1988; 151: 1163-1167.

18. Harner CD, Giffin JR, Dunteman RC, Annunziata CC, Friedman MJ. Evaluation and treatment of recurrent instability after anterior cruciate ligament reconstruction. *Instr Course Lect.* 2001;50:463-474.

19. Hassler H, Jakob RP. Ein beitrag zur ursache der anterolateralen instabilität des kniegelenkes. *Arch Orthop Trauma Surg.* 1981;98:45-50.

20. Helito CP, Demange MK, Bonadio MB, et al. Anatomy and Histology of the Knee Anterolateral Ligament. *Orthop J Sports Med.* 2013;1:2325967113513546.

21. Hughston J, Andrews J, Cross M, Moschi A. Classification of knee ligament instabilities. Part II. The lateral compartment. *J Bone Joint Surg Am.* 1976;58(2):173.

22. Jaureguito JW, Paulos LE. Why grafts fail. *Clin Orthop Relat Res.* 1996(325):25-41.

23. Kanamori A, Woo SL, Ma CB, et al. The forces in the anterior cruciate ligament and knee kinematics during a simulated pivot shift test: A human cadaveric study using robotic technology. *Arthroscopy.* 2000;16(6):633-639.

24. Kondo E, Merican AM, Yasuda K, Amis AA. Biomechanical comparison of anatomic double-bundle, anatomic single-bundle, and nonanatomic single-bundle anterior cruciate ligament reconstruction. *Am J Sports Med.*2011;39(2):279-288.

25. Lane JG, Irby SE, Kaufman K, Rangger C, Daniel DM. The Anterior Cruciate Ligament in Controlling Axial Rotation An Evaluation of Its Effect. *Am J Sports Med.* 1994;22:289-293.

26. LaPrade RF, Resig S, Wentorf F, Lewis JL. The effects of grade III posterolateral knee complex injuries on anterior cruciate ligament graft force. A biomechanical analysis. *Am J Sports Med.* 1999;27(4):469-475.

27. Lipke JM, Janecki CJ, Nelson CL, et al. The role of incompetence of the anterior cruciate and lateral ligaments in anterolateral and anteromedial instability. A biomechanical study of cadaver knees. *The Journal of bone and joint surgery. American volume.* 1981;63:954-960.

28. Lobenhoffer P, Biedert R, Stauffer E, Lattermann C, Gerich TG, Muller W. Occurrence and distribution of free nerve endings in the distal iliotibial tract system of the knee. *Knee Surg Sports Traumatol Arthrosc.* 1996;4(2):111-115.

29. Losee R, Johnson T, Southwick W. Anterior subluxation of the lateral tibial plateau. A diagnostic test and operative repair. *J Bone Joint Surg Am.* 1978;60:1015-1030.

30. Mannel H, Marin F, Claes L, Dürselen L. Anterior cruciate ligament rupture translates the axes of motion within the knee. *Clinical Biomechanics.* 2004;19(2):130-135.

31. Markolf KL, Park S, Jackson SR, McAllister DR. Anterior-posterior and rotatory stability of single and double-bundle anterior cruciate ligament reconstructions. *J Bone Joint Surg Am.* 2009;91(1):107-118.

32. Matsumoto H. Mechanism of the pivot shift. *Journal of Bone & Joint Surgery, British Volume.* 1990;72-B:816-821.

33. Monaco E, Ferretti A, Labianca L, et al. Navigated knee kinematics after cutting of the ACL and its secondary restraint. *Knee Surg Sports Traumatol Arthrosc.* 2012;20:870-877.

34. Monaco E, Labianca L, Conteduca F, Carli AD, Ferretti A. Double bundle or single bundle plus extraarticular tenodesis in ACL reconstruction? *Knee Surg Sports Traumatol Arthrosc.* 2007;15:1168-1174.

35. Noyes FR, Grood ES, Butler DL, Paulos LE. Clinical biomechanics of the knee: ligament restraints and functional stability. In: AAOS symposium on the athlete's knee. CV Mosby, St Louis: 1980: 1-35.

36. *Anatomy of the knee*: ESSKA DVD; 2006.

37. Oh YK, Kreinbrink JL, Ashton-Miller JA, Wojtys EM. Effect of ACL Transection on Internal Tibial Rotation in an in Vitro Simulated Pivot Landing. *The Journal of Bone & Joint Surgery.* 2011;93:372-380.

38. Parsons EM, Gee AO, Spiekerman C, Cavanagh PR. The biomechanical function of the anterolateral ligament of the knee. *Am J Sports Med* 2015; Epub: doi 10.1177/0363546514562751.

39. Ristanis S, Stergiou N, Patras K, Tsepis E, Moraiti C, Georgoulis AD. Follow-up evaluation 2 years after ACL reconstruction with bone-patellar tendon-bone graft shows that excessive tibial rotation persists. *Clin J Sport Med.* 2006;16(2):111-116.

40. Robinson JR, Bull AM, Thomas RR, Amis AA. The role of the medial collateral ligament and posteromedial capsule in controlling knee laxity. *Am J Sports Med.* 2006;34(11):1815-1823.

41. Seebacher JR, Inglis AE, Marshall JL, Warren RF. The structure of the posterolateral aspect of the knee. *J Bone Joint Surg Am.* 1982;64(4):536-541.

42. Suero EM, Njoku IU, Voigt MR, Lin J, Koenig D, Pearle AD. The role of the iliotibial band during the pivot shift test. *Knee Surg Sports Traumatol Arthrosc.* 2013;21(9):2096-2100.

43. Tashman S, Collon D, Anderson K, Kolowich P, Anderst W. Abnormal rotational knee motion during running after anterior cruciate ligament reconstruction. *Am J Sports Med.* 2004;32(4):975-983.

44. Terry GC, Hughston JC, Norwood LA. The anatomy of the iliopatellar band and iliotibial tract. *Am J Sports Med.* 1986;14:39-45.

45. Terry GC, LaPrade RF. The biceps femoris muscle complex at the knee Its anatomy and injury patterns associated with acute anterolateral-anteromedial rotatory instability. *Am J Sports Med.* 1996;24(1):2-8.

46. Terry GC, Norwood LA, Hughston JC, Caldwell KM. How iliotibial tract injuries of the knee combine with acute anterior cruciate ligament tears to influence abnormal anterior tibial displacement. *Am J Sports Med.* 1993;21:55-60.

47. Vincent J-P, Magnussen RA, Gezmez F, et al. The anterolateral ligament of the human knee: an anatomic and histologic study. *Knee Surg Sports Traumatol Arthrosc.* 2012;20:147-152.

48. Wroble RR, Grood ES, Cummings JS, Henderson JM, Noyes FR. The role of the lateral extraarticular restraints in the anterior cruciate ligament-deficient knee. *Am J Sports Med.* 1993;21:257-263.

49. Yamamoto Y, Hsu WH, Fisk JA, Van Scyoc AH, Miura K, Woo SL. Effect of the iliotibial band on knee biomechanics during a simulated pivot shift test. *J Orthop Res.* 2006;24(5):967-973.

50. Zantop T, Herbort M, Raschke MJ, Fu FH, Petersen W. The role of the anteromedial and posterolateral bundles of the anterior cruciate ligament in anterior tibial translation and internal rotation. *Am J Sports Med.* 2007;35(2):223-227.

51. Zantop T, Schumacher T, Diermann N, Schanz S, Raschke MJ, Petersen W. Anterolateral rotational knee instability: role of posterolateral structures. *Arch Orthop Trauma Surg.* 2007;127:743-752.

Figures:



Figure 5 Set-up of robotic test system, with femur on fixed mounting and tibia attached to the end of the robot arm.

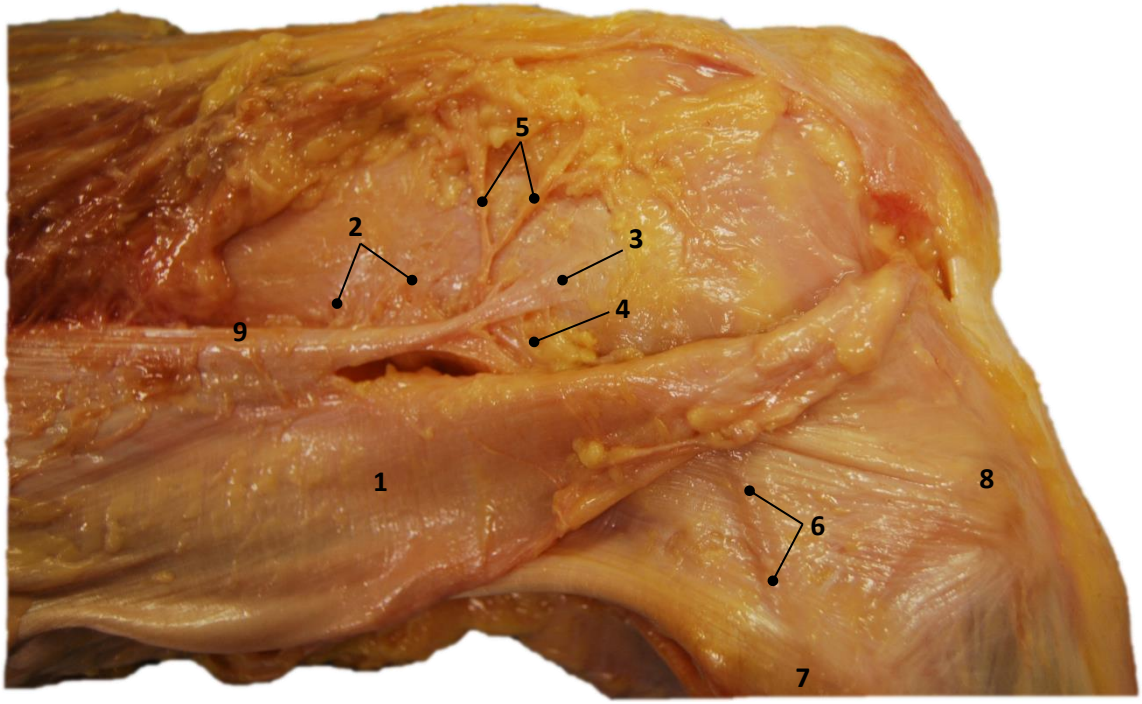

Figure 1. Lateral aspect of a right knee. Superficial layer of the iliotibial tract (ITT) flapped down (1), proximal femoral insertion of the ITT (2), supracondylar insertion of the ITT (3), retrograde insertion or capsulo-osseus layer (4), superior genicular artery (5), lateral collateral ligament (6), fibular head (7), Gerdy's tubercle (8), intermuscular septum (9).

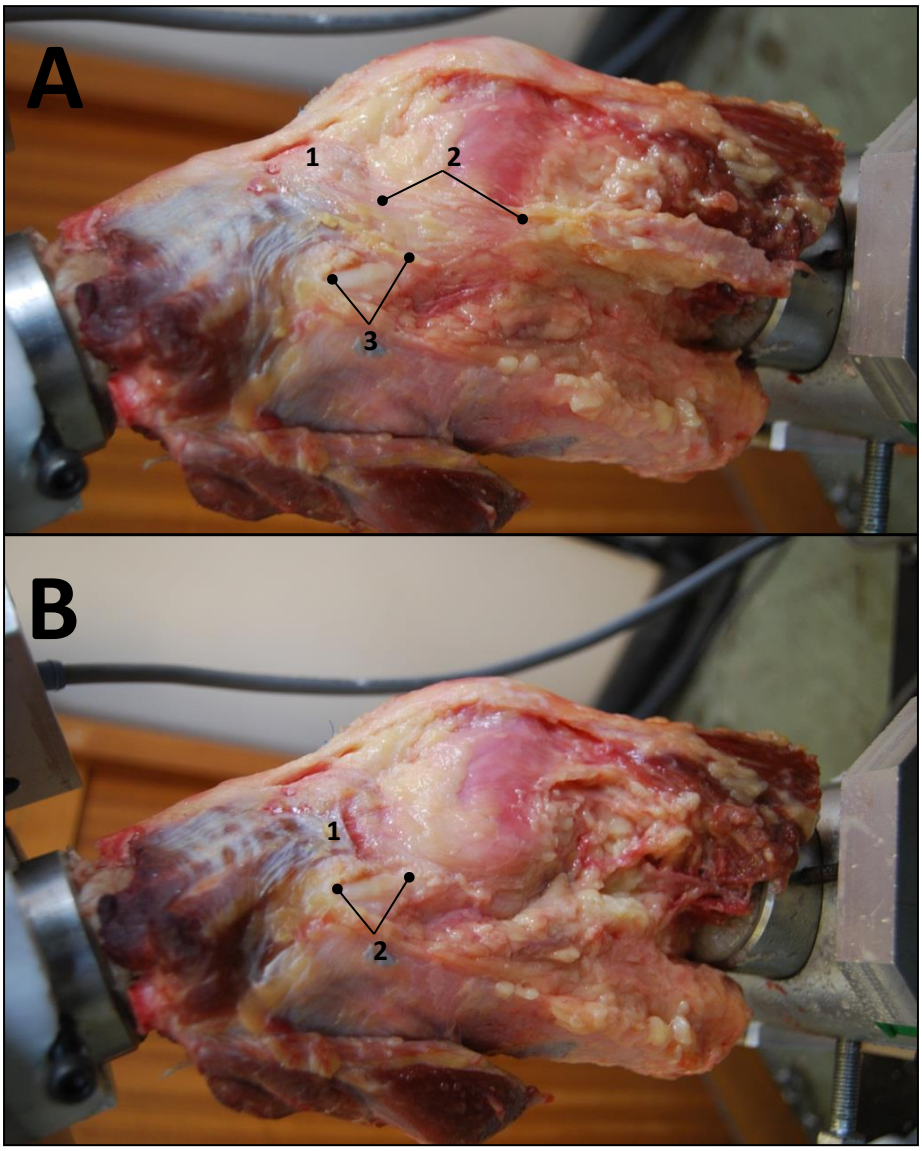

Figure 2. Lateral aspect of a left knee. **A**, superficial layer of the iliotibial tract (ITT) and biceps femoris muscle complex removed. Gerdy's tubercle (1), capsulo-osseus layer of the ITT (2) inserting posterior to Gerdy's tubercle, lateral collateral ligament (LCL) (3). **B**, insertion site of the resected capsulo-osseus layer of the ITT (1), LCL (2).

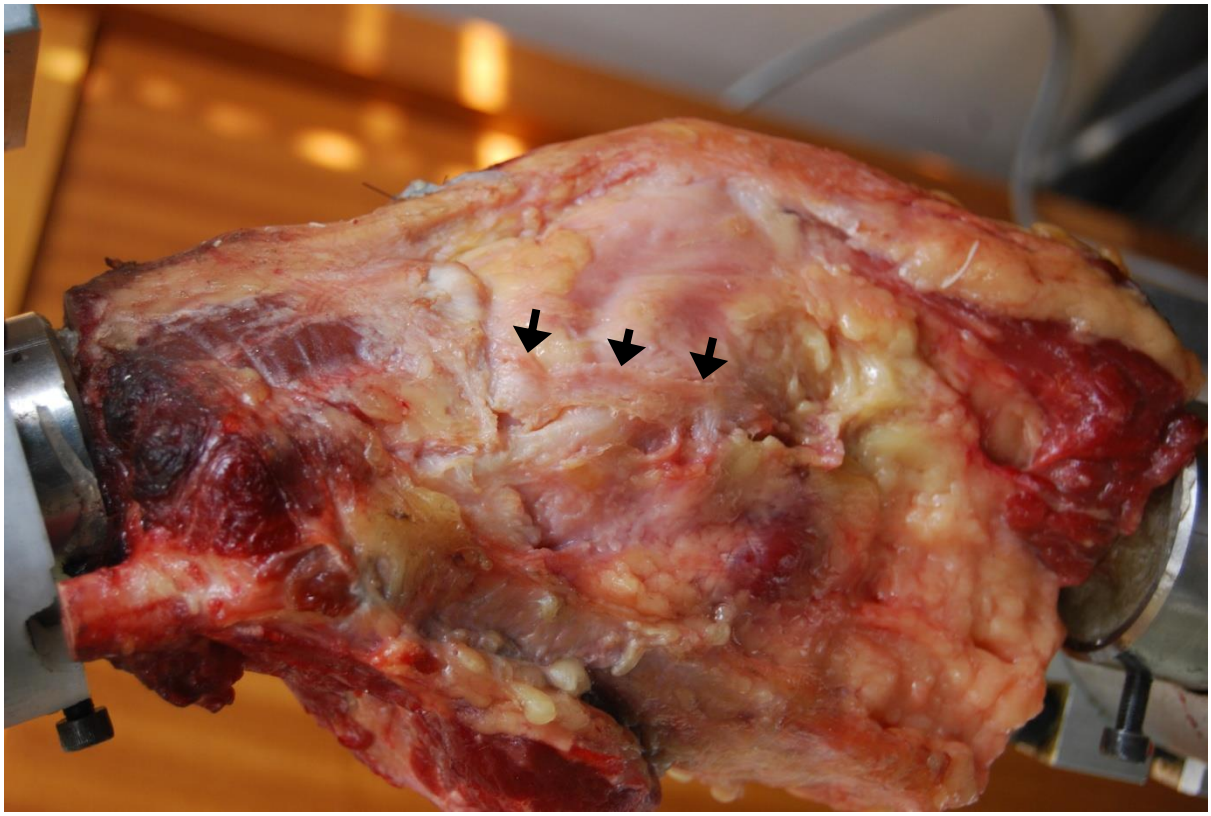

Fig 3: lateral aspect of left knee after removal of deep capsule-osseous layer of ITT, leaving the extracapsular ALL exposed (arrows), passing over the proximal LCL. The femoral attachment is proximal and posterior to the epicondyle; the tibial attachment is midway between Gerdy's tubercle and the head of the fibula.

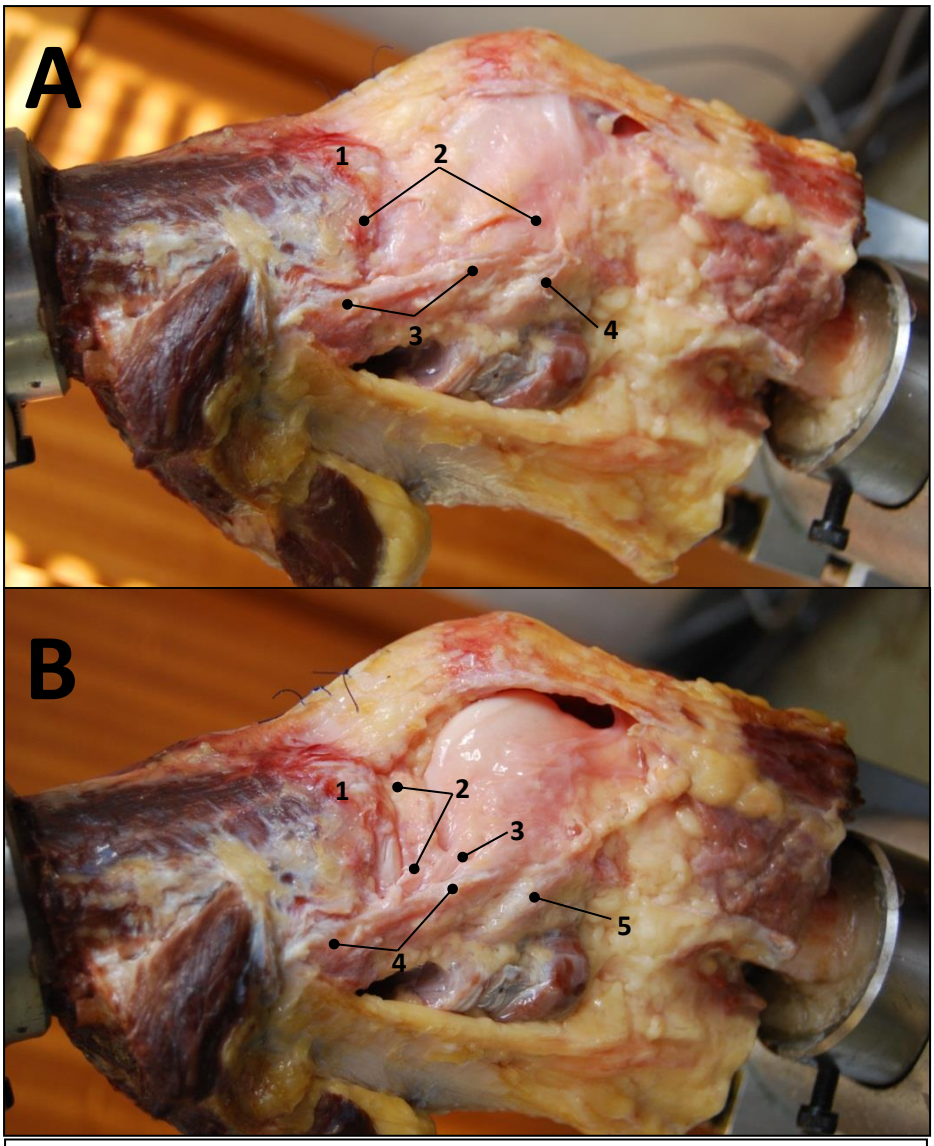

Figure 4. lateral aspect of a left knee. A, All structures running superficial to the lateral collateral ligament (LCL) were removed. Gerdy's tubercle (1), anterolateral capsule (2), LCL (3), femoral attachment of the lateral head of the gastrocnemius muscle (4). B, After removal of the anterolateral capsule, Gerdy's tubercle (1), lateral meniscus (2), popliteus tendon (3), LCL (4), femoral attachment of the lateral head of the gastrocnemius muscle (5).

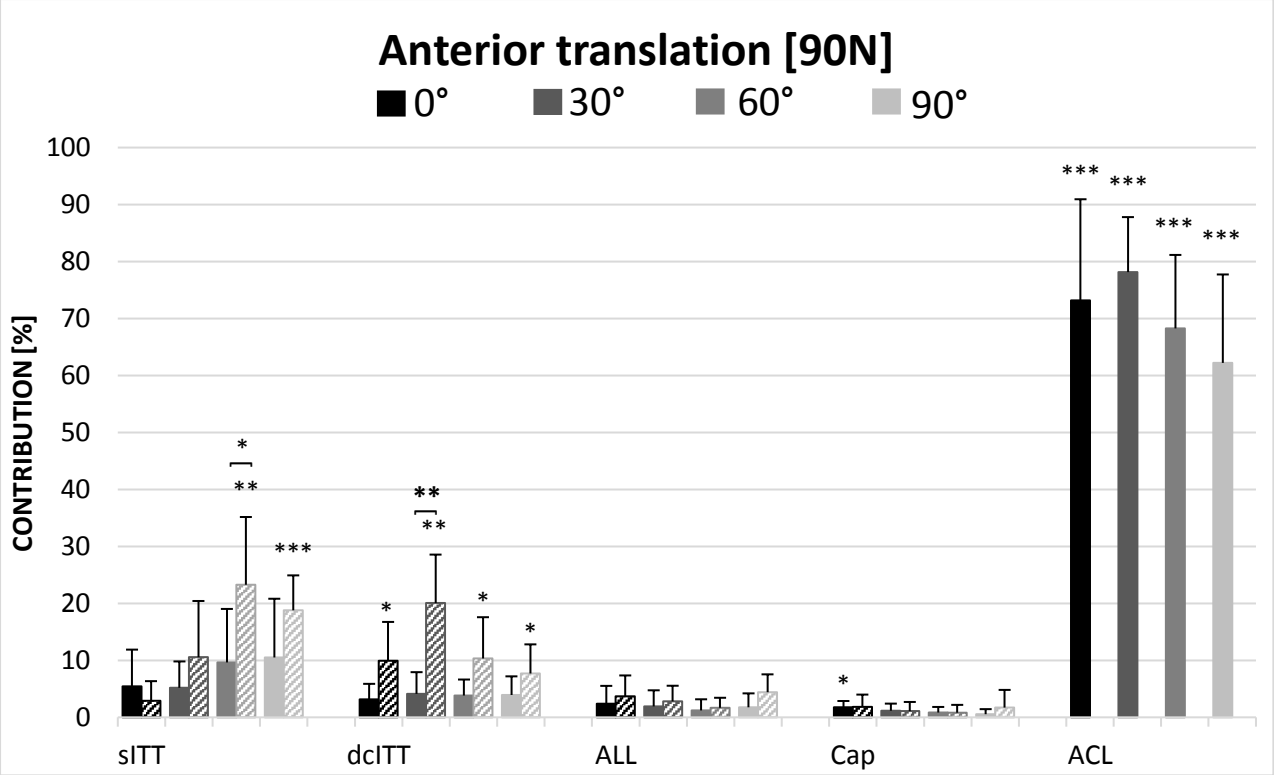

Figure 6. Contribution [%] of tested structures in restraining a 90N anterior tibial translation at 0°, 30°, 60°, and 90°. Cross-hatched areas indicate results from the ACL-deficient group. sITT=superficial layer of the iliotibial tract; dcITT= deep and capsulo-osseus layer of the iliotibial tract; ALL= anterolateral ligament; Cap= anterolateral capsule; ACL= anterior cruciate ligament. Statistical significance: *p<.05; **p<.01; *** p<.001. (Shown as mean + SD, n=8)

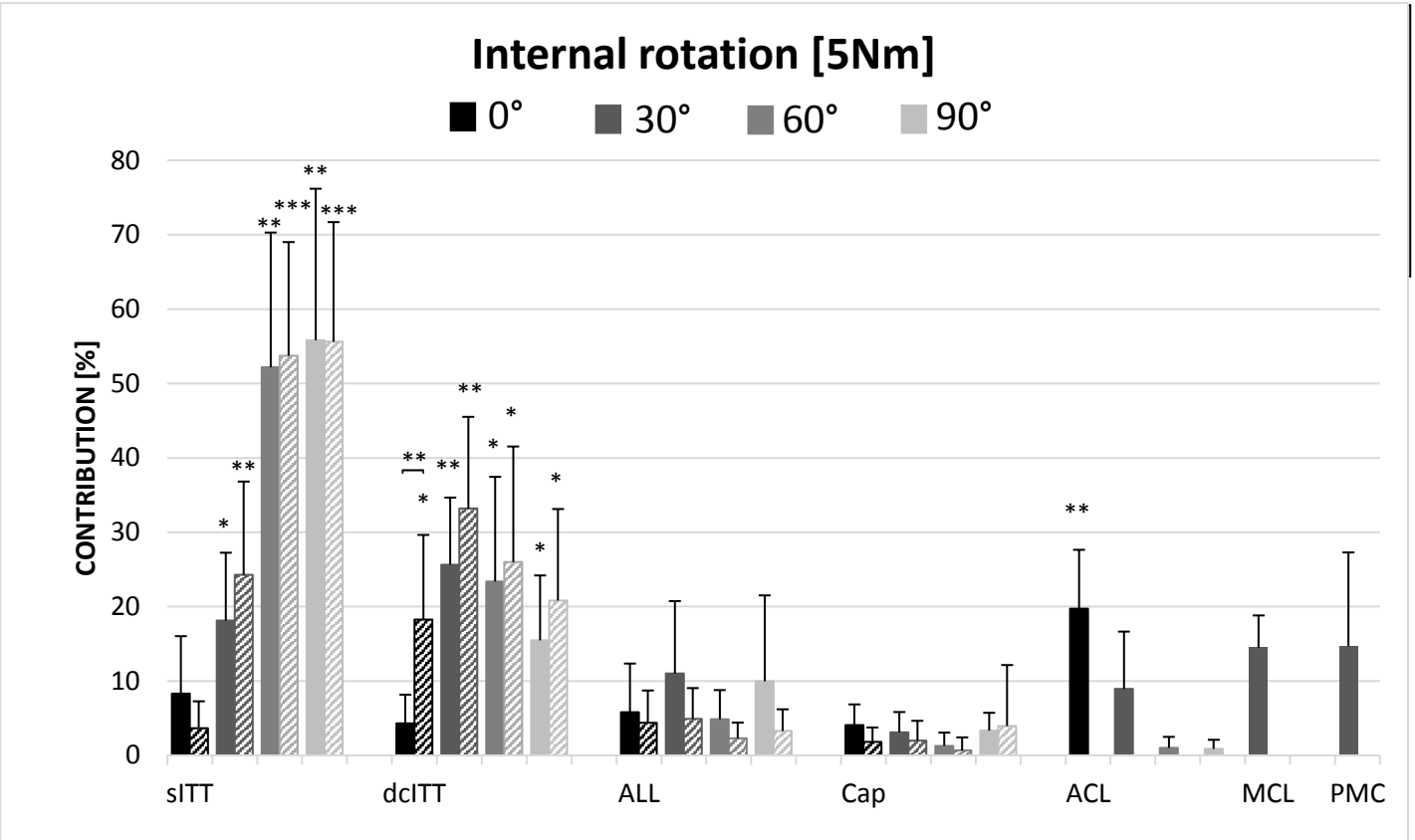
Internal rotation [5Nm]
0°
30°
60°
90°
CONTRIBUTION [%]
80
70
60
50
40
30
20
10
0
sITT
dcITT
ALL
Cap
ACL
MCL
PMC

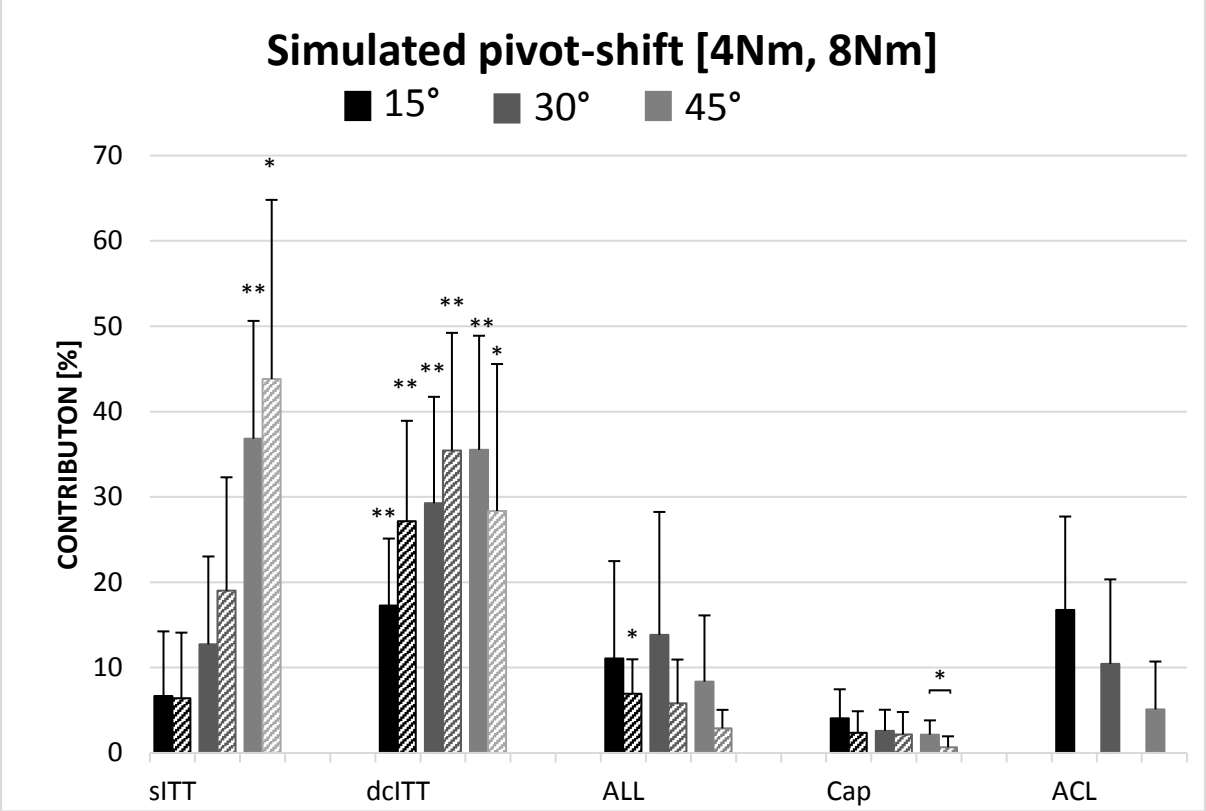

Figure 8. Contribution [%] of tested structures in restraining a 4Nm internal rotation torque in response to a simulated pivot shift test (4Nm internal rotation and 8Nm valgus rotation) at 15°, 30°, and 45°. Cross-hatched areas indicate results from ACL-deficient group. sITT=superficial layer of the iliotibial tract; dcITT= deep and capsulo-osseus layer of the iliotibial tract; ALL= anterolateral ligament; Cap= anterolateral capsule; ACL= anterior cruciate ligament. Statistical significance: *p<.05; **p<.01; *** p<.001. (Shown as mean + SD, n=8)