

CellMek SPS
Sample Preparation System

UNLOCK THE POWER OF LEAN

The CellMek SPS system helps you unlock the power of lean by addressing major process wastes related to sample preparation in your clinical flow cytometry laboratory. Drives Efficiency via Automation. Standardizes Processes & Reduces Potential for Error. Ensures Flexibility Via User-Defined Protocols. Provides Confidence in Results facilitated by a full audit trail. Frees up lab staff to deal with more value-added tasks.

beckman.com/cellmek-sps

The CellMek SPS System is CE marked and FDA listed (Class I exempt) and is available in countries that accept the CE mark as the basis for their country-specific registration.

© 2022 Beckman Coulter, Inc. All rights reserved. Beckman Coulter, the stylized logo, and the Beckman Coulter product and service marks mentioned herein are trademarks or registered trademarks of Beckman Coulter, Inc. in the United States and other countries. All other product names and brands are properties of their respective owners.

BECKMAN COULTER
Life Sciences

For Beckman Coulter's worldwide office locations and phone numbers, please visit Contact Us at beckman.com

22.01.3740 FLOW

Check for updates

Received: 24 June 2022 | Accepted: 5 July 2022
DOI: 10.1002/ajh.26655

CLINICAL PEARLS IN BLOOD DISEASES

MORPHOLOGY UPDATE

Peripheral CD5+ CD10+ B-cell proliferation with atypical morphology attributable to human herpesvirus 6 infection following umbilical cord blood transplantation

Alban Canali[1] | Jean-Baptiste Rieu[1] | Barbara J. Bain[2]

[1]Haematology Laboratory, Cancer University Institute of Toulouse – Oncopole, Toulouse, France

[2]Centre for Haematology, St Mary's Hospital Campus of Imperial College Faculty of Medicine, St Mary's Hospital, London, UK

Correspondence
Barbara J. Bain, Department of Blood Sciences, St Mary's Hospital, Praed Street, London W2 1NY, UK.
Email: b.bain@imperial.ac.uk

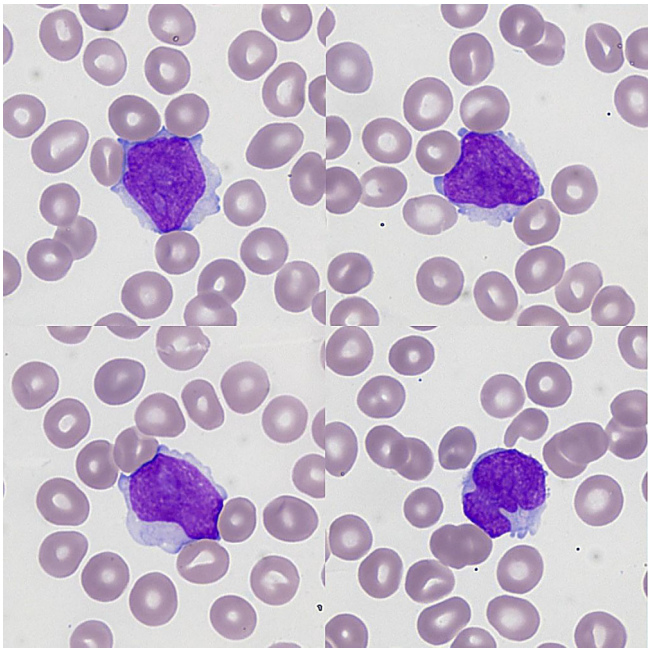

A 21-year-old man was under follow-up after a second hematopoietic stem cell transplant with umbilical cord blood (UCBT) for relapsed acute myeloid leukemia. One month after UCBT, he was in complete remission with incomplete count recovery (CRi, hemoglobin concentration 85 g/L, platelets 13×10^9/L, and neutrophils 1.2×10^9/L). Donor chimerism was 100%. Eleven days later, a sudden increase in the lymphocyte count from 0.5 to 2.1×10^9/L was observed concomitantly with human herpesvirus 6 (HHV6) reactivation with a peripheral blood viral load at log 3.32 copies/mL. Examination of the blood film revealed 41% large atypical lymphocytes with a high nucleocytoplasmic ratio, irregular nucleus, decondensed chromatin with indistinct nucleoli, and weakly basophilic cytoplasm with irregular protrusions (images May-Grünwald-Giemsa, ×100 objective). Flow cytometric immunophenotyping showed polyclonal CD19+ B cells (87% of lymphocytes) with a particular CD5+ CD10+ CD24+ CD38+ CD27− profile indicative of regulatory B-cell (Breg) proliferation. The absence of CD27 in this population showed that it was probably derived from the UCBT.[1] Since the general condition of the patient was good (WHO performance status 1) and physical examination was normal, no antiviral treatment was required. One hundred days after UCBT, he was still in CRi but with an improvement in the platelet count (46×10^9/L). Breg lymphocytosis was still present and was fluctuating as was the HHV6 viral load.

HHV6 infection is well documented in adult patients following UCBT.[2] A higher prevalence of Breg in human cord blood compared to peripheral adult blood has also been demonstrated.[1] Here we describe the cytological and immunophenotypic features of Breg lymphocytes in the peripheral blood of an adult patient with HHV6 infection following UCBT. It is important that these reactive cells are not confused with neoplastic cells.

CONFLICT OF INTEREST

The authors declare no conflict of interest.

This is an open access article under the terms of the Creative Commons Attribution-NonCommercial-NoDerivs License, which permits use and distribution in any medium, provided the original work is properly cited, the use is non-commercial and no modifications or adaptations are made.
© 2022 The Authors. *American Journal of Hematology* published by Wiley Periodicals LLC.

10968652, 2022, 11, Downloaded from https://onlinelibrary.wiley.com/doi/10.1002/ajh.26655 by Imperial College London, Wiley Online Library on [06/12/2022]. See the Terms and Conditions (https://onlinelibrary.wiley.com/terms-and-conditions) on Wiley Online Library for rules of use; OA articles are governed by the applicable Creative Commons License

ORCID

Alban Canali https://orcid.org/0000-0002-1609-3307
Jean-Baptiste Rieu https://orcid.org/0000-0002-0950-979X
Barbara J. Bain https://orcid.org/0000-0003-3077-4579

REFERENCES

1. Esteve-Solé A, Teixidó I, Deyà-Martínez A, et al. Characterization of the highly prevalent regulatory $CD24^{hi}CD38^{hi}$ B-cell population in human cord blood. *Front Immunol*. 2017;8:201.
2. Chevallier P, Hebia-Fellah I, Planche L, et al. Human herpes virus 6 infection is a hallmark of cord blood transplant in adults and may participate to delayed engraftment: a comparison with matched unrelated donors as stem cell source. *Bone Marrow Transplant*. 2010;45:1204-1211.

How to cite this article: Canali A, Rieu J-B, Bain BJ. Peripheral CD5+ CD10+ B-cell proliferation with atypical morphology attributable to human herpesvirus 6 infection following umbilical cord blood transplantation. *Am J Hematol*. 2022; 97(11):1489-1490. doi:10.1002/ajh.26655

10968652, 2022, 11, Downloaded from https://onlinelibrary.wiley.com/doi/10.1002/ajh.26655 by Imperial College London, Wiley Online Library on [06/12/2022]. See the Terms and Conditions (https://onlinelibrary.wiley.com/terms-and-conditions) on Wiley Online Library for rules of use; OA articles are governed by the applicable Creative Commons License