



## Diplopia and eye movement disorders

C Danchaivijitr and C Kennard

*J. Neurol. Neurosurg. Psychiatry* 2004;75;24-31  
doi:10.1136/jnp.2004.053413

---

Updated information and services can be found at:  
[http://jnp.bmj.com/cgi/content/full/75/suppl\\_4/iv24](http://jnp.bmj.com/cgi/content/full/75/suppl_4/iv24)

---

*These include:*

### References

This article cites 4 articles, 3 of which can be accessed free at:  
[http://jnp.bmj.com/cgi/content/full/75/suppl\\_4/iv24#BIBL](http://jnp.bmj.com/cgi/content/full/75/suppl_4/iv24#BIBL)

1 online articles that cite this article can be accessed at:  
[http://jnp.bmj.com/cgi/content/full/75/suppl\\_4/iv24#otherarticles](http://jnp.bmj.com/cgi/content/full/75/suppl_4/iv24#otherarticles)

### Rapid responses

You can respond to this article at:  
[http://jnp.bmj.com/cgi/eletter-submit/75/suppl\\_4/iv24](http://jnp.bmj.com/cgi/eletter-submit/75/suppl_4/iv24)

### Email alerting service

Receive free email alerts when new articles cite this article - sign up in the box at the top right corner of the article

---

### Topic collections

Articles on similar topics can be found in the following collections

[Neurology in Practice](#) (150 articles)  
[Other Neurology](#) (3657 articles)

---

### Notes

---

To order reprints of this article go to:  
<http://www.bmjournals.com/cgi/reprintform>

To subscribe to *Journal of Neurology, Neurosurgery, and Psychiatry* go to:  
<http://www.bmjournals.com/subscriptions/>

# DIPLOPIA AND EYE MOVEMENT DISORDERS

C Danchaiwitt, C Kennard

iv24

*J Neurol Neurosurg Psychiatry* 2004;75(Suppl IV):iv24–iv31. doi: 10.1136/jnp.2004.053413

**D**iplopia—seeing double—is a symptom with many potential causes, both neurological and ophthalmological. Accurate diagnosis and appropriate plans of management can be achieved with careful history taking and clinical examination. In this article we review the practical points for clinicians dealing with diplopia. The general approach is demonstrated in fig 1.

A diagnosis of functional diplopia should not be entertained based simply on the absence of gross ocular misalignment, because sometimes very subtle misalignment of the ocular axes, which are difficult to elucidate at the bedside, may require more sensitive tests. On the other hand, one should not be surprised to see gross ocular misalignment without diplopia as brain plasticity usually takes over if diplopia is longstanding and the image from one eye is suppressed.

## HISTORY TAKING

Careful history taking has an important role in the management of diplopia and details of the history can be used to focus examination on areas of relevance. The following points in the history should be elucidated.

### Is the diplopia monocular or binocular?

Whether the diplopia is monocular or binocular should be determined first. Should the symptom of diplopia persist with one eye occluded, the patient has monocular diplopia, the causes of which are usually ophthalmological with refractive error being the most common (table 1). Binocular diplopia resolves when one eye is occluded and it is caused by “misalignment of the visual axes”, and can be due to many different aetiologies.

It is very important to distinguish monocular from binocular diplopia because their possible causes differ significantly. Monocular diplopia is usually caused by intraocular pathology, therefore detailed ophthalmological assessment is required. The characteristics of the images may help to localise the problem. For example, a combination of glare and impaired visual acuity can be seen in monocular diplopia caused by cataract. Patients with macular disease causing monocular diplopia may also describe “bent” or “warped” images. Rarely, monocular diplopia may be seen in disorders of the primary or secondary visual cortex, especially when they are bilateral or the patient sees more than two images (cerebral polyopia). This group of patients may also describe palinopsia—multiple images appearing in the visual scene soon after gaze has been turned away from an object or after it has been removed from view.

### Alignment of the images and the direction that results in the most separation

Questions should be asked to identify if the diplopia is horizontal, vertical, or oblique. Horizontal diplopia, without vertical separation, is related to the impaired neural control or function of the medial rectus muscle, the lateral rectus muscle, or both. The direction of gaze that increases the separation of the images can be helpful in determining which extraocular muscle is involved. The images are maximally separated when the direction of gaze is in the region of action of the paretic muscle. For example, left trochlear nerve palsy causes most image separation on right and downward gaze. Horizontal diplopia that occurs almost exclusively at near distance is strongly suggestive of convergence insufficiency.

Oblique separation with one image slightly tilted is indicative of either superior or inferior oblique muscle dysfunction. Pronounced image tilting (90° or 180°) may be seen in lateral medullary syndrome. Aniseikonia, a condition caused by notable discrepancy of the refractive errors between two eyes, gives rise to diplopia because one image is smaller than the other and superimposed.

### Onset and progression of the symptoms

The onset of diplopia by its very nature is almost always sudden. Therefore, an abrupt onset of diplopia does not necessarily imply a vascular cause. Progression and the temporal sequence of symptoms provide much useful information. Diplopia that reaches the maximum image separation instantly and improves spontaneously is usually caused by a single event, often

See end of article for authors' affiliations

Correspondence to:  
Professor Christopher  
Kennard, Department of  
Visual Neuroscience, Division  
of Neuroscience and  
Psychological Medicine,  
Imperial College London,  
Charing Cross Campus, St  
Dunstan's Road, London W6  
8RP, UK; c.kennard@imperial.  
ac.uk

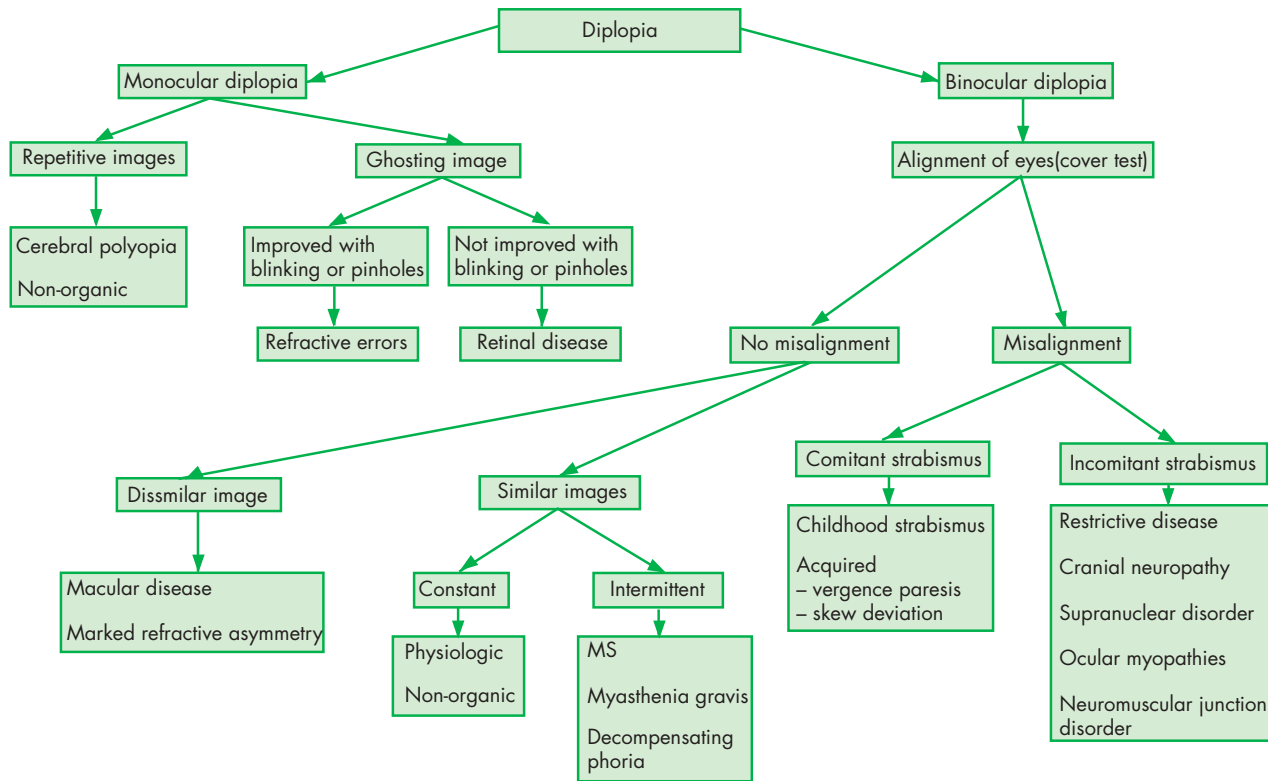


Figure 1 General approach to diplopia.

presumed to be vascular. On the other hand, progression or change of the pattern of diplopia usually indicates ongoing pathology such as a compressive lesion. Intermittent diplopia with associated ptosis and diurnal variation is suggestive of a neuromuscular junction disorder, such as myasthenia gravis.

**Exacerbating and relieving factors**

Blinking can improve monocular diplopia from corneal astigmatism or simply dry eyes, whereas it has no effect on cataract or macular diseases. Myasthenia gravis should be considered if diplopia is aggravated by intensive use of the eyes, has a tendency to worsen towards the end of the day, and is improved with rest.

**Associated symptoms**

Periorbital pain or pain on eye movements may be indicative of inflammatory causes. In the absence of obvious ptosis, a history of intermittent ptosis should be identified. Visual loss from optic neuropathy is usually seen in an orbital apex lesion. However, poor vision does not necessarily indicate optic nerve involvement because a pure oculomotor nerve

palsy can also result in a loss of the accommodative reflex and therefore poor near vision, which should improve with a pinhole. Weakness of proximal limb muscles may indicate the possibility of a mitochondrial myopathy, congenital myopathy, or myasthenia gravis.

**Past medical history and family history**

A significant past medical history, especially of childhood strabismus, treatment with prisms, or eye occlusion therapy and ocular surgery, should be identified. A diagnosis of ocular nerve palsy from a vascular cause may be supported by significant vascular risk factors such as hypertension and diabetes mellitus.

**EXAMINATION FOR DIPLOPIA**

Complete ophthalmological and orthoptic assessment should be carried out in a case of monocular diplopia. Detailed examination of refraction and the ocular media including cornea, lens, and retina is mandatory. Refractive error or lens disease should be suspected in monocular diplopia if it is resolved when testing with a pinhole.

Binocular diplopia requires the clinician to determine the cause of “ocular misalignment”, which can be either gross or subtle. The cause can be as obvious as “displacement of the eye”, resulting from exophthalmos or enophthalmos, secondary to a space occupying lesion behind the globe and an orbital wall defect, respectively. However, the most common causes of misalignment of the visual axes are extraocular muscle dysfunction and this should be addressed in detail.

**Identifying the paretic muscle(s)**

Eye movement examination can be started by observing the eyes in the primary position while the patient looks at a light source such that its reflection is located at the centre of both

Table 1 Causes of monocular diplopia	
▶	Refractive error
▶	Corneal disease (for example, irregular astigmatism)
▶	Iris injury
▶	Cataract
▶	Media opacity
▶	Macular disease
▶	Primary or secondary visual cortex disorder (usually bilateral monocular diplopia)

pupils. If the light reflection is not in the centre, heterotropia is present. However, this test is not very sensitive as it requires  $7^\circ$  of ocular deviation to cause 1 mm of shift of the reflection from the centre. The cover–uncover test, in which each eye is covered and then uncovered in turn, is more sensitive and should be able to demonstrate the deviated eye by observing refixation immediately after being uncovered. If the uncovered eye moves to take up fixation, it can be assumed that under binocular viewing conditions the eye was not aligned with fixation, and a manifest deviation was present (a tropia). Inward movement of the uncovered eye indicates an exotropia, and an outward movement an esotropia. A vertical deviation may be either a hypotropia or a hypertropia, depending on whether the eye moves up or down respectively. The examiner should determine whether the tropia is comitant or non-comitant by seeing if the magnitude of the deviation varies with the position of the eye, by which the variation is not seen in the former but present in the latter. The test is then repeated, and the same observations made while covering the other eye. The alternate cover test is more dissociating than the cover–uncover test and it may demonstrate subtle heterotropia more readily. If no tropia is present and the uncovered eye shows refixation during the alternate cover test, the patient has a latent deviation (a phoria). It is conventional that if there is a vertical deviation of the eyes, the higher of the two is referred to as hypertropic/hyperphoric, regardless of which eye is at fault.

The range of eye movements is examined by asking the patient to follow a target, placed 50 cm away in order to avoid convergence, and the patient should be asked to report any diplopia during the examination. It is conventional to record cardinal eye positions in an H fashion from the patient's perspective (fig 2). This method helps identify the paretic muscle more clearly as each direction corresponds with the main action of a particular extraocular muscle. Subjective diplopia in the absence of visible ocular motility restriction should be further tested by occluding each eye in turn, and the general rule is that the outer image comes from the paretic eye. For example, if the patient reports diplopia in left gaze and the outer image disappears with right eye occluded, the patient has a right medial rectus palsy.

Parks three-step test has been commonly used for identifying the paretic muscle in vertical diplopia. The steps are as follows:

- ▶ To determine which eye is hypertropic in the primary position. Example: If the right eye is hypertropic, one of four muscles must be paretic; right eye depressors (right superior oblique and right inferior rectus) or left eye elevators (left inferior oblique and left superior rectus).
- ▶ To determine whether the hypertropia increases in right or left horizontal gaze. Example: If the hypertropia is worse

on left gaze, the affected muscles have now been limited to two muscles; right superior oblique and left superior rectus muscles.

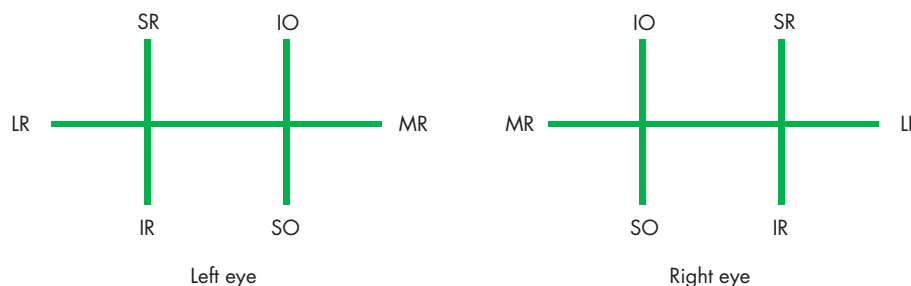- ▶ To determine whether the hypertropia is worse on head tilting to left or right (Bielschowsky test). Example: If the hypertropia is worse on head tilting to the right, only one possible paretic muscle remains; right superior oblique muscle. However, this step does not always show the difference and other clues should be used if this step is negative.

Although the range of eye movements on examination yields most information in identifying the paretic muscle, clues from general examination helps to confirm the abnormalities of eye movement and localise the disease process.

Self manipulation of head posture is one of the most effective ways to minimise diplopia. This strategy is commonly used by patients with both acute and chronic diplopia. The head is usually turned or tilted to the position where the action of the paretic muscle is least required. Rarely, patients with longstanding diplopia might adopt the head posture that makes the images most separated in order to suppress one image more easily. Certain head postures may be helpful, such as head tilting to the opposite side of a trochlear nerve palsy and the face turning towards the side of an oculomotor nerve palsy.

Evidence for exophthalmos should be examined by observing the eyes from above the patient's head. The supraorbital ridges can be used as a reference point. The Hertel exophthalmometer gives more precise readings which can be used both for diagnosis and follow up. A difference greater than 2 mm between the eyes is almost always pathological. Visual field testing should be undertaken routinely because the pattern of any field defect may assist in localisation. For example, bitemporal hemianopia may also cause diplopia due to the patient's inability to fuse the image on the nasal field from one eye to the image on the temporal field of the other eye (hemifield slip).

Eyelid function should also be examined and recorded with the face unturned and untilted. The normal upper eyelid position should be just below the top of the iris and ptosis is therefore present if the upper eyelid is below this point. Complete ptosis is seen only in oculomotor nerve palsy whereas partial ptosis can be seen in either oculomotor nerve palsy or Horner's syndrome. Pupil examination helps to discriminate these two conditions where a mydriatic pupil is seen in the former and a meiotic pupil in the latter. A combination of ptosis, weakness of eyelid closure, and restricted eye movements is strongly suggestive of a myopathic cause such as chronic progressive external ophthalmoplegia (CPEO). Lid lag—a condition where the eyelid lags behind the eye on downward pursuit movement—is indicative of



**Figure 2** Conventional clinical recording of ocular motility. Each direction corresponds with the main action of each particular extraocular muscle. It is drawn from the patient's perspective. MR, medial rectus; LR, lateral rectus; SR, superior rectus; IR, inferior rectus; SO, superior oblique; IO, inferior oblique.

thyroid eye disease. Lid retraction is not specific to thyroid ophthalmopathy because it can also be seen in dorsal midbrain syndrome and sympathetic overactivity.

Myasthenia gravis should be considered if the ocular motility restriction does not follow the distribution of any particular ocular motor nerve. Fatigability of eye movements and eyelids, a typical finding in myasthenia gravis, should be sought by asking the patient to sustain upward gaze for at least 1–2 minutes. In addition, fatigability of eye movements can be demonstrated by examining repetitive saccades or sustained gaze in various directions. Myopathic disorders rarely cause diplopia because the progression is usually very slow, but should be considered when eye movement restriction is bilateral, accompanied by ptosis and weakness of eyelid closure, and especially when there is a history of family members affected in a similar manner.

#### **Is the diplopia caused by mechanical restriction or a neurogenic paresis?**

It is important to determine whether the restricted eye movement is caused by weakness of the agonist muscle or a mechanical restriction of the antagonist muscle. For example, Brown's syndrome (superior oblique tendon sheath syndrome), which causes tethering of the superior oblique muscle, has a similar eye movement pattern to an inferior oblique paresis. Observation of the eye movement velocity can help differentiate between these two categories. In neurogenic paresis, as the eyes move into the direction of the defect, the underacting eye will move smoothly but progressively slower than the other eye. In contrast, eye movements will be smooth and symmetrical in mechanical restriction until the eye meets the point of obstruction, which causes abrupt slowing. When it is uncertain the forced duction test can be performed to distinguish between these two conditions. A full range of eye movements is observed in neurogenic paresis but not in mechanical restriction.

#### **Is the diplopia caused by a peripheral or a central neurogenic paresis?**

In general, diplopia secondary to brainstem lesions is usually accompanied by other neurological symptoms including hemiparesis, abnormal movement, and cerebellar signs. However, a single ocular nerve palsy in the absence of other neurological signs is usually peripheral, but the advent of magnetic resonance image (MRI) scanning has identified a focal central lesion as a not uncommon cause. Ocular motility restriction may be seen in supranuclear gaze disorders, but the patients rarely complain of diplopia because supranuclear gaze palsy is usually conjugate without misalignments. A supranuclear gaze palsy can be confirmed by the oculocephalic reflex whereby the reduced range of movement can be overcome by this procedure.

### **ISOLATED OCULAR NERVE PALSIES**

#### **Oculomotor nerve palsy (CN III)**

A complete oculomotor nerve palsy is easily recognised by a combination of ptosis, a fixed dilated pupil, and the affected eye in a "down and out" position, although partial oculomotor nerve palsies are more common. Pupil sparing CNIII palsy is often thought to be secondary to vascular microinfarction seen in patients with multiple vascular risk factors. However, this is true only when the ptosis is complete, and the pupil is completely spared. In any other circumstance brain imaging should be requested to exclude

the possibilities of a compressive lesion, especially a posterior communicating artery aneurysm.

The oculomotor nerve divides into two subdivisions, the superior and inferior branches, in the superior orbital fissure. The superior branch supplies the superior rectus and the levator palpebrae superioris muscle. Although a combination of ptosis and ipsilateral superior rectus palsy is suggestive of a peripheral pathology that affects the superior branch of the oculomotor nerve, incomplete damage to the ipsilateral oculomotor nerve fascicle or nucleus may also lead to a similar set of signs. Therefore, MRI may be required to distinguish between the two.

#### **Trochlear nerve palsy (CN IV)**

Trochlear nerve palsy is the most common cause for vertical extraocular muscle weakness and vertical diplopia. However, other causes of an apparent superior oblique palsy such as myasthenia gravis and thyroid eye disease should be excluded before it can be attributed to a trochlear nerve lesion. It is sometimes problematic to test superior oblique function in the presence of an ipsilateral oculomotor nerve palsy, because adduction is required for the superior oblique to act as an eye depressor. However, it is possible to declare intact superior oblique function if in this situation the affected eye intorts on attempted downward gaze.

A rare disorder is superior oblique myokymia in which there are bursts of small amplitude, high frequency torsional oscillations of one eye. This results in symptoms of intermittent vertical or torsional diplopia, monocular blurring of vision, and tremulous sensations in the eye that usually last less than 10 seconds and occur many times per day. The oscillation can be very subtle and observation with an ophthalmoscope or slit lamp when the patient is looking "down and in" may be required. This condition is usually benign and sensitive to small doses of gabapentin or carbamazepine. If drug treatment fails, surgical procedures such as superior oblique tenectomy with myectomy of the ipsilateral inferior oblique muscle are available.

#### **Abducens nerve palsy (CN VI)**

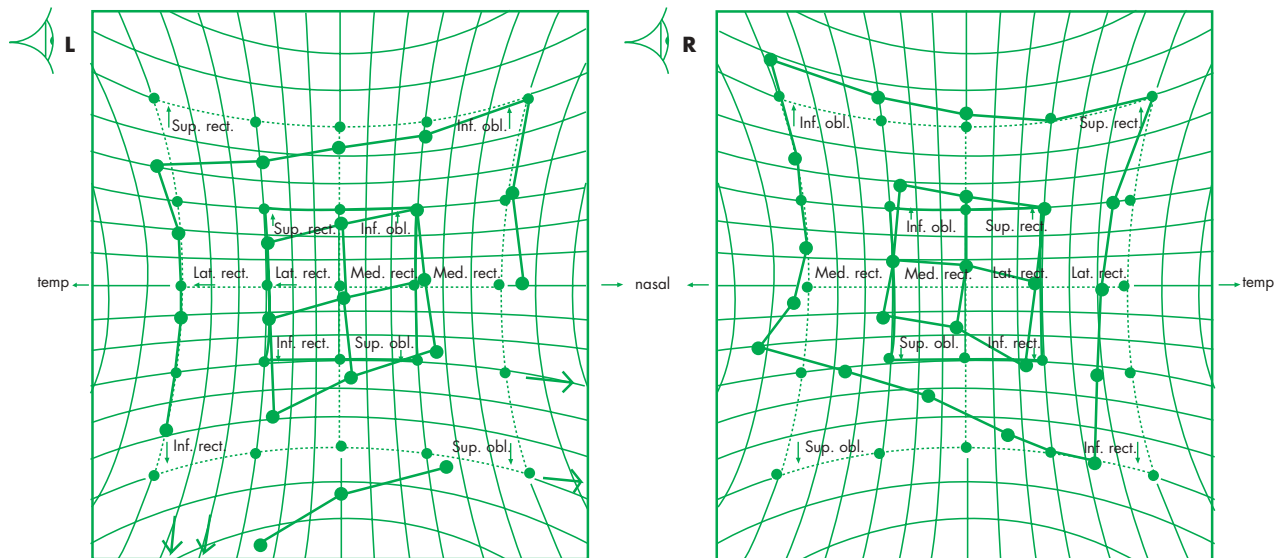
Abducens nerve palsy, which results in a lateral rectus muscle paresis and therefore horizontal diplopia, is the most common type of ocular nerve palsy, because the abducens nerve has the longest intracranial course and is therefore susceptible to direct and indirect insults. Although isolated abducens nerve palsy can be secondary to pathology of the nerve itself, such as microvascular infarction or direct compression, transient dysfunction caused by raised intracranial pressure from various aetiologies is also a possibility when it becomes a false localising sign.

#### **Combined ocular motor nerve palsies**

It is important to distinguish multiple ocular motor palsies from orbital or neuromuscular diseases such as dysthyroid eye disease, myasthenia gravis, and myopathic syndromes. This can usually be achieved by careful consideration of the progression and associated signs. Unilateral multiple ocular motor nerve palsies are usually associated with lesions involving the cavernous sinus, superior orbital fissure, or orbital apex. Differentiation between lesions at these sites is suggested by sensory disturbances in the first and sometimes second divisions of the trigeminal nerve, sensory loss in the first division only, and proptosis with visual loss, respectively. In the cavernous sinus syndrome, it is not uncommon to find



iv28



**Figure 3** Hess chart plotted from the patient's perspective. Range of eye movement is smaller in the right eye, therefore, it is a parietic eye. The diagnosis is right superior oblique palsy.

that the pupil size is relatively unaffected despite significant dysfunction of the oculomotor nerve. It has been suggested that this is caused by coincident parasympathetic (via oculomotor nerve) and sympathetic (via internal carotid artery) nerve paresis. Pathology in the cavernous sinus syndrome varies widely from cavernous sinus thrombosis (complication of infectious and non-infectious processes), infection (mycobacteria, fungus), tumour (meningioma, lymphoma), and granulomatous inflammation (Tolosa-Hunt syndrome). Cavernous sinus syndrome often requires extensive investigations, especially high resolution brain imaging with contrast enhancement that should include both orbits and cavernous sinuses, in addition to the brain.

### INVESTIGATION

The investigation of an adult usually consists of assessment of their eye position and movement. The Hess chart is commonly used to provide a pictorial and reproducible record of the patients' eye movements (fig 3). The patient is seated facing the screen being plotted, with the head centred on the fixation spot. Each eye is plotted in turn for the central fixation spot and targets at 15° and 30° eccentricity, respectively. Some general rules for interpreting a Hess chart are as follows:

- ▶ The smaller field belongs to the parietic eye
- ▶ Neurogenic pareses will show the largest underaction in the direction of parietic muscle and the largest over-action is seen in the contralateral synergist
- ▶ Mechanical defects show a compressed field without obvious over-action.

The advent of clinical imaging, the computed tomographic (CT) and MRI scan, opened a new era in clinical neurology and also clinical neuro-ophthalmology. In order to get the best out of imaging, scans should be requested to look for specific regions of the brain guided by the clinical findings. For example, it would be more appropriate to request an MRI scan of the cavernous sinuses and orbits instead of the whole brain in a case of cavernous sinus syndrome. For suspected orbital disorders a thin section CT scan through the orbit may be more useful than an MRI scan.

Electrophysiological investigation is of use in certain clinical circumstances when, for example, myasthenia gravis is suspected. Although it is usual to request electromyography (EMG) and nerve conduction studies with a repetitive stimulation test as standard investigations for myasthenia gravis, single fibre EMG (SFEMG) may be valuable because it is much more sensitive.

### TREATMENT OF BINOCULAR DIPLOPIA

The most logical treatment is to cure the pathology, if this is possible. However, symptomatic treatment is equally important in patients with disabling diplopia. A simple measure for treating binocular diplopia is unilateral eye occlusion therapy, either with an eye patch or by blurring one lens of the patient's glasses with semi-opaque surgical tape. Fresnel prisms can be used to realign the visual axes and may be incorporated on to the patient's existing glasses. They are very helpful in the case of horizontal or vertical diplopia but have virtually no effect on the torsional component. In addition, prism therapy can be problematic in the recovery phase because of the changing degree of misalignment, and prisms of differing strength are frequently required as recovery progresses. Driving regulations should be consulted.

Surgical treatment for strabismus is well established. It is usually offered when complete recovery is not achieved in 6–12 months and other treatments have failed. Botulinum toxin is increasingly popular as a treatment for strabismus. It is usually injected into the antagonist of the parietic muscle and the effect of a single injection can last for up to 3–6 months.

### EYE MOVEMENT DISORDERS

Eye movement disorders can be seen in a wide variety of disease processes affecting the central nervous system. Clinical examination of dynamic eye movements often yields useful information that can be used for neurological diagnosis. The relevant basic knowledge of eye movements and practical points for their clinical use are reviewed in this section.

### Functional class of eye movements

The various types of eye movements subserve the same goal—the projection and maintenance of an image of the object of interest onto the high resolution part of the retina, the fovea. A saccade, a rapid conjugate eye movement, is the most efficient way to bring the image of a new object of interest onto the fovea. Vergence eye movements ensure that the image of the object of interest is simultaneously projected onto both foveae, regardless of its distance from the observer. Images of a moving object are kept stabilised on the fovea by pursuit eye movements. Vestibular and optokinetic systems keep the images steady on the fovea and adjust the visual axes to the movement of the subject's head or body. These different types of eye movement can be rapidly examined both at the bedside and by eye movement recording devices.

## CLINICAL EXAMINATION OF EYE MOVEMENTS

### Fixation

Fixation should be observed in the primary gaze position by asking the patient to fixate on a particular object for at least 30 seconds. The eye is never completely still during fixation, because it is interrupted by miniature eye movements (microsaccades, continuous microdrift, and microtremor), which are invisible with the naked eye and the ophthalmoscope. The only physiologic saccadic intrusion that may be observed is the square wave jerk (SWJ)—spontaneous, horizontal saccades of about  $0.5^\circ$  that take the eyes off the target, followed about 200 ms later by a corrective saccade. This can be observed in most normal individuals at a rate up to 15 per minute. An increased number of SWJs is seen in cerebellar disease, progressive supranuclear palsy, and multiple system atrophy.

During fixation saccadic oscillations and nystagmus should also be noted. If nystagmus is present, further examination may provide useful information for disease localisation. This includes observing the nystagmus in various gaze positions and removing fixation by the use of Frenzel's goggles.

### Saccades

Voluntary saccade initiation should be assessed by instructing the patient to look to the left, right, up, and down. Reflexive saccades can be tested by asking the patient to fixate two targets alternately so that between each refixation the targets are briefly moved and their distance from each other varied. In addition to the range of movement, the examiner should observe for speed of initiation (latency), saccadic velocity, and accuracy (undershoot or overshoot). Saccadic hypometria (undershoot) is non-specific and may be seen in a number of neurological conditions, including cerebellar disorder, Parkinson's disease, and Huntington's disease. On the other hand, saccadic hypermetria is usually caused by cerebellar dysfunction.

Any slowing of saccades can be accentuated by using an optokinetic striped drum. This method is helpful for showing slowed adducting saccades in partial internuclear ophthalmoplegia, which may be missed if examined by pursuit movement alone. Another method to enhance this abnormality is to use oblique targets, which will result in an L shaped saccade because the velocity is relatively slower in the horizontal than the vertical plane. The examiner should also look for blinks or head thrusts towards the target before making a saccade, as occurs in Huntington's disease and ocular motor apraxia.

### Smooth pursuit

Both horizontal and vertical pursuit eye movements can be examined by instructing the patient to track a small target at about 1 m distance, while keeping the head still. The target should be moved at a slow and uniform speed and the examiner should observe the smoothness of the following eye movement. Broken pursuit is a non-specific sign if present in both directions and may occur with fatigue and anti-convulsant drugs. However, if broken pursuit is seen in only one direction, it may indicate a focal posterior cortical lesion ipsilateral to the direction of broken pursuit.

### Vergence

The vergence system can be examined by asking the patient to track an object that is gradually brought closer to the patient's nose. Alternatively, vergence eye movement can also be examined by telling the patient to look to the distance and then focus onto a close object. Normal subjects should be able to keep the image single up to the tip of the nose and the resulting convergence should be accompanied by accommodative reflexes. However, inability to converge is not always pathologic as many people are not good "convergers". Patients with convergence insufficiency usually present in early adulthood with eye strain, double vision, and difficulty maintaining near visual function that may respond to convergence exercise therapy. This condition is usually benign but may be caused by closed head trauma or viral encephalitis. On the other hand, convergence paralysis—total failure of convergence with normal adduction that results in constant diplopia at near—usually requires further investigation to exclude midbrain pathology and toxic encephalopathy.

### Optokinetic nystagmus (OKN)

The optokinetic system cannot be properly assessed at bedside because the OKN drum commonly used examines smooth pursuit and not the optokinetic system. A full-field revolving striped drum is required to elicit "true" OKN.

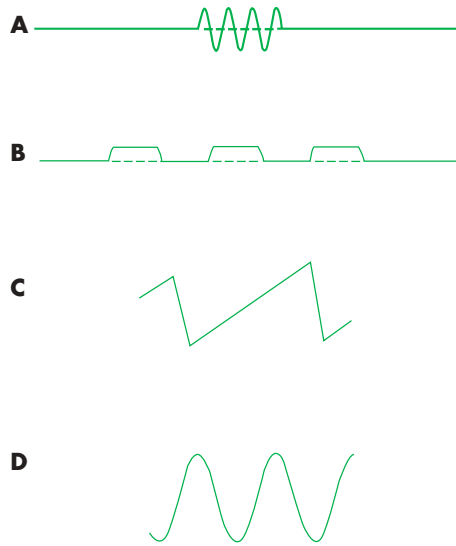
### Vestibular system

This is discussed by Davies (see p iv32).

## ABNORMALITIES OF HORIZONTAL AND VERTICAL GAZE

### Abnormal horizontal eye movement

Unilateral horizontal gaze palsy for all types of conjugate eye movements is seen in lesions affecting the ipsilateral abducens nucleus. This is based on the fact that the abducens nucleus (CN VI) contains the motor neurons innervating the ipsilateral lateral rectus muscle and in addition sends signals to the contralateral medial rectus subdivision of the oculomotor nerve nucleus (CN III). This syndrome is usually associated with an ipsilateral lower motor neurone facial palsy caused by involvement of the fascicles of the facial nerve as they course around the abducens nucleus. A selective horizontal gaze palsy that involves the saccadic system but not the pursuit eye and vestibular movements is seen as a result of a lesion affecting the premotor region, the paramedian pontine reticular formation (PPRF). The most common causes of horizontal gaze palsies are either vascular infarction and haemorrhage or demyelination. Lesions involving the PPRF can also cause a bilateral selective saccadic palsy with preservation of vestibular and optokinetic



**Figure 4** Common waveforms of saccadic oscillations and nystagmus. (A) Ocular flutter. Note back-to-back saccade without fixation between saccades. (B) Square wave jerks. Fixation of approximately 200 ms between two saccades. (C) Jerk nystagmus; slow phase and fast phase. (D) Pendular nystagmus; equal velocities in both phases.

eye movements, although impairment of vertical eye movements may also be seen.

### Internuclear ophthalmoplegia

A lesion of the medial longitudinal fasciculus (MLF) results in an internuclear ophthalmoplegia (INO), in which there is a disturbance of adduction ipsilateral to the side of the lesion and also nystagmus of the contralateral abducting eye. In a partial INO, adduction will be slowed but it will be completely absent in a complete lesion. Convergence should be examined and intact convergence usually indicates a more caudal lesion (posterior INO). In contrast, absent convergence is seen in a rostral lesion (anterior INO) as the medial rectus subdivision of the contralateral oculomotor nucleus will also be affected. The most common causes of INO include demyelination and vascular infarction. Bilateral INO is very suggestive of a demyelinating process and it can cause in addition impaired vertical pursuit and vestibular eye movements, and impaired vertical gaze holding with gaze evoked nystagmus on looking up and down. More extensive lesions affecting both MLFs and the abducens nucleus on one side only results in a one-and-a-half syndrome. The only preserved horizontal eye movement is abduction of the contralateral eye. The main causes of one-and-a-half syndrome are brainstem ischaemia, haemorrhage, and tumour.

### Abnormalities of vertical eye movements

Disturbances of vertical gaze are usually associated with damage to either the posterior commissure, the vertical equivalent of the PPRF, the rostral interstitial nucleus of the medial longitudinal fasciculus (riMLF), and the interstitial nucleus of Cajal, or a combination of these structures. Interpretation of limited vertical gaze should be undertaken with care because restricted upward gaze is seen in the normal elderly. Downward gaze palsy is usually pathologic and may be seen in brainstem lesions and certain neurodegenerative disorders such as progressive supranuclear palsy or adult Niemann-Pick disease. Dorsal midbrain syndrome

(Parinaud's syndrome) is caused by a lesion that affects the posterior commissure and results in skew deviation, light-near dissociation of pupil constriction, and convergence-retraction nystagmus, in addition to a vertical gaze palsy. The common causes are pineal tumour and hydrocephalus, and it can be secondary to drugs such as barbiturates, neuroleptics, and carbamazepine. When this syndrome is acute, the eyes are tonically deviated downwards (the setting sun sign), and this sign is well described in premature infants following intraventricular haemorrhage.

### DIAGNOSIS OF SACCADIC OSCILLATIONS AND NYSTAGMUS

It is important to distinguish saccadic oscillations from nystagmus because the mechanism and pathology responsible for these disorders can be significantly different (fig 4). Saccadic oscillations are sustained oscillations initiated by fast saccadic eye movements. In contrast, the oscillation in nystagmus is initiated by a smooth eye movement followed by a corrective saccade. Although the direction of nystagmus is usually described by the fast phase (corrective saccade), it is the slow phase that indicates the underlying pathology.

#### Saccadic oscillations

Saccadic oscillations are bursts of saccades, which may be intermittent or continuous, causing disruption of fixation. Oscillations without any intersaccadic interval (back-to-back saccades) include opsoclonus, ocular flutter, and convergence-retraction saccadic pulses (incorrectly called convergence-retraction nystagmus). Opsoclonus is characterised by multidirectional back-to-back saccades of varying amplitude and direction. This is seen in a variety of posterior fossa disorders and most commonly as a paraneoplastic syndrome, which in children is associated with neuroblastoma and in adults with small cell carcinoma of the lung and carcinoma of the breast and uterus. Antineuronal antibodies, including anti-Ri, and a cancer screen are indicated in patients with opsoclonus. Ocular flutter consists of bursts of back-to-back saccades exclusively in the horizontal plane. Isolated ocular flutter might be seen in 8% of the population (voluntary flutter induced by convergence—incorrectly termed voluntary nystagmus), but may also be seen in multiple sclerosis. Ocular bobbing consists of rhythmic downward jerks of the eyes followed by a slow return to the midposition. It is associated with pontine haemorrhage or infarction, which might also cause concurrent horizontal gaze palsies, and metabolic or toxic disorders. Symptomatic treatment for

**Table 2** Features of peripheral and central vestibular nystagmus

Peripheral vestibular	Central vestibular
▶ Combination of horizontal, vertical and torsional nystagmus	▶ Unidirectional
▶ Associated with severe vertigo	▶ Mild or no vertigo
▶ Quick phase beating away from the underactive labyrinth	▶ May be gaze evoked
▶ Amplitude increases with gaze toward the direction of quick phase	▶ No change in amplitude with fixation or when fixation is removed
▶ Notably suppressed by fixation	



saccadic abnormalities is not yet available but these conditions may resolve with time or once the cause has been treated.

### Nystagmus

Nystagmus can be classified into two categories based on the velocity of both phases. When the slow movement that takes the eye away from the target is followed by a fast phase, it is called jerk nystagmus, and if both phases have equal velocity, pendular nystagmus is observed. Patients with nystagmus usually have other brainstem, cerebellar, and vestibular symptoms and signs, which should be considered for diagnosis purposes. Although nystagmus almost always prompts the clinician to identify the cause, symptomatic treatment of nystagmus is indicated only when "oscillopsia"—illusion of movement of the seen world—is present.

The most common form of jerk nystagmus is vestibular nystagmus. It is most frequently a result of damage to the vestibular apparatus that may be either peripheral (labyrinth, vestibular nerve) or central (brainstem). These two categories can be distinguished clinically by careful observation of the features described in table 2.

Downbeat nystagmus, a jerk nystagmus with the quick phase moving downwards, is seen in bilateral disturbance of the cerebellar flocculus and lesions at the cranio-cervical junction, such as Chiari malformation type 1. Other causes include cerebellar degeneration, anticonvulsant and lithium intoxication, and intra-axial brainstem lesions; however, no cause can be identified in half of the patients. Symptomatic treatment for downbeat nystagmus is rather limited, but gabapentin and 3, 4-diaminopyridine are worth trying. Upbeat nystagmus, when present in the primary position, is usually associated with focal brainstem lesions in the tegmental grey matter. The most common causes are multiple sclerosis, tumour, infarction, and cerebellar degeneration.

Torsional jerk nystagmus is usually seen in combination with other types of nystagmus. However, pure torsional nystagmus indicates a lesion of the lateral medulla involving the vestibular nuclei. Periodic alternating nystagmus (PAN) is a primary position horizontal nystagmus that changes direction in a crescendo-decrescendo fashion, characteristically every 90 seconds, with a null period of 0–10 seconds between each directional change. This condition can be congenital or associated with various lesions at the brainstem and cranio-cervical junction, and anticonvulsant intoxication. Baclofen has been shown to be effective in PAN and the response is usually dramatic.

Gaze evoked nystagmus, a jerk nystagmus present only on eccentric gaze but not in the primary position, is commonly seen and has limited localising value. Bilateral horizontal and vertical gaze evoked nystagmus commonly occurs with structural brainstem and cerebellar lesions, diffuse metabolic disorder, and drug intoxication.

Pendular nystagmus can be either congenital or acquired. The acquired form is usually seen in multiple sclerosis, visual loss (including unilateral optic neuropathy), brainstem ischaemia, and spinocerebellar degenerations. It can affect one eye or both, equally or unequally, and often results in oscillopsia. When it is present in association with palatal myoclonus, oculopalatal myoclonus, the lesion usually involves the red nucleus, dentate nucleus, and inferior olivary nucleus (Mollaret's triangle). In see-saw nystagmus, one eye intorts and rises while the other eye extorts and falls in a

rapidly alternating sequence. It usually signifies a parasellar lesion that may also cause bitemporal hemianopia.

Congenital nystagmus is almost invariably a horizontal conjugate nystagmus unaltered by vertical position. Certain features are characteristic of congenital nystagmus including worsening on fixation, improvement on convergence, and the presence of a null point—a position of gaze where the nystagmus is minimal or absent. Latent nystagmus is a type of congenital nystagmus that is only present on monocular viewing and beats toward the viewing eye.

### EYE MOVEMENT RECORDINGS

Most abnormalities of ocular motility and alignment can be detected during clinical examination. However, subtle abnormalities of pursuit, saccadic, optokinetic, and vestibulo-ocular system may require eye movement recording devices that provide quantitative analysis. The most commonly used methods are electro-oculography (EOG) and infrared oculography. These techniques may be able to distinguish between myopathic and neuropathic conditions that affect ocular motility and can be used to follow the response or progression. In addition, quantitative analysis of nystagmus and saccadic intrusion is made available with high accuracy.

EOG is a recording technique which allows the standing potential between the cornea and the posterior pole of the eye to be recorded. Electrodes are placed at the inner and outer canthi of the eye to the left or right. It provides reasonable recording of horizontal eye movement but is of limited value in the vertical plane due to eyelid artefacts and non-linearities. Infrared oculography provides higher resolution of both horizontal and vertical eye movements. The newer generation of video based eye tracker (infrared camera) can be operated at the temporal resolution of up to 500 Hz, which can reliably detect subtle abnormality and saccades. However, both EOG and infrared oculography are not able to detect torsional movements of the eye. The only device that can detect all types of eye movements is a magnetic scleral search coil. The coil is embedded in a special contact lens that adheres to the sclera by suction and the recording is done in a magnetic fields. This method yields the highest resolution of measurement, but requires extensive setup and is slightly invasive.

### Authors' affiliations

**C Danchavijitr, C Kennard**, Department of Visual Neuroscience, Division of Neuroscience and Psychological Medicine, Imperial College, London, UK

### REFERENCES

- 1 Miller NR, Newman NJ, eds. *Walsh & Hoyt's clinical neuro-ophthalmology—the essentials*, 5th ed. Baltimore: Williams & Wilkins, 1998.
- 2 Leigh RJ, Zee DS. *The neurology of eye movements*, 3rd ed. Oxford University Press, 1999.
- 3 Liu G, Volpe N, Galetta S. *Neuro-ophthalmology: diagnosis and management*, Saunders, 2000.
- 4 Kennard C. Normal and abnormal eye movements. In: Luxon L, ed. *A textbook of audiological medicine: clinical aspects of hearing and balance*. London: Martin Dunitz, 2003:781–96.
- 5 Leigh RJ, Kennard C. Using saccades as a research tool in the clinical neurosciences. *Brain* 2004;127(Pt 3):460–77.
- 6 Stahl JS, Plant GT, Leigh RJ. Medical treatment of nystagmus and its visual consequences. *J R Soc Med* 2002;95:235–7.
- 7 Halmagyi GM, Rudge P, Gresty M, et al. Treatment of periodic alternating nystagmus. *Ann Neurol* 1980;8:609–11.
- 8 Strupp M, Schuler O, Krafczyk S, et al. Treatment of downbeat nystagmus with 3, 4-diaminopyridine: a placebo-controlled study. *Neurology* 2003;61:165–70.